

Endometriosis of the Appendix: A Narrative review

Abstract

Endometriosis of the appendix is condition that is seen in young women, and it clinically presents with chronic lower abdominal pain. It is one of the sites of extra pelvic endometriosis and it is confirmed on histopathological evaluation of the appendix. The dilemma for the surgeon is if an appendectomy is to be performed or not. The introduction of laparoscopic surgery has made visualization of the pelvis and appendix easier, and we have conducted this narrative review article to see if an appendectomy should be performed in all cases of endometriosis.

Keywords-Appendicular endometriosis, incidental appendectomy, intestinal endometriosis, endometriosis, and laparoscopic appendectomy

Introduction

Endometriosis is a disease of the female genital tract that is characterized by growth of endometrial like tissue that occurs outside the uterine cavity. It is seen in women of childbearing age among those aged 25 to 35 years of age. Endometriosis of the gastrointestinal tract is seen in 12% to 37% of cases, with the most common sites being the rectosigmoid, appendix, caecum, and terminal ileum. The prevalence of endometriosis of the appendix is 2.6% to 13% and they present as acute appendicitis or appendicular mass and it is 1% to 44.3% in those who underwent gynecological surgery. The site of involvement is the serosal region, and the deeper involvement includes the muscular and submucosal regions.(1–6)

Endometriosis of the appendix can clinically present with no symptoms of chronic right sided abdominal pain. They can also present as acute appendicitis and the definitive diagnosis is achieved after histopathological examination of the appendix.(7,8) The benefits of performing an appendectomy for patients with endometriosis of the appendix is that it improves the symptoms of chronic abdominal pain and eliminates the risk of future appendicitis. There is a role for performing an incidental appendectomy during gynecological surgery for endometriosis as it is associated with reduced morbidity and mortality.(9–13)

The introduction of laparoscopic surgery has made the diagnosis and treatment of endometriosis of the appendix easier as it is associated with reduced post operative complications and faster recovery.(14)

There are several risk factors that are associated with endometriosis of the appendix, which include, adenomyosis, right large endometrioma, bladder endometriosis, deep posterior pelvic endometriosis, left deep lateral pelvic endometriosis and ileocecal endometriosis.(15)

The risk of endometriosis of the appendix among women with deep- infiltrating endometriosis is high and warrants the removal of the appendix during surgical treatment for endometriosis.

The pathogenesis of endometriosis is based on three theories, retrograde menstruation with implantation and failure of immunological clearance, coelomic metaplasia and hematological and lymphatic metaplasia.(16,17)

Method

Currently there is no uniform consensus on the management of endometriosis of the appendix, and we have conducted this review article to investigate the role of appendectomy in endometriosis and the role of laparoscopic surgery. We conducted a literature review using PUBMED, Cochrane database of clinical reviews and Google scholar looking for clinical trial, observational studies, cohort studies, case studies, systemic reviews, and meta-analysis from 1970 to 2023. We used the following keywords, “appendicular endometriosis”, “incidental appendectomy”, “intestinal endometriosis”, “laparoscopic Appendectomy”, “endometriosis”. All articles were in English language only. Further articles were obtained by manual cross referencing of the literature and studies with less than 10 patients and editorials were excluded.

Results and Discussion

Role of laparoscopic appendectomy in endometriosis of the appendix

The introduction of laparoscopic surgery in the management of patients presenting with chronic pain in the lower abdomen or endometriosis has made inspection and removal of the appendix important as it may be associated with the symptoms of abdominal pain.(18) The retrospective study by berker et al showed that out of 231 patients who underwent appendectomy, abnormal pathology was detected in 115 patients with endometriosis of the appendix being the most common pathology. This study concluded that removal of the appendix is justified during gynecological surgery for endometriosis.(19)

Laparoscopic appendectomy is useful for patients who present with chronic abdominal pain due to endometriosis as it allows inspection of the peritoneal cavity and visualization of the pelvic organs. Inspection of the appendix can be done during laparoscopy and the decision to perform appendectomy can be done. Laparoscopic appendectomy is also associated with reduced morbidity and early ambulation.(20–24)

Nikou et al in their retrospective study on 135 patients who underwent laparoscopy for endometriosis and had undergone concurrent appendectomy. The prevalence of endometriosis of the appendix was 18% and they concluded that appendectomy should be performed during laparoscopy for endometriosis.(25)

Shavell et al evaluated the intraoperative findings and histopathology of the appendix in their retrospective study on patients undergoing benign gynecological surgery and their results showed that up to 68.2% of the cases showed abnormal pathology of the appendix. This study concluded that inspection of the appendix was important when deciding to perform an appendectomy.(26)

Harris et al in their nonrandomized control trial on 65 patients who had undergone laparoscopy for symptomatic endometriosis and 52 had undergone appendectomy. The histological examination of the appendix had revealed abnormal histology in 75% of the cases and this study concluded that inspection of the appendix was important during laparoscopy and if abnormal it should be removed.(27)

Alsallili et al prospectively evaluated the histology and outcomes of patients who underwent an appendectomy during laparoscopy for chronic lower abdominal pain. A total of 100 patients had undergone appendectomy and up to 20% of the specimen were positive for endometriosis. This study highlighted the importance of performing an appendectomy during chronic abdominal pain and the safety of laparoscopy. This was also confirmed by a retrospective study by chao et al and Lyons et al on the value of diagnostic laparoscopy on patients with chronic pelvic pain.(28–30)

A review by peters et al on the safety and efficacy of appendectomy being performed during laparoscopic surgery for benign gynecological conditions and they concluded that appendectomy should be performed in benign gynecological conditions like endometriosis and the procedure is safe and associated with low morbidity.(31)

Lee et al conducted a retrospective study on the safety and efficacy of incidental appendectomy during laparoscopic surgery for ovarian endometrioma.356 patients were included in the study and 172 underwent an interval appendectomy. Of the 172-appendix specimens,52 had an abnormal presentation and 16 had endometriosis. This study concluded that incidental appendectomy does not increase the morbidity, operative time and it is diagnostic.(32)

The conclusion from all these studies was that appendectomy should be performed for patients who undergo surgery for chronic abdominal pain due to endometriosis. The only drawback was that most of the studies were retrospective in nature.

Histopathological examination of endometriosis of the appendix

The histopathological examination of the appendix specimen is important to establish a diagnosis for patients who have undergone an appendectomy, with gynecological conditions like endometriosis among the causes of right lower abdominal pain. The diagnosis of endometriosis is confirmed by surgical excision and histopathological evaluation.(33–36) A systemic review and meta-analysis by bastiaenen et al on the routine histopathological examination of the appendix after appendectomy is important to establish a diagnosis of unexpected conditions like endometriosis or malignancy.(37)

Ross et al histologically evaluated the appendix specimen in patients with endometriosis who had underwent appendectomy. In their retrospective study up to 14.9% of cases had a histological diagnosis of endometriosis and this study highlights the importance of performing appendectomy when patients are undergoing surgical management for chronic abdominal pain for endometriosis.(38)

Misdraji et al also conducted a retrospective study on the histological evaluation of patients who had undergone appendectomy for endometriosis and this study showed obliteration of the lumen with infiltration of endometrial like stromal cells with no evidence of malignancy. This study highlighted the importance of histological evaluation of the appendix.(39)

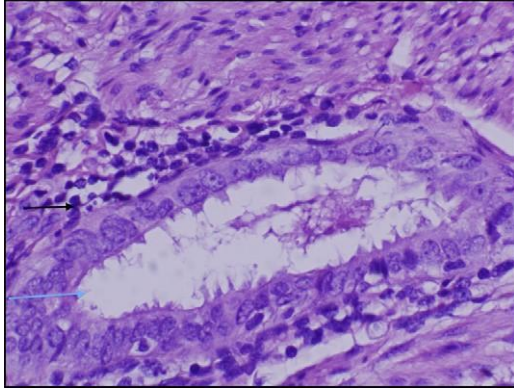
Chandrasegaran et al analyzed pathologies of the appendix in 2284 female patients and the negative appendectomy rate were 31%. Of these up to 14 cases were diagnosed as endometriosis of the appendix. This study highlighted the importance of endometriosis as one of the causes of negative appendectomy.(40)

Noor et al retrospectively assessed 51 specimens of appendiceal endometriosis and the histology revealed involvement of the serosal and muscular area, with obliteration of the lumen. This highlights the importance of histological evaluation of the appendix.(41)

A systemic review of the literature by swank et al on the routine histological evaluation of the appendectomy specimen showed that although the incidence of finding abnormal findings is low but histopathological evaluation of the appendix is still important and should be practiced.(42)

These studies highlighted the importance of histological evaluation of the appendix after performing an appendectomy.

Image 1 Microscopic examination of the appendix showing endometrial tissue in the appendix specimen



| Author | Sample size(N) | Study design | Prevalence of endometriosis |
|---------------------|----------------|----------------------------------|-----------------------------|
| Harris et al(2001) | 52 | Nonrandomized clinical trial | 31% |
| Berker et al(2005) | 231 | Retrospective study | 44.3% |
| Moulder et al(2017) | 1876 | Retrospective study | 13.2% |
| Coratti et al(2020) | 149 | Observational case control study | 14.7% |
| Ross et al(2021) | 609 | Retrospective study | 14.9% |
| Nikou et al(2021) | 135 | Retrospective study | 18% |

Table 1 Table on the prevalence of endometriosis of the appendix

Conclusion

The importance of performing an appendectomy in patients presenting with chronic lower abdominal pain or for asymptomatic patients with endometriosis highlights this condition which can be confirmed by histopathological evaluation. The use of diagnostic laparoscopy highlights the importance of inspecting the appendix and performing an appendectomy. In patients who undergo other gynecological procedures, an incidental appendectomy is usually encouraged to rule out endometriosis and prevent future causes of chronic abdominal pain. Gross appearance of the appendix may not reveal any abnormality; hence appendectomy and histological evaluation is important to establish a diagnosis of this condition.

Conflict of interest

There is no conflict of interest.

References

1. Agarwal N, Subramanian A. Endometriosis - Morphology, clinical presentations and molecular pathology. *J Lab Physicians*. 2010 Jan;2(01):001–9.
2. Bergqvist A. Different types of extragenital endometriosis: a review. *Gynecol Endocrinol*. 1993;7(3):207-221. doi:10.3109/09513599309152504
3. Cristescu C, Velişcu A, Marinescu B, Pătraşcu A, Traşcă ET, et al. O OR RI IG GI IN NA Endometriosis-clinical approach based on histological findings. *Rom J Morphol Embryol [Internet]*. 2013;54(1):91–7. Available from: <http://www.rjme.ro/>
4. Falcone T, Flyckt-Rebecca R. Clinical management of endometriosis. *Obstetrics and Gynecology*. 2018;131(3):557–71.
5. Khetan N, Torkington J, Watkin A, Jamison MH, Humphreys WV. Endometriosis: presentation to general surgeons. *Ann R Coll Surg Engl*. 1999;81(4):255-259.
6. Seydel AS, Sickel JZ, Warner ED, Sax HC. Extrapelvic endometriosis: diagnosis and treatment. *Am J Surg*. 1996;171(2):239. doi:10.1016/S0002-9610(97)89557-8
7. Coratti F, Vannuccini S, Foppa C, Staderini F, Coratti A, Cianchi F, et al. Emergency surgery for appendectomy and incidental diagnosis of superficial peritoneal endometriosis in fertile age women. *Reprod Biomed Online*. 2020 Oct 1;41(4):729–33.
8. Khoo JJ, Ismail MSA, Tiu CC. Endometriosis of the appendix presenting as acute appendicitis. *Singapore Med J*. 2004 Sep;45(9):435–6.
9. Allahqoli L, Mazidimoradi A, Momenimovahed Z, et al. Appendiceal Endometriosis: A Comprehensive Review of the Literature. *Diagnostics (Basel)*. 2023;13(11):1827. Published 2023 May 23. doi:10.3390/diagnostics13111827
10. Singh KK, Lessells AM, Adam DJ, et al. Presentation of endometriosis to general surgeons: a 10-year experience. *Br J Surg*. 1995;82(10):1349-1351. doi:10.1002/bjs.1800821017
11. Adeboye A, Ologun GO, Njoku D, Miner J. Endometriosis of the Vermiform Appendix Presenting as Acute Appendicitis. *Cureus*. 2019;11(10):e5816. Published 2019 Oct 1. doi:10.7759/cureus.5816
12. Uohara JK, Kobara TY. Endometriosis of the appendix. Report of twelve cases and review of the literature. *Am J Obstet Gynecol*. 1975 Feb 1;121(3):423–6.
13. Mittal VK, Choudhury SP, Cortez JA. Endometriosis of the appendix presenting as acute appendicitis. *Am J Surg*. 1981;142(4):519-521. doi:10.1016/0002-9610(81)90389-5
14. Bandeira Domiciano C, De Araújo Alves PA, Xavier da Nóbrega Pereira ALG, Gadelha e Xavier B, Nascimento de Oliveira DC, De Carvalho Nobre Felipe DH, et al. ENDOMETRIOSIS OF THE CECUM AND APPENDIX: REVIEW OF LITERATURE. *Brazilian Journal of Implantology and Health Sciences*. 2023 May 5;5(2):121–9.

15. Mabrouk M, Raimondo D, Mastronardi M, Raimondo I, Del Forno S, Arena A, et al. Endometriosis of the Appendix: When to Predict and How to Manage—A Multivariate Analysis of 1935 Endometriosis Cases. *J Minim Invasive Gynecol*. 2020 Jan 1;27(1):100–6.
16. Moulder JK, Siedhoff MT, Melvin KL, Jarvis EG, Hobbs KA, Garrett J. Risk of appendiceal endometriosis among women with deep-infiltrating endometriosis. *International Journal of Gynecology and Obstetrics*. 2017 Nov 1;139(2):149–54.
17. Justin Hale C, Benjamin Scott C, Camille Suydam C, Joel Brockmeyer L. Endometriosis of the Appendix: When Appendicitis Is Less Than Straightforward. *Mil Med [Internet]*. :2023. Available from: <https://academic.oup.com/milmed/advance-article/doi/10.1093/milmed/usad233/7207952>
18. Al Oulaqi NS, Hefny AF, Joshi S, Salim K, Abu-Zidan FM. Endometriosis of the appendix. *Afr Health Sci*. 2008;8(3):196-198.
19. Berker B, LaShay N, Davarpanah R, Marziali M, Nezhat CH, Nezhat C. Laparoscopic appendectomy in patients with endometriosis. *J Minim Invasive Gynecol*. 2005 Jun;12(3):206–9.
20. Yoon J, Lee YS, Chang HS, Park CS. Endometriosis of the appendix. *Ann Surg Treat Res*. 2014 Sep 1;87(3):144–7.
21. St. John BP, Snider AE, Kellermier H, Minhas S, Nottingham JM. Endometriosis of the appendix presenting as acute appendicitis with unusual appearance. *Int J Surg Case Rep*. 2018 Jan 1;53:211–3.
22. Croce E, Olmi S, Azzola M, Russo R. Laparoscopic appendectomy and minilaparoscopic approach: a retrospective review after 8-years' experience. *JSLs*. 1999;3(4):285-292.
23. Gon S, Barui GN, Majumdar B, Baig SJ. Endometriosis of the appendix: A diagnostic dilemma. *Indian Journal of Surgery*. 2010 Jul;72(S1):315–7.
24. Gupta R, Singh AK, Farhat W, Ammar H, Azzaza M, Mizouni A, et al. Appendicular endometriosis: A case report and review of literature. *Int J Surg Case Rep*. 2019 Jan 1;64:94–6.
25. Nikou AF, Tenzel NS, Hua P, Orbuch L, Orbuch IK. Appendectomy should be performed during minimally invasive surgery for endometriosis. *Journal of the Society of Laparoendoscopic Surgeons*. 2021 Jan 1;25(1).
26. Shavell VI, Mahdi HM, Awonuga AO, Edelman DA, Webber JD, Gidwani RM, et al. Appendectomy in the gynecological setting: Intraoperative findings and corresponding histopathology. *Gynecol Obstet Invest*. 2011 Apr;71(3):189–92.
27. Harris RS, Foster WG, Surrey MW, Agarwal SK. Appendiceal disease in women with endometriosis and right lower quadrant pain. *Journal of the American Association of Gynecologic Laparoscopists*. 2001;8(4):536–41.
28. AlSalilli M, Vilos GA. Prospective evaluation of laparoscopic appendectomy in women with chronic right lower quadrant pain. *J Am Assoc Gynecol Laparosc*. 1995;2(2):139-142. doi:10.1016/s1074-3804(05)80007-6

29. Chao K, Farrell S, Kerdelmelidis P, Tulloh B. Diagnostic laparoscopy for chronic right iliac fossa pain: a pilot study. *Aust N Z J Surg.* 1997;67(11):789-791. doi:10.1111/j.1445-2197.1997.tb04581.x
30. Lyons TL, Winer WK, Woo A. Appendectomy in Women with Pelvic Pain Lyons et al Appendectomy in Patients Undergoing Laparoscopic Surgery for Pelvic Pain. Vol. 8, *JOURNAL OF THE AMERICAN ASSOCIATION OF GYNECOLOGIC LAPAROSCOPISTS.* 2001.
31. Peters A, Mansuria SM. The role of appendectomy at the time of laparoscopic surgery for benign gynecologic conditions. Vol. 30, *Current Opinion in Obstetrics and Gynecology.* Lippincott Williams and Wilkins; 2018. p. 237–42.
32. Lee JH, Choi JS, Jeon SW, Son CE, Bae JW, Hong JH, et al. Laparoscopic incidental appendectomy during laparoscopic surgery for ovarian endometrioma. *Am J Obstet Gynecol.* 2011;204(1):28.e1-28.e5.
33. Langman J, Rowland R, Vernon-Roberts B. Endometriosis of the appendix. *Br J Surg.* 1981;68(2):121-124. doi:10.1002/bjs.1800680218
34. Douglas C, Rotimi O. Extragenital endometriosis - A clinicopathological review of a Glasgow hospital experience with case illustrations. *J Obstet Gynaecol (Lahore).* 2004 Oct;24(7):804–8.
35. Engin O, Calik B, Yildirim M, Coskun A, Coskun GA. Gynecologic pathologies in our appendectomy series and literature review. *J Korean Surg Soc.* 2011 Apr;80(4):267–71.
36. Stratton P, Winkel C, Premkumar A, et al. Diagnostic accuracy of laparoscopy, magnetic resonance imaging, and histopathologic examination for the detection of endometriosis. *Fertil Steril.* 2003;79(5):1078-1085. doi:10.1016/s0015-0282(03)00155-9
37. Bastiaenen VP, Allema WM, Klaver CEL, van Dieren S, Koens L, Tanis PJ, et al. Routine histopathologic examination of the appendix after appendectomy for presumed appendicitis: Is it really necessary? A systematic review and meta-analysis. *Surgery (United States).* 2020 Aug 1;168(2):305–12.
38. Ross WT, Newell JM, Zaino R, Kunselman AR, Harkins GJ, Benton AS. Appendiceal Endometriosis: Is Diagnosis Dependent on Pathology Evaluation? A Prospective Cohort Study. *J Minim Invasive Gynecol.* 2020 Nov 1;27(7):1531–7.
39. Misdraji J, Graeme-Cook FM. Miscellaneous conditions of the appendix. *Semin Diagn Pathol.* 2004;21(2):151–63.
40. Chandrasegaram MD, Rothwell LA, An EI, Miller RJ. Pathologies of the appendix: A 10-year review of 4670 appendectomy specimens. *ANZ J Surg.* 2012 Nov;82(11):844–7.
41. Noor M, Chen A, Gonzalez RS. Clinicopathologic findings in gynecologic proliferations of the appendix. *Hum Pathol.* 2019 Oct 1;92:101–6.
42. Swank HA, Eshuis EJ, Ubbink DT, Bemelman WA. Is routine histopathological examination of appendectomy specimens useful? A systematic review of the literature. Vol. 13, *Colorectal Disease.* 2011. p. 1214–21.

