

Case study

MULTICENTRIC CASTLEMAN DISEASE; A RARE CASE OF GENERALISED LYMPHADENOPATHY IN INDIA

ABSTRACT:

Castleman disease (CD) is a type of hematological disorder, classified based on the number of the regions of enlarged lymph node, histopathological features, and association with human herpes virus 8. It may be unicentric with single region of the lymph node enlarged, or multicentric with multiple regions of lymphadenopathy. Some cases of Multicentric Castleman Disease (MCD) are caused by human herpes virus 8 (75%) while in others it is HHV8 negative. The epidemiology of idiopathic MCD is poorly understood due to lack of diagnosis since it is a difficult clinical diagnosis and also require analysis from a pathologist that is not available worldwide. Diagnosis and treatment are incredibly challenging as it can presents with wide array of manifestation from asymptomatic to systemic manifestation. There is no exact treatment guideline, Anti IL6 monoclonal antibody with or without systemic steroid is the mainstay of treatment. Here, we report a case that was initially suspected to have a lymphoma but later histologically was confirmed to have Multicentric Castleman's Disease. Here we report a case of forty-year-old man with history of chronic fever & constitutional symptoms, anasarca, exertional dyspnea, easy fatiguability, palpitation and generalized lymphadenopathy on physical examination which later diagnosed as Multicentric Castleman Disease. He had bicytopenia, raised inflammatory markers, lymph node biopsy revealed Castleman disease like picture. All the possible differential diagnosis had been ruled out with respective investigations. He was treated with steroid and IL6 inhibitor Tocilizumab and the patient improved remarkably.

Keywords: Castleman disease (CD), HHV8, Unicentric, Multicentric Castleman Disease (MCD), Tocilizumab

Introduction:

Castleman's disease is an uncommon B-cell disorder characterized by non-neoplastic lymph node hypertrophy (1) Dr Benjamin Castleman has described the first case of Castleman Disease involving single lymph node region which is now called as Unicentric CD (2) later it has been observed that it can affect

multiple lymph node regions which is now known as Multicentric CD. Three characteristic histopathological subtypes of CD are hyalin vascular, plasmablastic and mixed variants (3). Human herpes virus 8 associated MCD occur most commonly among HIV infected individual or otherwise immunocompromised individuals. The etiology and pathogenesis of HHV8 associated MCD has been well understood where idiopathic or HHV8 negative MCD has been poorly understood. Limited data exist regarding the epidemiology and treatment pattern of iMCD, in the United States, particularly among patients receiving care in nonacademic settings (4). In the U.S, the annual incidence and prevalence of iMCD is estimated at 3.4 cases per million and 6.9 cases per million respectively (4). The presentation of idiopathic MCD is quite varied from mild constitutional symptoms to life threatening cytokine storm, organ failure, death. There are four clinical subgroups of idiopathic MCD-(a) POEMS associated MCD - polyneuropathy, organomegaly, endocrinopathy, monoclonal plasma cell disorder, skin changes. It is a paraneoplastic syndrome that co-occurs with MCD. (b) Idiopathic MCD - TAFRO syndrome-thrombocytopenia, anasarca, myelofibrosis, renal dysfunction and organomegaly occur in some patients with MCD. (c) Idiopathic MCD-IPL- some patient with MCD may have thrombocytosis, hypergammaglobulinemia and mixed or plasmacytic histopathological features. (d) Idiopathic MCD - not otherwise specified (iMCD -NOS), these patients may have thrombocytosis, hypergammaglobulinemia, and mixed or plasmacytic histopathological picture (5). iMCD has been treated with wide variety of agents like corticosteroid, rituximab, and combined chemotherapy. Recently monoclonal antibody against IL6 has been approved for treatment of iMCD (6).

CASE PRESENTATION:

Forty-year-old man without any comorbidity presented to our medicine department with 4 months history of intermittent fever & constitutional symptoms, abdominal distension & swelling of both lower limbs for last two months and exertional dyspnea, easy fatigability, palpitation for last one month. He had no history of chronic cough, hemoptysis, joint pain, oral ulcer, skin rash or alopecia. He had no complaint of jaundice or gastrointestinal bleeding. Patient is cultivator by occupation and had no history of high-risk sexual behavior. Physical examination revealed severe pallor, puffiness of the

lower eyelid, bilateral swelling of both lower limbs and generalized lymphadenopathy (cervical, axillary, inguinal, epitrochlear, popliteal) (**Figure 1A**). Those lymph nodes were nontender, enlarged, and firm in consistency. There was dull note on mediastinum percussion.

He had mild hepatosplenomegaly with ascites (**Figure 1B**).

In the **lab test**, he had severe anemia with thrombocytopenia (hemoglobin 4 gm/dl, TLC 5000/**microliter**, platelet count 80,000/**microliter**). All inflammatory markers were high (CRP-37.48 **mg/L**, ESR-**128mm/hour**, Ferritin-1183**mcg/L**, Procalcitonin-5.64 **ng/ml**, LDH-778 **U/L**). Renal function test was normal (**Urea 34mg/dl**, **Creatinine 1.4 mg/dl**). He had hypoalbuminemia with all other liver functions were normal. 24-hour urinary protein collection was 876 mg/day. Serological tests for hepatitis B, hepatitis C, HIV were negative. ANA was 2+ coarse speckled pattern in 1:160 dilution but ANA specific antibodies were negative. DCT was positive (IgG type). **RA Factor was positive but anti CCP was negative.**

CECT thorax and whole abdomen revealed multiple enlarged mediastinal and hilar nodes largest measuring 2.3 × 2.5 cm, multiple enlarged retroperitoneal lymph nodes largest measuring 3.7× 2.7 cm with mild hepatosplenomegaly (**Figure 2A&B**). **Ascitic fluid study low SAAG type which corresponds to non-portal hypertension secondary to proteinuria.**

Whole body PET- CT scan was done which revealed metabolically active lymph node on both sides of diaphragm likely lymphoproliferative disorder (**Figure 3**).

In bone marrow study, reticular fibrosis was there throughout the marrow. Histopathology of **lymph node biopsy** showed there are a few follicles with germinal centers, focal sclerosis of vessels within the germinal centers, in the interfollicular area there is presence of sheets of plasma cells, no Reed-Sternberg cells are identified, compatible with Castleman Disease (**Figure 4 A &B**).

To find out etiological association of MCD, we did qPCR of HHV-8 but it was negative. IL-6 was done which was remarkably high(22.3pg/ml) [normal reference range <7 pg/ml) and strongly favored to MCD.

Due to presence of thrombocytopenia, anasarca, reticular fibrosis on bone marrow biopsy, proteinuria, organomegaly patient has been classified as iMCD-TAFRO variant. Patient was classified as **having** severe disease ECOG performance status 4, features of volume overload, proteinuria, severe anemia, and thrombocytopenia.

Patient was treated with high dose steroid (injection Methylprednisolone 500mg/day for 5 days followed by tablet Prednisolone 2 mg/kg/day) and injection Tocilizumab 8mg/kg 2 weeks apart. After 1 dose of Tocilizumab and 5 days of methylprednisolone patient has improved drastically as evidenced by defervescence, improvement of platelet count, hemoglobin and decreased all inflammatory markers.

At present, patient has been taken treatment under our care, we are planning to give Tocilizumab 400mg 2 weeks apart and continuation of high dose oral Prednisolone with gradual tapering of 5 to 10mg at 2 weeks interval according to the clinical and hematological response .

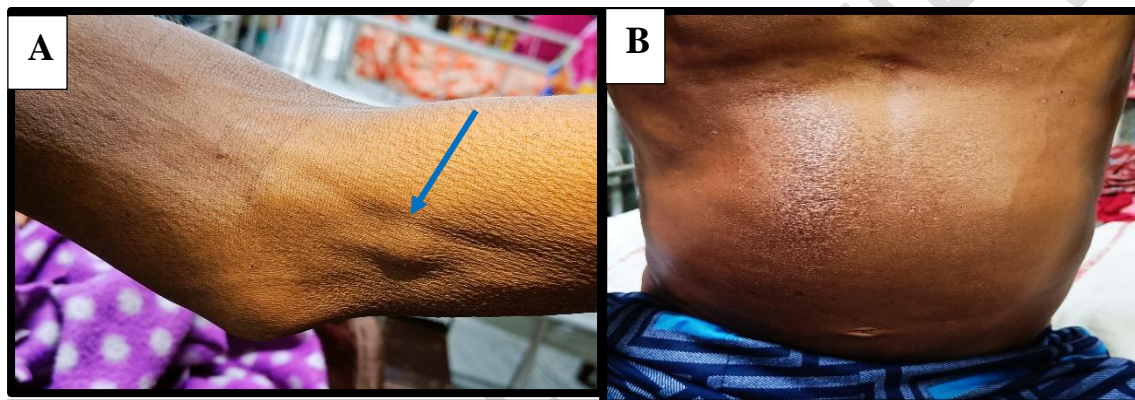


Figure 1: A) Shows enlarged epitrochlear lymph node (blue arrow). B) Shows ascites with venous prominence of anterior abdominal wall

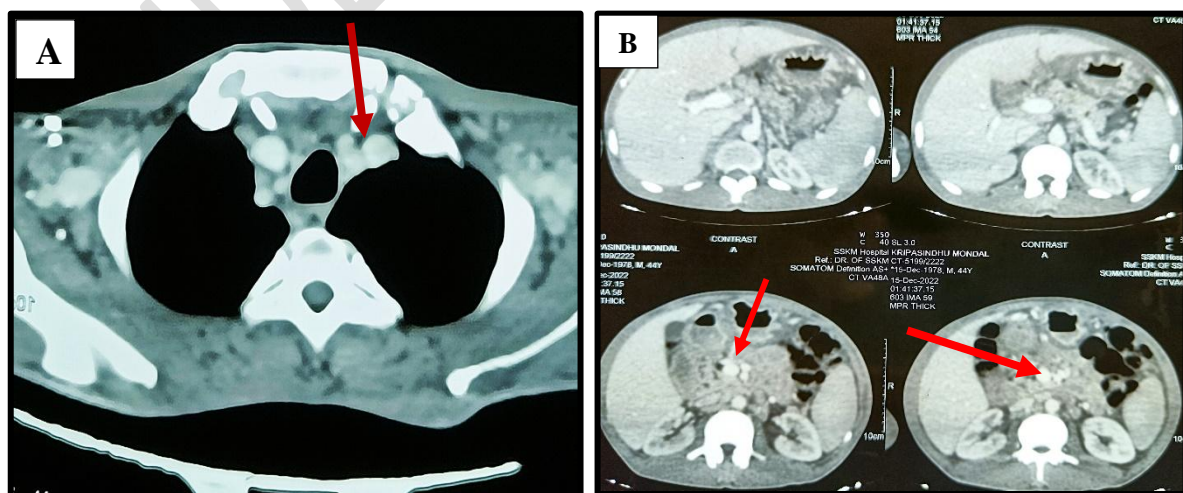


Figure 2 (CECT Thorax and Abdomen): A) Shows multiple enlarged lymph node (red arrow) B) Shows multiple mesenteric and retroperitoneal lymph nodes (red arrow).

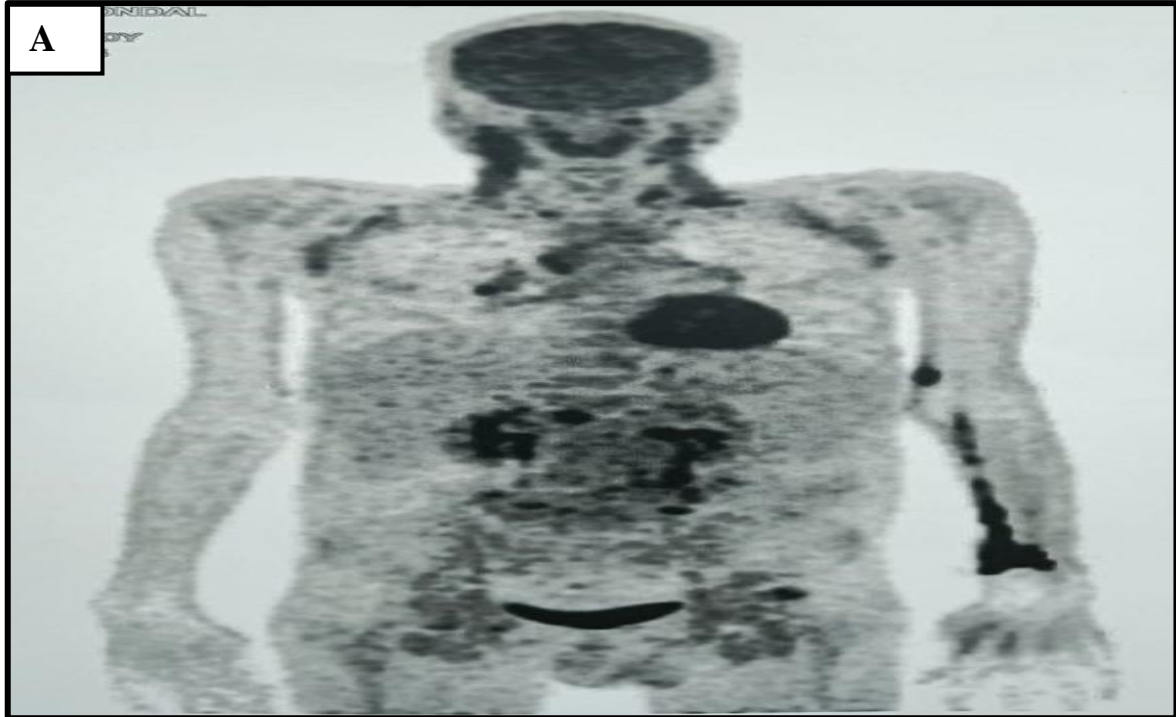


Figure 3 (^{18}F FDG PET Scan): Shows metabolically active lymph nodes on both sides of diaphragm.

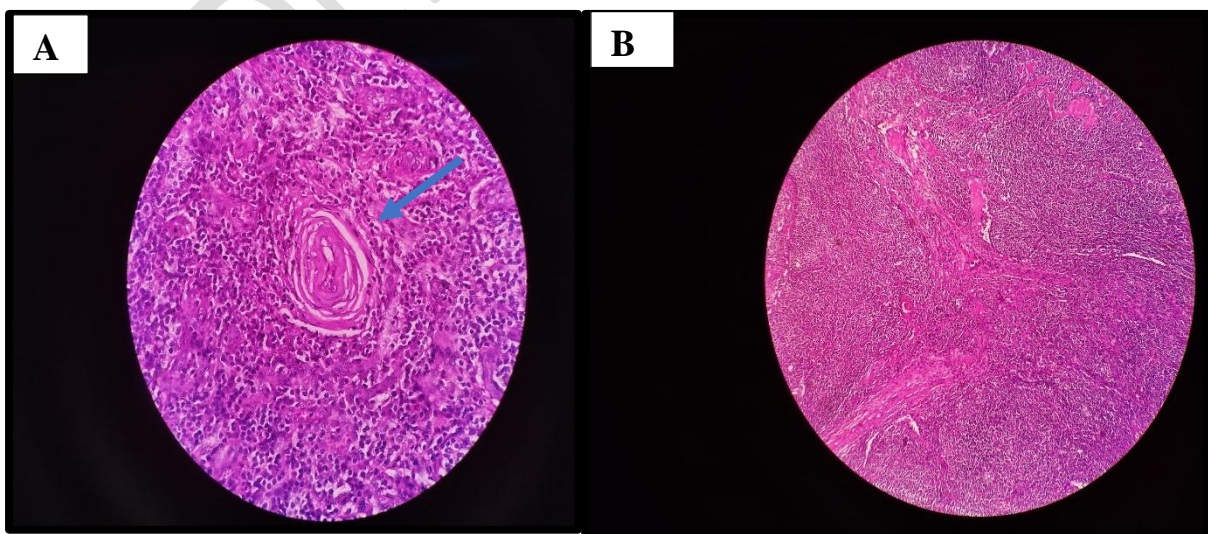


Figure 4 (HPE Lymph node): A) Shows sclerosis of vessel within germinal center (blue arrow) B) Sheets of plasma cells in the interfollicular area, features compatible with Multicentric Castleman Disease (x400 H&E).

PARAMETERS	1 week after treatment	3 rd week	6th week
Hemoglobin	6.7 gm/dl	8.1 gm/dl	10.8 gm/dl
Platelet count	87,000/microliter	95,000/microliter	1.09 Lac/microliter
ESR	116 mm/hour	93mm/hour	68 mm/hour
CRP	31.5 mg/L	21.9 mg/L	18 mg/L
Ferritin	1098 mcg/L	787 mcg/L	432 mcg/L
LDH	668 U/L	413 U/L	245 U/L
Albumin	2.9 gm/dl	3.2 gm/dl	3.9 gm/dl
IL6	22.3 pg/ml	17.5 pg/ml	12.9 pg/ml

DISCUSSION:

In the view of chronic fever with generalized lymphadenopathy, hepatosplenomegaly, ascites, severe anemia, thrombocytopenia, high LDH, with proteinuria and hypoalbuminemia we thought the possibilities of chronic lymphoproliferative disorders, systemic chronic infections like tuberculosis, chronic malaria, chronic kala-azar, autoimmune diseases like SLE, RA, sarcoidosis, and systemic mycosis. To rule out, the possibilities of CLPD, disseminated tuberculosis, sarcoidosis, systemic mycosis histopathological examination of supraclavicular lymph node and tissue CBNAAT were done. We also ruled out disseminated histoplasmosis by doing urinary histoplasma antigen and fungal culture. Tissue CBNAAT was nonconclusive. Autoimmune diseases have been ruled out with ANA, ANA profile, C3, C4, dsDNA, anti CCP. For chronic kala-azar, bone aspiration was done to look for LD Body.

Castleman disease is an exceedingly rare lymphoproliferative disorder that closely mimics common diseases like chronic infectious diseases, autoimmune disorders, and chronic lymphoproliferative disorders. That is why it creates diagnostic dilemma among physicians. As most of the time it presents as asymptomatic, unifocal, soft tissue mass without any systemic sign and symptoms, the diagnosis is often missed.

The etiology of iMCD is unknown, although it is hypothesized to involve one or more of the following mechanisms; autoimmunity/autoinflammatory, paraneoplastic or infections with a virus other than HHV8. 6500 to 7700 new

cases are diagnosed per year in the United States, with 1650 cases of MCD. Idiopathic MCD accounts for 33% to 58% of published MCD cases (5).

Fine needle aspiration cytology is non diagnostic as aspiration of lymphoid tissue leads to false interpretation of lymphoma. However, both unicentric and multicentric CD have been associated with lymphoma. As a result, definitive diagnosis is made by excisional biopsy and histopathological examination. The histopathological picture of hyalin vascular type CD is onion skin pattern of concentric expansion of mantle zone around burned-out germinal center (6). In plasma cell type of CD, there is extensive proliferation of plasma cell around the intact follicle (7).

CD is the polyclonal proliferation of the lymphoid tissue, when monoclonal proliferation occur it turns into malignant lymphoma (8).

There are some peculiarities among the laboratory finding of CD, it has been shown that 9 to 71% cases of CD may have positive direct Coombs test and 12 to 37% cases may have positive anti-nuclear antibody (9). In our case the patient is positive for both ANA and DCT.

Most of the patient with UCD can be treated with surgical resection. Where patients with MCD need systemic therapy. Those with systemic manifestation are difficult to treat. These patients are treated with high dose systemic glucocorticoid, combination chemotherapy and anti IL6 monoclonal antibody (10).

CONCLUSION:

Though the Castleman disease is exceedingly rare disorder it should always be kept in mind as it closely mimics common systemic illness. The early diagnosis and prompt treatment may give rise to satisfactory response & prevent progression to malignant diseases.

ETHICAL APPROVAL:

As per international standard or university standard written ethical approval has been collected and preserved by the author(s).

CONSENT:

Written informed consent was obtained from the patient for publication of this case report and accompanying images.

REFERENCE

1. Iyer S, Bhatti MI, Halliday M. Castleman's disease-A case report. *Int J Surg Case Rep.* 2010;1(3):25-6. doi: 10.1016/j.ijscr.2010.06.005. Epub 2010 Oct 15. PMID: 22096669; PMCID: PMC3199674.
2. El-Osta HE, Kurzrock R. Castleman's disease: from basic mechanisms to molecular therapeutics. *Oncologist.* 2011;16(4):497-511. doi: 10.1634/theoncologist.2010-0212. Epub 2011 Mar 25. PMID: 21441298; PMCID: PMC3228122.
3. Wojtyś M, Piekarska A, Kunc M, Ptaszyński K, Biernat W, Zaucha JM, Waloszczyk P, Lisowski P, Kubisa B, Grodzki T. Clinicopathological comparison and therapeutic approach to Castleman disease-a case-based review. *J Thorac Dis.* 2019 Nov;11(11):4859-4874. doi: 10.21037/jtd.2019.10.73. PMID: 31903277; PMCID: PMC6940266.
4. Simpson D. Epidemiology of Castleman Disease. *Hematol Oncol Clin North Am.* 2018 Feb;32(1):1-10. doi: 10.1016/j.hoc.2017.09.001. PMID: 29157611.
5. Mukherjee S, Martin R, Sande B, Paige JS, Fajgenbaum DC. Epidemiology and treatment patterns of idiopathic multicentric Castleman disease in the era of IL-6-directed therapy. *Blood Adv.* 2022 Jan 25;6(2):359-367. doi: 10.1182/bloodadvances.2021004441. PMID: 34535010; PMCID: PMC8791564.
6. Kojima, Masaru et al. "Idiopathic multicentric Castleman's disease. A clinicopathologic and immunohistochemical study of five cases." *Pathology, research, and practice* vol. 201,4 (2005): 325-32. doi: 10.1016/j.prp.2005.01.006
7. Tomohiro Koga, Remi Sumiyoshi, Atsushi Kawakami, Kazuyuki Yoshizaki, A benefit and the prospects of IL-6 inhibitors in idiopathic multicentric Castleman's disease, *Modern Rheumatology*, Volume 29, Issue 2, 4 March 2019, Pages 302–305, <https://doi.org/10.1080/14397595.2018.1532383>
8. Venkateswaran J, Balakrishna J. Castleman disease PathologyOutlines.com website <https://www.pathologyoutlines.com/topic/lymphnodescastleman.html>. Accessed March 30th, 2023.
9. Wang L, Chen H, Shi J, Tang H, Li H, Zheng W, Zhang F. Castleman disease mimicking systemic lupus erythematosus: A case report.

Medicine (Baltimore). 2018 Sep;97(38):e12291. doi:
10.1097/MD.00000000000012291. PMID: 30235674; PMCID:
PMC6160051.

10. van Rhee F, Voorhees P, Dispenzieri A, Fosså A, Srkalovic G, Ide M, Munshi N, Schey S, Streetly M, Pierson SK, Partridge HL, Mukherjee S, Shilling D, Stone K, Greenway A, Ruth J, Lechowicz MJ, Chandrakasan S, Jayanthan R, Jaffe ES, Leitch H, Pemmaraju N, Chadburn A, Lim MS, Elenitoba-Johnson KS, Krymskaya V, Goodman A, Hoffmann C, Zinzani PL, Ferrero S, Terriou L, Sato Y, Simpson D, Wong R, Rossi JF, Nasta S, Yoshizaki K, Kurzrock R, Uldrick TS, Casper C, Oksenhendler E, Fajgenbaum DC. International, evidence-based consensus treatment guidelines for idiopathic multicentric Castleman disease. *Blood*. 2018 Nov 15;132(20):2115-2124. doi: 10.1182/blood-2018-07-862334. Epub 2018 Sep 4. PMID: 30181172; PMCID: PMC6238190.

UNDER PEER REVIEW