

Original Research Article

Correlation of Shapes of The Orbit with Various Age Groups by Using Plain Skull Radiographs: A 5-Year Retrospective Cross-Sectional Study in Northwestern Nigeria

ABSTRACT

Introduction: Anthropometric measurements have been carried out in many studies to segregate people into races, ethnicity and various biological traits in the past. Such studies include cephalometry being deployed because of its significance in forensic and clinical evaluations of individuals. The objectives of our study were to determine the correlation between the shape types of the orbit with different age groups and their prevalence using simple Plain skull X-rays.

Materials and Methods: Plain X-rays of the skull with posteroanterior exposures were obtained for a retrospective period of 5-year period. The selected radiographs were those with clear and distinct recognition of the orbital margins assessed by 2 or more experienced Radiologist who determined the shapes of the orbits as being oval, round, or quadrangular. Out of total of five hundred (500) plain X-rays of the skull obtained, only 255 satisfied the inclusion criteria.

The data was analyzed statistically using INSTAT software to compare the mean values in relation to age distribution of the subjects with the Student's T-Test. Chi-Square (with Yates correction) was used for the comparison of proportions.

Results: In the first three decades, the oval shape is more predominant with values of 22(64.7%), 17(36.2%), and 27(38.6%) respectively. In the fourth to sixth decades, the round type has values of 23(42.6%), 16(50%), and 8(61.5%) respectively. In the last decade (61-70) years, the oval and round have equal prevalence.

Conclusions: In addition to the known oval and quadrangular (triangular) types of orbital shape, our study revealed a 3rd type of orbit which we described as round-shaped. The oval type of orbit is found to be more common in the first three decades of life but from the 4th to 6th decade the round type predominates.

Keywords: *Orbit, Shapes, Plain X-rays, Skull*

INTRODUCTION

Anthropometric measurements are taken on a variety of people for a variety of reasons such as monitoring athletes, tracking growth, development, and motor performance in children, which links physical activity and nutrition interventions to changes in body size, shape and composition.¹ Many studies were done to reliably differentiate between races criminal temperament and intelligence amongst other traits especially for Caucasians and Negroes². Many anthropologists believe by doing some morphometric analyses, they can accurately classify people to their race and continents of origin³. The orbit forms a craniofacial cavity which contains the visual apparatus and other soft tissues⁴. Its margin has been often been described as quadrilateral with rounded corners⁵. The relationship between the orbital height and width is given by the *orbital index*, which varies in the different races of mankind⁶. Taking the orbital index into context, the Megaseme (large-sized) orbit typical of Mongolians (yellow races) usually has round-shaped orbital openings, while the Mesoseme (medium-sized) is seen mostly in the Caucasians (white races), and the Microseme (small-sized) found mostly in the Negroes (black races) usually has quadrangular/rectangular-shaped type of orbital openings⁷. The orbital margin is basically made up of three bones: the frontal, zygomatic, and maxilla⁸.

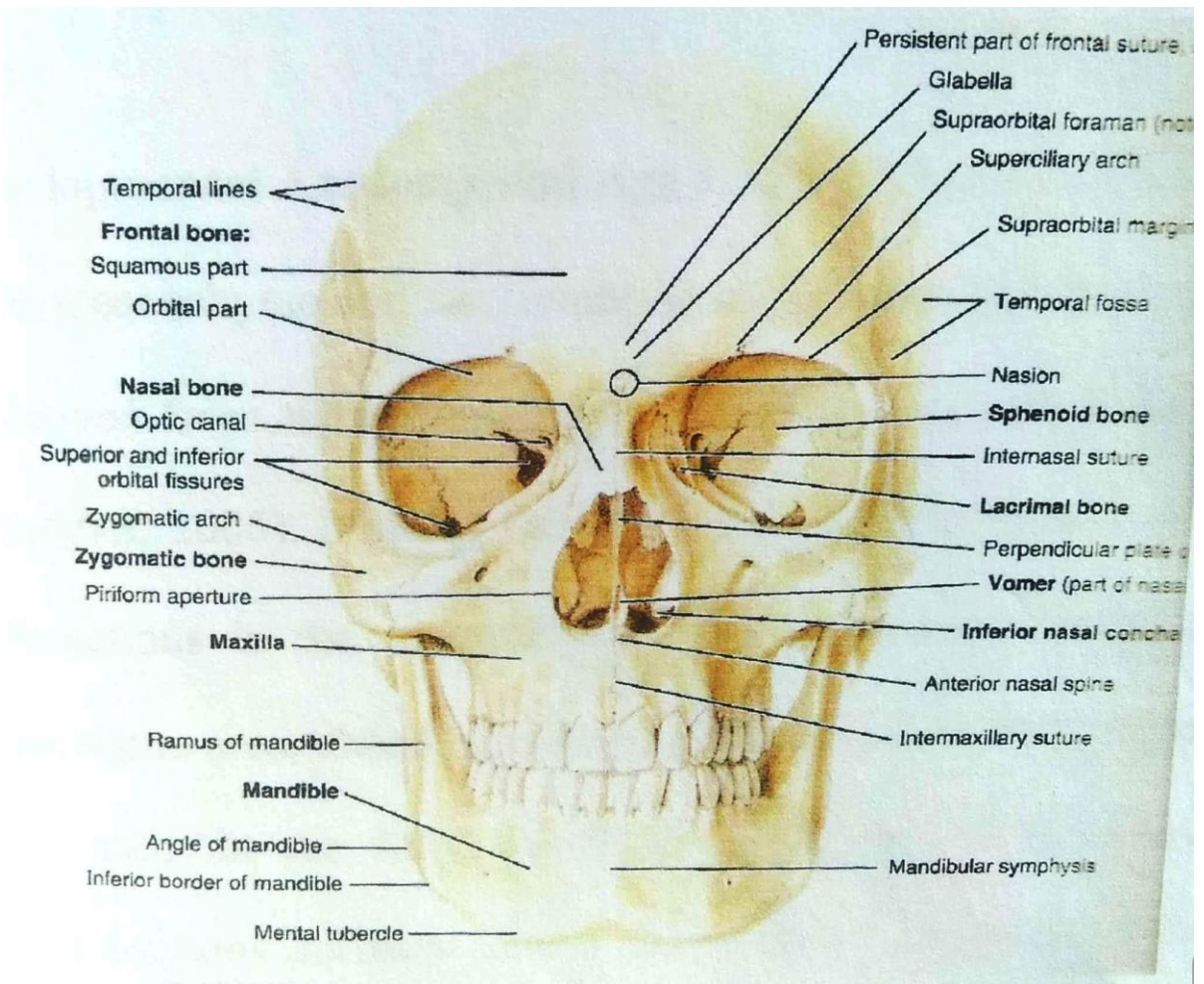


Figure 1: Anterior View of the Skull (*Norma frontalis*) showing the orbit and its parts
 (Adopted from Keith L. Moore Text Book of Clinically Oriented Anatomy)⁸

UNDER

The mesenchyme for the formation of the orbit is derived from neural crest⁹. The condensation of this mesenchymal connective tissue area is surrounded by periosteum and muscular fragments¹⁰.

In the prenatal stage, the orbit undergoes the mutual rotation around its both axes which results in the frontalization of the eyes from approximately 180 degrees in the early prenatal stages to approximately 50 degrees in adulthood¹¹.

The changes in the orbit during the period of growth depend partly on the development of the cranium and skeleton of the face between which the orbit is placed and also on the growth of the neighboring air sinuses. At birth, the orbital margin is sharp and well ossified. This serves as protection to eyeball from injury during child birth. At this stage, the infantile orbit looks more laterally than the adult¹⁰.

The orbital fissures are relatively large in the child due to the narrowness of the orbital surface of the greater wing of the sphenoid and the wide and narrow portions are not well differentiated¹⁰. The interorbital distance is small which is why children are often brought to ophthalmic surgeon because they are thought to have squint because narrowness makes the eyes to look much closer but with further development the interorbital distances increase and so causes the squint to disappear. In old age, the changes being noticed are mostly due to absorption of the bony walls¹².

The study will be useful for clinicians in knowing the expected orbital shape in concordance with the age group while assessing the orbit and also to forensic experts in classifying cases. how to diagnose and tackle subtle orbital bony injuries, subtle lesions of retro-orbital space and the orbital muscles, and reconstructive surgeries¹³. Deviation from the normal orbit shape in the developing human will enhance the diagnosis of orbital tumors or injuries to the area¹⁴. **Hence, the value of orbital morphometry in determining orbital lesions severity or postoperative complications of orbital surgeries cannot be over emphasized¹⁵.**

The bulk of past studies were on Caucasian⁴, Asian subjects^{8,13}, and a few Africans¹. Most of the studies were by either invasive procedures of mensuration or cadaveric and bony specimens^{1,6}. Our present study, determined the different shapes of the orbits using plain X-rays done on Nigerian subjects to establish **a baseline data on the different shape of the orbit, and their prevalence for the population under the study.**

MATERIALS AND METHODS

Plain X-rays of the skull with posteroanterior exposures were obtained for a retrospective period of 5 years from the Radiology Unit of the Usmanu Danfodiyo University Sokoto which is a metropolitan city in the Northwestern part of Nigeria. The X-rays collected were from 2004 to 2009. The inclusion criteria of the radiographs were based on clearness of the images with distinct recognition of the orbital margins also only those that were interpreted by 2 or more experienced Radiologist who determined the shapes as oval, round, or quadrangular. Out of total of five hundred (500) plain X-rays of the skull obtained, only 255 satisfied the inclusion criteria.

Statistical Methods

The data was recorded in Microsoft word and excel format before being imported into INSTAT Statistical for the data analysis. Comparisons of mean values in relation to age distribution of the subjects were done using the Student's T-Test. Chi-Square (with Yates correction) was used for the comparison of proportions. Proportional percentages of the different orbital shapes obtained were observed.

Ethical consideration

Ethical clearance for the study was obtained from the Ethical Committee of the Radiology Department of Usmanu Danfodiyo University Teaching Hospital Sokoto, Nigeria, with the ethical clearance number **UDUTH/HREC/2010/NO.827.**

RESULTS

The results of two hundred and fifty-five samples were analyzed that met the inclusion criteria and the following results were obtained as depicted in the table form below.

Table 1 :Various anatomical shapes of the orbit in relation to age groups

Group	Oval	Quadrangular	Round	Total
1-10	22(64.7%)	5(14.7%)	7(20.6%)	34
11-20	17(36.2%)	16(34.0%)	22(31.4%)	47
21-30	27(36.6%)	21(30.0%)	23(42.6%)	70
31-40	16(29.6%)	15(27.8%)	16(50%)	54
41-50	10(31.3%)	6(31.3%)	8(61.5%)	32
51-60	2(15.4%)	3(23.1%)	8(1.5%)	13
61-70	2(40%)	1(20%)	2(40%)	5
Total	96	67	92	255

X = 19.6; df = 18; p<0.05. No statistical significance.

A table showing the various anatomical shapes of the orbit in relation to age groups.

The above table shows the disposition of different orbital shape types in relation to the different age groups stratified into decades according to the age of the subjects i.e., 1-10, 11-20, etc. and we set the age limit of 70 years of life. Within the first three (3) decades of postnatal life, the oval orbital shape type was found to be more predominant with values of 22(64.7%) in the first decade, 17(36.2%) in the second decade, and 27(38.6%) in the third decade of life. By the fourth to sixth decades of post-natal life, the round type was found to be more common than the other shape types with values of 23(42.6%) in the fourth decade, 16(50%) in the fifth decade, and 8(61.5%) in the sixth decade of life. At the sixth decade, which comprises the age range of (61-70) years, the oval and round shaped-types of orbits were found to have equal prevalence as

indicated in the table above. However, in all the differences found, they were of no statistical significance.

DISCUSSION

The types of orbital shapes have been previously described in many studies based on the posteroanterior radiographic view of the skull which are oval and quadrangular (rectangular). But our study revealed another third type which fits our description of The Round-type of orbit. In relation to age group, the oval type predominates in the first three decades of life but from the 4th to 6th decades the round type was found to predominate while in the last decade of the study the oval and round types had equal proportions. The quadrangular type as seen in the study has the least representation/frequency of all the types in all age groups under study. **These findings are like what was obtained by other scholars when they performed similar studies on dry human skulls¹⁴.** However, the differences observed were not proven to be significant statistically.

Conclusion

Our study found out that the most common type of shape of the orbit amongst the samples under study within the first three decades of life is the oval type of orbit. However, from the 4th to 6th decade, our study revealed the round-shaped type of the orbit to be the most common. As part of our study limitations, using the plain X-rays could not determine the volume of the orbit as the view is in 2D format. Incomplete biodata from the hospital records did not permit other comparisons to be made as the records were obtained retrospectively. Therefore, other confounders like the BMI, Vital signs records and also ethnicity, nutritional status and full demographic domain of the study subjects could not be ascertained. It is our recommendation that future studies be done in a prospective cohort with newer innovations that allows for volumetric assessment on 3D format such is 3D/4D doppler ultrasounds, CT scans or MRI to give better views for a more accurate analysis.

REFERENCES

1. Umar, M.B.T. Singh, S.P., Shugaba, A.I. (2005): Orbital Measurements among the Ethnic Groups of Plateau State, Nigeria, Highland Medical Research Ltd. July-December; Bol. 3. 2: 26-28.
2. Westcott, D.K and Jantz, R.L (1999) Anthropometric Variation Between the Sixious and Assiniboine. Human Biology (United States), 71(5): 877-888.

3. Wade N.: 2002. A New Look at Old Data May Discredit a Theory on Race. New York Times. 8 October.
4. Khan Z., Nadeem G., Khan H., Billah A. K., (2021): An anatomical study of orbital dimensions and Its Utility in Orbital Reconstructive Surgery. Journal of Oncology and Radiotherapy; Vol.15 Iss.3:001-9.
5. Susan, S. Harold E *et al.*, (2005). Gray's Anatomy. The Anatomical Basis of Clinical Practice. Elsevier Churchill Livingstone. 39th Edition. 27: 487-489; 28:493-495; 48:688-690.
6. Zurifa A,Uzeir A,Lejla D,Haris H,Alma V,(2023) A Geometric Morphometrics Approach for Sex Estimation Based on the Orbital Region of Human Skulls from Bosnian Population. Hindawi Scanning Volume 2023, Article ID 2223138, 9 pages <https://doi.org/10.1155/2023/2223138>.
7. Karakas, P., Bozkir, M. and Oguz, O Morphometric Measurements from Various Reference Points in the Orbit of Male Caucasians. Surgical and Radiologic Anatomy, 2002, Vol. 24, No.6 P 358-362.
8. Moore, Keith L., Arthur F. Dalley, and Anne Agur. (2014). *Clinically Oriented Anatomy*. 7th ed. Philadelphia, PA: Lippincott Williams and Wilkins.
9. Sandler, T.W. Langman's medical embryology, 14th ed. Philadelphia: Wolters Kluwer, 2019.
10. Moore Keith L and T. V. N Persaud. 2016. *The Developing Human: Clinically Oriented Embryology [10th Ed.]*. 10th ed. Elsevier.
11. Taylor, W.O.G: The Effect of Enucleation of One Eye in Childhood Upon the Subsequent Development of the Face. Transaction of the Ophthalmological Societies of UK, **59** (Part 1), 361. 1939.
12. Kier, E.L (1966) Embryology of the Normal Optic Canal and its Anomalies Investigative Radiology, 1:346-362.
13. Williams, P.L; Bannister, L.H; Berry M.M; Collins, P.; Dyson, P; Dussek, J.E. Ferguson, M.W.J: Gray's Anatomy in: Skeletal System Edited by Soames, R.W. Churchill Livingstone, Edinburgh, London. 555-560. 1999.
14. Lloyd M.A., Glynn A.S (1973) Radiology of the Orbit, W.B. Saunders, and Company Ltd London. 1st Edition 1-29.

15. Khwaja MJ, Shaikh SH, Hiware SD, et al. Morphometric Assessment of Orbit in the Human Skull. *J Evolution Med Dent Sci* 2020;9(48):3623-3627, DOI: 10.14260/jemds/2020/796.

UNDER PEER REVIEW