

Short Research Article

Peripapillar radial nerve fiber layer (RNFL) and choroidal macular thickness (CMT): valid biomarkers of disability progression during one year in patients with multiple sclerosis (MS)

ABSTRACT

Aims: Multiple Sclerosis (MS) is an autoimmune disease that shows a great variability in its clinical aspects. We did this study to investigate whether vascular changes (choroidal thickness and macular vascular plexuses) as well as changes in the thickness of retinal nerve fiber layers and retinal ganglion cells occur over one year in patients with MS and if these changes are related with the disability that the patients have.

Study design: Prospective observational study

Place and Duration of Study: Department of Ophthalmology and Neurology (in Hospital Clínico Universitario de Valencia (Spain). Between January 2016 and September 2017.

Methodology: We analysed 104 eyes of MS patients (divided in groups depending of the type of the MS and their grade of disability measured by the Expanded Disability Status Scale (EDSS) by Kurtzke). Anatomical parameters: RNFL and ganglion cell layer (GCL) were studied using optical coherence tomography (OCT). Vascular parameters were analysed: CMT by OCT and the macular vascular plexuses by OCT-angiography (OCTA). Any subject has an optical neuritis history.

Results: RNFL was thinner in the highest degree of disability group and in patients with primary progressive MS (PPMS). CMT showed a significant decreased in the group that has moderate-severe disability and showed a decrease in the group that their disability worsened during the year of study. Retinal macular plexus showed no difference in any group at one year of study. **Conclusion:** The study of the RNFL and CMT are objective and valuable indicators in these patients, especially with regard to the progression of their disability and with the worst forms of the disease.

Keywords: [Multiple sclerosis, OCT, AngioOCT, RNFL, EDSS, not required you mention their definitions below disability, macular choroidal thickness, retinal vascularization} (you should add valid biomarkers
r

3. *Research Papers and Short Notes* should follow the structure of Abstract, Introduction, Methodology, Results and Discussion, Conclusion, Acknowledgements, Competing Interests, Authors' Contributions, Consent (where applicable), Ethical approval (where applicable), and References plus figures and/or tables.)

1. INTRODUCTION

Multiple sclerosis (MS) is considered to be an disease with two clearly defined aspects¹: an autoimmune inflammatory disease characterises its initial years and is manifested by outbreaks and shows up in MRI as demyelinating lesions that affect both white and grey matter. The other is a degenerative aspect related to the production of irreversible damage to axons and neurons, which occurs from the early stages but becomes relevant later on as a substrate for the late progressive phase.

Multiple sclerosis presents with great clinical variability and its progression is inconstant. Vascular alterations could play an important role in the course and presentation of the disease. One of the aspects that is not currently clear is whether or not vascular impairment can condition the type of MS, its symptoms and its course.

Multiple sclerosis, like the rest of neurodegenerative diseases, eventually leads to clinical disability that is evaluated, in practice, by using quantification methods such as the Expanded Disability Status Scale (EDSS). It is essential to have objective biomarkers of central nervous system (CNS) pathological changes that precede the progression of disability. In detecting these changes, nuclear magnetic resonance (NMR) constitutes the gold standard test, but since demyelinating lesions do not cover the entire pathology of MS, techniques are being developed to detect and monitor the loss of brain volume. (References ??)

Since the retina is a window to the CNS, studies which studies?? finding decreased cerebral perfusion in MS could be supported by optical coherence tomography angiography (OCTA) findings in these patients, and it could constitute an additional biomarker to that provided by optical coherence tomography (OCT).

The aim of this study is to elucidate whether retinal microvascular and choroidal thickness changes correlate with the degree of disability and progression of the disease and, if so, whether studying them rewrite this sentences can provide additional information to that of the thickness of the inner retinal layers.

2. MATERIAL AND METHODS / EXPERIMENTAL DETAILS / METHODOLOGY

We studied 104 eyes of MS patients. Subjects were divided into two groups depending of the type of the MS: primary progressive MS (PPMS) and relapsing-remitting MS (RRMS). Any subject has optic neuritis history. We also divided the two groups depending on their disability: patients with low disability (EDSS score ≤ 3) and high disability (>3) measured by the Expanded Disability Status Scale (EDSS) by Kurtzke. We analysed whether there were statically differences between baseline and one year data of the two main groups and of the subgroups that had been initially established according to their degree of disability and type of MS. We analysed anatomical parameters (RNFL, and GCL with Triton OCT, Topcon) and CMT (with the same OCT) and macular vascular plexuses (with the OCTA of the same platform). Moreover, a new classification of patients was established according to the progression of their disability and whether there was a significant one-year variation in the different parameters investigated according to whether or not the EDSS score of their disability had worsened during the study year. which methods of statistical analysis you used?????

3. RESULTS AND DISCUSSION

During the year of study, anatomical parameters showed a statically decreased in patients with the highest degree of disability and in patients with PPMS. CMT showed significant decrease in the group that had moderate-severe disability. Retinal vascular macular plexuses showed no difference according to the EDSS or type of MS. Fig. 1 and table 1.

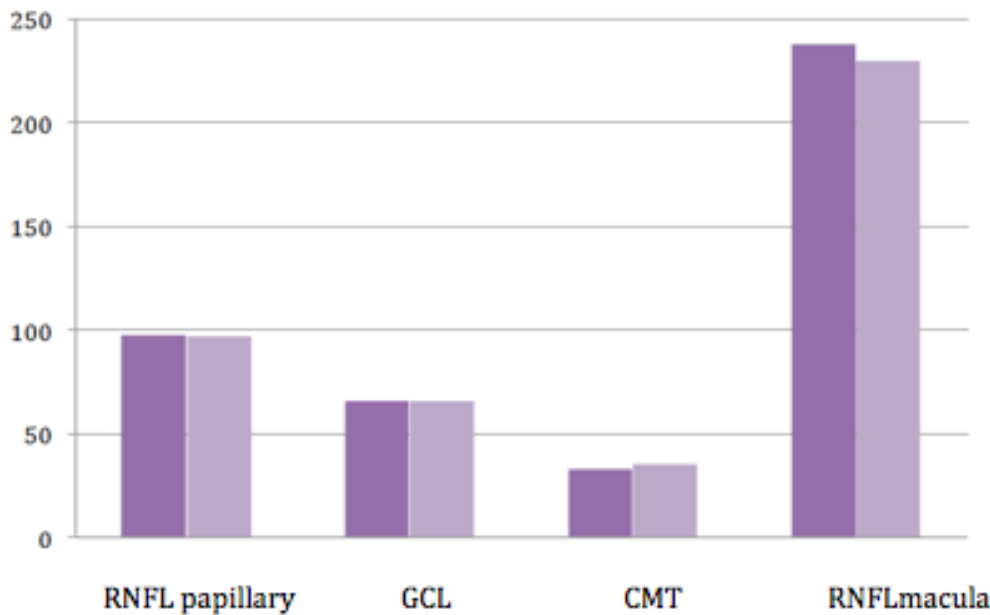


Figure 1. The anatomical parameters studied by OCT in patients with the highest degree of disability (EDSS >3) are shown: the first column shows the results at the beginning of the study and in the second column are the results of the one -year study.

	P value t-student
RNFL optic nerve (RFNL NO)	0,031
GCL	0,157
CML	0,013
RNFL macula	0,392

Table 1. Results of the p-value between the values at the baseline study and the values at one-year study in patients with PPMS. RNFL of the optic nerve and MCT showed statically decrease in one-year study.

Moreover, a new classification of patients was established according to the progression of their disability and whether there was a significant one-year variation in the different parameters investigated according to whether or not the EDSS score of their disability had worsened during the study year. As we see in Table 2, the CMT showed a statically decrease during the year of the study in the patients that increased their disability.

Paired samples	P- value t-student

RNFL optic nerve basal-annual	0,161
GCL basal-annual	0,144
CMT basal-annual	0,038
RNFL macula basal-annual	0,504
Superficial vascular macular plexus basal-annual	0,078
Deep vascular macular plexuses basal-annual	0,704
Choriochapillaris plexus basal-annual	0,608

Table 2. In the group with a worsening according to the disability, the choroidal macular thickness, CMT, showed a significant decrease during the one-year study.

It has been established that inflammation and neurodegeneration are involved in the pathogenesis of MS. It is mainly these two components that determine the degree of disability and the clinical presentation of the patient. The dysfunction observed in the vessels of MS patients has led to the hypothesis that this pathology also has a partially vascular basis². Thus, several studies have demonstrated cerebral hypoperfusion³ and suggest that, although MS is due to an impairment of the immune system, there may be a vascular component⁴⁻⁹ that determines the progression of the disease, as many disease-modifying treatments that profoundly suppress the immune system, including autologous transplantation of haematopoietic derivatives^{10,11}, do not prevent the progression of neurodegeneration¹⁰⁻¹². Furthermore, increased cardiovascular events have been reported in these patients, the mechanism of which are unknown but may be explained by endothelial dysfunction secondary to inflammation; CNS venous drainage dysfunction has also been observed¹³.

When **we** analysed the behaviour of the anatomical parameters depending on the type of MS, **we** found that, over the year of the study, the thickness of the papillary RNFL underwent significant thinning in patients classified as primary progressive multiple sclerosis (PPMS) subjects, while this was not observed in those in the relapsing-remitting multiple sclerosis (RRMS) subgroup. This suggests that monitoring the thickness of this layer could help to identify a difference in behaviour between two MS subtypes with a different prognosis, as PPMS is more aggressive. We believe this to be an interesting indicator as it could support the definition of progressive forms and, perhaps, anticipate their detection in order to provide early disease-modifying treatments, which would ultimately be useful to improve their prognosis.

Similarly, the one-year analysis of the disability subgroups points to a possible difference in papillary RNFL thinning dependent on the initial EDSS score, as we found that patients with initially moderate-severe disability showed a statistically significant decrease in the thickness of the papillary RNFL; this change is not evident in patients with initially mild disability. However, when patients were distributed according to whether or not their EDSS score worsened over the study year, there was no significant change in the thickness of the inner retinal layers, including papillary RNFL, in either subgroup.

Therefore, during the study year, papillary RNFL showed a significant thinning in the MS group and, more specifically, in the subgroups including patients with a more severe form or more advanced stage of the disease.

Since the choroid is a richly-vascularised anatomical structure, it has been dealt with in our research work as another vascular parameter. The importance of studying this layer together with the plexuses arises from the fact that currently the images and information obtainable with Swept-Source OCT (SS-OCT) are of high quality¹³¹ you didn't have this in the references list and make it possible to carry out a very detailed analysis of it. However, for the study of retinal plexuses we are using a more recent technique, OCTA, which at present has limitations, especially in terms of image acquisition.

CMT also showed a different behaviour between the subgroups according to the EDSS, as it showed a significant decrease in the subgroup of patients who, at the beginning of the study, had moderate-severe disability and conversely, in the subgroup which was initially classified as mild disability, no differences were found at one year. On the other hand, we found that, over the year of the study, in the subgroup of patients in which the EDSS score did not worsen, we did not detect significant changes in choroidal thickness; nevertheless, the subgroup of patients in which the EDSS assessment worsened did show a statistically significant thinning of the choroid.

Different scales are available to measure the degree of disability of a patient, the most widely used being the EDSS. These tools are based on the clinical assessment of the patient, which in itself is subject to inter-observer variability and inaccurate quantification (add references) The results obtained in our study suggest that, in the case of choroidal thickness, we may have a useful marker to complement clinical scales in the assessment and monitoring of disability, as it is a quantifiable and reproducible indicator.

In the study of retinal vascular plexuses, we focused only on the macular area, partly due to certain technical limitations of OCTA. We found no significant differences between any of the subgroups according to the type of MS or EDSS in any moment of the study.

It is worth considering whether vascular parameters can provide additional information to that already provided by the thickness of the inner retinal layers. In this respect, choroidal thickness seems to be a particularly interesting measurement. Both the CMT and peripapillary RNFL show, at the one-year follow-up, a statistically significant decrease but both parameters seem to provide complementary information. In the peripapillary RNFL, the one-year thinning was observed in the subgroups with generally higher severity at baseline (PPMS and moderate-severe EDSS). In the case of the CMT, thinning after a year was equally significant for all forms of MS regardless of severity; however, it discriminated between patients with initially low disability and those with moderate-severe disability, with a significant one-year decrease in CMT detected only in the latter. Moreover, it is the only parameter that has shown a significant decrease at one year in those patients whose EDSS score worsened during the study. Thus, in our longitudinal study, variations in choroidal thickness seem to closely reflect the progression of disability in the MS group. you need to add more references

Did you have any limitation in this study ??

4. CONCLUSION

BASED ON **OUR THIS STUDY** RESULTS, MACULAR CHOROIDAL THICKNESS MEASURED BY OCT COULD BE A PARTICULARLY VALUABLE INDICATOR FOR MONITORING THESE PATIENTS, ESPECIALLY WITH REGARD TO THE PROGRESSION OF THEIR DISABILITY. FURTHER RESEARCH IS NEEDED TO ASSESS THE FULL CLINICAL POTENTIAL OF MONITORING MACULAR VASCULAR PLEXUS DENSITY BY OCTA AND TO BETTER UNDERSTAND THE AETIOPATHOGENESIS OF VASCULAR CHANGES IN MS.

ETHICAL APPROVAL (WHEREEVER APPLICABLE)

"All authors hereby declare that all experiments have been examined and approved by the appropriate ethics committee and have therefore been performed in accordance with the ethical standards laid down in the 1964 Declaration of Helsinki."

DEFINITIONS, ACRONYMS, ABBREVIATIONS

RNFL: RADIAL NERVE FIBER LAYER

CMT: CHOROIDAL MACULAR THICKNESS

EDSS: EXPANDED DISABILITY STATUS SCALE

OCT: OPTICAL COHERENCE TOMOGRAPHY

OCTA: OCT- ANGIOGRAPHY-

GCL: GANGLION CELL LAYER

REFERENCES

1. Navarré Gimeno A., Coret Ferrer F., Casanova Estruch B. Estudio de la afectación medular en la Esclerosis Múltiple. Establecimiento de patrones de lesión en neuroimagen y su relación con la discapacidad. Tesis doctoral, 2015. Universidad de Valencia
2. Minagar A, Jy W, Jimenez JJ, Alexander JS. Multiplesclerosis as a vascular disease. *Neurol Res.* 2006;28(3):230–5.
3. D'haeseleer M, Hostenbach S, Peeters I, **et al.** Cerebral hypoperfusion: a new pathophysiologic concept in multiplesclerosis? *J CerebBloodFlow& Meta.* 2015;35:1406–10.
4. Moccia M, Lanzillo R, Palladino R, et al. The Framingham cardiovascular risk score in multiplesclerosis. *Eur J Neurol.* 2015 Aug 1;22(8):1176–83.
5. Flammer J, Pache M, Resink T (2001) Vasospasm, its role in the pathogenesis of diseases with particular reference to the eye. *Prog Retin Eye Res* 20: 319--- 349.
6. Kochkorov A, Gugleta K, Kavroulaki D, **et al.** (2009) Rigidity of retinal vessels in patients with multiplesclerosis. *Klin Monbl Augenheilkd* 226: 276--- 279
7. Swank RL, Roth JG, Woody DC, Jr. Cerebral bloodflow and red cell delivery in normal subjects and in multiplesclerosis. *Neurol Res* **1983**; 5:37–59.
8. Brooks DJ, Leenders KL, Head G, et al. Studies on regional cerebral oxygen utilisation and cognitive function in multiplesclerosis. *J Neurol Neurosurg Psychiatry* **1984**; **47**: 1182–1191.

9. Lycke J, Wikkelso C, Bergh AC, J **et al.** Regional cerebral bloodflow in multiplesclerosis measured by single photon emission tomography with technetium-99m hexamethylpropyleneamineoxime. *EurNeuro* 1993; 33: 163–167.

10. Metz I, Uccinetti C, Openshaw H, et al. Autologous haematopoietic stem cell transplantation fails to stop demyelination and neurodegeneration in multiplesclerosis. *Brain* 2007 130 (5): 1254–1262.

UNDER PEER REVIEW