

Case report

A Transmesocolic Hernia of the Transverse Colon with Intestinal Obstruction

Abstract

Internal hernias can be either congenital or acquired. Meyers described several main types of internal hernias, including paraduodenal, pericecal, foramen of Winslow, transomental, transmesenteric, transmesocolic, intersigmoid, and retroanastomotic hernias. While the overall incidence of internal hernias is relatively low, ranging from 0.2% to 0.9%, and they account for only 0.5% to 5.8% of cases of intestinal obstruction, they can be life-threatening with a mortality rate exceeding 50% if strangulation occurs.

In the case of transmesocolic hernias, defects in the mesentery can be congenital, surgically induced, traumatic, inflammatory, or idiopathic in origin. Our reported case represents a rare occurrence in an adult without a history of trauma or previous bowel surgery. Congenital transmesocolic hernias are exceptionally uncommon, with only a few cases reported in the medical literature.

Here, we present a case of a congenital transmesocolic hernia involving the transverse colon, leading to intestinal obstruction in a 50-year-old male patient. The condition was diagnosed preoperatively, and an emergency laparotomy was performed.

Keywords

Transmesocolic hernia, Internal hernia, Small bowel obstruction

Introduction

Transmesocolic hernia is an exceptionally uncommon type of internal hernia, with reported incidences ranging from 0.6% to 5.8% of all cases of small bowel obstruction. Among internal hernias, transmesocolic hernias make up approximately 5% to 10% of cases. Specifically, transmesocolic hernias involving the transverse colon are exceedingly rare, while those involving the sigmoid colon account for the majority, around 60%, of all mesocolic hernias. [1,2]

In our case, we confirmed the presence of a congenital transmesocolic hernia involving the transverse colon through a laparotomy procedure. The hernia was successfully reduced, and the defect was closed, resulting in a full recovery for the patient.

It's worth noting that acquired transmesocolic hernias, often related to previous abdominal surgeries, are becoming more common. However, congenital transverse transmesocolic hernias remain exceptionally rare, and their preoperative diagnosis presents a significant challenge. [1,2,3]

Case Presentation

On June 3, 2007, a 50-year-old male patient was admitted to our centre with complaints of abdominal pain, abdominal distention, and vomiting persisting for two days. He had no prior history of gastrointestinal surgery. During the physical examination, the patient displayed generalized abdominal distention and tenderness, with rigidity noted over the epigastric and left upper quadrant of the abdomen. Laboratory tests returned normal results. An abdominal x-ray taken in the supine position revealed multiple small bowel loops displaying air-fluid levels but no free air under the diaphragm, indicative of acute intestinal obstruction.

Subsequent surgical laparotomy revealed a transmesocolic internal hernia involving the transverse colon, leading to small bowel obstruction. Transmesocolic hernia defect of 8x4 cm in size and was located to the left of the middle colic vessels would be similar to Treves avascular field. The proximal small bowel loops had herniated through this defect into the supra-colic compartment. Fortunately, the contents were easily reduced, and the defect in the transverse mesocolon was meticulously repaired using 2.0 silk sutures. The small bowel displayed viability and, therefore, did not require resection. The patient's postoperative recovery was uneventful, and he was discharged on the 8th day following the surgery. (Fig 1-6)

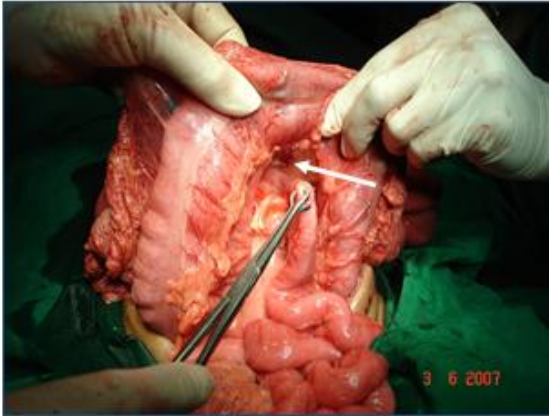


Fig-1 Intraoperative photograph showing transmesocolic internal hernia

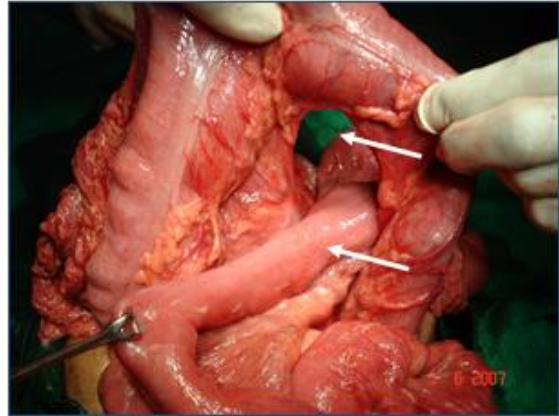


Fig-2 Intraoperative photograph showing transmesocolic strangulated small bowel

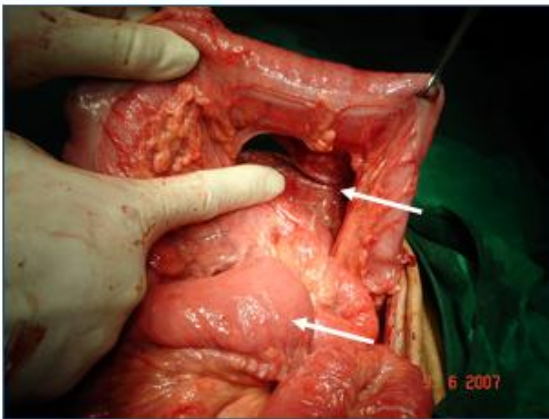


Fig-3 Intraoperative photograph showing transmesocolic hernia and Small bowel released

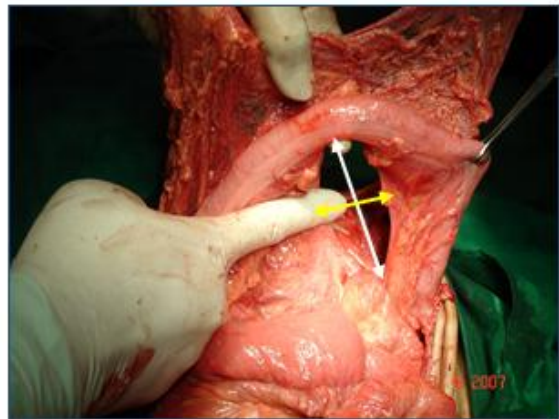


Fig-4 Intraoperative photograph showing transmesocolic defect

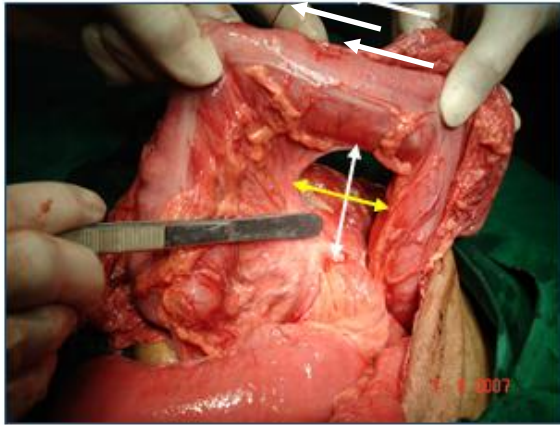


Fig-5 Intraoperative photograph showing transmesocolic defect of size 8x4 cm

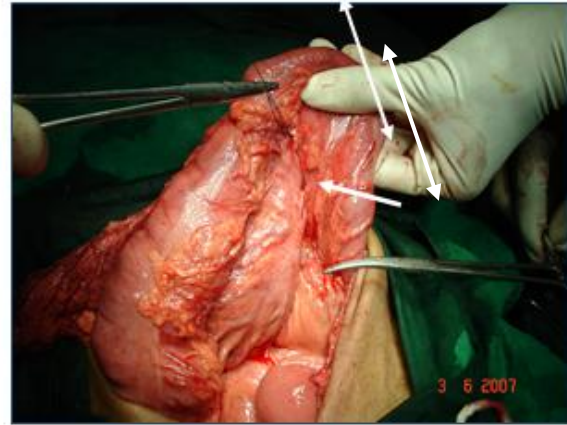


Fig-6 Defect in the transverse mesocolon was repaired using 2.0 silk sutures.

Discussion

The anomaly known as transmesocolic hernia, which was initially reported by Rokitansky in 1835, represents an exceedingly rare form of internal hernia. The exact cause of congenital transmesocolic hernias remains unclear. In 1919, Pringle proposed that the area within the transverse mesocolon to the left of the midline colic vessels, referred to as Treves' avascular field, is particularly susceptible to thinning and avascular changes, potentially leading to the development of transmesocolic defects and subsequent internal hernias. [2,4,5]

The first documented case of a transmesocolic hernia was reported by Loeb in 1944. From 2000 to 2020, we identified 26 cases of congenital transverse transmesocolic hernias in adults. There is a predominance of females, with 16 female and 10 male cases. In 88% of these cases, the hernia defect was located to the left of the midcolic artery, and the hernia contents consisted exclusively of small bowel in 84% of cases, while in 8%, only the sigmoid colon was involved. Abdominal pain was reported in 96% of cases, vomiting in 85%, and two patients exhibited evidence of an abdominal lump. It's worth noting that in adults, most mesenteric defects are acquired as a result of previous gastrointestinal surgeries, abdominal trauma, or intraperitoneal inflammation. Our case represented a rare congenital occurrence in an adult without a history of trauma or prior bowel surgery. [1,2,4,6]

For patients suspected of having an internal hernia, a CT abdomen is considered the gold standard imaging modality for assessing bowel obstruction and suspected internal hernias. Common imaging features of internal hernias include crowding of small bowel loops within a hernia sac and crowding, twisting, and stretching of mesenteric vessels. [2,4,5]

In cases of suspected internal hernia, early surgical intervention is advisable due to the high rates of complications and associated morbidity and mortality. Surgical intervention is the preferred treatment, although performing a laparoscopic approach can be more challenging, especially in emergency situations. [6,7]

Conclusion

Transmesocolic internal hernias are extremely rare and CT abdomen is the gold standard imaging modality to diagnose the internal hernia. The treatment is surgical and consist in hernia

reduction and closure of the defect, with a good prognosis. Fairley surgical intervention is the key to decrease morbidity and mortality.

Ethical Approval

As per international standard or university standard written ethical approval has been collected and preserved by the author(s).

Consent

As per international standard or university standard, patient(s) written consent has been collected and preserved by the author(s).

References

1. Jung P, Kim MD, Ryu TH, Choi SH, Kim HS, Lee KH, Park JH. Transmesocolic hernia with strangulation in a patient without surgical history: case report. *World J Gastroenterol.* 2013 Mar 28;19(12):1997-9. doi: 10.3748/wjg.v19.i12.1997. PMID: 23569347; PMCID: PMC3613117.
2. Nolasco Vaz J, Dias R, Faria A, Sousa M, Fernandes S, Nogueira F, et al. Transverse Congenital Transmesocolic Hernia: A Case Report and Review of the Literature. *Clin Surg.* 2021; 6: 3082.
3. Agarwal AA, Sonkar AA, Singh KR, Rai A. Left-sided transmesocolic herniation of small bowel in an otherwise unaffected abdomen. *BMJ Case Rep.* 2015 May 15;2015:bcr2014207499. doi: 10.1136/bcr-2014-207499. PMID: 25979958; PMCID: PMC4434302
4. ubasinghe, D., Keppetiyagama, C.T. & Samarasekera, D.N. Jejunal obstruction due to a variant of transmesocolic hernia: a rare presentation of an acute abdomen. *BMC Surg* 15, 57 (2015). <https://doi.org/10.1186/s12893-015-0051-z>
5. Han N Beh, Yuni F Ongso, David B Koong, Transmesocolon internal hernia masking as simple sigmoid volvulus, *Journal of Surgical Case Reports*, Volume 2020, Issue 3, March 2020, rjaa017, <https://doi.org/10.1093/jscr/rjaa017>
6. T. Kuga, S. Taniguchi, T. Inoue, N. Zempo, and K. Esato, "The occurrence of a strangulated ileus due to a traumatic transmesenteric hernia: report of a case," *Surgery Today*, vol. 30, no. 6, pp. 548–550, 2000.
7. Kandaragi NG, Vinayagam S, Mudali S. Stretched bowel sign in combined transmesocolic and transomental internal hernia: A case report and review of literature. *Indian J Radiol Imaging* 2014; 24:171-4.

8. Gupta, Rahul & Pokharia, Pradip & Varshney, Rahul. (2020). Transmesocolic Internal Hernia: a Rare Cause of Bowel Obstruction. *Journal of Gastrointestinal Surgery*. 24. 10.1007/s11605-020-04535-4.
9. Fan HP, Yang AD, Chang YJ, Juan CW, Wu HP. Clinical spectrum of internal hernia: A surgical emergency. *Surg Today*. 2008;38(10):899-904.
10. Yang DH, Chang WC, Kuo WH, Hsu WH, Teng CY, Fan YG. Spontaneous internal herniation through the greater omentum. *Abdom Imaging*. 2009;34(6):731-733.

UNDER PEER REVIEW