

Original Research Article

Interrupted versus Running Sutures for Amniotic Membrane Fixation in cases of Resistant Infected Corneal Ulcers

Abstract

Background: Infected corneal ulcers that don't show any healing within two weeks despite proper medical treatment are considered resistant and need surgical intervention. ⁽¹⁾ the amniotic membrane transplantation has been used to treat resistant corneal ulcers because it acts as a bioactive substratum that accelerates epithelial healing. ⁽²⁾

Aim of the work: comparison between interrupted and running sutures for amniotic membrane fixation in cases of resistant infected corneal ulcers.

Patients and methods: This prospective, comparative, interventional randomized study was carried out on 40 eyes with resistant infected corneal ulcers. They underwent amniotic membrane transplantation as an adjunctive to the medical treatment. Divided into 2 groups: group A (interrupted suture group) and group B (running suture group). The duration of study was 12 months.

Results: The duration of healing in group A ranged from 25 to 40 days with mean duration of 34.25 ± 4.94 days, while in group B the duration of healing ranged from 20 to 40 days with mean duration of 31.0 ± 6.61 days. UDVA didn't improve in 65% of cases in group A and 45% of cases in group B.

Conclusion: Amniotic membrane transplantation is an adjunctive surgical procedure for the management of infectious corneal ulcer by promoting wound healing and reducing inflammation. We noticed that the running suture adhered the amniotic membrane firmly to

the entire corneal surface so it accelerated the corneal epithelial healing and made it less affected with eyelid movement and less annoying to patient.

Key words: Resistant Infected Corneal Ulcers, Amniotic Membrane, Interrupted Versus Running Sutures.

UNDER PEER REVIEW

Introduction

Amniotic membrane is the innermost layer of the placenta which is semi-transparent, avascular tissue.^(3,4) Infected corneal ulcers that don't show any healing within two weeks despite proper medical treatment are considered resistant and need surgical intervention.⁽¹⁾ Amniotic membrane promotes epithelialization, reduces formation of scars and new vessels, and reduces inflammation.⁽⁵⁾ It contains nerve growth factor and believed to be non-immunogenic.⁽⁶⁾ Also it reduces the pain caused by friction of eyelids over the ulcer surface and decrease the risk of infection.⁽⁷⁾ Interrupted and running sutures are types of suturing techniques that have been used to fixate the amniotic membrane to the cornea.^(8,9)

Materials and Methods

There was adequate provision to maintain privacy of participants and confidentiality of the data are as follows: We put a code number to every case with the name and address was kept in special file. We hid the name of the case when we used the research. We used the results of the study only in a scientific manner and did not use it in any other aim.

Our prospective study was carried out at The Department of Ophthalmology, Corneal bank and research unit clinic, Tanta University Hospitals, a tertiary referral center on forty eyes suffered from resistant infected corneal ulcers. The duration of study was 12 months, starting from 1st of December 2019 to 30st of November 2020. Inclusion criteria: 1. Patients with infectious keratitis not responsive to topical treatment for at least 7 days. 2. Corneal infiltration area measuring less than 8 mm in diameter. 3. Age above 18 years. Exclusion criteria: 1. Corneal infiltration area measuring more than 8 mm in diameter. 2. Corneal perforation or impending perforation. 3. Patients with other ocular diseases. 4. Previous ocular surgery. 5. Age less than 18 years. 6. Pregnancy and lactation.

1-History taking: Detailed history was collected from the patients including (age, sex, any systemic disorders, and past history of topical or systemic medications. History of contact lens wearing, corneal scratch, corneal foreign body, and eye trauma.

2-Clinical examination The pre- operative examination for all patients included: Visual acuity (VA): Uncorrected distance visual acuity (UDVA) and Corrected distance visual acuity (CDVA). Slit lamp examination to assess the ulcer size in both horizontal and vertical meridians, depth of ulcer, density of the surrounding infiltration, edema and hypopyon. Fundus examination was performed whenever possible. Ultrasonography to access the fundus in opaque media

3.Operative technique: Anesthesia: general anesthesia.(GA). AfterGA, debridement of the ulcer base and necrotic tissue was performed with a sclerotome blade and a micro sponge, and the poorly adherent epithelium adjacent to the edges of the ulcer was removed. Freshly prepared monolayer AM was used. Group A: the amniotic membrane was applied with the epithelial side up and the stromal side in contact with the corneal surface then sutured to the intact edges of the ulcer with interrupted 10/0 nylon suture in 20 eyes. Group B: the amniotic membrane was applied with the epithelial side up and the stromal side in contact with the corneal surface then sutured to the intact edges of the ulcer with running 10/0 nylon suture in the other 20 eyes. Bandage contact lens was applied.

4. Post-operative treatment: Topical antimicrobial therapy according to the pre-operative culture and sensitivity results. After epithelialization was completed the fluorometholone ophthalmic suspension was used three times a day and the topical antimicrobial therapy was modified according to the case.

5. Follow up: Follow up was daily for the first week, weekly for the first month and then monthly for 3months. Routine ophthalmic examination was done with special attention to the cornea for signs of healing and presence of any complication.

Results

Our prospective study was done on 40 patients divided into two groups; group A (The amniotic membrane was sutured using interrupted 10/0 nylon sutures) consisted of 9 males and 11 females, their age ranged between 28 and 63 years with mean age of 45.70 ± 11.32 years while group B (The amniotic membrane was sutured using running 10/0 nylon sutures) was 12 males and 8 females, their age ranged between 25 and 66 years with mean age of 43.95 ± 12.31 years as shown in **table 1**. We found that the most common risk factor of persistent corneal ulcer was plant trauma in 45% of cases in each group followed by foreign body in 35% and 20% of cases in group A and group B respectively as shown in **table 2**. The percentage of cases that healed within 20 days was (0.0 % and 10% in group A and group B respectively) while the percentage of cases that healed within 40 days was (30% and 20% in group A and group B respectively) as shown in **table 3**. UDVA didn't improve in 65% of cases in group A and 45% of cases in group B. Improvement in VA more than one line was 10%, 15% in group A and group B respectively as shown in **table 4**. After amniotic membrane transplantation, healing with scar but no vascularization occurred in 6 cases (30%) and 4 cases (20%) in group A and group B respectively while healing with scar and vascularization occurred in 14 cases (70%) and 16 cases (80%) in group A and group B respectively as shown in **table 5**.

Discussion

Corneal persistent epithelial defects, ulcers, and perforations are significant challenges in ophthalmology. Possible aetiologies are infections, autoimmune diseases, neuropathic disorders and other conditions. ⁽¹⁰⁾Infectious keratitis is one of the leading causes of corneal blindness. Infection disrupts the normal corneal healing process and induces inflammation, limbal cell dysfunction, and corneal surface irregularity, which can lead to corneal opacities or persistent epithelial defects. Untreated PED can cause corneal thinning, resulting in

corneal perforation. ⁽¹¹⁾ Infectious corneal ulceration is an avoidable vision threatening disease that still represents a considerable proportion of the daily new cases that creates a huge burden on the resources of health services. Our prospective study included 40 patients who were divided into two groups; The interrupted suture group consisted of 9 males and 11 females, their age ranged between 28 and 63 years with mean age of 45.70 ± 11.32 years while The running suture group was 12 males and 8 females, their age ranged between 25 and 66 years with mean age of 43.95 ± 12.31 years. There were no statistically significant differences between the study groups in demographic data. The study of Nuzzi R, and his group was similar to our study, they used interrupted sutures 20 patients 9 females, 11 males with mean age of 42.86 ± 13.54 years while the single running suture were 20 patients 12 females, 8 males with mean age of 45.34 ± 16.12 years. ⁽¹²⁾ However, the number of study subjects was higher in other studies as Laspina, F. et and his group in their retrospective, chart-reviewed study of patients diagnosed with infectious corneal ulcers, including 660 patients (435 males and 22 Other studies had lower subjects' numbers in their research like Dhillon HK. and his group in their interventional, prospective study which included 30 patients underwent AMT, 27 males and 3 females with mean age of 48.1 ± 18.4 years. As well, Sereda KV, and his group ⁽¹³⁾ there were 17 men (60.7%) and 11 women (39.3%). Mean patient age was 51.3 ± 0.81 years. ⁽¹⁴⁾ Moreover, Letk and his group found that the mean age of patients was

55.3 years (ranged from 9 to 78 years). The male-female ratio was 2:1. ⁽¹⁵⁾ Average age at presentation according to Roozbahani M, and his group was 56.0 years (ranged from 6 to 92 years), and most of the patients were females (n= 31, 60.8%). ⁽¹⁶⁾ We found that the infection with mixed organisms was the most prevalent cause of infected corneal ulcer in interrupted suture and running suture groups (40%-75% respectively). In interrupted suture group, bacterial and fungal infection had the same percent 30% while in running suture

group, it was 15% bacterial and 10% fungal infection. Other studies as, Roozbahani M, and his group noticed in their study that the most common aetiologies of infected corneal ulcer were bacterial (44.7%) and fungal (31.9%).⁽¹⁶⁾ As well, Laspina,F. and his group in their study of bacterial infectious keratitis was 51% while fungal infectious keratitis was 26%.⁽¹⁷⁾ We found that the most common risk factor of resistant infected corneal ulcer was plant trauma in 45% of cases in each group followed by foreign body in 35% and 20% of cases in group A and group B respectively. Contact lens wearer and exposure keratitis presented equally with 10% in group A, and 20%, 15% respectively in group B. The results of Casalita V and his group study in patients with infectious corneal ulcer was similar to ours, they had the most common local predisposing factors for corneal ulcer were nonsurgical trauma (22 eyes with foreign body particles, followed by contact lens use (14 eyes), surgical trauma (2 eyes), eyelid function disorders, ocular surface disorders, irradiation-induced dry eye and allergic conjunctivitis.⁽¹⁸⁾ While Masoumi A and his group in a study of thirty eight cases of culture-proven klebsiella keratitis were identified in 37 patients. They identified Multiple predisposing factors; 33 eyes with history of ocular trauma (7 cases), pre-existing ocular surface disease (7 cases) and diabetes (6 cases) history of previous keratoplasty (11 cases).⁽¹⁹⁾ In the study of Laspina,F and his group approximately half of cases had a history of trauma, the other half of these involved foreign bodies.⁽¹⁷⁾ In our study, the duration of healing in group A ranged from 25 to 40 days with mean duration of 34.25 ± 4.94 days, while in group B the duration of healing ranged from 20 to 40 days with mean duration of 31.0 ± 6.61 days. We found that the percentage of cases that healed within 20 days was (0.0% and 10% in group A and group B respectively) while the percentage of cases that healed within 40 days was (30% and 20% in group A and group B respectively with more acceleration of healing in group B. Letk and his group study showed that PEDs healed within an average of 25.5 days (ranged between 5 and 68 days) after surgery. The epithelial

defect healed after the first AMT in 21 eyes (70%). In 9 eyes (30%), the defect persisted after the first AMT. the PED did not heal or recurred after the first AMT in 15 (50%) of 30 eyes. ⁽¹⁵⁾ In contrary, Fan J and his group reported that the average duration of epithelial healing was 1.97 ± 0.56 weeks (ranged from 1 to 3.5) in a study of AMT by using interrupted and running sutures. ⁽²⁰⁾ In our study UDVA didn't improve in 65% of cases in group A and 45% of cases in group B. Improvement in VA more than one line was 10%, 15% in group A and group B respectively. There were no statistically significant differences between the study groups according to UDVA after healing. Nuzzi R, and his group found that Mean UDVA values at 12 months after surgery were 0.37 ± 0.11 (LogMAR) in the interrupted sutures group, 0.36 ± 0.13 (LogMAR) in the running sutures group, no statistically significant differences UDCA differences were detected among the study groups. ⁽¹²⁾ In addition, the study of Schuerch K and his group evaluated the outcome of amniotic membrane transplantation by as using interrupted sutures as treatment for corneal ulcers; reported UDVA improved significantly from a mean of 1.8 ± 0.6 LogMAR at baseline to a mean of 1.6 ± 0.8 LogMAR. ⁽²¹⁾ Casalita V, and his group study aimed to describe the outcomes of AMT in patients with infectious corneal ulcer by using interrupted sutures they noticed that baseline UDVA improved from 2.48 (0.22–2.80) LogMAR to 1.30 (0–2.80) LogMAR within 3–4 weeks postoperatively and to 0.94 (0–2.80) LogMAR at the last follow-up. ⁽¹⁶⁾ Dhillon HK and his group, reported that UDVA was 1.30 ± 0.5 LogMAR ⁽⁶⁴⁾ while Letk and his group found that the mean visual acuity before and after the surgery was 0.04 (range, 0.01-0.13) and 0.05 (range, 0.01-0.20), respectively with improvement post-operative in the previous studies. ⁽¹⁵⁾ In our study; After AMT healing with scar but no vascularization occurred in 6 cases (30%) and 4 cases (20%) in group A and group B respectively while healing with scar and vascularization occurred in 14 cases (70%) and 16 cases (80%) in group A and group B respectively. The majority of the patients 50 (83.3%),

in Dhillon HK and his group study, had no pre-existing corneal vascularization when examined preoperatively; remaining ten patients had superficial vascularization of which eight (13.3%) it was observed deep vascularization among the patients in amniotic membrane transplantation group. ⁽¹⁴⁾ Chen Y and his group reported that corneal neovascularization were observed in 3 eyes in AMT group and 4 eyes in LKP group. ⁽²²⁾ We found that the potential differences between the two groups that the running suture technique promotes more stable, adherent and fixed surface with less fluid leakage for rapid, less annoying healing of corneal ulcers.

Conclusion:

Amniotic membrane transplantation is an adjunctive surgical procedure for the management of infectious corneal ulcer by promoting wound healing and reducing inflammation. Running suture adhered the amniotic membrane firmly to the entire corneal surface so it accelerated the corneal epithelial healing and made it less affected with eyelid movement.

Ethical Approval:

This current research's protocol has been accepted from local research ethical committee on (33338/09/19), Quality Assurance unit, faculty of medicine.

Consent

As per international standard or university standard, patient(s) written consent has been collected and preserved by the author(s).

References:

1. Livingstone I, Stefanowicz F, Moggach S, Connolly J, Ramamurthi S, Mantry S, Ramaesh K. **New insight into non-healing corneal ulcers: iatrogenic crystals.** Eye (Lond). 2013 Jun;27(6):755-62.
2. Stamate AC, Tătaru CP, Zemba M. **Update on surgical management of corneal ulceration and perforation.** Rom J Ophthalmol. 2019 Apr-Jun;63(2):166-173.
3. Malhotra C, Jain AK. **Human amniotic membrane transplantation: Different modalities of its use in ophthalmology.** World J Transplant. 2014 Jun 24;4(2):111-21.
4. Ngan ND, Chau HT. **Amniotic membrane transplantation for Mooren's ulcer.** Clin Exp Ophthalmol. 2011 Jul;39(5):386-92.
5. Ashraf NN, Adhi MI. **Outcome of application of amniotic membrane graft in ocular surface disorders.** J Pak Med Assoc. 2017 Jul;67(7):1045-1049.
6. Mohan S, Budhiraja I, Saxena A, Khan P, Sachan SK. **Role of multilayered amniotic membrane transplantation for the treatment of resistant corneal ulcers in North India.** Int Ophthalmol. 2014 Jun;34(3):485-91.
7. Stamate AC, Tătaru CP, Zemba M. **Update on surgical management of corneal ulceration and perforation.** Rom J Ophthalmol. 2019 Apr-Jun;63(2):166-173.
8. Uhlig CE, Müller VC. **Resorbable and running suture for stable fixation of amniotic membrane multilayers: A useful modification in deep or perforating sterile corneal ulcers.** Am J Ophthalmol Case Rep. 2018 Apr 19;10:296-299.
9. Röck T, Bartz-Schmidt KU, Landenberger J, Bramkamp M, Röck D. **Amniotic Membrane Transplantation in Reconstructive and Regenerative Ophthalmology.** Ann Transplant. 2018 Mar 6;23:160-165.

10. Luccarelli SV, Villani E, Lucentini S, Bonsignore F, Sacchi M, Martellucci CA, Nucci P. **Sutureless "Contact Lens Sandwich" Technique for Amniotic Membrane Therapy of Central Corneal Ulcers.** *Eur J Ophthalmol.* 2022 Jul;32(4):2141-2147.
11. Shin JH, Jung YH, Song HB, Kim MK, Yoon CH. **Sutureless contact lens-type amniotic membrane for persistent epithelial defects after infectious keratitis.** *Int J Ophthalmol.* 2022 Aug 18;15(8):1404-1406.
12. Nuzzi R, Burato C, Tridico F, Nuzzi A, Caselgrandi P. **Advantages of Double Running Sutures in Astigmatism After Penetrating Keratoplasty.** *Clin Ophthalmol.* 2022 Mar 15;16:797-802.
13. Sereda KV, Drozhzhyna GI, Gaidamaka TB. **Using an improved multilayer amniotic membrane transplantation technique.** *J.ophthalmol. (Ukraine).*2022;2:3-9.
14. Dhillon HK, Bahadur H, Raj A. **A comparative study of tarsorrhaphy and amniotic membrane transplantation in the healing of persistent corneal epithelial defects.** *Indian J Ophthalmol.* 2020 Jan;68(1):29-33.
15. Letko E, Stechschulte SU, Kenyon KR, Sadeq N, Romero TR, Samson CM, Nguyen QD, Harper SL, Primack JD, Azar DT, Gruterich M, Dohlman CH, Baltatzis S, Foster CS. **Amniotic membrane inlay and overlay grafting for corneal epithelial defects and stromal ulcers.** *Arch Ophthalmol.* 2001 May;119(5):659-63.
16. Roozbahani M, Hammersmith KM, Rapuano CJ, Nagra PK, Zhang Q. **Therapeutic penetrating keratoplasty for acanthamoeba keratitis: a review of cases, complications and predictive factors.** *Int Ophthalmol.* 2019 Dec;39(12):2889-2896.
17. Laspina F, Samudio M, Cibils D, Ta CN, Fariña N, Sanabria R, Klauss V, Miño de Kaspar H. **Epidemiological characteristics of microbiological results on patients with infectious corneal ulcers: a 13-year survey in Paraguay.** *Graefes Arch Clin Exp Ophthalmol.* 2004 Mar;42(3):204-9.

18. Casalita V, Nora RLD, Edwar L, Susiyanti M, Sitompul R. **Amniotic membrane transplantation for infectious corneal ulcer treatment: a cohort retrospective study.** Med J Indones . 2020Dec;29(4):379-85.
19. Masoumi A, Zeidabadinejad H, Jafari B, Esfandiari A, Soleimani M. **Infectious keratitis caused by Klebsiella spp.: predisposing factors, presentation, and management.** Int Ophthalmol. 2022 Sep 17.
20. Fan J, Wang M, Zhong F. **Improvement of Amniotic Membrane Method for the Treatment of Corneal Perforation.** Biomed Res Int. 2016;2016:1693815.
21. Schuerch K, Baeriswyl A, Frueh BE, Tappeiner C. **Efficacy of Amniotic Membrane Transplantation for the Treatment of Corneal Ulcers.** Cornea. 2020 Apr;39(4):479-483
22. Chen Y, Gao R, Gao M, Liu Q, Song L. **Comparative Study on the Efficacy of Frozen Amniotic Membrane Transplantation and Lamellar Keratoplasty in the Treatment of Mooren Ulcer.** J Craniofac Surg. 2021 Mar-Apr 01;32(2):637-641.

Figure legend:

1-Figure (1): A photo showing resistant infected corneal ulcer of a male patient aged 37-years old underwent AMT using running suture.

2-Figure (2): A photo showing resistant infected corneal ulcer of a female patient 55-years old underwent AMT using running suture.

3-Figure (3): A photo showing resistant infected corneal ulcer of a female patient 47-years old underwent AMT using interrupted suture.

4-Figure (4): A photo showing resistant infected corneal ulcer of a male patient 60-years old underwent AMT using interrupted suture.

UNDER PEER REVIEW

Table (1): Demographic data

Demographic Data	Group A (n = 20)		Group B (n = 20)		Test of sig.	p
	No.	%	No.	%		
Sex						
Male	9	45.0	12	60.0	$\chi^2=0.902$	0.342
Female	11	55.0	8	40.0		
Age (years)						
Min. – Max.	28.0 – 63.0		25.0 – 66.0		t=0.468	0.643
Mean \pm SD.	45.70 \pm 11.32		43.95 \pm 12.31			

SD: Standard deviation χ^2 : Chi Square test t: Student t-test

p: p value for comparing between **the two studied groups**

UNDER PEER REVIEW

Table (2): Risk factors

Risk factors	Group A (n = 20)		Group B (n = 20)		χ^2	#p
	No.	%	No.	%		
Plant trauma	9	45.0	9	45.0	1.685	0.640
Contact lens wearing	2	10.0	4	20.0		
Foreign body	7	35.0	4	20.0		
Exposure keratitis	2	10.0	3	15.0		

χ^2 : Chi Square test

p: p value for comparing between **the two studied groups**

UNDER PEER REVIEW

Table (3): Duration of healing

Duration of healing (days)	Group A (n = 20)		Group B (n = 20)		χ^2	p
	No.	%	No.	%		
20	0	0.0	2	10.0	4.130	0.389
25	2	10.0	5	25.0		
30	5	25.0	4	20.0		
35	7	35.0	5	25.0		
40	6	30.0	4	20.0		

χ^2 : Chi square test

p: p value for comparing between the two studied groups

UNDER PEER REVIEW

Table (4): UDVA changes

UDVA after healing	Group A (n = 20)		Group B (n = 20)		χ^2	#p
	No.	%	No.	%		
One line gain	5	25.0	8	40.0	1.620	0.445
More than one line gain	2	10.0	3	15.0		
Not improved	13	65.0	9	45.0		

χ^2 : Chi Square test

p: p value for comparing between **the two studied groups**

UNDER PEER REVIEW

Table (5): Corneal scarring and vascularization after healing

Corneal Scarring and vascularization after healing	Group A (n = 20)		Group B (n = 20)		χ^2	#p
	No.	%	No.	%		
Healed with scar but no vascularization	6	30.0	4	20.0	0.533	0.465
Healed with scar and vascularization	14	70.0	16	80.0		

χ^2 : Chi Square test

p: p value for comparing between **the two studied groups**

UNDER PEER REVIEW

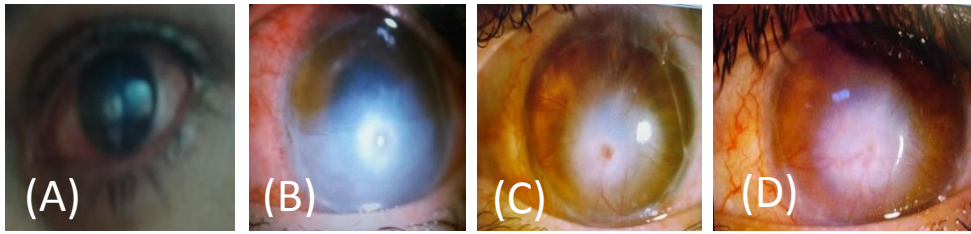


Figure 1: A photo of male patient aged 37 years old presented with central round corneal ulcer (A) underwent AMT using running suture (B), the ulcer healed with scar and vascularization within 30 days(C). The sutures were removed after 35 days (D).

UNDER PEER REVIEW

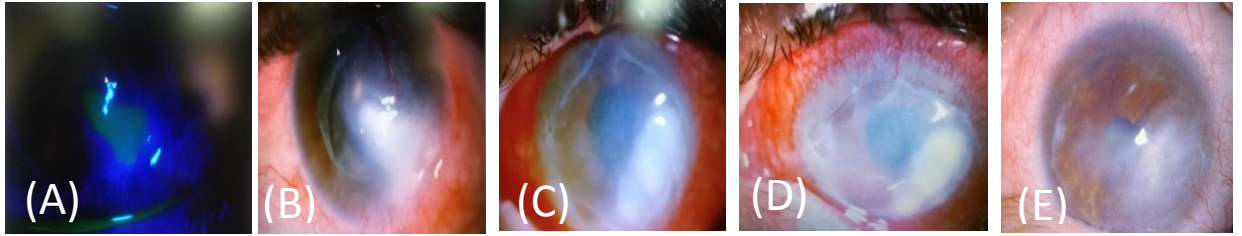


Figure 2: A photo of female patient aged 55 years old presented with a paracentral irregular corneal ulcer (A,B) underwent AMT using running suture (C).The ulcer healed with scar within 25 days(D).The sutures were removed after 35 days (E).

UNDER PEER REVIEW

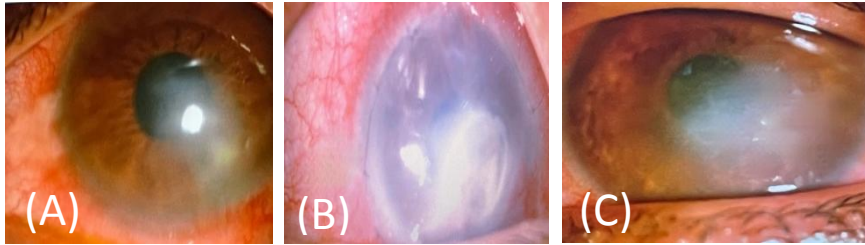


Figure 3: A photo of female patient aged 47 years old presented with para central irregular corneal ulcer (A) underwent AMT using interrupted suture (B). The ulcer healed with scar within 25 days and sutures were removed after 30 days (C).

UNDER PEER REVIEW

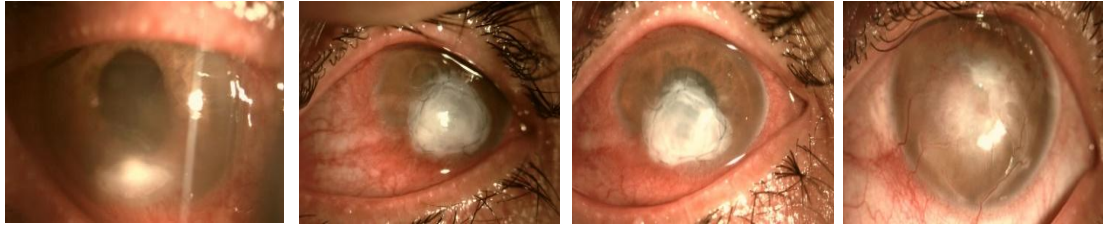


Figure 4: A photo of male patient aged 60 years old presented peripheral irregular corneal ulcer (A) underwent AMT using interrupted suture (B). The ulcer healed with scar and vascularization within 35 days (C). The sutures were removed after 35 days (D).

UNDER PEER REVIEW