

Right Ventricular Myocardial Infarction: A Mono-Centric Retrospective Study

ABSTRACT:

Coronary heart disease is one of the world's leading causes of morbidity and mortality. Much is known about left ventricular myocardial infarction. It was not until much later (1974) that right ventricular myocardial infarction was studied as a distinct entity [1]. Isolated VD MI is rare [2,3,4]. It is often associated with infero-posterior MI (in a third of patients)[2,5], with higher morbidity and in-hospital mortality due to hemodynamic and rhythmic complications [4]. The culprit lesion is often occlusion of the proximal right coronary artery [2,4,6,7]. However, the VD is relatively resistant to infarction and recovers even after prolonged occlusion [8]. In this work, we will study the epidemiological, clinical, electrical, echocardiographic and angiographic aspects of MDI with extension to the VD, as well as its complications and therapeutic modalities.

Keywords : myocardial infarction, acute coronary syndrome, right ventricular.

INTRODUCTION:

Coronary heart disease is one of the world's leading causes of morbidity and mortality. Much is known about left ventricular myocardial infarction. It was not until much later (1974) that right ventricular myocardial infarction was studied as a distinct entity [1]. Isolated VD MI is rare [2,3,4]. It is often associated with infero-posterior MI (in a third of patients) [2,5], with higher morbidity and in-hospital mortality due to hemodynamic and rhythmic complications [4]. The culprit lesion is often occlusion of the proximal right coronary artery [2,4,6,7]. However, the VD is relatively resistant to infarction and recovers even after prolonged occlusion [8]. In this work, we will study the epidemiological, clinical, electrical, echocardiographic and angiographic aspects of MDI with extension to the VD, as well as its complications and therapeutic modalities.

MATERIALS AND METHODS:

1. Type, place and period of recruitment :

This is a retrospective and descriptive mono-centric study spread over a period of 01 year, covering patients hospitalized in the Cardiology A department of the "Ligue Nationale de Lutte contre les Maladies Cardiovasculaires at the Mohammed VI University Hospital Center in Marrakech, for myocardial infarction of the left heart extended to the right ventricle.

2. Inclusion criteria :

Patients of all ages, men and women, hospitalized for left-heart infarction, mainly of the inferior wall of the LV, with electrical or echocardiographic criteria demonstrating extension to the VD, were selected.

3. Exclusion criteria :

Patients with inferior LV MI without extension to the VD were excluded.

4. Definition of study parameters

a. Clinical parameters

- Smoking is defined as active or weaned smoking for less than 2 years.
- Diabetes is defined as the use of oral antidiabetics and/or insulin.
- Hypertension defined by a history of treated hypertension
- Dyslipidemia defined by a history of treated dyslipidemia
- Obesity defined by a body mass index (BMI) ≥ 30 kg/m²
- A history of heart disease defined as heart failure, ischemic, valvular, rhythmic, hypertrophic, restrictive or dilated heart disease.

b. Electrical parameters :

ST-segment elevation in the right leads ≥ 1.0 mm is considered a major electrical criterion for defining right ventricular infarction.

c. Echocardiographic parameters :

Echocardiographic results, performed by specialist physicians in the laboratory for the diagnosis of LV MI extended to the VD were systematically sought and reported when available:

- An impaired LVEF is less than 50%. - Impaired TAPSE is less than 16 mm
- An impaired tricuspid S wave is less than 10 cm/sec.
- Impaired VD shortening fraction is less than 35%.

5. Data collection process :

For this study, a fairly exhaustive data sheet was drawn up, containing all the clinical, electrical and echocardiographic data on this pathology, as well as the treatment methods and evolution of these patients.

These data sheets were completed using patient files, which enabled us to obtain the results presented in the following chapter.

Our statistical analysis focused on descriptive statistics (frequency, percentage, mean, standard deviation).

6. Study limits :

Difficulties were encountered in analyzing the files, particularly those that were incomplete.

RESULTS:

1. Population description:

Between January 2018 and December 2019, 65 patients were admitted to the cardiology department for myocardial infarction of inferior topography, including 16 with extension to the right ventricle, i.e. a frequency of 26.14%. 08 of them presented to the emergency department with an acute coronary syndrome picture, while the other 09 patients arrived outside the early revascularization timescale. The age of our patients ranged from 46 to 82, with an average of 62. Peak frequency was between 60 and 70 years of age.

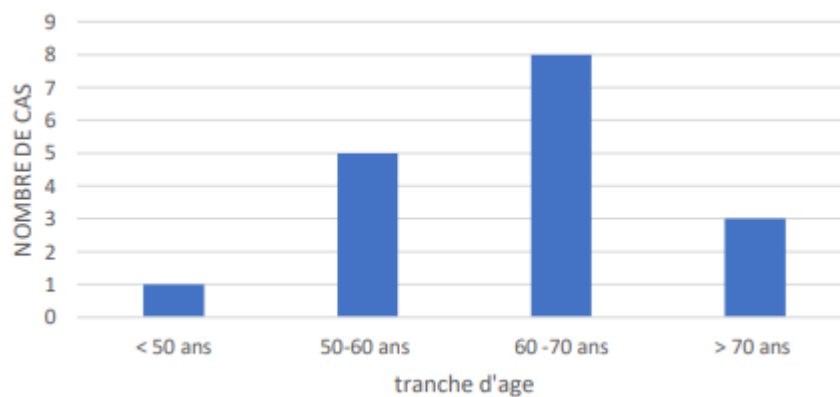


Fig 1: Age distribution of our patients

2. Breakdown by gender

Men make up 82% of the study population, while women account for 18%, with an M/F sex ratio of 4.6.

3. Cardiovascular risk factors :

The cardiovascular risk factors sought in our patients are :

- High blood pressure: 58% of patients have high blood pressure.
- Diabetes: 52% of patients have type 2 diabetes.
- Smoking: 70% of patients smoke,
- Dyslipidemia: present in 11% of patients.
- Obesity: 5% of patients have a BMI>30.
- Coronary heredity: Coronary heredity is found in 5% of patients.

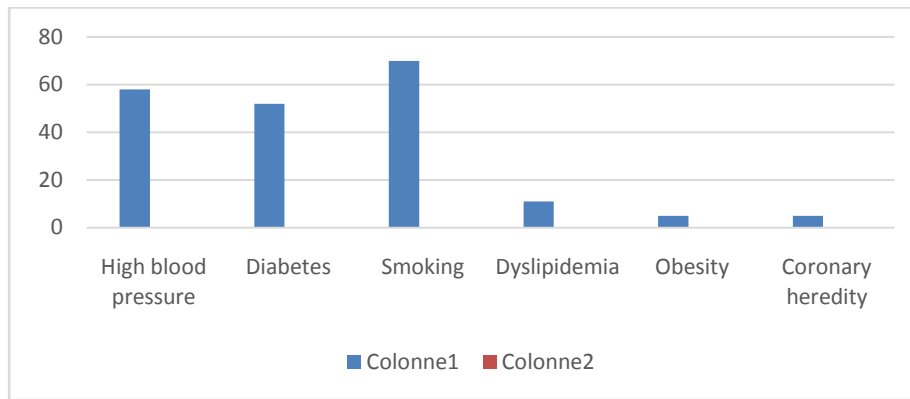


Fig 2: Cardiovascular risk factors

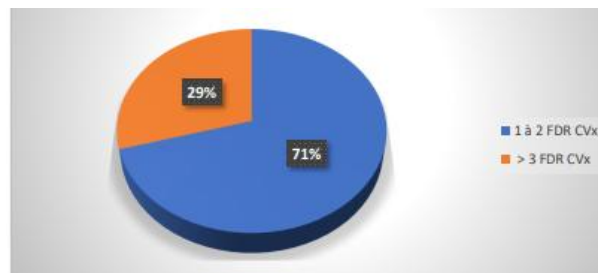


Fig 3: Distribution of patients by number of cumulative risk factors

4. Mode of presentation of our patients :

- 03 of our patients (17%) presented to the emergency department with ST-segment elevation acute coronary syndrome, arriving within 12 hours of the onset of their symptoms.
- 09 patients (52%) consulted 12 hours after the onset of chest pain
- 05 of our patients (29%) presented to the emergency department with non-ST-segment elevation acute coronary syndrome.

5. Physical signs :

Clinical examination of our patients on admission revealed that: 1 patient showed signs of right heart failure, 1 patient showed signs of left heart failure. 3 patients were admitted in shock. 13 patients had a strictly normal clinical examination.

6. ECG appearance of our patients:

The ECG, performed in all patients on admission with right leads in 9 of them, showed :

- Repolarization disorders: Sus ST-segment shift in V3R and V4R (9 patients). Sus ST-segment shift in D II D III AVF (12 patients). Sus ST-segment shift in V1 V2 V3 (1 patient).

- Rhythm disorders: Ventricular tachycardia (01 patient)

- Conduction disorders: 2nd degree AVB (01 patient). 3rd degree AVB (01 patient). Left bundle branch block (02 patients)

7. ECHOCARDIOGRAPHY PROFILE OF OUR PATIENTS :

Doppler echocardiography was performed in all patients. Parameters studied: LV EF, in our series, was impaired in 8 of our patients (47%). LV systolic function, in our study population, was impaired in 9 of our patients (52%) based mainly on TAPSE and tricuspid s-wave parameters.

Disorders of VD segmental kinetics: Akinesia of the VD lateral wall (03 patients). Akinesia of the inferior wall of the VD (01 patient). Akinesia of the anterior wall (01 patient). Pericardial effusion was present in 01 patient. Doppler study revealed tricuspid insufficiency in 03 patients.

8. ANGIOGRAPHIC PROFILE OF OUR PATIENTS :

16 patients were referred for coronary angiography. The various lesions are summarized in the following diagram:

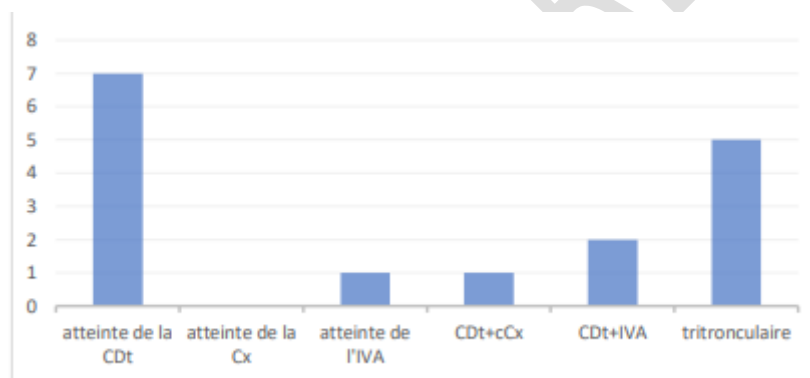


Fig 4: Coronary angiography anomalies

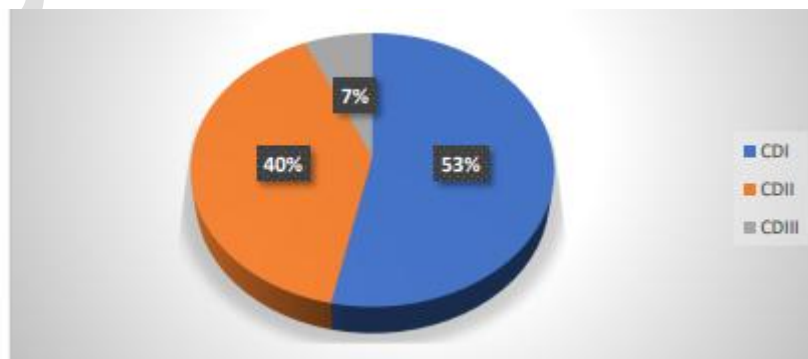


Fig 5: Affected segment of right coronary artery

9. THERAPEUTIC MANAGEMENT:

a. Drug treatment :

Thrombolysis was indicated in 03 patients by Metalysis. Aspirin and Clopidogrel were administered in all our patients. LMWH was used in all our patients. 05 patients required vascular filling. DOBUTAMINE was indicated in 03 patients. Atropine was used in 01 patients. IEC was used in 14 patients. BB was used in 10 patients. All patients received a statin.

b. Instrumental treatment :

Coronary angioplasty was performed in 07 patients, following coronary angiography.

Only one patient benefited from an electrosystolic pacing lead.

c. Surgical treatment :

Only one patient underwent coronary artery bypass surgery.

10. Evolution :

Only one patient died during hospitalization as a result of a high-grade conductive disorder. 03 patients presented hemodynamic instability, stabilized with drug treatment. 02 patients presented rhythmic complications.

11. Length of hospital stay :

The length of hospitalization for our patients varies between 01 and 22 days, with an average of 8 days.

DISCUSSION:

1. Epidemiological profile :

Isolated VD MI is exceptional (0.5-2%). On the other hand, biventricular involvement is frequent, not in anterior MI, where it is found in only 5% of cases, but in posterior MI (inferior, inferolateral, inferobasal), where it is present in 30 to 50% of cases. In our study, biventricular involvement was present in all our patients, and no cases of isolated VD infarction were identified. We also note that VD MI accompanies around 26% of inferior LV necrosis, which is very comparable in different

studies worldwide [24]. Smoking was the main cardiovascular risk factor found in our patients, followed by hypertension and diabetes, in line with the study by s. KHAN et al [25], with a clear male predominance.

2. Clinical profile:

The mode of onset of this combination of VD and inferior MI does not differ greatly from that of isolated inferior MI. Patients present to the emergency department with typical infarct chest pain (found in all our patients), consistent with acute coronary syndrome with or without ST elevation.

Sometimes the patient arrives at a late stage where the early reperfusion phase has been exceeded (post-MI in 52% of our patients), or even at the complication stage, as was the case in 3 of our patients who arrived in cardiogenic shock, requiring special management. [26].

3. Electrical profile :

Electrical diagnosis of VD infarction is essentially based on the detection of ST-segment elevation in the right precordial leads (V3R and V4R). [41] .

On the standard 12-lead ECG, less frequent and less specific electrical signs can be found. However, these may point towards extension to the VD, as described in the first theoretical section, and as seen on the ECG of one of our patients [40].

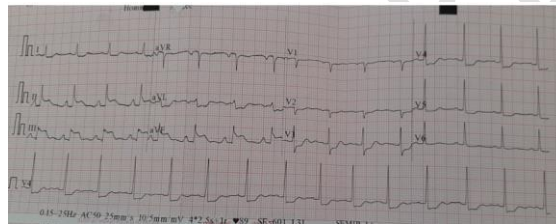


Figure 6: ST segment hypershift in inferior leads (DII, DIII and aVF) , more marked in DIII , with mirror images in lateral leads in one of our patients.

4. Echocardiography profile :

It is now the key examination for the positive diagnosis of biventricular infarction at the patient's bedside, for differential diagnosis and for the search for complications. In two-dimensional echocardiography, the signs in favor of VD infarction are [54-62] :

- Dilatation of the right cavities, with an increase in the ratio of VD diameter to VG diameter
- A disorder of segmental kinetics in the form of akinesia of one or more walls of the right ventricle (the infarcted zone is also thinned and bright at a later stage).
- Paradoxical movement of the interventricular septum.
- The inter-atrial septum may be pushed back towards the left atrium (by increasing right intra-atrial pressure).
- Inferior vena cava may be dilated (>18mm), with loss of inspiratory collapse
- Right ventricular surface shortening fraction (in apical 4-cavity section) is reduced (<50%)
- A small amount of pericardial effusion may be present. Echocardiography can also be used to detect complications and rule out differential diagnoses.

In our study, the echocardiographic signs in favor of VD infarction were essentially altered VD systolic function (09 patients) and disturbances in the segmental kinetics of the VD walls (03 patients).

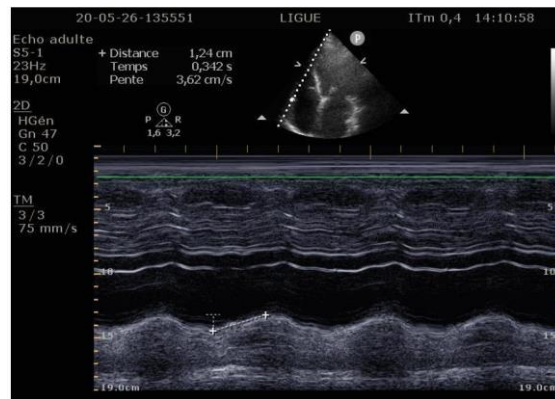


Figure 7: Echocardiographic image showing altered TAPSE in one of our patients

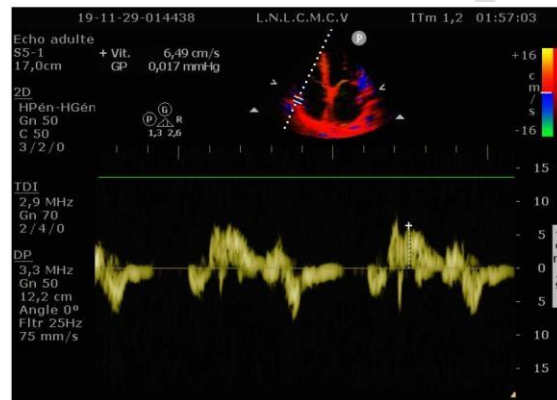


Figure 8: echocardiographic image showing tricuspid S wave alteration on tissue Doppler

5. angiographic profile :

Angiographically, the right coronary artery is the culprit artery in 94% of cases (53% of lesions are located on CD I), which is comparable with the literature [7].

We also report a case of anterior MDI extended to the VD secondary to proximal IVA occlusion, considered in the literature as a rare association [7].

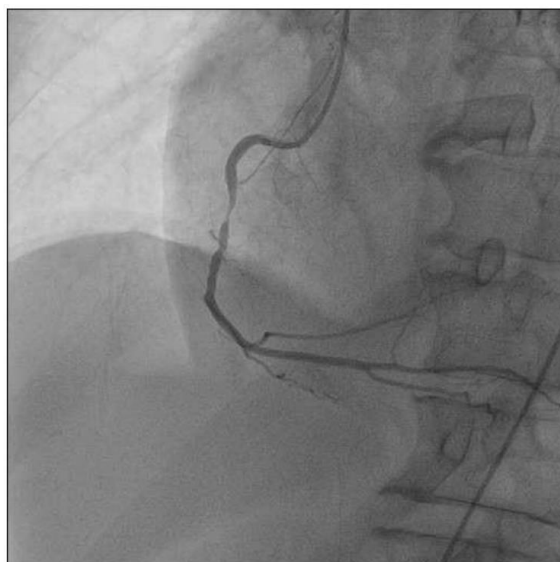


Figure 9: coronary image showing a tight lesion on the right coronary in one of our patients

6. Therapeutic management :

VD infarction is a cause of arterial hypotension related to a sudden drop in right ventricular systolic ejection. Immediate mortality is high in the absence of adequate treatment (filling, deobstruction, etc.).

In our study, 03 patients benefited from vascular filling, which enabled them to correct their hypotension,

In addition to volume expansion, the best treatment for right ventricular infarction is the earliest possible de-clogging of the thrombosed artery, either with drugs (although the rate of re-occlusion is higher) or with instruments (primary angioplasty), In our series, 03 patients underwent thrombolysis and 07 benefited from successful primary angioplasty.

CONCLUSION:

One-third to one-half of patients with inferior MI are complicated by VD MI, ranging from simple, asymptomatic VD dysfunction to severe hypotension, cardiogenic shock and even sudden cardiac death.

Diagnosis of VD MI can be difficult; the 12-lead ECG with recording of additional precordial leads on the right remains the main diagnostic tool in the acute setting, but results can be transient.

The physiology of the VD makes it resistant to infarction, but acute ischemia can have serious hemodynamic consequences. Resuscitation with vascular filling to maintain an adequate preload of the VD remains the first-line treatment. Revascularization, preferably by primary percutaneous intervention, is the cornerstone in the management of VD MI.

Patients who survive the acute phase of MI have an overall favorable long-term prognosis.

ETHICAL APPROVAL

As per international standard or university standard written ethical approval has been collected and preserved by the author(s).

References:

- [1]. Chhapra DA, Mahajan SK, Thorat ST. A study of the clinical profile of right ventricular infarction in context to inferior wall myocardial infarction in a tertiary care centre. *Journal of Cardiovascular Disease Research*. 2013;4(3):170-6.
- [2]. Namana V, Balasubramanian R, Hollander G. A 71-Year-Old Man With Complicated Myocardial Infarction. *JAMA Cardiol*. 2016;1(6):735-6. doi:10.1001/jamacardio.2016.1263
- [3]. Van der Bolt CL, Vermeersch PH, Plokker HW. Isolated acute occlusion of a large right ventricular branch of the right coronary artery following coronary balloon angioplasty. *Eur Heart J*. 1996;17(2):247-250.
- [4]. Carroll R, Sharma N, Butt A, Hussain KM. Unusual electrocardiographic presentation of an isolated right ventricular myocardial infarction secondary to thrombotic occlusion of a non-dominant right coronary artery. *Angiology*. 2003;54(1):119-124.
- [5]. Andersen HR, Falk E, Nielsen D. Right ventricular infarction: frequency, size and topography in coronary heart disease: a prospective study comprising 107 consecutive autopsies from a coronary care unit. *J Am Coll Cardiol* 1987;10:1223.
- [6]. Geft IL, Shah PK, Rodriguez L, et al. ST elevations in leads V1 to V5 may be caused by right coronary artery occlusion and acute right ventricular infarction. *Am J Cardiol*. 1984;53(8):991-6.
- [7]. Ondrus T, Kanovsky J, Novotny T, Andrsova I, Spinar J, Kala P. Right ventricular myocardial infarction: From pathophysiology to prognosis. *Experimental & Clinical Cardiology* 2013;18(1):27-30.
- [8]. Goldstein JA. Pathophysiology and management of right heart ischemia. *J Am Coll Cardiol* 2002;40(5):841-53.
- [9]. L. Cassagnes ,B. Magnin, L. Boyerl « Anatomie des cavités cardiaques », *Journal d'imagerie diagnostique et interventionnelle* 2018;1:360-362
- [10]. Javier Sanz, Damián Sánchez-Quintana, Eduardo Bossone, Harm J. Bogaard, Robert Naeije, « Anatomy, Function, and Dysfunction of the Right Ventricle » ; *JOURNAL OF THE AMERICAN COLLEGE OF CARDIOLOGY* VOL . 73 , NO. 12 , 2019
- [11]. Loukianos S. Rallidis, MD, FESC, Georgios Makavos, MD, and . Petros Nihoyannopoulos, MD, FRCP, FESC, FACC, Athens, Greece; London, United Kingdom
« Right Ventricular Involvement in Coronary Artery Disease: Role of Echocardiography for Diagnosis and Prognosis » . *J Am Soc Echocardiogr* 2014;27:223-9.
- [12]. Isner JM, Roberts WC. «Right ventricular infarction complicating left ventricular infarction secondary to coronary heart disease». *Am J Cardiol* 1978;42:885-894.
- [13]. . Forman MB, Wilson BH, Sheller JR, Kopelman HA, Vaughn WK, Virmani R, et al. Right ventricular hypertrophy is an important determinant of right ventricular infarction complicating acute inferior left ventricular infarction. *J Am Coll Cardiol* 1987;10:1180-7.
- [14]. . Kinch JW, Ryan TJ. Right ventricular infarction. *N Engl J Med* 1994;330: 1211-7.
- [15]. Haddad F, Hunt SA, Rosenthal DN, Murphy DJ. Right ventricular function in cardiovascular disease, part I: anatomy, physiology, aging, and functional assessment of the right ventricle. *Circulation* 2008;117:1436-48
- [16]. Goldstein JA, Vlahakes GJ, Verrier ED et al. «The role of right ventricular systolic dysfunction and elevated intrapericardial pressure in the genesis of low output in experimental right ventricular infarction». *Circulation* 1982; 65: 513.[17]. Tani M. Roles of the right ventricular free wall and ventricular septum in right ventricular performance and influence of the parietal pericardium during right ventricular failure in dogs. *Am J Cardiol* 1983;52:196-202.
- [18]. Goto Y, Yamamoto J, Saito M, Haze K, Sumiyoshi T, Fukami K, Hiramori K: Effects of right ventricular ischemia on left ventricular geometry and the end-diastolic pressure-volume relationship in the dog. *Circulation* 1985;72:1104-14.
- [19]. Ravn H, White P, Moeldrup U, Oldershaw P, Redington A: Acute right ventricular dilatation in response to ischemia significantly impairs left ventricular systolic performance. *Circulation* 1999;100:761-7.
- [20]. Cushing EH, Feil HS, Stanton EJ, et al. Infarction of the cardiac auricles (atria): clinical, pathological, and experimental studies. *Br Heart J* 1942;4:17-34.
- [21]. Lasar EJ, Goldberger JH, Peled H, et al. Atrial infarction: diagnosis and management. *Am Heart J* 1988; 6:1058-63.
- [22]. Haji AS, Movahed A. right ventricular infarction—diagnosis and treatment *Clin. Cardiol* 2000; 23(7):473-82.
- [23]. Turkoglu S, Erden M, Ozdemir M. Isolated right ventricular infarction due to occlusion of the right ventricular branch in the absence of percutaneous coronary intervention. *Can J Cardiol*. 2008;24:793-794
- [24]. . Velam Vanajakshamma¹ Kancherla Vyshnavi² Kasala Latheef¹ Rayi Ramesh³ Kodem Damodara Rao¹ . Right Ventricular Infarction in Inferior Wall Myocardial Infarction . *Indian J Cardiovasc Dis Women-WINCARS* 2017;2:29-34.
- [25]. . S. KHAN, A. KUNDI, S. SHARIEFF . Prevalence of right ventricular myocardial infarction in patients with acute inferior wall myocardial infarction . *National Institute of Cardiovascular Diseases, Karachi, Pakistan* . 2004 Blackwell Publishing Ltd *Int J Clin Pract*, April 2004, 58, 4, 354-357
- [26]. Erice durand « IDM, situation particulière : extension VD- thrombus intra cardiaque- CIV» . 24eme congré du CNCH 22.11.2018
- [27]. . Arif Albulushi, Andreas Giannopoulos, Nikolaos Kafkas, Stylianos Dragasis, Gregory Pavlides & Yiannis S. Chatzizisis (2018): Acute right ventricular myocardial infarction, *Expert Review of Cardiovascular Therapy*,
- [28]. . Namana Vinod, Gupta Sushilkumar Satish, Abbasi Anna A., Raheja Hitesh, Shani Jacob, Hollander Gerald, Right Ventricular Infarction, *Cardiovascular Revascularization Medicine* (2017),
- [29]. Taku Inohara, Shun Kohsaka , Keiichi Fukuda and Venu Menon . The challenges in the management of right ventricular infarction . *European Heart Journal: Acute Cardiovascular Care* 2013 2: 226 originally published online 21 May
- [30]. Dell'Italia LJ, Starling MR, O'Rourke RA. Physical examination for exclusion of hemodynamically important right ventricular infarction. *Ann Intern Med*. 1983;99:608-611
- [31]. Cintron GB, Hernandez E, Linares E, Aranda JM. Bedside recognition, incidence and clinical course of right ventricular infarction. *Am J*

Cardiol. 1981;47:224-227

- [32] S. KHAN, A. KUNDI, S. SHARIEFF « Prevalence of right ventricular myocardial infarction in patients with acute inferior wall myocardial infarction » National Institute of Cardiovascular Diseases, Karachi, Pakistan . 2004 Blackwell Publishing Ltd Int J Clin Pract, April 2004, 58, 4, 354–357
- [33] - Giannitsis E, Potratz J, Schmoecker G et al. «Impact of right ventricular infarction on in-hospital patency after early thrombolysis with an accelerated dose regimen of 100 mg t- PA». American Heart Association. 69th Scientific sessions. New Orleans, November 10-13, 1996.
- [34] Jeremiah L. Jeffers ; Lance J. Parks . « Right ventricular myocardial infarction» .Treasure Island (FL): StatPearls Publishing ; 2020 janv.
- [35]. Wang JJ, Pahlm O, Warren JW, Sapp JL, Horáček BM. Criteria for ECG detection of acute myocardial ischemia: Sensitivity versus specificity. J Electrocardiol. 2018; 51(6): S12-S17.
- [36]. Jia X, Heiberg E, Sejersten Ripa M, Engblom H, Carlsson M, Halvorsen S, Arheden H, Atar D, Clemmensen P, Birnbaum Y. Cardiac magnetic resonance evaluation of the extent of myocardial injury in patients with inferior ST elevation myocardial infarction and concomitant ST depression in leads V1-V3: analysis from the MITOCARE Study. Cardiology. 2018; 140(3): 178-185.
- [37]. Somers MP, Brady WJ, Bateman DC, Mattu A, Perron AD. Additional electrocardiographic leads in the ED chest pain patient: right ventricular and posterior leads. Am J Emerg Med. 2003; 21(7): 563-573.
- [38]. Russi CS, Myers LA, Kolb LJ, Steever K, Nestler DM, Bjerke MC, White RD, Ting HH. Prehospital diagnosis of ST-segment elevation myocardial infarction using an "all- posterior" 12-lead electrocardiogram. Prehosp Emerg Care. 2011; 15(3): 410-413.
- [39]. Carley SD. Beyond the 12 lead: review of the use of additional leads for the early electrocardiographic diagnosis of acute myocardial infarction. Emerg Med (Fremantle). 2003;15(2): 143-154.
- [40]. Manvi R Nagam, MBBS; David R Vinson, MD; Joel T Levis, MD, PhD, FACEP, FAAEM . « ECG Diagnosis: Right Ventricular Myocardial Infarction » . The Permanente Journal/Perm J 2017;21:16-105
- [41]. Somers MP, Brady WJ, Bateman DC, Mattu A, Perron AD. Additional electrocardiographic leads in the ED chest pain patient: right ventricular and posterior leads. Am J Emerg Med 2003 Nov;21(7):563-73. DOI: <http://dx.doi.org/10.1016/j.ajem.2003.08.008>.
- [42]. Geft IL, Schamroth I. «ST elevation in leads V1 to V5 may be caused by right coronary artery occlusion, and acute right ventricular infarction». Am J Cardiol 1984; 53: 421-427.
- [43]. Grollier G, Scanu P, Gofard M et al. «Sus décalage du segment ST dans les dérivations précordiales antérieures et infarctus du ventricule droit». Arch Mal Coeur 1992 ; 85 :67-75.
- [44]. Zehender M, Kasper W, Kauder E, Schonhaler M, Geibel A, Olschewski M, Just H: Right ventricular infarction as an independent predictor of prognosis after acute myocardial infarction. N Engl J Med 1993;328:981–8.
- [45]. Rodrigues EA, Dewhurst NG, Smart LM, Hannan WJ, Muir AL: Diagnosis and prognosis of right ventricular infarction. Br Heart J 1986;56:19–26.
- [46]. Anderson HR, Nielson D, Lung O, Falk E: Prognostic significance of right ventricular infarction diagnosed by ST elevation in right chest leads V3R to V7R. Int J Cardiol 1988;23:349–56.
- [47]. Berger PB, Ryan TJ: Inferior myocardial infarction high-risk subgroups. Circulation 1990;81:401–11.
- [48]. Wellens HJ: Right ventricular infarction. N Engl J Med 1993;328:1036–38.
- [49]. Andersen HR, Nielsen D, Lund O, Falk E. Prognostic significance of right ventricular infarction diagnosed by ST elevation in right chest leads V3R to V7R. Int J Cardiol 1989 Jun;23(3):349-56. DOI: [http://dx.doi.org/10.1016/0167-5273\(89\)90195-2](http://dx.doi.org/10.1016/0167-5273(89)90195-2).
- [50]. Shiraki H, Yokozuka H, Negishi K, et al. Acute impact of right ventricular infarction on early hemodynamic course after inferior myocardial infarction. Circ J 2010 Jan;74(1):148-55. DOI: <http://dx.doi.org/10.1253/circj.cj-09-0405>.
- [51]. Haddad F, Hunt SA, Rosenthal DN, Murphy DJ. Right ventricular function in cardiovascular disease, part I: anatomy, physiology, aging, and functional assessment of the right ventricle. Circulation 2008;117:1436-48.
- [52]. Ho SY, Nihoyannopoulos P. Anatomy, echocardiography, and normal right ventricular dimensions. Heart 2006;92(suppl):2-13.
- [53]. Dell'Italia LJ. The right ventricle: anatomy, physiology, and clinical importance. Curr Probl Cardiol 1991;16:653-720.
- [54]. Shah AR, Grodman R, Salazar MF, Rehman NU, Coppola J, Braff R. Assessment of acute right ventricular dysfunction induced by right coronary artery occlusion using echocardiographic atrioventricular plane displacement. Echocardiography 2000;17:513-9.
- [55]. Jugdutt BI, Sussex BA, Sivaram CA, Rossall RE. Right ventricular infarction: two-dimensional echocardiographic evaluation. Am Heart J 1984; 107:505-18.
- [56]. Lebeau R, Di Lorenzo M, Sauve C. Two-dimensional echocardiography estimation of right ventricular ejection fraction by wall motion score index. Can J Cardiol 2004;20:169-76.
- [57]. Vargas-Barron J, Espinola-Zavaleta N, Romero-Cardenas A, Simon-Ruiz S, Keirns C, Peña-Duque M, et al. Clinical echocardiographic correlation of myocardial infarction with extension to right chambers. Echocardiography 1998;15:171-80.
- [58]. Anavekar NS, Gerson D, Skali H, Kwong RY, Yucel EK, Solomon SD. Two-dimensional assessment of right ventricular function: an echocardiographic- MRI correlative study. Echocardiography 2007;24:452-6.
- [59]. Goldstein JA. Pathophysiology and management of right heart ischemia. J Am Coll Cardiol 2002;40:841-53.
- [60]. Rambihar S, Dokainish H. Right ventricular involvement in patients with coronary artery disease. Curr Opin Cardiol 2010;25:456-63
- [61]. Alam M, Wardell J, Andersson E, Samad BA, Nordlander R. Right ventricular function in patients with first inferior myocardial infarction: assessment by tricuspid annular motion and tricuspid annular velocity. Am Heart J 2000;139:710-5.
- [62]. Ozdemir K, Altunkeser B, Icli A, Ozdil H, Gök H. New parameters in identification of right ventricular myocardial infarction and proximal right coronary artery lesion. Chest 2003;124:219-26.
- [63]. Leibungdutt G, Rohner A, Grize L, Bernheim A, Kessel-Schaefer A, Bremerich J, et al. Dynamic assessment of right ventricular volumes and function by real-time three-dimensional echocardiography: a comparison study with magnetic resonance imaging in 100 adult patients. J Am Soc Echocardiogr 2010;23:116-26.