

Case report

Left atrial Myxoma revealed by a stroke in a young female patient.

Abstracts

Introduction

Cardiac myxoma is a primary benign tumor most often located in the left atrium and it is a rare source of cerebral stroke of young subjects.

Case Presentation

We report the case of a young women with cardiac myxoma revealed by hemiplegia.

The patient suddenly presented vertigo followed by a fall, a heaviness of her left body, and dysarthria.

Brain CT tomography and magnetic resonance imaging revealed cerebral ischemia in the right Sylvian territory. Transthoracic echocardiography revealed a round cardiac mass, mobile, heterogeneous, multilobed, appended to the interatrial septum and the atrial side of the large mitral valve by wide implantation, measuring 38 x 25mm in the parasternal short axis (PSAX) and apical 4 chamber views evocative of left atrium myxoma. After the surgical resection, which was postponed for a month, the removed tumor was sent for histopathological examination. The morphological examination revealed a myxoid tumor proliferation compatible with cardiac myxoma expressing calretinin by these tumor cells in the immunohistochemical study.

Conclusion

Left atrium myxoma is a benign cardiac tumor and a rare cause of ischemic stroke.

Transthoracic echocardiography facilitates the diagnosis of this tumor which will then be confirmed by histological analysis.

Keywords: left atrial myxoma, ischemic stroke, transthoracic echocardiography, cardiac mass tumor, case report.

Introduction

Left atrium myxoma is a rare and benign primary cardiac tumor, its clinical expression consists of a triad including constitutional symptoms, embolization, and intracardiac obstruction.

Ischemic stroke is a rare but possible pattern of the revelation of left atrium myxoma.

Transthoracic echocardiography carried out as part of the initial assessment of an ischemic stroke in the primary imaging examination for diagnosis is performed in young patients. Histological examination confirmed the diagnosis and benign nature of this tumor which can cause serious or deadly manifestations.

We report the case of a young patient with a left atrium myxoma revealed by cerebral embolization.

Case report

We report a case of 46 years old female patient, who had six gravidities and four parities including two miscarriages. The young patient had no cardiovascular risk factors and was referred to us by the neurology department for a cardiovascular evaluation as part of the etiological work-up of an ischemic stroke.

On Monday, October 25, 2021, at around 11 o'clock, the patient suddenly presented with vertigo followed by a fall, heaviness of her left body, and dysarthria. She also reported some chest pain a week prior to her hospitalization and headaches associated with nausea, vomiting, and photophobia a month earlier. Clinically, the patient had left-sided hemiparesis in her left body and was hemodynamically stable without any cardiovascular peculiarities. The electrocardiogram and biological assessment (immunological and thrombophilia tests) were strictly normal.

The brain CT scan and magnetic resonance imaging have revealed cerebral ischemia located in the right Sylvian territory (stenosis of the branches of the right superficial Sylvian artery) with a discreet mass effect without signs of hemorrhagic infarction. Echo-Doppler of the supra-aortic vessels showed good permeability of the carotid arteries.

Transthoracic echocardiography highlighted a round cardiac mass, mobile, heterogeneous, multilobed, appended to the interatrial septum and the atrial side of the large mitral valve by wide implantation and measuring 38x25mm (Figs. 1 and 2) in the parasternal short axis (PSAX) and apical 4 chamber views evocative of left atrium myxoma.

After the surgical resection, which was postponed for a month, the removed tumor was sent for histopathological examination. The morphological examination revealed a myxoid tumor proliferation compatible with cardiac myxoma (Fig. 3) expressing calretinin by these tumor cells in the immunohistochemical study (Figure 4).

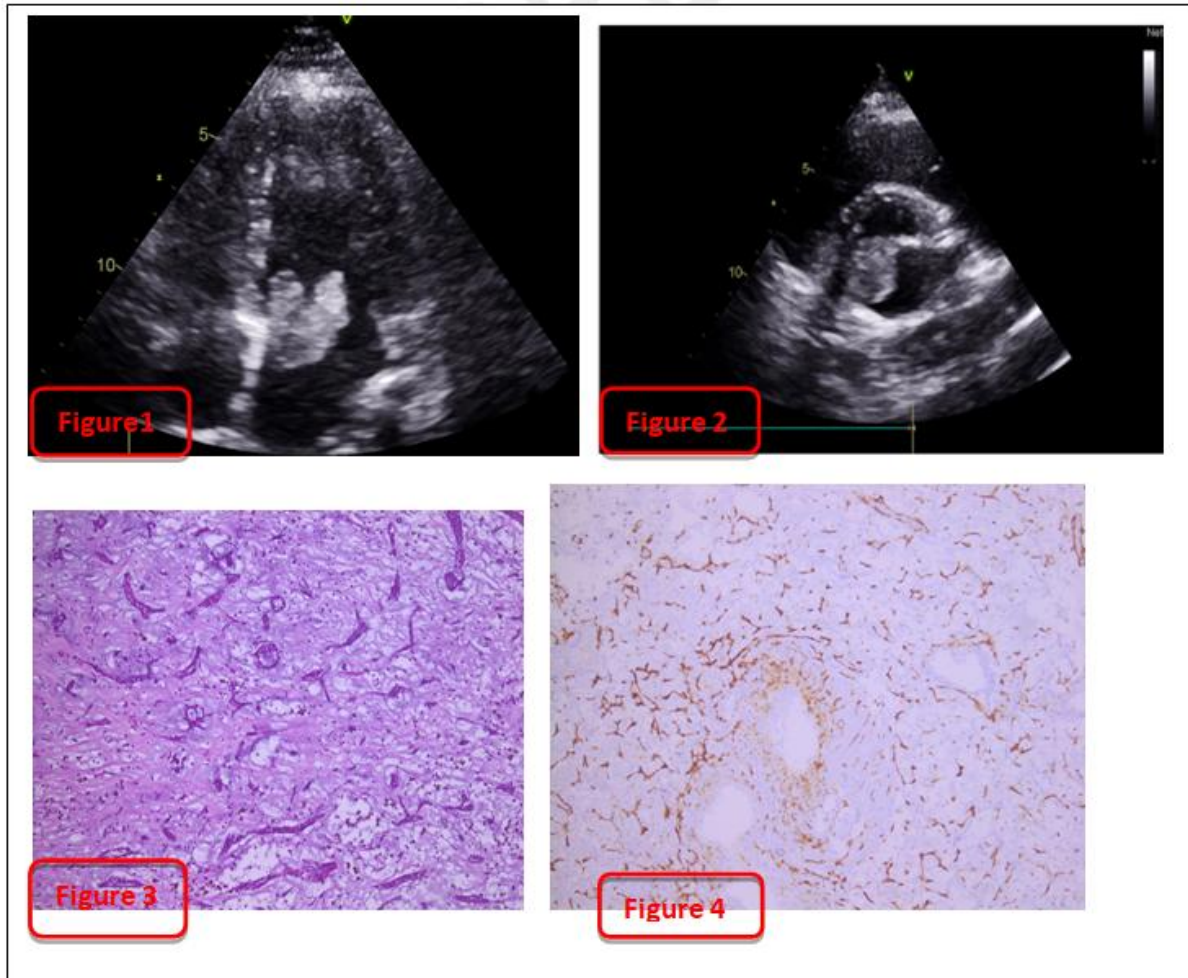


Figure 1: cardiac mass in apical 4 chamber view.

Figure 2: cardiac mass in parasternal short axis view.

Figure 3: morphological aspect of a tumor proliferation arranged in spans and nests within an abundant myxoid.

Figure 4: Immunohistochemistry, expression of calretinin by tumor cells.

Discussion

Myxoma is a rare primary cardiac tumor frequently localized in the left atrium appended to the inter-atrial septum, the right atrial localization represents 15–25% [2, 7, 12].

It occurs more predominantly in women than in men, with a sex ratio of 2-3 women to 1 man. The annual incidence is estimated at 0.5/1 million people, with a peak occurring in young adults aged 30-60 years [3, 4, 10]. It represents 21.5–80% of all cardiac tumors, and 75% of these tumors are located in the left atrium (LA) [1–4]. We report the case of a 46-year-old woman with no family history, which is consistent with the data in the literature. The sporadic form is mostly predominant. In about 7% of cases, we can observe familial forms with an autosomal dominant

transmission, the typical example is the Carney complex associating cutaneous and cardiac myxoma, skin lesions, endocrinopathies, and non-myxomatous extracardiac tumors [1, 11, 12].

The clinical presentation of left atrium myxomas varies depending on its location, size, and mobility [3,11, 21]. Thus, non-specific systemic symptoms such as asthenia, myalgia, arthralgia, fever, and weight loss; due to the expression of interleukin 6 by myxoma may be the first revelations of this cardiac tumor [1, 3, 5]. These constitutional, general symptoms can err the diagnosis and lead to a delay in diagnosis or the revelation of the disease by a more serious manifestation such as cerebral embolic events or elsewhere in the vascular tree [16, 21, 27]. These embolic incidents are found in 30 to 40% of cases and were the revealing mode in the first description of the left atrium myxoma described by Goldberg et al in a hemiparesis patient, similar to our patient [1, 16, 17]. These accidents are caused by the embolization of a myxomatous aneurysm, a friable tumor fragment, or an adherent thrombus, which explains why anticoagulation not only protects from these embolization incidents but also decreases the risk of

dementia by progressive infarction or death by massive embolism in addition to neurological functional sequelae [1, 4, 19]. Ischemic strokes associated with myxoma of the left atrium have been described even in the pediatric population but represent only 0.5% of all strokes. The third group of symptoms that make up the triad is related to the obstruction of the mitral valve by myxoma, which leads to dyspnea, dizziness, or even syncope or sudden death [2, 3, 4, 23].

Transthoracic echocardiography (TTE) is the non-invasive imaging modality of choice, to be performed in patients with a stroke in order to eliminate the cardioembolic origin [1, 8, 13, 37]. In the case of a myxoma, TTE shows an inhomogeneous mass, pediculated, appended to the interatrial septum, and usually located in the left atrium [4, 5, 13, 17]. This was the TTE finding of our young patient in whom a TTE was performed as part of the etiological assessment of her ischemic stroke. TTE may show no signs in 36% of cases and transesophageal echocardiography is a good option for a better and more accurate description of the tumor, its location, and attachment with a sensitivity close to 100% [6, 15]. MRI and/or cardiac CT scan can help in the tissue characterization of the mass, its exact location, and cardiac anatomy and therefore valuable support for the surgical approach [1, 4].

Once diagnosed, management of cardiac myxoma should be early and complete to avoid serious complications such as an ischemic stroke, amnesia, myocardial infarction, syncope, sudden death, and possible fatal relapse [8, 19]. Surgery is the treatment of choice for the complete removal of the tumor [14,18].

Histological analysis of the removed tumor is the gold standard to confirm the diagnosis by highlighting a myxoid proliferation of cells expressing calretinin in immunohistochemistry. Cardiac myxoma is a histologically benign tumor resulting from the proliferation of multipotent mesenchymal cells of the oval fossa [9, 23, 37], it presents a risk of recurrence of 1 to 5% after inadequate surgical excision. Recurrence occurs for poorly differentiated active myxomas [3, 4].

Conclusion

Left atrium myxoma is a benign cardiac tumor and a rare cause of ischemic stroke, present especially in young women. Transthoracic echocardiography, the first-line examination to be carried out in the etiological investigation of strokes in young patients, facilitates the diagnosis of this tumor which will then be confirmed by histological analysis.

Declarations

Ethics Approval

As per international and university standards, ethical approval has been collected and preserved by the author(s).

Consent for Publication

Written informed consent was obtained from the patient for publication of this case report and accompanying images. A copy of the written consent is available for review by the Editor-in-Chief of this journal on request.

Availability of Data and Material

All materials used are listed in the manuscript.

References

1. Fintan O'Rourke, Dean N, et al. Atrial myxoma as a cause of stroke: case report and discussion. *Can Med Assoc J.* 2003;169(10):1049–51.
2. Schiele, et al; Left Atrial Myxoma When Big Is Too Big *Circ Cardiovasc Imaging.* 2019;12:e008820.
3. Tzani A, Doulamis IP, Mylonas KS, Avgerinos DV, Nasioudis D. Cardiac tumors in pediatric patients: a systematic review. *World J Pediatr Congenit Heart Surg.* 2017;8(5):624–32.
4. Uzun O, Wilson DG, Vujanic GM, Parsons JM, De Giovanni JV. Cardiac tumours in children. *Orphanet J Rare Dis.* 2007;2:11.
5. Singh, et al. Large Left Atrium Myxoma Presenting as 'Positional Pre-Syncope'. *Clin Med Img Lib.*2021;7:164.
6. Yuan SM, Humuruola G. Stroke of a cardiac myxoma origin. *Braz J Cardiovasc Surg.* 2015;30(2):225–34.
7. Stefanou, et al. Cardiac Myxoma and Cerebrovascular Events: A retrospective Cohort Study. *Front Neurol.* 2018;9:823.
8. Lalla, et al. Atrial myxoma presenting as a non-ST-segment elevation myocardial infarction. *International Medical Case Reports Journal* 2019;12 179–183.
9. Scalise M, et al. Atrial myxomas arise from multipotent cardiac stem cells. *Eur Heart J.* 2020;41(45):4332–45.
10. Ekici B, et al. Recurrent left atrial myxoma: A case report. *Eastern J Med.* 2013;18:214–16.
11. Souaga ka, et al. Right atrial Myxoma revealed by pseudo syncope: opereted case. *Rev int sc méd.* 2011;13(1):49–51.
12. David H. Hsi, et al. A giant right atrial myxoma-The growth rate and multi-modality imaging Echocardiography. 2021;38(6):1057–60.
13. Xiang, Ji. Left atrial myxoma with left ventricular myxoma diagnosed by ultrasound examination A case report. *Medicine.* 2021;100(32):e26903.
14. Lin, et al. Treating cardiac myxomas: a 16-year Chinese single-center study. *Journal of Cardiovascular Medicine.*2016.17(1):44–53.

15. Kallstrom, et al. Differentiation of Left Atrial Myxomas by Multimodality Imaging. *J Diagn Med Sonography*. 2020;36(1):52–63.
16. Rolando E. Rios, et al. Complications of atrial myxoma. *Am J Emerg Med*. 2016; 34(12):2465.e1- 2465.e2.
17. Phillip, Tran, et al. A Rare Case of left Atrial Myxoma With Coronary Fistula In A Patient With Dyspnea On Exertion. *JACC*. 2021; 77(18) :p. 3012.
18. Sadegh, Shabab, et al. A case report of left atrial myxoma presenting with amnesia. *BMC Cardiovasc Disord*. 2021;21(1):225.
19. Ahmad Al-Fakhouri. Acute myocardial infarction caused by left atrial myxoma: Role of intracoronary catheter aspiration. *Rev Port Cardiol*. 2017;36(1):63. .e1-63.e5.
20. Bassil Khalil Al-Zamkan. et al. An exceptionally giant left atrial myxoma: a case report and literature review. *Eur Heart J- Case Rep*. 2020;4(6):1–7.
21. Zizi O, et al. Intracardiac myxoma complicated by acute aortic occlusion (case report). *Ann de Cardiol Angeiol*. 2017;66(2):116–18.
22. Zhang Y, Ye Z, Fu Y, et al. Characterizations of Ischemic Stroke Complications in Cardiac Myxoma Patients at a Single Institution in Eastern China. *Neuropsychiatr Dis Treat*. 2021;17:3340.
23. Muthiah R. (2016) Left Atrial Myxoma-A Case Report. *Case Reports in Clinical Medicin*. 2016; 5(1): 6–10.
24. Iyer P, Aung MM, Awan MU, Kososky C, Barn K. A case of large atrial myxoma presenting as an acute stroke. *J Community Hosp Intern Med Perspect*. 2016;6(1):29604.
25. Juaneda I, Peirone A. el. A Rare Cause of Pediatric Stroke: Left Atrial Myxoma. *World J Pediatr Congenital Heart Surg*. 2016;8(2):220–23.
26. Bui Q, Tran S, Pham S, Phan V, Nguyen K, Mai N, et al. Acute ischemic stroke on the setting of left atrial myxoma: optimal time for cardiac surgery. *Case Rep Intern Med*. 2021;8(2):1.
27. Shrestha S, et al. Atrial myxoma with cerebellar signs: a case report. *J Med Case Rep*. 2020;14(1):29.
28. Tona C, Nosadini M, Pelizza MF, Pin JN, Baggio L, Boniver C, et al. Cardiac Myxoma as a Rare Cause of Pediatric Arterial Ischemic Stroke: Case Report and Literature Review. *Neuropediatrics*. 2020;51(06):38996.
29. Sohal RS, Shergill KK, et al. Atrial Myxoma – An unusual cause of ischemic stroke in young. *Autops Case Rep (São Paulo)*. 2020 Oct-Dec;10(4):e2020178.
30. Kesav P, John S, Joshi P, Gaba WH, Hussain SI. Cardiac Myxoma Embolization Causing Ischemic Stroke and Multiple Partially Thrombosed Cerebral Aneurysms. *Stroke*. 2021;52(1):e10–4.
31. Kumar, Harish, et al. Cardiac myxoma: An uncommon cause of recurrent stroke in uncommon age. 2015; 2(1):137–9.
32. Kumar D, et al. “Left atrial myxoma-A tumor in transit”. *Ann Card Anaesth*. 2019;22(4):432–34.

33. Silva Júnior ML, et al. Giant atrial myxoma leading to stroke. *Med J Aust.* 2021;215(6):258–8.e1.
34. Ise H, Ishikawa N, Nakanishi S, Kamiya H. Giant left atrial myxoma causing acute ischemic stroke in a child. *Surgical Case Reports.* 12 janv 2018;4(1):6.
35. Jessica Weiss DO, et al. Hemorrhagic atrial myxoma causing a cardioembolic stroke: a case report. *J Neurol Stroke.* 2015;2(1):00042.
36. Khedher S, Mokni N, Dossary HMA. Intravenous thrombolysis in a patient with cardio embolic stroke with left atrial myxoma and positive COVID19. *Atherosclerosis* 1 août. 2021;331:e262.
37. Majdoub A, Adamou Nouhou K, Daouda A, Messouak M. Cardiac myxomas: about 18 operated cases. *JCTCV.*2017; 21(3).
38. Tarun Teja B, et al. Stroke Due to Left Atrial Myxoma. *J Case Rep.* 2017;7(1):858.

UNDER PEER REVIEW