

Original Research Article

Demographic and Clinical Profile of Adult Patients with Closed Diaphyseal Femoral Fracture

Abstract

Background: Diaphyseal femur fractures are typically caused by high-speed trauma. Treating these adult fractures involves options such as traction, bracing, plating, intramedullary nails, external fixation, and interlocking nails. Understanding patient demographics and clinical conditions is essential for effective fracture management. **Aim of the study:** This study aimed to create a clinical profile of adult patients with closed diaphyseal femoral fractures. **Methods:** This quasi-experimental study was conducted at the Dhaka Medical College Hospital, Dhaka, Bangladesh from July 2017 to June 2019. The study focused on 38 adult patients who had suffered closed femur shaft fractures and were treated with closed-reamed interlocking nailing, selected through purposive sampling. Data analysis and dissemination were carried out utilizing Microsoft Office tools. **Results:** The mean \pm SD age of the respondents was 32.84 \pm 13.94 years, 73.68% were male, and the majority of the cases (78.9%) had injuries due to Road Traffic Accidents (RTAs). Falls from height were the cause of 15.8% of the cases and the majority of patients (63.2%) experienced injuries on the right side. Transverse fractures were the most common pattern of fracture, accounting for 63.1% of cases, followed by spiral fractures (21.1%) and oblique (15.8%) of the cases. **Conclusion:** Closed diaphyseal femoral fractures are predominantly seen in young adult males in their early thirties. Road Traffic Accidents (RTAs) stand out as the primary cause of these fractures, with the right side of the body being particularly susceptible. Among the various fracture patterns observed, transverse fractures emerge as the most common in this patient group. **Keywords:** Adult patients, Demographic, Clinical profile, Closed diaphyseal femoral fracture

INTRODUCTION

Fractures of the femur shaft are a common occurrence, accounting for an estimated 5-10% of all fractures. In most cases, these fractures result from high-energy trauma, often accompanied by severe injuries to other parts of the body [1]. These femur shaft fractures are a significant contributor to morbidity and mortality, particularly in patients with lower extremity injuries. They are frequently seen in young adults involved in high-velocity incidents, such as road traffic accidents, gunshot injuries, or falls from heights [2,3]. With the ongoing trends of industrialization and urbanization and the associated increase in traffic, the incidence of high-energy trauma is rising rapidly. Survival after the initial trauma does not guarantee a full recovery, as disability often results from femoral shortening, fracture malalignment, or prolonged immobilization using traction or casting to maintain fracture length and alignment during early healing. Leg shortening and malalignment can lead to a limp and post-traumatic arthritis [2,3]. Treatment options for femoral shaft fractures vary and include traction alone, traction followed by a standard cast brace, external fixation, or open reduction and internal fixation. Internal fixation methods encompass intramedullary nailing and plate and screw fixation. The choice of treatment method depends on factors like fracture type and location, degree of comminution, patient age, and socioeconomic status [1]. Early rehabilitation, including muscle strengthening and joint range-of-motion exercises, is possible, and if there is good bone contact, early weight-bearing can be permitted [4]. The effectiveness of different treatment modalities can be assessed in terms of knee function, total hospitalization duration, bone union, and the presence or absence of complications [1]. In a study by Arun KV et al. (2015) [5] on femur shaft fractures, 28 males and 12 females were included, with a male preponderance. Road traffic accidents (RTAs) were the most common mode of injury, accounting for 75% of cases, followed by falls from height (25%). Transverse fracture patterns were predominant (60%), with an average blood loss of around 350 ml. Reaming was performed in all cases, and the entry point was the piriformis fossa in all 40 patients. There were no cases of non-union or infection. Qureshi et al. (2012) [3] reported a study with 21 males and 4 females, resulting in a male-to-female ratio of 5.25:1. The age range of the patients was 20 to 50 years, with a mean age of 31.2 years. Deepak KM et al. (2012) [6] emphasized that closed intramedullary interlocking nailing has become the preferred treatment for closed diaphyseal femur fractures in adults, especially those with high comminution, long spiral, and segmental fractures. Vécsei V et al. (2011) [4] highlighted the evolution of intramedullary nailing as the standard treatment for long-bone diaphyseal and selected metaphyseal fractures. This approach offers substantial stability while minimizing disruption to soft tissues. Importantly, it preserves the muscular envelope surrounding the fracture, maintaining the vital extra-osseous blood supply to the bone. Consequently, intramedullary nailing enhances bone revascularization and stimulates the formation of periosteal callus. In contrast to screws and plates, intramedullary stabilization offers the advantage of "load-sharing," reducing the need for additional support such as casting. This method also allows for early rehabilitation, including muscle strengthening and joint range-of-motion exercises, and, if there is good bone contact, even

permits early weight-bearing. Kimmatkar N et al. (2014) [7] emphasized that the choice between open or closed femoral intramedullary nailing should be determined by several factors. These factors include the type of fracture and its specific pattern of injury, the availability of appropriate equipment and instruments, and, critically, the level of experience and expertise of the surgeon involved in the procedure. Olasinde AA et al. (2011) [8] concluded that the SIGN nailing technique has proven to be a valuable addition to their orthopedic toolkit in hospitals. This method is appreciated for its ease of use and demonstrates a fracture union rate similar to other interlocking nailing methods. Moreover, it offers the advantage of being cost-effective, as it does not require the mandatory use of an image intensifier. The objective of this current study was to create a clinical profile of adult patients with closed diaphyseal femoral fractures.

. METHODOLOGY

A quasi-experimental study was conducted at the Department of Orthopaedics and Traumatology, Dhaka Medical College Hospital, Bangladesh, spanning from July 2017 to June 2019. The primary focus of this study was on 38 adult patients who had suffered closed femur shaft fractures, and they were selected through purposive sampling. These patients underwent treatment using the closed-reamed interlocking nailing method. Ethical considerations were paramount in this study, and it received approval from the hospital's ethical committee. Furthermore, written consent was diligently obtained from all participants before any data collection procedures commenced. The study strictly adhered to ethical guidelines as outlined in the Helsinki Declaration [9], and it was conducted in compliance with relevant regulations, including those outlined in the General Data Protection Regulation (GDPR) [10]. The eligibility criteria for participants included individuals aged between 18 to 65 years, who were admitted within 24 hours of sustaining their injury and presented with specific closed simple femur shaft fractures. Exclusion criteria encompassed cases of open fractures, fractured neck of femur, pregnancy, individuals aged below 18 or above 65, pathological fractures, comminuted or segmental fractures, communication barriers, or a lack of interest in participating. Data collection was meticulously executed through the use of a pre-structured questionnaire, which covered historical, clinical, and laboratory data. Additionally, pre-operative and post-operative assessments, along with records of any complications, were included in the data collection process. The subsequent data analysis and reporting were performed utilizing Microsoft Office tools.

RESULT

In this study, the largest groups of participants were those aged 20 and below, as well as those in the 21-30 age bracket, both accounting for 26.3% of the total respondents. The 31-40 age group constituted 21.1%, while respondents aged 41-50 comprised 10.5% of the sample. The overall mean age of the respondents was 32.84 years, with a standard deviation of 13.94, indicating a considerable spread in age within the study population. Out of the total of 38 patients, 28 (73.68%) were male, while 10 (26.32%) were female, resulting in a male-to-female ratio of 2.8:1. The largest group was comprised of businessmen, constituting 36.84% of the sample, indicating a substantial representation from this occupational category. Service holders accounted for 15.79% of the patients, while homemakers constituted 21.05%. Day laborers formed the remaining 26.32%, making up a significant portion of the study participants. In the study, 30 patients (78.9%) had experienced injuries due to Road Traffic Accidents (RTAs). Falls from height were the cause of injury in 6 patients (15.8%), while 2 patients (5.3%) reported injuries resulting from the fall of heavy objects. The majority of patients (63.2%) experienced injuries on the right side, while 36.8% of patients had injuries on the left side. A majority of patients, 22 (57.9%), underwent surgery more than 7 days after admission, while 16 (42.1%) patients were operated on within 5-7 days of their trauma. The findings regarding the distribution of the study patients (n=38) by the pattern of fracture revealed distinct categories. Transverse fractures were the most common, accounting for 63.1% of cases, followed by spiral fractures, which comprised 21.1% of the sample. Oblique fractures constituted 15.8% of the cases.

Table 1: Respondent age distribution (N=38)

Age (Year)	n	%
≤ 20	10	26.3
21-30	10	26.3
31-40	8	21.1
41-50	4	10.5
≥ 51	6	15.8
Total	38	100
Mean ±SD	32.84±13.94	

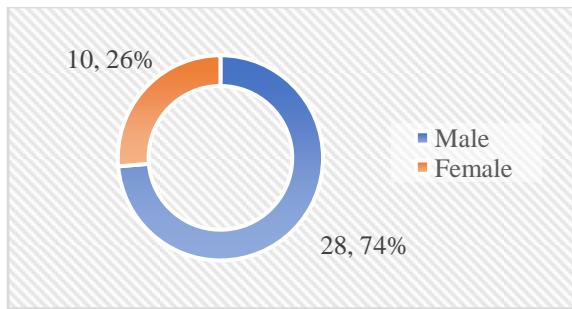


Figure 1: Gender distribution of patients (N=38)

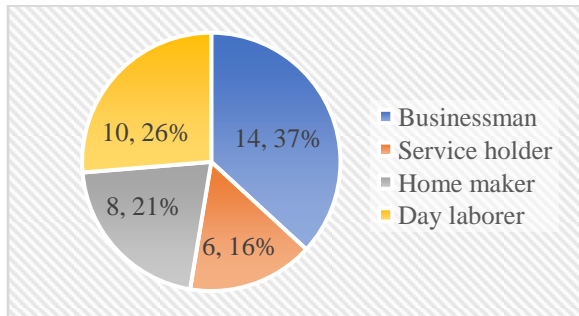


Figure 2: Occupational status of patients (N=38)

Table 2: Patient mode of injury (N=38)

Mode of injury	n	%
RTA	30	78.9
Fall from height	6	15.8
Fall of a heavy object	2	5.3
Total	38	100

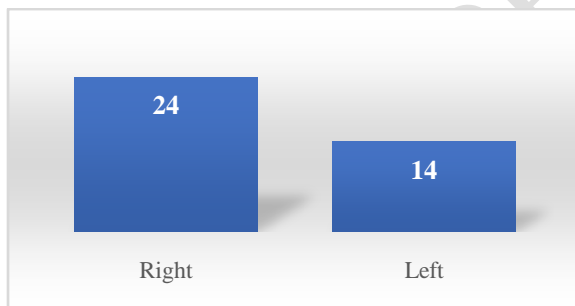


Figure 3: Side of injury distribution (N=38)

Table 3: Patient admission-to-surgery interval (N=38)

Days	n	%
5-7	16	42.1
>7	22	57.9
Total	38	100
Mean \pm SD	8.1 \pm 2.32	

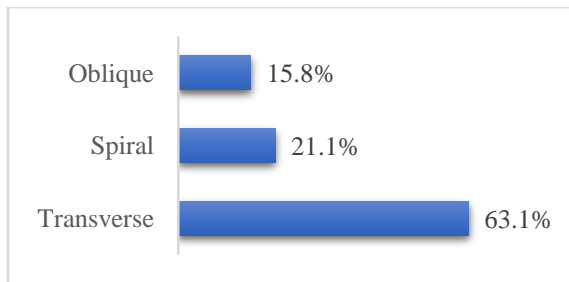


Figure 4: Patient fracture patterns (N=38)

DISCUSSION

This quasi-experimental study took place at the Department of Orthopaedics, Dhaka Medical College Hospital, Dhaka, from July 2017 to June 2019. It involved a cohort of 38 patients who exhibited clinical and radiological indications of closed femur shaft fractures and were admitted to the hospital for surgical intervention. This study aimed to create a clinical profile of adult patients with closed diaphyseal femoral fractures. We observed that the majority of patients (26.3%) fell within the second decade of life, with an equal proportion (26.3%) in the third decade and a substantial portion (21.1%) in the fourth decade. The mean age of our patient group was 32.84 ± 13.94 years. Comparable to our findings, Tiwari et al. (2019) [11] noted that a significant number of patients (53.5%) were in their second decade of life, followed by 17.1% in the third decade, with a mean age of 29.7 ± 11.21 years. Additionally, we found that males comprised the majority in our study, with a male-to-female ratio of 2.8:1. This aligns with the observations of Tiwari et al. (2019) [11] who reported a male predominance of 85.3%, and Deepak et al. (2019) [12] who noted 75% male predominance in their study. This male predominance is consistent with previous research findings, including a study by Bhandari et al. (2000) [13], which reported a gender ratio of 6.69:1. Interestingly, our study found a slightly higher male-to-female ratio compared to some Indian studies, such as Arun et al. (2015) [5] with a ratio of 2.33:1. This skewed gender ratio across studies may be attributed to the higher likelihood of males engaging in activities leading to femoral shaft fractures. Furthermore, our study indicated that most cases occurred in young males aged 18 to 40 years, representing 63.2% of the total. These individuals tend to lead active lives and are often affected by road traffic accidents (78.9%) or falls from heights (15.8%). As previously mentioned, Road Traffic Accidents (RTAs) were responsible for a significant proportion of femoral shaft fractures, consistent with findings from Mohammad et al. (2015) [14], Tiwari et al. (2019) [11], and Metsemakers et al. (2015) [15]. This pattern suggests that femoral shaft fractures frequently result from high-energy trauma and are often associated with other injuries. Regarding occupation, our study revealed that businessmen constituted the largest group (36.84%), followed by laborers (26.32%), housewives (21.05%), and service holders (15.79%). These results are comparable to the study by Jan et al. (2018), which reported 25% housewives, 10% laborers, and 35% service holders. In terms of the side of injury, we observed a predominance of right-sided fractures compared to the left side (63.2% vs. 36.8%). This finding is in line with Tiwari et al. (2019) [11], who reported 61.1% right-sided femoral shaft fractures and 38.9% on the left side. Additionally, Deepak et al. (2019) [12] noted a slightly higher involvement of the right side (55%) compared to the left side. Our study also assessed the interval between injury and surgery, revealing that 42.1% of patients underwent surgery within 7 days of injury, while 57.9% waited for more than 7 days before surgery, with an average interval of 8.1 days. In comparison, Tiwari et al. (2019) [11] demonstrated that 17.1% of patients received surgery within 24 hours, 39.1% within 1-3 days, 39.1% within 4-6 days, and 4.9% had to wait for more than 6 days, with an average interval of 3.7 days. Lastly, our study analyzed fracture patterns, with transverse fractures being the most prevalent (63.1%), followed by spiral fractures (21.1%), and oblique fractures (15.8%). This distribution aligns with the findings of Tiwari et al. (2019), who reported that the majority of fractures (51.2%) were transverse, followed by spiral and comminuted fractures (17.1%), and oblique fractures (14.6%). Deepak et al. (2012) [6] also noted that the most common pattern of fracture was comminuted and transverse fractures.

Limitation of the study:

This study has notable limitations. It was confined to a single medical center, and conducted within a limited period, which may limit its generalizability. The small sample size and short follow-up duration could hinder the formation of strong conclusions. Furthermore, the absence of C-Arm equipment for several months impacted the quality of radiographic data. Lastly, difficulties in patient follow-up presented challenges in data collection.

CONCLUSION & RECOMMENDATION

Closed diaphyseal femoral fractures tend to affect primarily young adult males, typically in their early thirties. This demographic group appears to be particularly prone to these fractures. The leading cause behind

such fractures is Road Traffic Accidents (RTAs), underscoring the importance of road safety measures to prevent these injuries. Furthermore, there is a noticeable vulnerability on the right side of the body, possibly related to the mechanics of accidents. Among the diverse fracture patterns observed in this patient cohort, transverse fractures stand out as the prevailing type. These findings collectively highlight the demographic and clinical characteristics of individuals affected by closed diaphyseal femoral fractures, shedding light on the specific factors contributing to this orthopedic condition.

References

- [1] Dim, E.M., Ugwoegbulem, O.A. and Ugbeye, M.E., 2012. Adult Traumatic Femoral Shaft Fractures: A review of the literature. *Ibom Med J*, 5, pp.26-38.
- [2] Shafi, M.K., Ahmed, N., Khan, A.H. and Aziz, A., 2008. Results of fracture union in closed reamed interlocking nail in fractures of the femur. *Pak J Med Sci*, 24(5), pp.698- 701.
- [3] Qureshi, Z.Z.A., Shah, S.W.A., Kumar, J. And Yousaf, M., 2012. Management of diaphyseal femur fractures in adults with intramedullary interlocking nail. *Biomedica*, 28(2), pp.117-120.
- [4] Vécsei, V., Hajdu, S. and Negrin, L.L., 2011. Intramedullary nailing in fracture treatment: history, science and Küntscher's revolutionary influence in Vienna, Austria. *Injury*, 42, pp. S1-S5.
- [5] Arun KV, Gopala KT, Biju R, et al. Study of outcome of closed interlocking intramedullary nailing of fracture shaft of femur in adults. *IOSR-JDMS*.2015 Dec 14;3:48-52.
- [6] Deepak, M.K., Jain, K., Rajamanya, K.A., Gandhi, P.R., Rupakumar, C.S. and Ravishankar, R., 2012. Functional outcome of diaphyseal fractures of femur managed by closed intramedullary interlocking nailing in adults. *Annals of African medicine*, 11(1), pp.52-57.
- [7] Kimmatkar, N., Hemnani, J.T., Hemnani, T.J. and Jain, S.K., 2014. Diaphyseal Femoral Intramedullary Nailing: Closed or Open Intervention? choice (Figures 1 & 2), 30, p.38.
- [8] Olasinde, A.A., Oluwadiya, K.S., Olakulehin, O.A. and Adetan, O., 2011. Locked intramedullary nailing of femur and tibial in a semi-urban area. *Niger J Orthop Trauma*, 10, pp.89-91.
- [9] World Medical Association . (2001). World Medical Association Declaration of Helsinki . Ethical principles for medical research involving human subjects . *Bulletin of the World Health Organization* , 79 (4), 373 - 374. World Health Organization. <https://apps.who.int/iris/handle/10665/268312>.
- [10] Voigt, Paul, and Axel von dem Bussche. "Enforcement and fines under the GDPR." *The EU General Data Protection Regulation (GDPR)*. Springer, Cham, 2017. 201-217.
- [11] Tiwari A, Kohli SS, Kokne M, 2019. Study of management of diaphyseal fracture shaft femur by intramedullary interlocking nail. *Int J Res Orthop*, 5, pp. 588-93.
- [12] Deepak, C.D., Chethan, B.A., 2019. A study of functional outcome of femoral diaphyseal fractures by closed reduction and internal fixation using intramedullary interlocking nail in adults. *International Journal of Orthopaedics Sciences*, 5(1): pp. 132-138.
- [13] Bhandari, M., Guyatt, G.H., Tong, D., Adili, A. and Shaughnessy, S.G., 2000. Reamed versus nonreamed intramedullary nailing of lower extremity long bone fractures: a systematic overview and meta-analysis. *Journal of orthopaedic trauma*, 14(1), pp.2-9.
- [14] Mohammad, T., Sawati, A., Ahmed, A., Awan, A.S. and Siddique, S., 2015. Outcomes in closed reamed interlocking nail in fractures of shaft of femur. *Journal of Ayub Medical College Abbottabad*, 27(4), pp.811-816.
- [15] Metsemakers, W.J., Roels, N., Belmans, A., Reynders, P. and Nijs, S., 2015. Risk factors for nonunion after intramedullary nailing of femoral shaft fractures: remaining controversies. *Injury*, 46(8), pp.1601-1607.