Ventricular tachycardia revealing an Anderson– Fabry disease: a rare case report

Abstract :

Anderson-Fabry disease ranks as the second most common lysosomal storage disorder. It is a hereditary and rare metabolic condition resulting from a mutation in the GLA gene, responsible for encoding the lysosomal enzyme alpha-galactosidase A. This condition impacts multiple organs in the body, leading to symptoms like cerebrovascular and cardiac problems, chronic renal failure, skin lesions, peripheral neuropathy, and various other abnormalities. While the cardiac manifestations of Fabry disease are well-documented in the medical literature, occurrences where cardiac symptoms are the initial and sole clinical sign of Fabry disease are relatively infrequent. This case report highlights one such unusual situation in which persistent ventricular tachycardia serves as the first and exclusive indication of cardiac involvement in Fabry disease.

Keywords: Fabry disease, Hypertrophic cardiomyopathy, Ventricular tachycardia, Alpha-galactosidase A, Metabolic disease

Introduction:

Anderson-Fabry disease, an X-linked genetic disorder, arises from a deficiency in the enzyme alpha-galactosidase A. This condition is marked by the gradual buildup of globotriaosylceramide (Gb3) in various organs, resulting in a broad spectrum of progressive signs and symptoms. "Typical manifestations and affected organs encompass acral pain crises, cornea verticillata, hypertrophic cardiomyopathy, stroke, and chronic kidney disease accompanied by proteinuria. Nevertheless, in certain instances, organ damage may be absent or symptoms limited, with some common symptoms such as gastrointestinal or ear involvement potentially going unnoticed" [13].

"In classical Fabry disease, symptoms typically emerge during childhood or adolescence in males and may present later in females. Some patients may also exhibit non-classical or late-onset Fabry disease, which features delayed symptoms or impacts a single organ. Recognizing Fabry disease is crucial due to the availability of treatments, despite the diagnostic challenges it poses" [13]. In this case report, we describe an unusual cardiac manifestation of Fabry disease.

Case presentation:

A 42-year-old man with no prior medical history or regular medications , presented with sudden episodes of shortness of breath at rest and a general feeling of unwellness over the past four

UNDER PEER REVIEW

months. He reported no instances of chest pain in any situation. During the physical examination, his pulse was regular, and his blood pressure reading was 150/70 mmHg. Oxygen saturation was 100%, and lung sounds were normal upon auscultation. There were no signs of peripheral edema. An initial 12-lead electrocardiogram (ECG) revealed sinus rhythm at a rate of 75 beats per minute. Notably, there was concave ST-segment elevation in leads V1 and V2, and T-waves exhibited biphasic changes in lead III. The precordial leads indicated left ventricular hypertrophy (LVH) according to the Sokolow-Lyon criteria. Due to these findings, the decision was made to urgently transfer him to a hospital with suspicion of acute coronary syndrome without ST-segment elevation. While awaiting transportation, the patient experienced an acute onset of dyspnea along with non-specific chest discomfort. A repeat ECG revealed ventricular tachycardia, which progressed to ventricular fibrillation. Fortunately, the patient was successfully defibrillated. Upon arrival at the hospital, coronary angiography was performed, revealing unobstructed coronary arteries. Transthoracic echocardiography demonstrated concentric left ventricular hypertrophy (LVH) and normal systolic function, along with severe diastolic dysfunction. Magnetic resonance imaging (MRI) confirmed the presence of LVH and did not show any late gadolinium enhancement. Biochemical tests indicated acute-on-chronic kidney failure (creatinine level at 35 g/L, GFR of 17 ml/min), while all other biochemical parameters were within the normal range.

The patient remained in the coronary care unit for 72 hours and was subsequently transferred to a monitored bed on the standard cardiology ward. He did not experience any further episodes of ventricular tachycardia during his hospital stay. Treatment included bisoprolol at a dose of 2.5 mg per day, ramipril at a dose of 2.5 mg per day, and enzyme replacement therapy (ERT). The need for implantable cardioverter-defibrillator (ICD) therapy was discussed and subsequently implanted. In the list of potential differential diagnoses, Fabry disease was considered as a possible cause of concentric ventricular hypertrophy, despite the absence of classical pain symptoms (such as acroparesthesia and abdominal pain) or specific signs like skin changes (angiokeratomas in lower abdomen, groin, gluteal regions, and anhidrosis). A screening dried blood spot test yielded positive results for Fabry disease, which was confirmed by low plasma activity of alpha-galactosidase A. Genetic counseling and family screening were offered to the patient and his relatives.

Discussion:

Fabry disease is a rare hereditary metabolic disorder caused by mutations in the GLA gene, responsible for encoding the enzyme alpha-galactosidase A found within lysosomes. This genetic abnormality leads to an excessive buildup of neutral glycosphingolipids within cellular lysosomes. The condition is systemic and results in various health complications, including cerebrovascular and cardiac diseases, chronic renal failure, skin lesions, peripheral neuropathy, and other abnormalities. “In adults, the primary clinical manifestations typically center around renal issues, such as chronic kidney disease, followed by cardiac involvement, which encompasses arrhythmias and heart failure with preserved ejection fraction. Neurological symptoms such as strokes are also prevalent”. [12] There is a variant form of Fabry disease

UNDER PEER REVIEW

associated with reduced alpha-galactosidase A activity, resulting in delayed onset renal or cardiac symptoms.

While cardiac involvement in Fabry disease is well-documented in medical literature, cases where cardiac symptoms are the initial and sole clinical indication of Fabry disease are relatively rare. For instance, in the international Fabry outcome survey, which included 714 patients, none presented with exclusive cardiac involvement. The most commonly reported symptoms were dyspnea (23%) and chest pain (22%). Left ventricular hypertrophy (LVH) is a key clinical indicator of cardiac involvement in Fabry disease. Unexplained LVH should raise suspicion of Fabry disease, and if diagnosed, enzyme replacement therapy should be considered.

Studies have shown that tissue Doppler imaging can detect myocardial impairment before the development of overt LVH in Fabry patients with causal mutations lacking LVH. Cardiovascular magnetic resonance (CMR) is valuable for non-invasive differentiation of LVH and cardiomyopathy. Typical CMR findings in Fabry disease include late gadolinium enhancement (LGE) distributed in specific myocardial segments, low native T1 values, and prolonged T2 values, particularly in regions with LGE, which are characteristic of the disease. “CMR assessments have also revealed that the extent of myocardial fibrosis is an independent predictor of the incidence of malignant ventricular arrhythmias, such as non-sustained and sustained ventricular tachycardia, and sudden cardiac death in Fabry disease patients”. [12] Syncope, while relatively rare (3%), may be associated with ventricular tachycardia. In some cases, implantable cardioverter-defibrillator (ICD) therapy may be necessary. “In 2007, the Fabry Registry data reported a 9% incidence of arrhythmias among 2187 enrolled patients, with only 74 of them experiencing congestive heart failure (3.4%). Unfortunately, data on the number of patients receiving ICD therapy were not provided”. [12]

Conclusion:

Our case report highlights a rare occurrence where sustained ventricular tachycardia is the only indication of cardiac involvement in Fabry disease, a situation that has been seldom documented. It underscores the vital significance of astute clinical judgment in diagnosing uncommon but treatable hereditary cardiomyopathies.

Ethical Approval:

As per international standard or university standard written ethical approval has been collected and preserved by the author(s).

Consent

As per international standard or university standard, patient(s) written consent has been collected and preserved by the author(s).

References

(1) Echevarria L, Benistan K, Toussaint A, Dubourg O, Hagege AA, Eladari D, Jabbour F, Beldjord C, De Mazancourt P, Germain DP. X-chromosome inactivation in female patients with Fabry disease. Clin Genet 2016;89:44–54.

UNDER PEER REVIEW

(2) Schiffmann R. Fabry disease. Pharmacol Ther 2009;122:65–77.
(3) Linhart A, Lubanda C, Palecek T, Bultas J, Karetova D, Ledvinova J, Elleder M, Aschermann M. Cardiac manifestations in Fabry disease. J Inherit Metab Dis 2001; 24:75–83.
(4) Rolfs A, Fazekas F, Grittner U, Dichgans M, Martus P, Holzhausen M, Bo¨ttcher T, Heuschmann PU, Tatlisumak T, Tanislav C, Jungehulsing GJ, Giese AK, Putaala J, Huber R, Bodechtel U, Lichy C, Enzinger C, Schmidt R, Hennerici MG, Kaps M, Kessler C, Lackner K, Paschke E, Meyer W, Mascher H, Riess O, Kolodny E, Norrving B. Acute cerebrovascular disease in the young: the Stroke in Young Fabry Patients study. Stroke 2013;44:340–349.
(5) Linhart A, Kampmann C, Zamorano JL, Sunder-Plassmann G, Beck M, Mehta A, Elliott PM. Cardiac manifestations of Anderson-Fabry disease: results from the international Fabry outcome survey. Eur Heart J 2007;28:1228–1235.
(6) Toro R, Perez-Isla L, Doxastaquis G, Barba MA, Gallego AR, Pintos G, Barbados FJ, Mangas A, Zamorano JL. Clinical usefulness of tissue Doppler imaging in predicting preclinical Fabry cardiomyopathy. Int J Cardiol 2009;132:38–44.
(7) Habib G, Bucciarelli-Ducci C, Caforio ALP, Cardim N, Charron P, Cosyns B, Dehaene A, Derumeaux G, Donal E, Dweck MR, Edvardsen T, Erba PA, Ernande L, Gaemperli O, Galderisi M, Grapsa J, Jacquier A, Klingel K, Lancellotti P, Neglia D, Pepe A, Perrone-Filardi P, Petersen SE, Plein S, Popescu BA, Reant P, Sade LE, Salaun E, Slart RHJA, Tribouilloy C, Zamorano J. Multimodality Imaging in Restrictive Cardiomyopathies: an EACVI expert consensus document In collaboration with the "Working Group on myocardial and pericardial diseases" of the European Society of Cardiology Endorsed by The Indian Academy of Echocardiography. Eur Heart J Cardiovasc Imaging 2017;18:1090–1121.
(8) De Cobelli F, Esposito A, Belloni E, Pieroni M, Perseghin G, Chimenti C, Frustaci A, Del Maschio A. Delayed-enhanced cardiac MRI for differentiation of Fabry's disease from symmetric hypertrophic cardiomyopathy. AJR Am J Roentgenol 2009; 192:W97–W102.
(9) Sado DM, White SK, Piechnik SK, Banypersad SM, Treibel T, Captur G, Fontana M, Maestrini V, Flett AS, Robson MD, Lachmann RH, Murphy E, Mehta A, Hughes D, Neubauer S, Elliott PM, Moon JC. Identification and assessment of Anderson-Fabry disease by cardiovascular magnetic resonance noncontrast myocardial T1 mapping. Circ Cardiovasc Imaging 2013;6:392–398.
(10) Kra¨mer J, Niemann M, Sto¨rk S, Frantz S, Beer M, Ertl G, Wanner C, Weidemann F. Relationof burdenofmyocardialfibrosis to malignit ventricular arrhythmias and outcomes in Fabry disease. Am J Cardiol 2014;114:895–900.
(11) Wilcox WR, Oliveira JP, Hopkin RJ, Ortiz A, Banikazemi M, Feldt-Rasmussen U, Sims K, Waldek S, Pastores GM, Lee P, Eng CM, Marodi L, Stanford KE, Breunig F, Wanner C, Warnock DG, Lemay RM, Germain DP. Females with Fabry disease frequently have major organ involvement: lessons from the Fabry Registry. Mol Genet Metab 2008;93:112–128.

UNDER PEER REVIEW

(12)Pavlu L, Kocourkova L, Taborsky M, Petrkova J. Ventricular tachycardia: a presentation of Fabry disease case report. European Heart Journal-Case Reports. 2019 Mar;3(1):yty154.
(13)Germain DP, Benistan K, Boutouyrie P, Mutschler C. Osteopenia and osteoporosis: previously unrecognized manifestations of Fabry disease. Clinical genetics. 2005;68(1):93-5.

Figure 1. Eletrocardiogram (ECG) showing ventricular tachycardia.

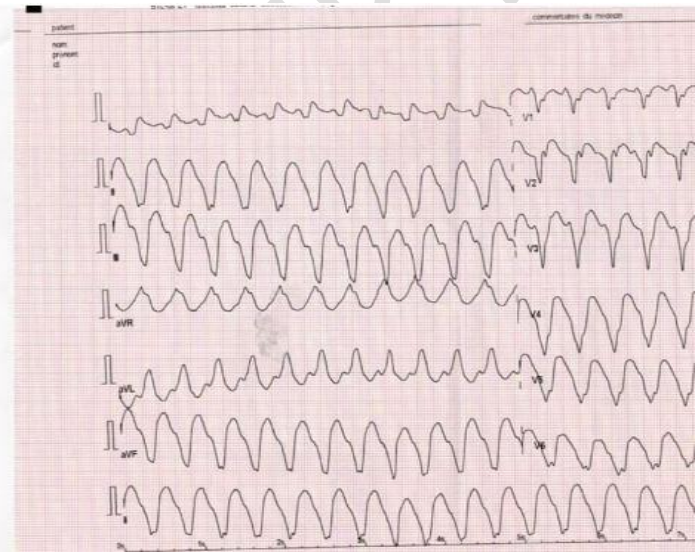

Figure2. Magnetic resonance imaging, short axis T1 mapping of the myocardium at 1,5Tesla with low T1 value at 824ms.

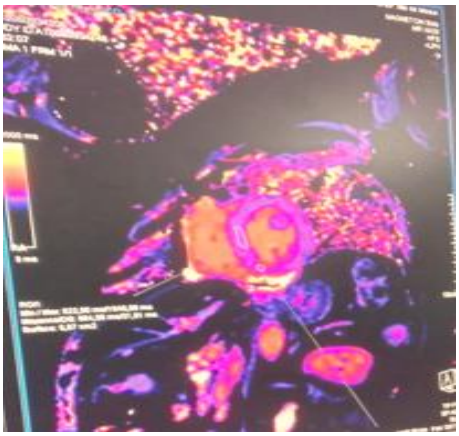

UNDER PEER REVIEW