

eTEP RS approach for Ventral hernia - A short term observational case series of our initial experience

Abstract

Background

There has been a significant increase in ventral hernia surgeries over the last few decades. The operative modalities have changed from open surgery to a wide variety of laparoscopic surgery procedures. Our objective of this study is to present the early clinical results of the procedure, its feasibility and key technical aspects.

Method :

This is a prospective short term 6 months analysis of 15 patients in our hospital who underwent eTEP RS surgery for small to medium size ventral hernias between December 2021 and December 2022. We performed an observational study of the feasibility and clinical outcome of the procedure and analysis of the data in terms of operative details, intraoperative and postoperative complications.

Result :

Out of 15 patient, 1 patient required conversion to Open Rives Stoppa procedure and was excluded from the study. 14 patients underwent eTEP RS procedure. One patient required additional Transversus Abdominis Release (TAR) procedure for tension free posterior wall closure. The mean duration was 187.5 min and mean postoperative stay was 2.07 days. The mean defect size was 15.28 cm² and average mesh size 359.64 cm². At 6 months follow up, there was no recurrence on clinical examination. However 2 patients had seroma which was managed conservatively.

Conclusion

eTEP RS Procedure is a safe and effective procedure for ventral hernia repair. However surgeons need to have a reasonable skill and expertise in minimally invasive surgery with an understanding of anterior abdominal wall anatomy. Proper case selection in the initial few patients is important.

Keywords : Ventral hernia, eTEP RS procedure, Minimally Invasive Surgery

Introduction

The abdominal wall is a complex structure with the primary function to protect and enclose the structures of gastrointestinal and urogenital tract . A ventral hernia occurs where there is a defect or weakness in the anterior abdominal wall resulting in the protrusion of preperitoneal fat, omentum or bowel contents through it. Over the years , a wide variety of surgical modalities have evolved specially with the advancement and progress of minimally invasive surgery with the aim for better outcome and patient satisfaction.

The conventional and widely popularised open method for ventral hernia repair is the Rives stoppa approach which involves placing the prosthetic mesh in the retro rectus plane between the rectus muscle anteriorly and the posterior rectus sheath posteriorly. This space in the midline is dissected into the preperitoneal plane and continues caudally into the space of Retzius. This is considered to be the gold standard in ventral hernia repair.

[1, 2] There is ample and conclusive evidence suggesting the advantages of retromuscular plane for hernia repair in terms of lower recurrence and better functionality due to restoration of anterior abdominal wall functionality [2,3]

The advent of minimally Invasive procedure for ventral hernia repair was with the placement of Intraperitoneal Onlay mesh (IPOM) by Karl LeBlanc and Booth ^[4] in the year 1993. For over a decade laparoscopic IPOM gained widespread acceptance in ventral hernia surgery. However limitations of IPOM repair came to the forefront with larger defects, adhesions and intestinal obstructions due to intraperitoneal mesh, postoperative pain due to traumatic fixation methods and the obvious cost of the composite mesh. Soon laparoscopic procedures started to develop to avoid placement of mesh in the peritoneal cavity.

Dr Igor Beliansky successfully replicated and published the endoscopic retromuscular repair (eTEP RS) following the same principles of open Rives stoppa repair for ventral and incisional hernias. ^[5,6,7] This facilitated the placement of a large polypropylene mesh in the retrorectus plane . This procedure combines the benefit of minimally Invasive process with the placement of a routine mesh away from intraperitoneal cavity. It seems to be the closest to ideal technique for ventral and incisional hernias having the benefit of minimal access, wide

mesh placement and possible low recurrence, minimal intra abdominal breach and complications and reduced cost. The procedure requires surgical expertise mainly due to the constraints of the working space and a thorough knowledge and understanding of anterior abdominal wall anatomy. ^[5, 6]

Here we present an observational study and our early experience in the initial 15 patients of ventral hernias undergoing eTEP RS procedure in our institute

Materials and Method

Study design

This is a prospective observational study to analyse the short term -6 months outcome conducted on all small to medium size ventral hernia patients undergoing eTEP RS at our centre from December 2021 to December 2022. A single team of four people led the first author carried out the procedure. Clinical evaluation and assessment were done for all patients. Ultrasound abdomen was done for diagnosis and only incisional hernia or suspected multiple defects in primary hernia was subjected to CT abdomen.

Patient with the following criteria were included in the study

1. Patients with primary abdominal wall hernias and incisional hernias.
2. Age > 18 years
3. Defect size equal to or less than 6 cm

We excluded recurrent hernias with previous history of mesh hernioplasty for the study group.

Procedure

The patient is placed in the supine position with both arms tucked by the side. There is a table 'break' at the umbilicus level facilitating extension thereby enabling instrument movement without hindrance. (Figure 1).

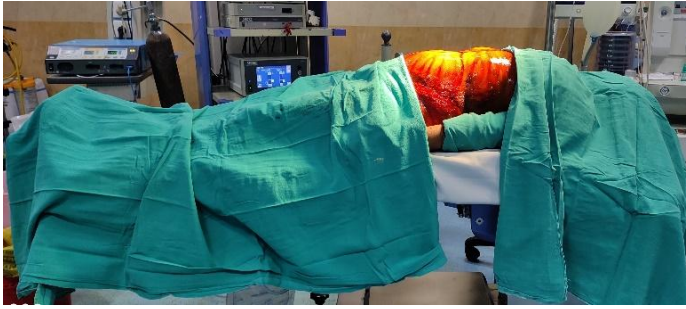

Figure 1 : Patient Position

Abdominal wall markings are done along the costal margin cranially and the symphysis pubis to anterior superior iliac spine caudally. The approximate location of linea semilunaris is marked 8 cm from the midline on either side. The markings can also be done under ultrasound guidance. An 12 mm incision is made in the left paramedian just below left costal margin and blunt dissection is done to reach the anterior rectus sheath. With retraction by an S shaped retractor, the anterior rectus sheath is incised with cautery to visualise the left rectus muscle. The rectus muscle is retracted and a 10 mm port placed. A 10 mm 30 deg telescope is introduced and blunt dissection is done with the telescope in retro rectus place in cranio-caudal direction (Figure 2).

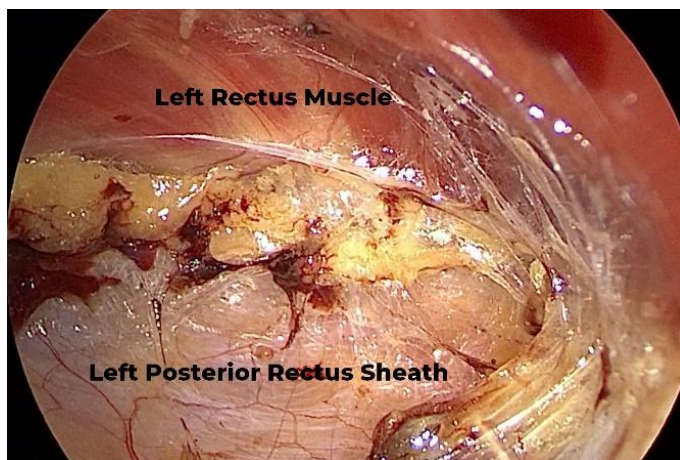


Figure 2 : Left Retrorectus dissection

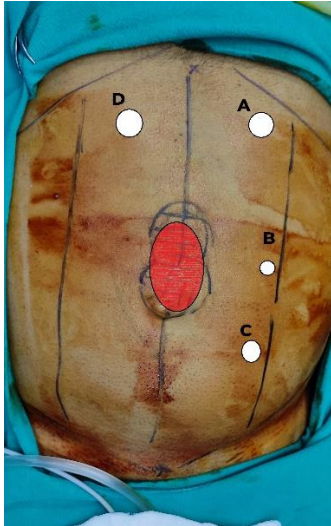


Figure 3 : Port Positions

The lateral limit of dissection is the linea semilunaris and care is taken to prevent injury to the neurovascular bundle. Caudally the dissection proceeds into the retropubic space as required. One 5 mm and one 10 mm port is then placed medial to the linea semilunaris in the retrorectus plane taking care not to injure the posterior rectus sheath or peritoneum by the trocar during insertion. Prior to insertion of the port, a 24 g spinal needle or a 24 G needle is inserted for direction and guidance of entry. Entry of working ports medial to the semilunar line should be under vision smooth and gradually (Figure 3). A sudden movement may cause the trocar to puncture the posterior sheath and peritoneum to result in pneumoperitoneum and loss of space. Retrorectus dissection is then done by a combination of monopolar hook cautery and bipolar to release the thin stands between the rectus muscle and posterior rectus sheath.

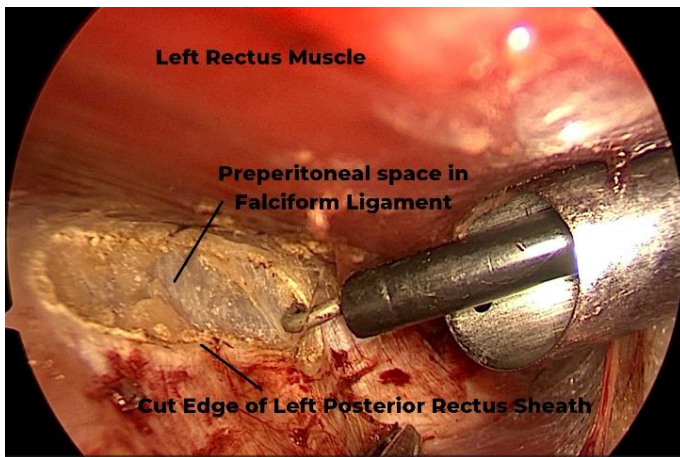


Figure 4 : Dissection of Left posterior rectus sheath

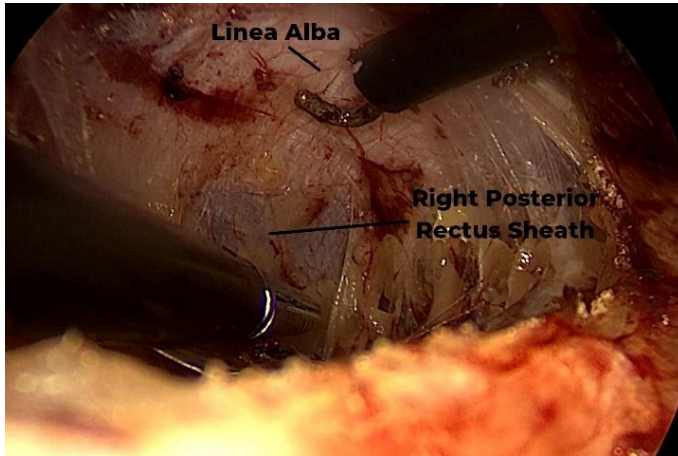


Figure 5 : Crossover – entering the preperitoneal space to opposite PRS

The telescope is then shifted to the 10 mm lower port to visualise and facilitate the cranial end of dissection. Left posterior rectus sheath is then incised at about 5 mm lateral to the medial most margin using a hook cautery or scissors at the level of epigastrium(Figure 4). This facilitates entry into the preperitoneal space at the level of the falciform ligament. We found useful is to perform a blunt dissection and stay close to the roof which is the white transverse fibres of Linea alba. The fat of falciform ligament is swept down which is a bloodless plane and there are less chances of peritoneal injury. As the blunt dissection proceeds to the right side , the white transverse fibres end and the colour change is noted to reddish brown at the roof (Figure 5) . This is the posterior rectus sheath in the opposite (Right) side which is incised to enter the right retrorectus space (Figure 6). After opening up the right retrorectus space for about 1 – 2 cm, a 10 mm port is placed in this space under vision. At this point it is useful to perform blunt dissection on the right side with the telescope and after connection the gas to the port. Once both PRS space is developed , even if there is pneumoperitoneum due to peritoneal breach, there is less difficulty in dissection and minimal loss of space.

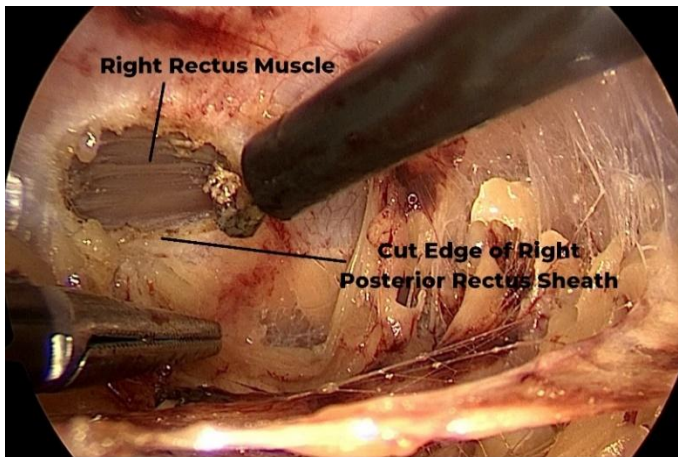


Figure 6 : Entering right retrorectus space

Dissection now proceeds caudally as the medial edges of the PRS on either side are cut to create a common large retrorectus space. The hernia sac is dissected and reduced. During this process of dissection of hernia sac there may be a breach of the peritoneal layer causing development of pneumoperitoneum and causing collapse of the retrumuscular space. However if bilateral RMS space is created previously this does not result in much problem. A verrees needle may be placed in left hypochondrium to release pneumoperitneum if space and vision is affected. The posterior layer consists of the posterior rectus sheath on either side and in the midline by the the falciform ligament cranially and the thin peritoneal bridge and sac caudally. Any breach or defect that may form at the time of dissection is closed with 2 .0 vicryl suture (Figure 7). This integrity of this layer is important only to provide a barrier between the mesh and intra abdominal viscera .

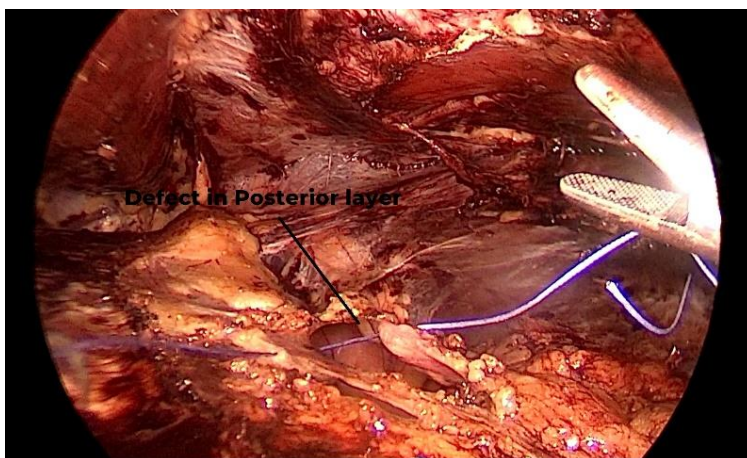


Figure 7 : Suturing of posterior layer

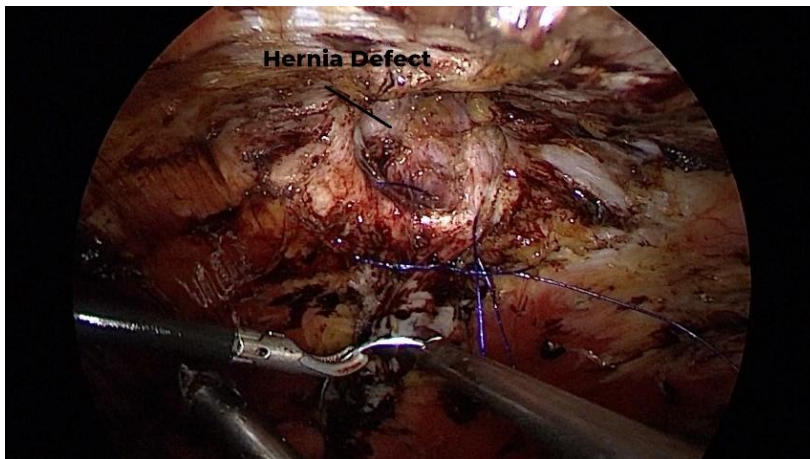


Figure 8 : Suturing of hernial defect

The linea alba and defect can be repaired with 1- 0 barbed, non absorbable suture (Figure 8). The suturing is best possible after reducing the pressure to 6 – 8 mm Hg. Alternatively in some patients defects were closed with multiple transfascial figure 8 sutures with No 1 Nylon passed with a suture passer. Finally the mesh is placed after measurement of the area. We halfrolled the mesh and tied with sutures and inserted it into the space. It is then placed in one half on the roof ,the sutures are cut and then unrolled. The basic principle is that the mesh should lie flat on the posterior layer without any rolling of edges (Figure 9).




Figure 9 : Placement of appropriate size mesh

We commonly used a 15 x 20 cm polypropylene mesh . For larger defects and incisional hernia we have used upto 30 x 25 cm polypropylene mesh. Although in the initial few patients we used interrupted 2-0 absorbable

sutures to fix the mesh but subsequently we have not used any fixation for the mesh. A romovac suction drain was placed routinely in first 5 patients. However subsequently we avoided routine placement of drain and it was only based on intraoperative judgement such as extent of dissection, size of mesh and surface area of dissected space.

Post-operative care

Postoperatively most of the patients were ambulant the same evening or the next day. In most patients catheter was removed on the first postoperative day. Patients were usually discharged on 2nd to 4th post operative day on routine oral analgesics for a period of 5 days. Follow up was done at 7 days , 1 month and 6 months. Monitoring was done for Surgical site infection, seroma / hematoma or skin necrosis. Clinical assessment and examination was done for recurrence and relevant radiological investigation was advised , if required.

Results

A total of 15 patients were planned for procedure between January 2022 till December 2022. Out of them , 1 patient with incisional hernia and multiple defects required conversion to open Rives stoppa procedure . He had developed multiple defects in the posterior peritoneal layer. We managed to salvage with an open Rives stoppa and unilateral TAR procedure. We have excluded this patient in the final study data. (Table 1)

Patient Characteristics

Out of 14 patients in the study group , 9 patients were female and 5 males. The Median /age was 52.5 years and mean BMI 26.5 (range 25.3 – 35.6). Four patients were hypertensive, two patients were diabetic and two patients had Coronary artery disease. 12 patients had primary hernia and 2 patients had incisional hernia(Table 1). One of the patients with primary hernia had 2 defects – paraumbilical and epigastric. According to the EHS classification, the two incisional Hernia patients had a M3-5 W1 and M3-5 W2 defect.

Table 1 : Patient Characteristics

Total patient	15
Conversion to Open Surgery	1

Final patient count (N)	14
Male: Female	9 : 5
Mean age (Years)	52.5 (Range 33 - 76)
Mean BMI	26.5
Hypertension	4
Diabetes Mellitus	2
Coronary artery disease	2
Primary Hernia	12
Incisional Hernia	2

Perioperative characteristics and outcome

13 patients underwent eTEP RS and 1 patient eTEP with unilateral TAR. The mean operative time in the study group was 187.5 +/- 44.49 min (Range 120 – 270 min). The mean defect size was 15.28 cm². The minimum defect size was 9 cm² and maximum defect size was 30 cm². One patient had multiple defect comprising of paraumbilical and epigastric hernia . two of our patients had an epigastric divarication which was repaired simultaneously. The mean mesh size was 359.64 +/- 169.30 cm² (Range 300 to 750 cm²). The commonest mesh used was a 15 x 20 cm polypropylene mesh and the largest was a 30 x 25 cm polypropylene mesh.(Table 2).

Table 2 : Intraoperative and Postoperative results

e TEP TS	13
E TEP unilateral TAR	1
Operative time (min)	
Mean	187.4
Range	120-270
SD	44.49
Defect Area (cm ²)	
Mean	15.28
Range	9- 30

SD	7.08
Mesh Area (cm ²)	
Mean	359.64
Range	300-750
SD	169.30
Drain placed	
Yes	8
No	6
Duration of Drain (Days)	
Mean	8.8
Range	8 - 12
Hospital Stay (Days)	
Mean	2.07
Range	1 - 4
Postoperative Complications	
Seroma	2 (14%)
Hematoma	0
Surgical site infection	0
Readmission	0
Recurrence	0

In 8 out of the 14 patients drain were placed . Drain output was serosanguinous and minimal The drains were removed on an average of 8.8 days (range 8 - 12 days) on the first follow up. Average postoperative stay in the study group was 2.07 days (Range 1 – 4 days). There were no surgical site infection , hematoma or skin necrosis. At 1 month follow up, 3 patients complained of discomfort around surgical site and was advised ultrasonography. This showed mild fluid collection in 2 patients possibility of seroma which were managed conservatively without intervention. **Both the patients were reviewed after 4 weeks which showed improvement of clinical symptoms and minimal fluid collection on follow up ultrasound.** We observed no evidence of recurrence on clinical examination till date with the minimum follow up of about 6 months

Discussion

Hernias have been a significant burden to the healthcare for many years . With the technological advancement of minimal access surgery , there has been a significant shift of hernia surgery from open to Laparoscopic surgery . A wide spectrum of laparoscopic techniques have developed in search for the ideal procedure which has minimal access, better postoperative comfort and recovery to the patient , wider acceptability and easy learning curve to the surgeon and reduced overall cost.

E TEP RS procedure was developed and published by Dr. Belyansky et al ^[5] in a seminal article in the year 2018. It allows creation of a large surgical space for placement of mesh with good postoperative outcome and low recurrence . For larger defects the same plane can be extended with a Posterior component separation (TAR) as described by Novitsky YW ^[8]. With the growing popularity of eTEP RS mesh hernioplasty for ventral hernias in recent times we hope to have rapidly expanding data available in literature in the near future with respect to long term outcome and results. However one factor is certain that this procedure has a steeper learning curve and meticulous dissection and technical expertise. ^[5,9,10]

Although we did not have a comparative pain score with our IPOM procedure for ventral hernia , we noted a lower analgesic requirement and early mobility in patients undergoing eTEP RS. This is supported by most of the studies and series on eTEP RS . Multiple studies have previously demonstrated that transfascial sutures and tackers are the cause of postoperative and occasional chronic pain following IPOM repair. ^[11, 12] In eTEP RS there is this significant advantage that fixation is usually not required thereby decreasing postoperative pain and discomfort . Most of our patients were ambulant the next postoperative day and the average length of stay in our patient was 2.07 days. Mishra A et al ^[13] reported a mean length of stay for eTEP RS for 48 cases of primary hernias of 3.75 days and Sharma B B et al ^[14] 6 in their series of 38 cases had a mean length of stay of 3.9 days.

Our mean operative time was comparable to other studies. We had a mean of 187.5 min , while Sharma B B et al ^[14] in their series reported a mean of 171 min . Mishra A et al ^[13] in a large series of over 100 cases reported operative time of 124.33 +/- 23.68 min. Here it would be important to mention that over a period of time and after the initial 5 to 6 cases the orientation of space, understanding of the anatomy and manouverability of the instruments made the surgical procedure comparably easier with possible decreasing operative times.

We started our initial cases of e TEP RS with small to medium sized primary paraumbilical and epigastric hernias which were reasonably easier for dissection and then progressed to a few patients with incisional hernia. Our mean defect size was 15.28 cm² (Range 9 – 30 cm²) . Sharma B B et al ^[14] in their initial series had a mean defect size of 21 cm² . One of the patients in their study required an unilateral TAR for tension free posterior wall closure. Multiple studies including the initial study by the innovator have described their experience with larger defects. Baig S J ^[9] in their study had a mean defect size of 45.33 cm² and mean defect width 6.65 cm. Dr Igor Belyansky ^[5] in their original article had an average defect size of 132.1 cm². It is important to note that a concept and skill of the additional Transversus Abdominis Release procedure as proposed by Novitsky YW ^[8] is imperative adjunct to e TEP RS repair of larger defects and specially for incisional hernia . This will aid in tension free repair of the posterior layer in patients with larger hernias or peritoneal breach.

Conclusion

An ideal surgical option for a ventral hernia would possibly be one which is Minimally Invasive , have a significant postoperative comfort and recovery, low chance of recurrence , good cosmetic outcome , less chances of postoperative / intra abdominal complication and lower economic burden to the patient. The currently available studies widely accepts the fact that E TEP RS procedure scores in all of the above .

Despite the limitation in our study due to the small number of cases, short follow up and the absence of comparison with other procedure, the only drawback that we see and is noted in almost all studies is the steep learning curve and the fact that surgeons should have a reasonable skill and experience in laparoscopic procedure before embarking on e TEP RS procedure. Intraoperative suturing for closure of posterior wall and closure of linea alba requires technical expertise, skill and experience. Overall it is a safe and effective procedure with good postoperative outcome. **Studies with longer follow up period and detailed comparison with other Minimally invasive surgeries for ventral hernia will be able to prove its superiority over others** . However for surgeons embarking on e TEP RS, a proper case selection in the initial few procedures and a gradual progress to larger defects and incisional hernia with multiple defects Is advisable. Additionally, a understanding ,concept and skill of TAR is mandatory as we progress to managing more large and complex hernias by e TEP RS procedure .

Ethical Approval:

As per international standard or university standard written ethical approval has been collected and preserved by the author(s).

Consent

As per international standard or university standard, patient(s) written consent has been collected and preserved by the author(s).

References

1. Rives J, Lardennois B, Pire JC, Hibon J. Large incisional hernias. The importance of fail abdomen and of subsequent respiratory disorders. *Chirurgie* 1973; 99:547–563
2. Stoppa RE. The treatment of complicated groin and incisional hernias. *World J Surg* 1989;13:545–554.
3. J. Rives, J. C. Pire, J. B. Flament, J. P. Palot, and C. Body, “Treatment of large eventrations. New therapeutic indications apropos of 322 cases,” *Chirurgie*, vol. 111, no. 3, pp. 215–225, 1985.
4. LeBlanc KA, Booth WV. Laparoscopic repair of incisional abdominal hernias using expanded polytetrafluoroethylene: preliminary findings. *Surg Laparosc Endosc.* (1993) 3:39–41.8258069
5. Belyansky I, Daes J, Radu VG, Balasubramanian R, Reza Zahiri H, Weltz AS, Sibia US, Park A, Novitsky Y. A novel approach using the enhanced – view totally extraperitoneal (eTEP) technique for laparoscopic retromuscular hernia repair. *Surg Endosc* 2018; 32(3): 1525–1532. DOI: 10.1007/s00464-017-5840-2.
6. Radu VG. Retromuscular Approach in Ventral Hernia Repair-Endoscopic Rives-Stoppa Procedure. *Chirurgia.* 2019 Jan 1;114:109-14.
7. Daes J. The enhanced view–totally extraperitoneal technique for repair of inguinal hernia. *Surgical endoscopy.* 2012 Apr;26(4):1187-9.
8. Novitsky YW, Elliott HL, Orenstein SB, Rosen MJ. Transversus abdominis muscle release: a novel approach to posterior component separation during complex abdominal wall reconstruction. *Am J Surg.*2012; 204:709–716
9. Baig SJ, Priya P. Extended totally extraperitoneal repair (eTEP) for ventral hernias: Short-term results from a single centre. *J Min Access Surg* 2019;15:198-203.
10. Radu VG, Lica M. The endoscopic retromuscular repair of ventral hernia: the eTEP technique and early results. *Hernia* 2019; 23(5): 945–955.

11. Nguyen SQ, Divino CM, Buch KE, Schnur J, Weber KJ, Katz LB, Reiner MA, Aldoroty RA, Herron DM.
Postoperative pain after laparoscopic ventral hernia repair: a prospective comparison of sutures versus tacks.
JSLs: Journal of the Society of Laparoendoscopic Surgeons. 2008 Apr;12(2):113.
12. Cobb WS, Kercher KW, Heniford BT. Laparoscopic repair of incisional hernias. Surgical Clinics. 2005 Feb
1;85(1):91-103.
13. Mishra A, Jabbal H S , Nar A S, Mangla R. Analysis of 'enhanced-view totally extra-peritoneal' (eTEP)
approach for ventral hernia: Early results. J Minim Access Surg, 2022 Oct 6. doi:
10.4103/jmas.jmas_129_22. Online ahead of print.
14. B B Sharma, S Singhal , A K Sharma , D Vishnoi . Endoscopic eTEP-RS for small ventral hernia: Initial
experience at MGH hospital. European Journal of Molecular & Clinical Medicine. Volume 9, Issue 7, Summer
2022

