

Original Research Article

The Dermoscopic Patterns in Patients with Acanthosis Nigricans and its Relation to Duration and Control of Diabetes Mellitus

Abstract

Background: Acanthosis nigricans (AN) is associated with endocrine dysfunction, especially insulin resistance and ~~hyper-insulinaemia~~hyperinsulinaemia, as seen in diabetes mellitus (DM). Clinical and dermoscopic findings of AN are associated with control of DM.

Aim: This study ~~aims~~ aims to evaluate the dermoscopic patterns in patients with AN and its relation to the duration and control of diabetes mellitus.

Material and Methods: This ~~Comparative analytical cross-sectional~~ study was conducted on ~~prediabetic~~Prediabetic patients (20 patients) complaining of AN with ~~age~~ages ranging from 30 to 52 years old (2 male and 18 female) and ~~patients~~Patients of chronic diabetes mellitus of different durations (20 patients), complaining of AN with age ranging from 33 to 60 years old (5 male and 15 female); ~~we investigated~~ HbA1C level and random blood glucose, in addition to dermoscopic examination of AN, were performed using the dermoscope (DL4).

Results:~~Significantly~~ Significant positive correlation between dermoscopic findings of AN and ~~BMI~~, random blood glucose and HbA1C of both groups. ~~Significantly positive correlation between (hyperpigmented dots, hyperpigmented globule and papillary projection) of dermoscopic findings of AN and clinically hyperpigmented patch and Velvety-like appearance of both groups.~~ Significant increase in papillary projection, hyperpigmented dots and hyperpigmented globule in Group II compared to Group I.

Conclusion: Significant positive correlation between dermoscopic findings of acanthosis nigricans and BMI, ~~RBG~~ and HbA1C of both groups. ~~Severity~~The severity of the clinical appearance of AN is related mainly to ~~the~~ level of blood glucose and ~~IR~~ so it more marked in diabetic group than prediabetic group.

Keywords: Diabetic mellitus, Acanthosis nigricans, Dermoscopy.

Introduction

Acanthosis nigricans is a skin condition characterized by a velvety papillomatous overgrowth of the skin that occurs mainly in the flexural areas, particularly the axillae, groins, inframammary regions, and neck. Acanthosis nigricans is usually a sign of an underlying condition or disease, such as obesity or diabetes (benign). Its presence as a sign of internal ~~malignancy~~ is very rare (1).

First described in 1889 by a German dermatologist, as a ~~physical~~ skin finding. In 1976, acanthosis nigricans was linked to hyperinsulinemia - a consequence of insulin resistance that is associated with obesity. Presently ~~it is~~ suggested as a clinical marker for high blood insulin levels, suggesting insulin resistance. The presence of acanthosis nigricans indicates to both ~~the physician and the patient~~ that there is a serious biochemical disorder that requires intervention (2).

Types of acanthosis nigricans:

Comment [PB1]: Check what type of study you are undertaking

Formatted: Highlight

Comment [PB2]: Elaborate when used first

Formatted: Highlight

Formatted: Highlight

Comment [PB3]: Make a proper statement.

Comment [PB4]: elaborate

Formatted: Highlight

Comment [PB5]: what does it stand for? I know but how can you know that your readers know?

Formatted: Highlight

Comment [PB6]: Which internal malignancy. Write down.

Type I–familial: Familial acanthosis may arise as a result of an autosomal dominant trait, presenting at birth or developing during childhood (3).

Type II – endocrine: Acanthosis nigricans is associated with endocrine dysfunction, especially insulin resistance and hyperinsulinemia, as seen in diabetes mellitus. This activates the insulin-like growth factor receptors, which leads to the proliferation of keratinocytes, fibroblasts, and other cells in the skin. Activation of other growth ~~factors~~factor receptors such as fibroblast growth factor receptors or epidermal growth factor receptors can also be responsible. Excess circulating androgens, particularly in Cushing’s disease, acromegaly, polycystic ovarian disease, Addison’s disease and hypothyroidism (4).

Type III–obesity and pseudo acanthosis nigricans: In young persons, acanthosis nigricans is a visible marker which strongly suggests insulin resistance (5).

Formatted: Highlight

Type IV–drug-related: Acanthosis nigricans has been linked to the use of nicotinic acid, glucocorticoid use, combined oral contraceptive pills, and growth hormone therapy (6).

Type V–malignancy: Malignant acanthosis nigricans refers to acanthosis nigricans occurring as a paraneoplastic syndrome associated with ~~a~~–cancer. Malignant acanthosis nigricans is most commonly associated with gastrointestinal adenocarcinomas, as well as genitourinary cancers such as those of the prostate, breast, and ovary. Other cancers, such as those of the lung, stomach, and lymphoma, are occasionally associated with acanthosis nigricans (7).

Acanthosis Nigricans in Ppre-diabetic states, the identification of dark patches on the skin may be the first indication of type 2 diabetes mellitus (DM type 2) (8).

Prediabetes is a component of the metabolic syndrome and is characterized by elevated blood sugar levels that fall below the threshold to diagnose diabetes mellitus. Prediabetes can be diagnosed by measuring ~~hemoglobin~~–HbA1c or blood glucose level (9).

Diabetes mellitus describes a heterogenic group of metabolic diseases whose basic characteristic is chronic hyperglycemia with subsequently elevated sugar in the urine (10). Diabetes is caused by insufficient production of insulin (either absolutely or relative to the body’s needs), production of defective insulin (which is uncommon), or the inability of cells to use insulin properly and efficiently leading to hyperglycemia and diabetes (11).

Formatted: Highlight

Dermoscopy is a non-invasive procedure method that allows the in vivo evaluation of ~~colors~~ colours and microstructures of the epidermis, the ~~dermoepidermal~~–dermo-epidermal junction, and the papillary dermis not visible to the naked eye. The use of this technique provides a valuable aid in diagnosing pigmented skin lesions (12).

Dermoscopy of acanthosis nigricans (AN) usually reveals linear crista cutis and sulcus cutis with scattered black or dark brown dots and globules (13). In chronic lesions with thickened skin, exophytic papillary structures are seen (14).

Material and methods

This Comparative analytical cross-sectional study included 40 patients who fulfilled the criteria for the definition and classification of patients with acanthosis nigricans. Group I: Prediabetic patients (20 patients) complaining of acanthosis nigricans with ages ranging from 30 to 52 years old (2 male and 18 female). Group II: Patients of chronic diabetes mellitus of different durations (20 patients), complaining of acanthosis nigricans with ages ranging from 33 to 60 years old (5 male and 15 female). We exclude Other endocrine or systemic diseases known to result in AN, internal malignancy (gastrointestinal), autoimmune conditions such as (systemic lupus erythematosus, scleroderma, Sjogren’s syndrome and Hashimoto’s

thyroiditis), history of intake of drugs which can cause AN (nicotinic acid, oral contraceptives, topical fusidic acid, methyl testosterone and triazinate), history of high alcohol intake (>14 units/week for women and >21 units/week for men), **used illicit drugs** and Pregnancy.

Comment [PB7]: Means??

Formatted: Highlight

Written informed consent was obtained from each patient after informing him/her about the steps of the procedure, and the importance of photo documentation in adherence to the ethical committee guidelines of Alzhray Hospital, AL-Azhar University, Cairo, Egypt.

Method

The patients ~~They were~~ subjected to Personal history, history of acanthosis nigricans including (onset, course and duration), history of DM, duration of DM in diabetic patients, history of dermatological disease, history of previous treatment, clinical assessment, general examination including BMI, dermatological examination including (onset, course, duration, site, shape, and distribution of acanthosis nigricans, hyperpigmentation, velvety appearance and skin tag). Laboratory investigation including: HbA1C and random blood glucose

Comment [PB8]: Use proper terminology

Formatted: Highlight

Photography of the lesion of each patient **was taken** with a digital camera (Sony cyber shot DSC – W710, 64 megapixels, and 5 x optical zoom).

Dermoscopic examination of the patients ~~were~~ **was** performed using the dermoscope ((DermLite DL4, 3Gen, 10x magnifications, USA).

Two types of examination by dermoscopy were performed. Non-polarized dermatoscope and Polarized dermatoscope. Non-polarized images show multiple cristae and sulci clearly, whereas polarized imaging allows better visualization of hyperpigmented dots and streaks.

Statistical analysis:

Recorded data ~~was~~ **were** analyzed using the statistical package for social sciences, version 23.0 (SPSS Inc., Chicago, Illinois, USA). The quantitative data were presented as mean ± standard deviation and ranges. Also, qualitative variables were presented as numbers and percentages. Data ~~was~~ **were** explored for normality using Kolmogorov-Smirnov and Shapiro-Wilk test.

Results

Table 1 revealed a significant increase in the percentage of dermoscopic findings of acanthosis (papillary projection, hyperpigmented dots and hyperpigmented globule) in Group II compared to Group I. While there ~~was~~ **is** no significant difference between the two groups regarding the percentage of crista cutis and sulcus cutis.

Table 2 revealed a significant positive ~~c~~ **correlation** between the percentage of (crista cutis, sulcus ~~c~~ **cutis**, hyperpigmented globule and papillary projection) ~~of the~~ dermoscopic finding of AN and RBG of ~~p~~ **prediabetic** patients, a significant positive correlation between the percentage of (hyperpigmented globule and papillary projection) of ~~the~~ dermoscopic finding of AN and HbA1C of ~~p~~ **prediabetic** patients. And a significant positive correlation between the percentage of (hyperpigmented ~~globule~~ **globules**, hyperpigmented dots and papillary projection) of dermoscopic findings of AN and BMI of ~~p~~ **prediabetic** patients.

Table 3 revealed a significant positive correlation between ~~the~~ **percentage** of (hyperpigmented globule, hyperpigmented dots and papillary projection) of dermoscopic finding of AN with RBG and HbA1c of Group II, and a significant positive correlation between ~~the~~ **percentage** of (Hyperpigmented globule, hyperpigmented dots, Crista Cutis, Sulcus Cutis and Papillary projection) and BMI of Group II.

| Table 4 revealed a significant increase in [the](#) percentage of (hyperpigmented dots and papillary projection) in uncontrolled DM compared to controlled DM.

|

UNDER PEER REVIEW

Table (1): Percentage of dermoscopic findings of acanthosis nigricans in the studied groups:

Percentage of Dermoscopic Findings	Total (n=40)	Group I: Prediabetic (n=20)	Group II: Type II DM (n=20)	Test value	p-value
Percentage of Crista Cutis Mean±SD Range	84.00±9.28 60-95 (%)	83.75±8.41 70-95 (%)	84.25±10.29 60-95 (%)	t= - 0.168	0.867
Percentage of Sulcus Cutis Mean±SD Range	83.75±9.52 60-95 (%)	83.75±8.41 70-95 (%)	83.75±10.75 60-95 (%)	t= 0.000	1.000
Percentage of Hyperpigmented dots Mean±SD Range	15.13±8.06 0-30 (%)	12.00±6.23 0-30 (%)	19.25±10.06 0-30 (%)	U= - 2.176	0.025
Percentage of Hyperpigmented globule Mean±SD Range	16.50±9.26 0-50 (%)	14.25±7.04 0-30 (%)	19.75±10.04 0-50 (%)	U=- 2.215	0.021
Percentage of Papillary projection Mean±SD Range	16.00±12.02 0-60 (%)	5.75±4.63 0-30 (%)	26.25±14.59 5-60 (%)	U= - 5.244	<0.001**

Table (2): Correlation between [the](#) percentage of dermoscopic Findings of AN with Baseline characteristics in Group I:

Percentage of dermoscopic findings		Baseline characteristics			
		Age (years)	HbA1C	Random Blood Glucose	BMI [wt/(ht)^2]
Percentage of crista cutis	Rs	-0.103	0.399	.493*	-0.102
	p-value	0.666	0.081	0.027	0.668
Percentage of sulcus cutis	Rs	-0.103	0.399	.493*	-0.102
	p-value	0.666	0.081	0.027	0.668
Percentage of hyperpigmented dots	Rs	-0.340	0.415	0.418	.747**
	p-value	0.142	0.069	0.067	<0.001
Percentage of hyperpigmented globule	Rs	-0.405	.700**	.626**	.566*
	p-value	0.076	<0.001	0.003	0.009
Percentage of papillary projection	Rs	-0.307	.732**	.651*	.565*
	p-value	0.187	<0.001	0.002	0.009

Table (3): Correlation between percentage of dermoscopic findings of acanthosis with baseline characteristics in group II:

percentage of dermoscopic findings		Baseline characteristics				
		Age (years)	HbA1C	Random Blood Glucose	Duration of DM (years)	BMI [wt/(ht) ²]
Percentage of crista cutis	Rs	-0.103	0.398	0.435	-0.179	.487*
	p-value	0.664	0.082	0.055	0.449	0.029
Percentage of sulcus cutis	Rs	-0.108	0.410	0.432	-0.218	.462*
	p-value	0.650	0.073	0.057	0.357	0.040
Percentage of hyperpigmented dots	Rs	-0.178	.459*	.771**	-0.168	.457*
	p-value	0.453	0.042	<0.001	0.480	0.043
Percentage of hyperpigmented globule	Rs	-0.426	.458*	.626*	-0.102	.493*
	p-value	0.061	0.042	0.003	0.670	0.027
Percentage of papillary projection	Rs	-.457*	.591*	.758**	-0.292	.455*
	p-value	0.043	0.006	<0.001	0.212	0.044

Table (4): Correlation between percentage of dermoscopic findings of acanthosis with control of DM in group II:

Percentage of Dermoscopic Findings	HbA1c				U-test	p-value
	Controlled (n=11)		Uncontrolled (n=9)			
	Mean	±SD	Mean	±SD		
Percentage of Crista Cutis	80.91	10.68	88.33	8.66	-1.680	0.110
Percentage of Sulcus Cutis	80.00	11.18	88.33	8.66	-1.829	0.084
Percentage of Hyperpigmented dots	13.18	11.24	24.44	10.44	-2.300	0.034*
Percentage of Hyperpigmented globule	15.00	12.65	23.33	15.00	-1.349	0.194
Percentage of Papillary projection	18.64	9.77	35.56	14.46	-3.116	0.006*

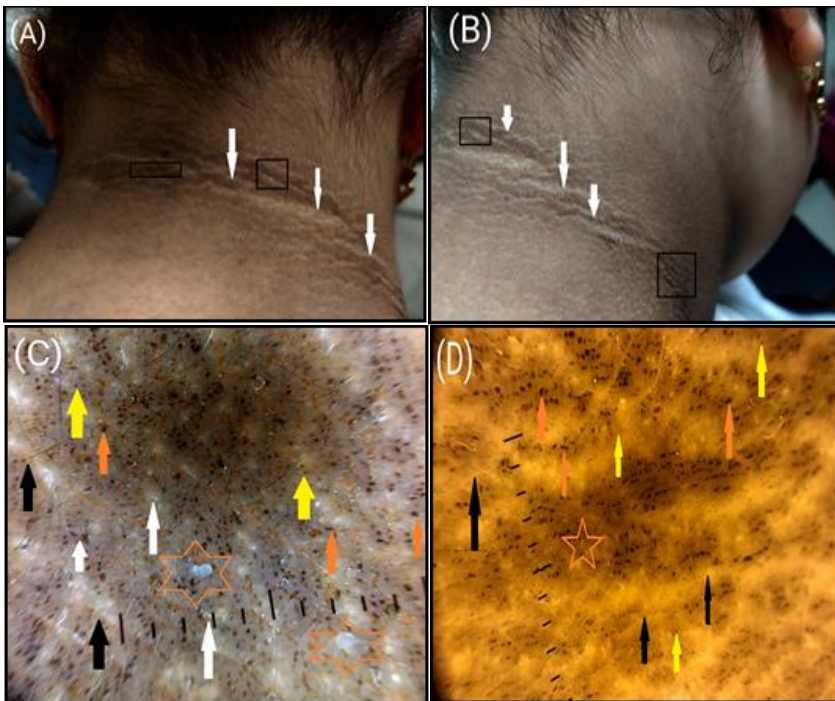


Figure 1: diabetic Patient A ~~33-year-old~~ 33-year-old female with (A) Clinical picture anterior view of the nape of the neck of AN showing hyperpigmented patch (black square) and velvety-like appearance (white arrow). (B) Clinical picture left lateral view of the neck of AN showing hyperpigmented patch (black square) and velvety-like appearance (white arrow). (C) Dermoscopic picture of AN with 10x dermoscopic magnification power (mixed light of DL4) showing hyperpigmented dots (yellow arrow), hyperpigmented globule (orange arrow), crista cutis and sulcus cutis (black arrow), papillary projection (white arrow) and acrochordon (orange star). (D) Dermoscopic picture of AN with 10x dermoscopic magnification power (non-polarized light) showing hyperpigmented dots (yellow arrow), hyperpigmented globule (orange arrow) and acrochordon (orange star).

Formatted: Highlight

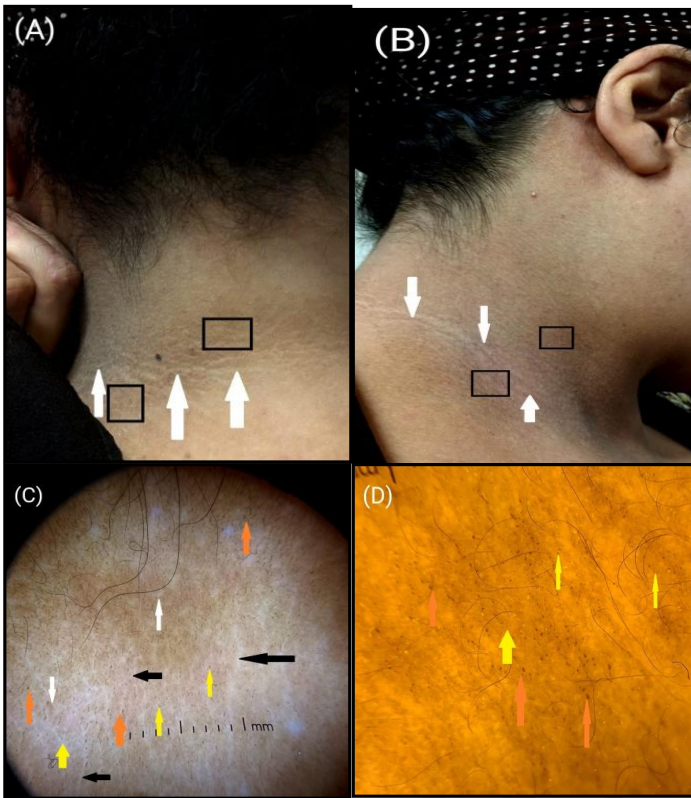


Figure 2; prediabetic Patient: A 42-year-old female with (A) Clinical picture anterior view of the nape of the neck of AN showing hyperpigmented patch (black square) and velvety-like appearance (white arrow). (B) Clinical picture left lateral view of the neck showing hyperpigmented patch (black square) and velvety-like appearance (white arrow). (C) Dermoscopic picture of AN with 10x dermoscopic magnification power (mixed light of DL4) showing hyperpigmented dots (yellow arrow), crista cutis and sulcus cutis (black arrow), hyperpigmented globule (orange arrow) and papillary projection (white arrow). (D) Dermoscopic picture of AN with 10x dermoscopic magnification power (non-polarized light) showing hyperpigmented dots (yellow arrow) and hyperpigmented globule (orange arrow).

Discussion

Acanthosis nigricans is a medical sign characterised by brown-to-black, poorly defined, velvety hyperpigmentation of the skin. It is usually found in body folds, such as the posterior and lateral folds of the neck, the armpits, groin, navel, forehead, and other areas (15)

In this study the clinical findings of acanthosis nigricans are described as thickened, symmetrical greyish-brown hyperpigmentation plaques in the sides and back of the neck.

In the current study, the dermoscopic findings of acanthosis nigricans in the neck of both groups were sulcus cutis (it represents Basket weave stratum corneum filled in the

valley of the downwardly progressed epidermis) and crista cutis (which is related histopathologically to uplifted and pigmented epidermis) seen in all patients with mixed light of DL4. Other common findings were papillary projections (which correspond to papillomatous projections of the dermis), hyperpigmented dots and hyperpigmented globule (due to accumulations of free melanin or an increased

Formatted: Indent: First line: 0.5"

number of highly pigmented melanocytes in the cornified layers of the epidermis) better seen with non-polarized light. No pigment network or other signs

The current study findings are consistent with previous studies on 36 women [which](#) found [that](#) the most common finding was the presence of sulci cutis and cristae cutis. The histopathologic correlate of cristae is extensive papillomatosis and ~~of~~ sulci are the interspersed rete ridges, together forming a 3-dimensional egg-carton-like structure. Multiple brown-to-dark brown dots were observed, probably due to focal melanin accumulation at the dermo-epidermal junction. Another common finding was milia-like cysts, seen due to [the](#) presence of intraepidermal keratin cysts formed as a result of papillomatosis and hyperkeratosis(16).

According to demographic data of randomly studied groups, there was [a](#) non-significant statistical difference between the two groups regarding family history of acanthosis, BMI and sex. While there ~~was~~ [is](#) a significant increase in age in Group II compared to Group I. ~~As~~ [A](#) family history of acanthosis and BMI act as good risk ~~factor~~ [factors](#) for IR in both groups.

These results are ~~in~~ [in](#) ~~concordance~~ [concordance](#) with the study which reported that prediabetes is more prevalent in middle age (25-44 age group) and diabetes in (45-60 age group)(17).

In the current study, there is a significant positive correlation between the dermoscopic findings of acanthosis nigricans and BMI, random blood glucose and HbA1C of both groups. These results are ~~in~~ [in](#) ~~concordance~~ [concordance](#) with the study which reported that insulin resistance and the degree of obesity increase with the severity of AN in Korean obese children. BMI Z-score, which represented the degree of obesity increased with increasing AN severity(18,19).

In the current study, there is a statistically significant increase in the hyperpigmented ~~patches~~ [patches](#), and velvety-like appearance in group II compared to group I. As the severity of the clinical appearance of acanthosis is related mainly to the level of blood glucose more than the duration of DM, so it [is](#) more marked in [the](#) diabetic group.

The current study results are inconsistent with **Antonio et al (20)** who reported that high AN severity may occur in the presence of high glucose ~~level~~ [levels](#) during a shorter time frame of exposure.

Conclusion

In conclusion, ~~there~~ [there](#) is a significant positive correlation between dermoscopic findings of acanthosis nigricans and BMI, random blood glucose and HbA1C of both groups.

~~Severity~~ [The severity](#) of [the](#) clinical appearance of acanthosis is related mainly to [the](#) level of blood glucose and IR so it [is](#) more marked in [the](#) diabetic group than prediabetic group.

References

- 1-Kutlubay Z, Engin B, Bairamov O and Tüzün Y (2015): “Acanthosis nigricans: A fold (intertriginous) dermatosis”. Clin Dermatol; 33:466-70.
- 2-Miller, J (2009): “Acanthosis Nigricans”. E Medicine Dermatology.
- 3- Innaurato S, Brierley GV, Grasso V, Massimi A, et al (2018): “Severe insulin resistance in disguise: A familial case of reactive hypoglycemia associated with a novel heterozygous INSR mutation”. Pediatr Diabetes; 19:670-674.

- 4-Brady MF, Rawla P (2022):** “Acanthosis Nigricans”. In: StatPearls. Treasure Island (FL): StatPearls; 28613711.
- 5- Verma, Shyam, Vasani, Resham, Joshi, et al (2016):** “A descriptive study of facial acanthosis nigricans and its association with body mass index, waist circumference and insulin resistance using HOMA2 IR”. Indian Dermatology Online Journal; 7: 498–503.
- 6- Hartman R, Defelice T, Tzu J, Meehan S, et al (2011):** “Acanthosis nigricans in the setting of niacin therapy”. Dermatol Online J; 17:11.
- 7- Lee SS, Jung NJ, Im M, Lee Y, et al (2011):** “Acral-type malignant acanthosis nigricans associated with gastric adenocarcinoma”. Ann Dermatol; 23:208–10.
- 8- Bhagyanathan Meera, Deepak Dhayanithy, Vijayan Ampaya Parambath, and R. Bijayraj (2017):** “Acanthosis nigricans. A screening test for insulin resistance – An important risk factor for diabetes mellitus type-2”. J Family Med Prim Care; 6: 43–46.
- 9- Wilson and Mara Lynn (2017):** “Prediabetes”. Nursing Clinics of North America; 52: 665–677.10.
- 10- Zheng Y, Ley SH and Hu FB (2018):** “Global aetiology and epidemiology of type 2 diabetes mellitus and its complications”. Nat Rev Endocrinol; 14:88-98.
- 11-Roden M and Shulman G.I (2019):** “The integrative biology of type 2 diabetes”. Nature; 576, 51–60.
- 12- Marghoob AA (2013):** “Current status of dermoscopy in the diagnosis of dermatologic disease”. J Am Acad Dermatol; 2:252-53.69.
- 13- Uchida S, Oise N, Suzuki T and Kawada A (2012):** “Dermoscopic features of hyper pigmented dots in crista cutis with inherited acanthosis nigricans”. J Cosmetics Dermatol Sci Appl; 2:252-53.
- 14- Sonthalia S, Gupta A, Jha AK and Sarkar R (2019):**“Hyperpigmented disorders (disorders of pigmentation)”. Dermoscopy in General Dermatology. London: CRC Press; P; 257-69.
- 15- Smid CJ, Madoff P, Alade A, Legare JM, et al (2018):** “Acanthosis nigricans in achondroplasia”. Am J Med Genet; 176:2630-2636.
- 16- Ranglani and Harshal (2019):** “Dermoscopic features of acanthosis nigricans”: A case series. International Journal of women dermatology; 5: 282.
- 17- Khaled K. Aldossari, Abdulrahman Aldiab, Jamaan M. Al-Zahrani, Sameer H. Al-Ghamdi, et al (2018):**“Prevalence of Prediabetes, Diabetes, and Its Associated Risk Factors among Males in Saudi Arabia”. A Population-Based Survey ; 2194604.
- 18- Byung-Gue Lee, Kyung Hee Park, Young-Gyun Seo, Hye-Mi Noh, et al (2020):** “Insulin Resistance and Obesity according to degree of acanthosis nigricans in obese korean children and adolescents” Korean J Fam Pract; 332-337.

- 19- yung-Gue Lee, Kyung Hee Park, Young-Gyun Seo, Hye-Mi Noh, et al., (2020):** “Insulin Resistance and Obesity according to Degree of Acanthosi` s Nigricans in Obese Korean Children and Adolescents, Department of Family Medicine”. Korean J Fam Pract; 10: 332-337.
- 21- Antonio Videira-Silva, MSc, Carolina Albuquerque, MD, MSc, and Helena Fonseca, MD (2019):** “Acanthosis nigricans as a clinical marker of insulin resistance among overweight adolescents” Ann Pediatr Endocrinol Metab; 24: 99–103.

UNDER PEER REVIEW