

## *fCase study*

# **A retrospective analysis of Paraduodenal Internal Hernia: A Case Series of Nine Patients**

### **Abstract**

Internal abdominal hernias are a rare condition, making up only 0.9% of all cases of intestinal obstruction. Among these, Paraduodenal hernias are exceptionally rare, comprising approximately 53% of all internal hernias. They are more frequently found in the left Paraduodenal fossa compared to the right, have a higher incidence in males and are primarily congenital in nature.

A Left Paraduodenal hernia represents a congenital defect situated posterior to the inferior mesenteric vein and the left branches of the middle colic artery, located to the left of the fourth part of the duodenum. Most patients are diagnosed with this condition between their fourth and sixth decades of life. Delay in diagnosis can lead to surgical complications such as bowel obstruction, gangrene, and perforation. The preferred imaging method for diagnosis is typically a CT scan. The treatment of choice is either an open exploratory laparotomy or laparoscopic surgery.

In this report, we present findings from nine cases of Left Paraduodenal hernias with management involving exploratory laparotomy for seven adult patients and laparoscopic surgery for two paediatric cases.

### **Keywords**

Paraduodenal hernia, Internal hernia, Strangulation of small bowel.

### **Introduction**

An internal hernia refers to an abnormal protrusion of abdominal organs through a defect within the peritoneum or mesentery. These defects can be either congenital or acquired, and they can take various forms, including Paraduodenal, Pericecal, Foramen of Winslow, Transmesenteric and Transmesocolic, Pelvic, Intersigmoid, Retroanastomotic, and Transomental hernias. [1,2,4]

Among these, Paraduodenal hernias are classified into two types: left-sided (accounting for 75%) and right-sided (25%). Left Paraduodenal hernias occur through the fossa of Lanzert, located to the left of the fourth segment of the duodenum. This is an uncommon congenital fossa positioned behind the transverse or descending mesocolon, with the inferior mesenteric artery and vein and the ascending branch of the left colic artery bordering it anteriorly. On the other hand, right Paraduodenal hernias pass through the defect in the transverse mesocolon into Woldeyer's fossa.[3,4,5]

The gold standard for diagnosing Paraduodenal hernias is a CT abdomen scan. In these hernias, the small bowel can become entrapped and strangulated between the mesocolon and the posterior abdominal wall. Symptoms and signs of left Paraduodenal hernia typically include abdominal pain, vomiting, and a palpable mass in the left upper quadrant of the abdomen. The standard approach for treating this condition is through open surgery, although laparoscopic hernia repair can be considered in the hands of experienced surgeons. [5,7,8]

**AIM-**The objective of this study is to investigate the clinical manifestations, radiological assessment, and surgical interventions related to the condition under investigation.

### **Material and Methods**

A retrospective study was carried out at the Jatal Hospital and Research Centre spanning from January 1992 to March 2022. During this period, a total of nine cases of left Paraduodenal hernia were documented, comprising seven adult patients and two paediatric patient, seven patients were male and two were female.

## Result

Nine patients were diagnosed with left Paraduodenal hernia in this study, and seven male patients and 2 female patients. These patients exhibited common clinical symptoms, including abdominal pain, vomiting, and small bowel obstruction. Among the seven adult patients, presented with strangulation of the small bowel inside the hernial sac, leading to gangrene and resection anastomosis was done. However, two paediatric patient received treatment involving laparoscopic reduction of the hernia contents and hernia repair. The diagnostic tool of choice in these cases was a CT abdomen scan, recognized as the gold standard. Notably, there were no reported instances of mortality or morbidity within our case study, and all the documented cases were specifically categorized as left-sided Paraduodenal hernias.

Table 1. Cases of Left Paraduodenal Hernia Reported from January 1992 to March 2022

Case	Age/Sex	Presentation	Radiological Imaging	Surgical Procedure
1	50/M	C/o severe abdominal pain, vomiting, distention and tenderness	CT Abdomen	Explorative laparotomy Reduction of hernia
2	55/M	C/o severe abdominal pain, vomiting, and palpable mass left upper quadrant	CT Abdomen/ X-ray Abdomen	Explorative laparotomy Segmental resection of gangrene with anastomosis done
3	9/M	C/o severe abdominal pain, vomiting, and constipation	CT Abdomen	Laparoscopy
4	13/M	C/o severe abdominal pain, vomiting, Abdomen distension	CT Abdomen	Laparoscopy
5	46/M	C/o severe abdominal pain, vomiting, Abdomen distension	USG/ CT Abdomen/ X-ray Abdomen	Explorative laparotomy Segmental resection of gangrene with anastomosis done
6	58/M	C/o severe abdominal pain, vomiting, Constipation and abdomen distension	USG/ CT Abdomen	Explorative laparotomy Segmental resection of gangrene with anastomosis done
7	45/M	C/o severe abdominal pain, vomiting, and palpable mass left upper quadrant of the abdomen	CT Abdomen	Explorative laparotomy Reduction of hernia
8	60/F	C/o severe abdominal pain, vomiting, Constipation and abdomen distension	USG/CT Abdomen/ X-ray Abdomen	Explorative laparotomy Segmental resection of gangrene with anastomosis done
9	48/F	C/o severe abdominal pain, vomiting, abdomen distention and palpable mass left upper quadrant of the abdomen	USG/CT Abdomen	Explorative laparotomy Reduction of hernia

### Here are some key points from the study:

- Two paediatric patients, aged 9 and 13 years, underwent laparoscopic surgery.
- Out of 9 patients, there were seven males and two females, with a ratio of 3:1.

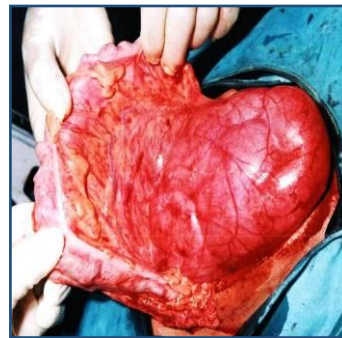
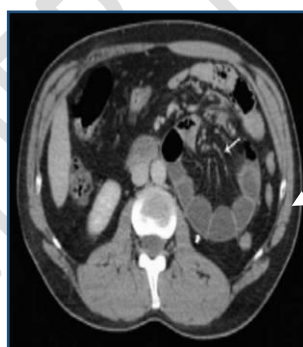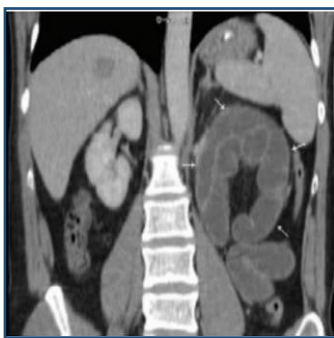- In four cases, strangulation and gangrene were observed, so resection and anastomosis performed.
- All patients presented with common symptoms of abdominal pain and vomiting, with three of them having a palpable mass in the left upper quadrant of the abdomen.

### Case Report

**Case I** –We are reporting a rare case of a large left Paraduodenal hernia with strangulation of the small bowel in a 50-year-old male patient. The patient was admitted to our centre on December 10, 2010, presenting with abdominal pain, vomiting, and constipation lasting for three days. Upon physical examination, we noted a distended abdomen with tenderness in the left upper quadrant and a palpable mass in both the left upper quadrant and epigastric region. An upper right abdominal radiograph confirmed the presence of small bowel obstruction. Subsequent abdominal CT scans revealed an internal left Paraduodenal hernia, characterized by a sac-like structure causing crowding of the small bowel loops. Routine blood and biochemical tests showed normal results.

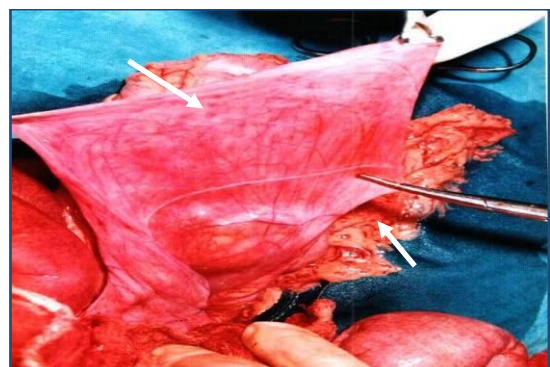
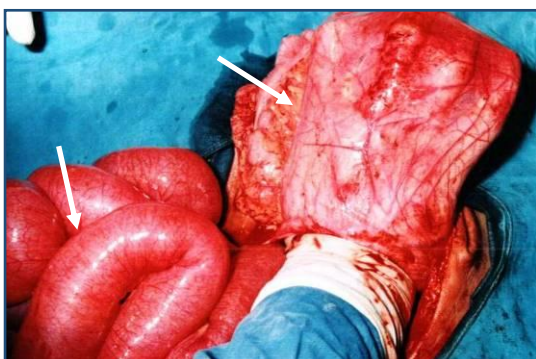
An explorative laparotomy, performed through a midline incision, revealed the presence of a large hernia sac located on the left side of the ligament of Treitz. This hernia sac extended into the lesser sac, situated posterior to the stomach and anterior to the pancreas. The neck of the internal hernia sac was surgically opened, revealing the dilated proximal small bowel. Within the hernia sac, a significant amount of blood accumulation was observed. A large duodenal recess hernia was identified, involving the fourth part of the duodenum, the transverse mesocolon, and the descending mesocolon. The herniated small bowel was gently removed without any adhesions. After relieving the compression on the hernia sac, the blood flow to the small bowel improved, fortunately eliminating the need for small bowel resection.

During the procedure, the inferior mesenteric vein and left colonic vein were exposed, and the excess sac was completely removed. The duodenal recess was then closed using 2.0 silk sutures. The patient's postoperative recovery was smooth, and they were discharged on the 8th postoperative day. ( Fig 1-6)

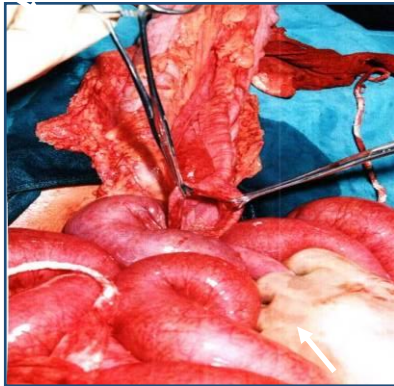


**Fig-1 CT Abdomen photograph showing Left Paraduodenal hernia with Intestinal Obstruction**

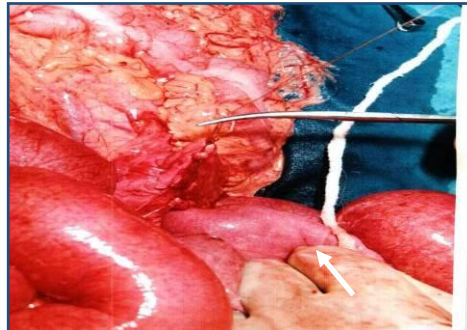
**Fig-2 Intraoperative photographs showing Large Paraduodenal hernial sac**



**Fig-3 Intraoperative photographs showing reduction of small bowel from the hernial sac**



**Fig-4 Intraoperative photographs showing inferior mesenteric vessels on anterior border hernia**

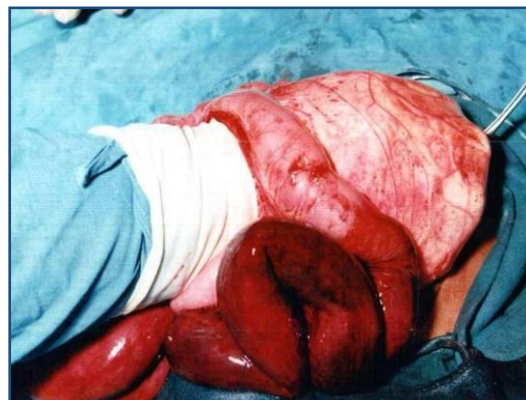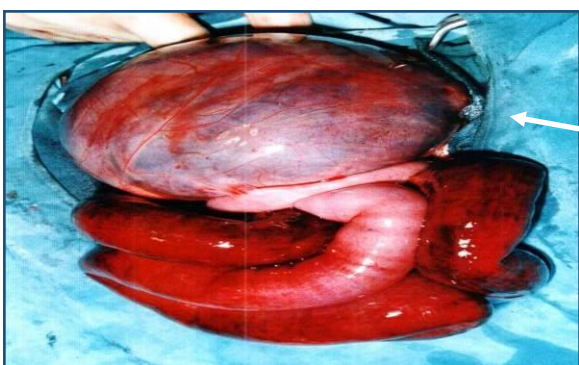


**Fig-5 Intraoperative photographs showing excision of hernial sac (left Paraduodenal hernia)**

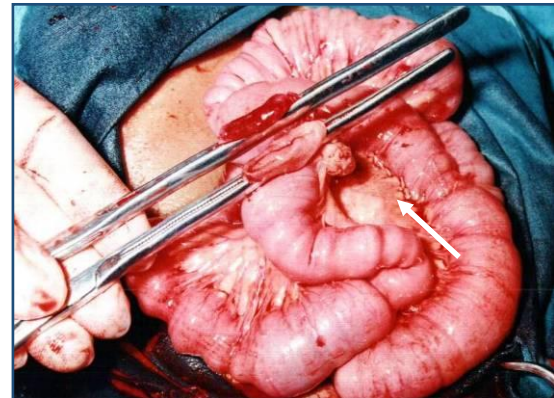
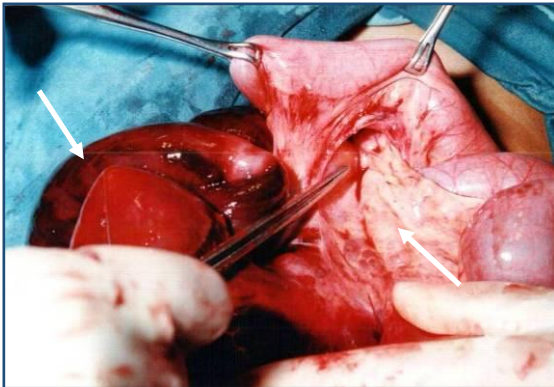
**Fig-6 Intraoperative photographs showing closure of Hernial defect with normal bowels**

**Case II** - On April 15, 2009, a 55-year-old male patient was admitted to our medical centre, presenting with severe abdominal pain, vomiting, and constipation persisting for four days. Upon physical examination, we noted a distended abdomen with generalized tenderness, primarily concentrated in the epigastric region. Additionally, there was a palpable mass detected in the left upper quadrant of the abdomen. The patient displayed guarding and lacked bowel sounds. All laboratory investigations returned with normal results. A plain abdominal radiograph confirmed the presence of acute intestinal obstruction, which was subsequently confirmed by a CT abdomen scan, establishing a diagnosis of strangulated internal hernia in the left upper quadrant of the abdomen. Given the critical condition of the patient, an emergency open laparotomy was deemed necessary. During the surgical procedure, it was revealed that the proximal one-third of the jejunum was enclosed within a sac-like structure that projected to the left of the midline. This sac protruded through the mesentery of the transverse colon, with the inferior mesenteric vessels positioned in the anterior wall of the hernia defect. The posterior wall of the defect was formed by the posterior abdominal wall. Examination of the intestinal loops within the hernia sac revealed signs of entrapment, strangulation, and gangrene. Consequently, the gangrenous bowel segments were resected, and a primary hand-sewn anastomosis was performed.

Following the bowel resection and anastomosis, the hernia sac was excised, and the hernia opening was meticulously closed using 2.0 silk sutures. To facilitate drainage, a drainage tube was inserted before the abdomen was closed. The drainage tube remained in place until the 5th postoperative day when it was removed, and the patient was gradually transitioned to oral fluid intake. The patient's postoperative recovery proceeded without complications, and they were discharged on the 10th postoperative day after demonstrating a satisfactory recovery. **(Fig 7-10)**



**Fig-7 Intraoperative photographs showing large left Paraduodenal hernia with strangulation of small bowel**



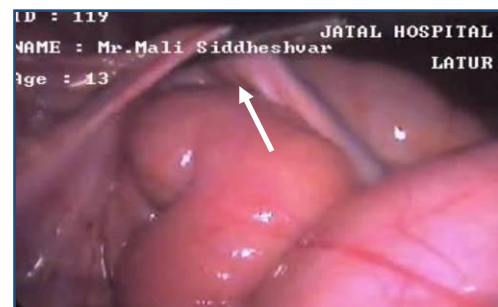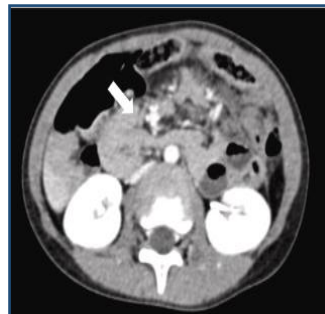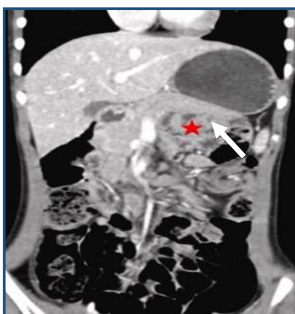**Fig-9 Intraoperative photographs showing Paraduodenal hernia through transmesocolic window**

**Fig-10 Intraoperative photographs showing excision of small bowel gangrene and anastomosis**

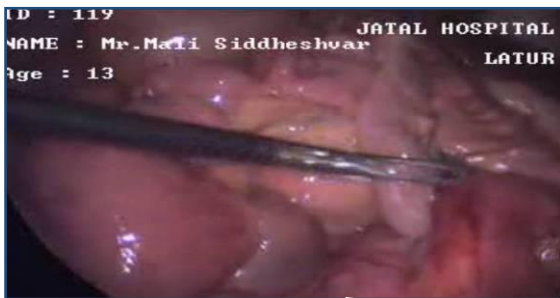**Case III and IV** - Two paediatric patients, a 13-year-old boy admitted on April 13, 2012, and a 9-year-old boy admitted on November 15, 2012, were both preoperatively diagnosed with left Paraduodenal hernias through abdominal CT scans, confirming the diagnosis. Abdominal examinations and routine blood tests yielded normal results, leading to the decision to proceed with laparoscopic surgery for both patients.

The surgical procedure involved positioning the surgeon and the camera operator on the right side of the patient. Under general anaesthesia, a laparoscope was inserted through a 10 mm umbilical port, with additional 5 mm epigastric and two 5 mm right and left midclavicular line ports below the subcostal margin used by the surgeon and assistant for traction. Laparoscopy validated the radiological findings, revealing that a significant portion of the jejunum and small bowel resided within the left Paraduodenal hernia sac. This hernial sac was situated behind the mesentery of the descending colon, extending cranially behind the transverse colon. The anterior wall of the hernial sac was formed by the inferior mesenteric vein, while the posterior wall was composed of retroperitoneal tissue.

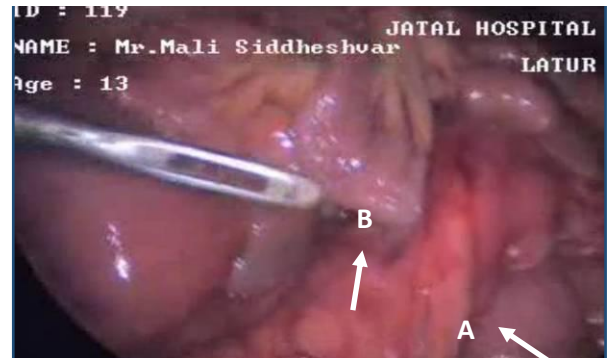
Laparoscopic reduction of the hernia was performed using atraumatic forceps, with no adhesions observed within the hernial sac. The neck of the sac was cleared and mobilized. The small intestine was gently reduced into the abdominal cavity, and the hernia neck was closed using continuous sutures, aligning the peritoneum of the free border of the descending colon mesentery with the peritoneum of the fourth part of the duodenum to the left of the aorta. Both patients were discharged on the 4th postoperative day, displaying a smooth recovery. Importantly, there was no recurrence of symptoms during the 3-year follow-up period. **(Fig 11-16)**



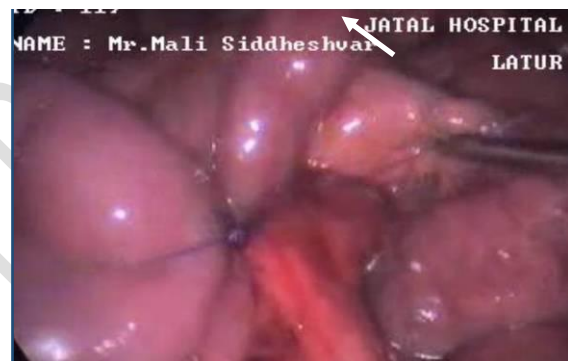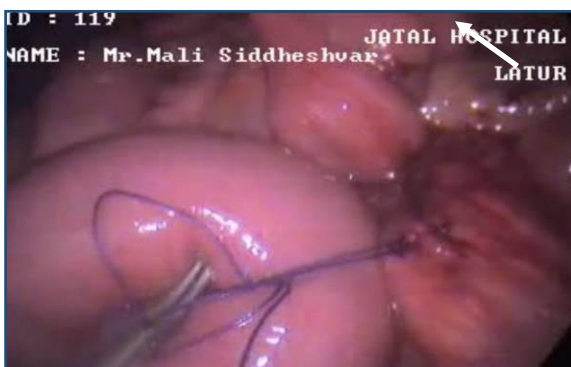**Fig-11 CT Abdomen photograph showing Left Paraduodenal hernia with Intestinal Obstruction**



**Fig-12 Laparoscopic image showing Left Paraduodenal hernia**



**Fig-13,14 Laparoscopic image showing Left Paraduodenal hernia situated behind the mesentery of descending colon  
A- Neck of hernial sac, B- small bowel**



**Fig-15,16 Laparoscopic image showing Left Paraduodenal hernia, neck of the sac closed with 2.0 vicryl**

## Discussion

Paraduodenal hernias, although rare, account for approximately 53% of all internal hernias. They predominantly occur in the left Paraduodenal fossa, with a threefold higher occurrence rate compared to the right side. These hernias are more commonly observed in males and are typically congenital in nature. Most cases present between the fourth and fifth decades of life. [1,2,]

The prevailing theory attributes the development of these hernias to errors in the rotation and fixation of the intestines during embryonic development, resulting in the entrapment of the small bowel between the mesocolon and the posterior abdominal wall. Left Paraduodenal hernias, specifically, are congenital anomalies that form during midgut malformation. The bowel herniates through a structure known as Lanzert's fossa, which is situated behind the fourth part of the duodenum and to the left of the ligament of Treitz. This fossa is present in approximately 2% of the population. Right Paraduodenal hernias, also congenital, are found in Waldeyer's fossa and are less common, occurring in about 1% of the population. [3,4,5]

The fossa of Lanzert is positioned to the left of the fourth part of the duodenum and extends behind the descending mesocolon. Recognizing the location of the inferior mesenteric vein is crucial during surgery, as the inferior border of the hernia opening is the safest point to incise for widening the neck of the hernia and reducing the small bowel without risking damage to vital structures. The fossa of Waldeyer extends inferior to the duodeno-jejunal junction and is bounded anteriorly by the superior mesenteric artery and ascending left colic artery. Herniation of Small bowel through congenital defects on the right side of the transverse mesocolon. [1,2,3]

Clinically, most patients with Paraduodenal hernias present with abdominal pain, vomiting, and partial or complete intestinal obstruction. Radiological imaging, such as X-rays and ultrasonography, often reveals a characteristic clustering of small bowel loops in the left upper quadrant. However, CT abdomen scans have become the preferred diagnostic method for internal hernias. [4,6]

Despite being a rare condition, Paraduodenal hernias have been reported in the literature, with fewer than 500 cases documented in total. While open surgery is the conventional approach for treatment, laparoscopic methods have been explored in recent years. There have been only 28 published reports of laparoscopic Paraduodenal hernia repair between January 1998 and November 2015. Laparoscopic surgery is technically feasible and may represent an optimal surgical approach, especially in children and young individuals, as it offers safety and feasibility in addressing this condition. [2,5,8]

## Conclusion

Paraduodenal hernias are extremely rare and difficult to diagnose. CT abdomen is the gold standard diagnostic tool. Open surgical intervention must be considered to avoid the risk of life threatening complication. The laparoscopic approach seems to be an excellent diagnostic and therapeutic modality.

## References

1. Hassani KI, Aggouri Y, Laalim SA, Toughrai I, Mazaz K. Left paraduodenal hernia: A rare cause of acute abdomen. *Pan Afr Med J.* 2014 Mar 27;17:230. doi: 10.11604/pamj.2014.17.230.3546. PMID: 25170374; PMCID: PMC4145264.
2. Shadhu, K., Ramlagun, D. & Ping, X. Para-duodenal hernia: a report of five cases and review of literature. *BMC Surg* 18, 32 (2018). <https://doi.org/10.1186/s12893-018-0365-8>
3. Kuzinkovas V, Haghighi K, Singhal R, Andrews NJ. Paraduodenal hernia: a rare cause of abdominal pain. *Can J Surg.* 2008 Dec;51(6):E127-8. PMID: 19057724; PMCID: PMC2592587.
4. Dragan Manojlović, Nenad Čekić, Mario Palinkaš, Left paraduodenal hernia – A diagnostic challenge: Case report, *International Journal of Surgery Case Reports*, <https://doi.org/10.1016/j.ijscr.2021.106138>.
5. Maheshwari, S., Khadka, A., Bhattacharjee, S. et al. A case report of left paraduodenal hernia with a spontaneous reduction on follow-up: the rare demonstration on computed tomography. *Egypt J Radiol Nucl Med* 51, 224 (2020). <https://doi.org/10.1186/s43055-020-00338-4>

6. Okino Y, Kiyosue H, Mori H, et al. Root of the small-bowel mesentery: correlative anatomy and CT features of pathologic conditions. *RadioGraphics* 2001; 21:1475-1490.

7. Gabriele Giordano, Elena La Mirata, Valentina Politi, Massimiliano Veroux , Gaetano Alfio Meli, Left Paraduodenal Hernia in a Young Patient with Recurrent Abdominal Pain: A Case Report and Short Literature Review DOI: 10.12659/AJCR.935413 *Am J Case Rep* 2022; 23:e935413

8. Cundy TP, Di Marco AN, Hamady M, et al Giant left paraduodenal hernia Case Reports 2014;2014:bcr2013202465.

9. Xu H, Nie N, Kong F, Zhong B. Large left paraduodenal hernia with intestinal ischemia: a case report and literature review. *Journal of International Medical Research*. 2020;48(9). doi:10.1177/0300060520955040

10. Vanmali A, Maharajh J, Haines M. Left paraduodenal hernia: Embryological and radiological findings. *S Afr J Rad*. 2021;25(1), a1979. <https://doi.org/10.4102/sajr.v25i1.1979>

UNDER PEER REVIEW