

## Case report

# Strangulated Pericecal Internal Hernia –Two Case Reports

### Abstract

A Pericecal hernia is a relatively uncommon form of internal hernia, accounting for only 6-13% of all cases of abdominal internal hernias. It presents with clinical symptoms that closely resemble appendicitis, often causing severe lower abdominal pain and potential complications. This type of hernia occurs due to a defect in the mesentery of the cecum, which can be either congenital or acquired. The most prevalent subtype of Pericecal hernia is the retrocecal hernia, where ileal loops herniate through a defect in the cecal mesentery and the right paracolic gutter. These hernias typically develop within one of four peritoneal fossae: the superior ileo-cecal, inferior ileo-cecal, retro-cecal, and paracolic sulci. Pericecal hernias are also referred to as ileo-colic, retrocecal, ileocecal, or paracecal hernias.

Diagnosis of a Pericecal hernia is often made through abdominal CT scans, which reveal a cluster of bowel loops, typically ileal, located posteriorly and laterally to the normal cecum, extending into the right paracolic gutter. These hernias can lead to small bowel obstruction and displace the cecum anteriorly and medially. Early diagnosis and surgical intervention are crucial to prevent complications.

We present two cases of Pericecal internal hernia: one involving a 9-year-old boy and the other a 35-year-old male patient. Both patients exhibited symptoms of small bowel obstruction. Abdominal CT scans confirmed the presence of a Pericecal hernia with a strangulated small bowel. Exploratory laparotomy revealed the strangulated Pericecal hernia, which was successfully treated through manual hernia reduction and repair of the mesenteric defect.

### Keywords

Pericecal hernia, Paracecal hernia, Internal hernia, Cecum

### Introduction

Internal hernias involve the protrusion of an organ through congenital defects in the peritoneal or mesenteric structures. Although their overall occurrence is less than 1%, they can contribute to approximately 5.8% of all cases of small bowel obstruction. The primary manifestation of an internal hernia is the strangulation of the small bowel, typically occurring in the context of a closed-loop obstruction. [1,2,3]

Pericecal hernia represents a particularly rare subtype of internal hernia. This type is also referred to as paracecal, retrocecal, ileocolic, or ileocecal hernia and is reported to have an incidence rate ranging from 0.1% to 0.3% among all internal hernias. Around the cecum, there exist four potential peritoneal recesses: the superior, inferior, ileocecal, and retrocecal fossa. Strangulation of the herniated contents in a Pericecal hernia can result in tissue necrosis or gangrene, leading to a considerably high mortality rate, with more than 50% of cases reported to be fatal.[3,4,5]

### Case Presentation-1

On February 18, 2015, a 9-year-old boy was admitted to our medical centre due to severe abdominal pain, accompanied by 2-3 episodes of vomiting. The child had experienced a similar episode six months prior, and there was no history of previous abdominal surgeries. Upon physical examination, tenderness was observed in the right iliac fossa, along with guarding. Abdominal

ultrasonography and a plain X-ray of the abdomen indicated the presence of acute intestinal obstruction. Laboratory tests revealed an elevated white blood cell count of 17,000/mm<sup>3</sup>, while kidney and liver function tests returned normal results.

The gold standard diagnostic method, in this case, was a contrast-enhanced CT scan, which revealed a “sac-like” structure in the right iliac fossa containing herniated small bowel loops. The cecum had been displaced upwards and laterally. This preoperative diagnosis confirmed the presence of a Pericecal hernia with small bowel strangulation.

An explorative laparotomy was performed, revealing a mass of small bowel located behind the cecum. The cecum had been pushed upward and laterally, with strangulated small bowel loops located in **the inferior ileo-cecal fossa** or recess. It was identified as a retrocecal internal hernia. Following the reduction of the strangulated small bowel, it regained viability, and there was no evidence of gangrene. The mesenteric defect responsible for the internal hernia was repaired using 2.0 silk sutures. Additionally, an appendectomy was performed during the procedure. The boy was **discharged from** the

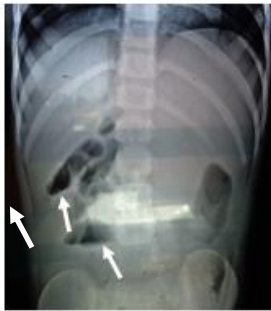

Fig-1 Abdominal plain x-ray showing Multiple fluid levels in RIF

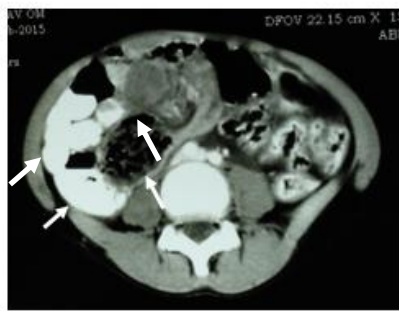

Fig-2 Contrast-enhanced CT abdomen showing “Sac Like” Mass pushing caecum and ascending colon upwards and laterally

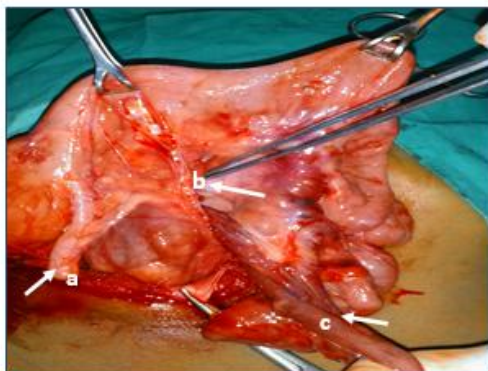
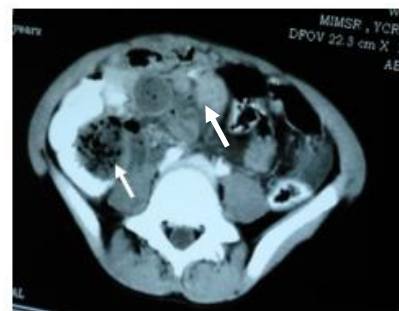


Fig-3 Intraoperative photographs showing a- appendix, b-retrocecal hernia, c- small bowel

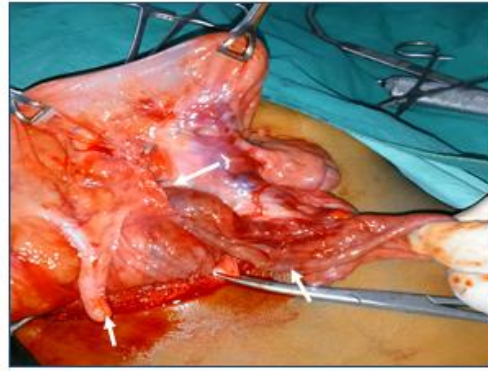


Fig-4 Intraoperative photographs showing strangulated retrocecal hernia

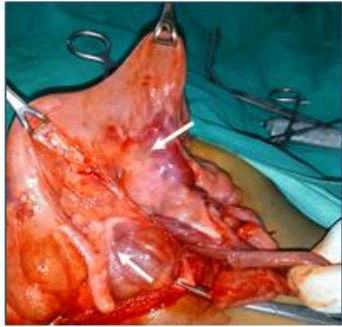

Fig-5 Intraoperative photographs showing strangulated retrocecal hernia

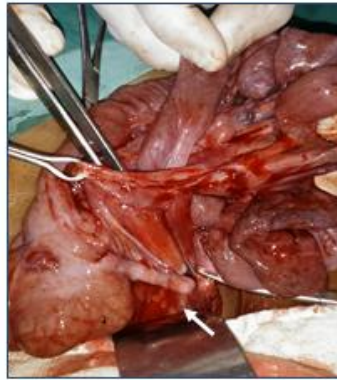

Fig-6 Intraoperative photographs showing reduction of small bowel

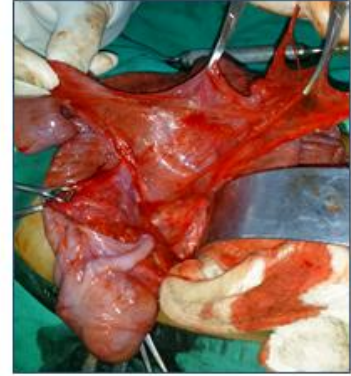

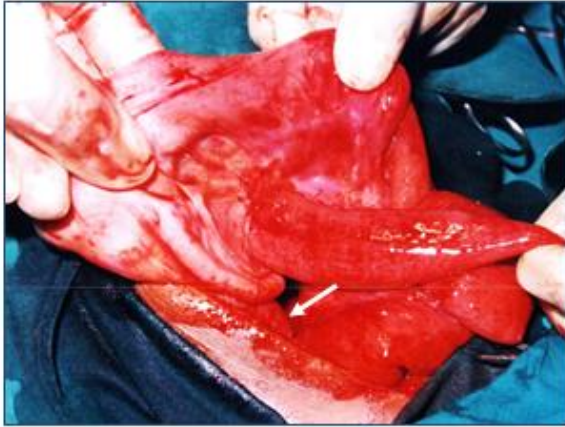Fig-7 Intraoperative photographs showing excision and repair of hernia sac

### Case Presentation -2

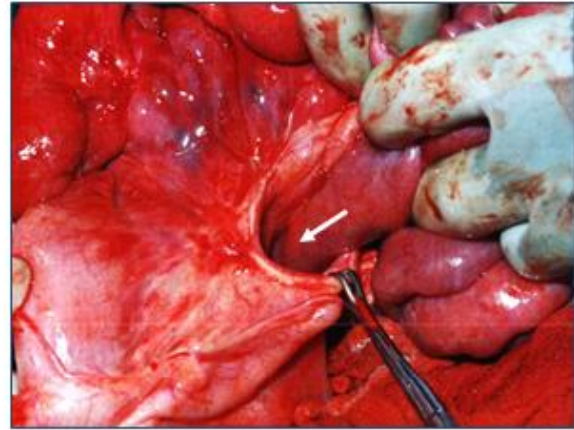
On May 10, 2012, a 35-year-old male patient was admitted to our medical centre with complaints of abdominal pain, abdominal distension, and vomiting persisting for two days. Ultrasonography and a plain X-ray of the abdomen revealed the presence of acute intestinal obstruction. During abdominal examination, a palpable mass was detected in the right lower quadrant, accompanied by guarding and rebound tenderness. The patient had no prior history of surgical procedures, and all laboratory investigations returned normal results.

A provisional diagnosis of acute abdominal condition with small bowel obstruction was established. The patient was taken to the operating room for an exploratory laparotomy, which revealed a herniation of the small bowel with strangulation through a mesenteric defect within the avascular space of Treves. Specifically, this was identified as an inferior ileocecal strangulated hernia. The lateral border of the hernia contained the ileocolic vessels anteriorly, with these vessels constituting the free margin of the hernia orifice.

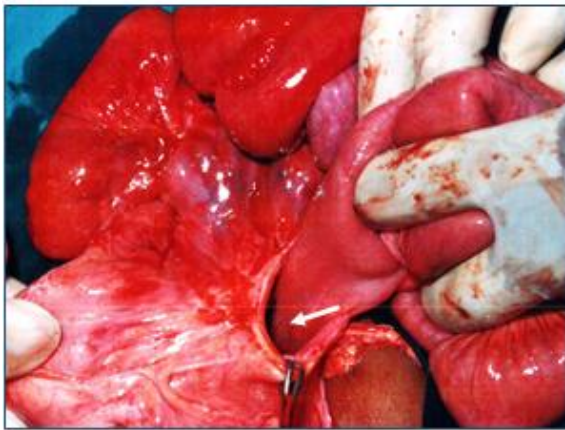
Following the careful extraction of the strangulated small bowel and the reduction of hernia contents, warm sponges and full oxygenation were applied. Fortunately, the small bowel remained viable, and no signs of gangrene were observed. The hernia defect was subsequently closed using 2.0 silk sutures. The patient's postoperative course was without complications, and he was discharged on the 8th day following the surgery. [Fig 8-11]



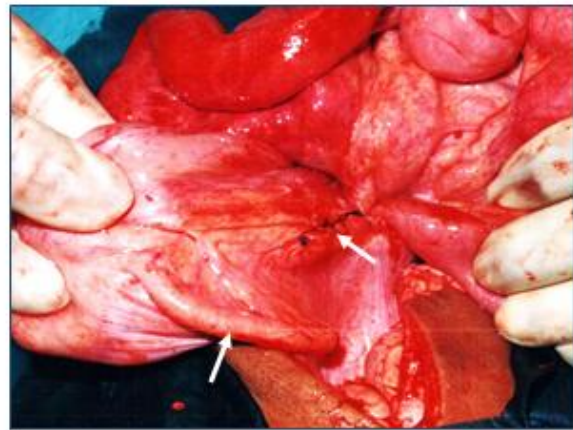
**Fig-8 Intraoperative photographs showing strangulated Pericecal hernia**



**Fig-9 Intraoperative photographs showing strangulated Pericecal hernia**



**Fig-10 Intraoperative photographs showing reduction of strangulated small bowel**



**Fig-11 Intraoperative photographs showing sutured neck of hernia with 2.0 silk**

UNDEH

## Discussion

An internal hernia is defined as the protrusion of abdominal organs into various recesses, foramina, or congenital defects within the abdominal or pelvic cavity. There are six main classifications for internal abdominal hernias, including para-duodenal hernia (55%), foramen of Winslow hernia (61%), Pericecal hernia (13%), intro-sigmoid hernia (6%), para-vessels hernia (4%), and transomental hernia (6%). These hernias can lead to intestinal obstruction, with reported incidence rates ranging from 0.2% to 5.8% of all cases of intestinal obstruction. Among these, Pericecal hernias account for 13% of all internal hernias. They typically develop within one of four peritoneal fossae: the superior ileo-cecal, inferior ileocecal, retro-cecal, and paracolic sulci. In Pericecal hernias, the small bowel herniates through a defect in the cecal mesentery and extends into the right paracolic gutter. [3,4,6]

The embryological anatomy of Pericecal hernias is attributed to the migration of the ileocecal region during the midgut rotation in the fifth month of gestation. This process leads to adhesions between the ascending colon and mesentery, resulting in the formation of four peritoneal recesses.

For the diagnosis of Pericecal hernias, contrast-enhanced CT scans are considered the best modality. Multi-detector computed tomography (MDCT) has become the primary imaging technique, playing a crucial role in preoperative diagnosis and surgical planning. An abdominal CT scan revealing a "sac-like" adherence of crowded small bowel loops within the hernia sac strongly suggests an internal hernia. [2,3]

A search of the PubMed database for literature published from January 1980 to August 2000, using keywords such as Pericecal hernia, retrocecal hernia, paracecal hernia, and ileocecal hernia, yielded 27 English-language reports describing 33 surgical cases of Paracecal hernia. Subsequent searches on PubMed and Medline from 2000 to 2021 identified only 21 cases of Pericecal hernia in the literature. Including our cases, the count may reach 22 or 23 up to August 2023. [1,3] Internal hernias typically present with small bowel strangulation. If reduction of the herniated bowel is not achieved, the mortality rate can be as high as 75%. Therefore, an emergency urgent surgical procedure is recommended. The open surgical approach for treating internal hernias involves reducing the herniated intestinal contents, resecting any necrotic bowel tissue, and closing the hernia defect. Laparoscopic surgery can also be a useful surgical option for Pericecal hernias. [3,5,7]

## Conclusion

A Strangulated Pericecal hernia is a rare and challenging condition, with a high mortality rate. The diagnostic method of choice is contrast enhanced CT and treatment should consist of an emergency open surgery or laparoscopic surgery is mandatory to avoid severe complications.

## Ethical Approval:

As per international standard or university standard written ethical approval has been collected and preserved by the author(s).

## Consent

As per international standard or university standard, patient(s) written consent has been collected and preserved by the author(s).

## References

1. Svetlana Kleyman, Shafia Ashraf, Sherin Daniel, Dinesh Ananthan, Aliu Sanni, Feroze Khan, Pericecal hernia: a rare form of internal hernias, *Journal of Surgical Case Reports*, Volume 2013, Issue 2, February 2013, rjs021, <https://doi.org/10.1093/jscr/rjs021>

2. Kang SI. Incarcerated pericecal hernia: a rare form of the internal hernia. *Yeungnam Univ J Med.* 2018 Dec;35(2):236-239. doi: 10.12701/yujm.2018.35.2.236. Epub 2018 Dec 31. PMID: 31620601; PMCID: PMC6784704.
3. Masaaki Shida, Masayuki Tanaka, Toshiya Tanaka, Yoshihiko Kitajima, Seiji Sato, Successful Retrocecal Hernia Diagnosis and Treatment: A Case Report, *Int Surg* 2021;105:469–473 DOI: 10.9738/INTSURG-D-16-00187.1
4. Yokota, T., Otani, K., Yoshida, J. et al. Paracecal hernia due to membranous adhesion of the omentum to the right paracolic gutter. *surg case rep* 5, 183 (2019). <https://doi.org/10.1186/s40792-019-0749-8>
5. Ogami T, Honjo H, Kusanagi H. Pericecal hernia manifesting as a small bowel obstruction successfully treated with laparoscopic surgery. *J Surg Case Rep.* 2016 Mar 1;2016(3):rjw020. doi: 10.1093/jscr/rjw020. PMID: 26933000; PMCID: PMC4772000.
6. Bensaad A, Habi J, El Aidaoui K, et al. (July 01, 2021) A Fatal Case of Strangulated Pericecal Hernia. *Cureus* 13(7): e16097. doi:10.7759/cureus.16097
7. Seretis, C, Katz, C, Ahmed, A, Palit, A, Piramanayagam, B, Marimuthu, K. Pericecal fossa strangulated internal hernia. *Clin Case Rep.* 2021; 9: 2469–2470. <https://doi.org/10.1002/ccr3.3917>
8. Doishita S, Takeshita T, Uchima Y, Kawasaki M, Shimono T, Yamashita A, et al. Internal hernias in the era of multidetector CT: correlation of imaging and surgical findings. *Radiographics.* 2016;36:88-10
9. Anand M, Sahi PK. Pericecal hernia: An unusual cause of abdominal pain in a child. *Indian Pediatr Case Rep* [serial online] 2021 [cited 2023 Sep 18];1:43-6. Available from: <http://www.ipcares.org/text.asp?2021/1/1/43/310210>
10. Jang EJ, Cho SH, Kim DD. A case of small bowel obstruction due to a paracecal hernia. *J Korean Soc Coloproctol.* 2011;27:41–3. [PMC free article] [PubMed] [Google Scholar]