

HEMOPHAGOCYTIC LYMPHOHISTIOCYTOSIS SECONDARY TO CHRONIC LYMPHOCYTIC LEUKAEMIA AND MULTIPLE INFECTIONS MANIFESTED WITH QUOTIDIAN PYREXIA: A CASE REPORT

Abstract

Hemophagocytic lymphohistiocytosis (HLH) is a rare, life-threatening immune regulatory condition that can cause end-organ damage and death. HLH is clinically characterized by uncontrolled activation of cytotoxic T lymphocytes, natural killer cells, and macrophages that can lead to a cytokine storm. Fever, hepatosplenomegaly, cytopenia, elevated liver enzymes, hypertriglyceridemia, hyperferritinemia, and hemophagocytosis in the bone marrow, spleen, or lymph nodes are the hallmarks of the disease. Its primary (genetic) form is typically observed in pediatric patients whereas its secondary, acquired form is seen in adult patients with an underlying autoimmune, malignant, or infectious disease. Here, we present a case of secondary hemophagocytic lymphohistiocytosis in a 70-year-old male with a history of chronic lymphocytic leukemia, severe prolonged COVID-19, and multiple infections who presented with persistent pyrexia of unknown origin (PUO). Diagnosis and management of HLH in adults are often extrapolated from the pediatric HLH-94 and HLH-2004 protocols. The management includes etoposide-based regimens containing corticosteroids, cyclosporine A, intravenous immunoglobulins (IVIG), intrathecal therapy, and liberal allogeneic stem cell transplant use in higher-risk patients. Due to the diverse clinical manifestations and the presence of numerous diagnostic mimics, the diagnosis of HLH is challenging. Since the prognosis is typically poor, prompt diagnosis and strong treatment are required. Here is a description of how our patient is diagnosed and treated based on the HLH 2004 protocol.

Keyword

Hemophagocytic lymphohistiocytosis, Macrophage activation syndromes, Chronic lymphocytic leukemia, COVID-19, Hyperferritinemia, Pyrexia of unknown origin, Thalidomide

Introduction

“Hemophagocytic Lymphohistiocytosis (HLH) is a rare life-threatening hyper-immunoinflammatory condition characterized by immune activation and proliferation of cytotoxic T cells and macrophages leading to a potentially fatal cytokine storm that results in the engulfment of hematopoietic cells, malignant inflammation, and immunosuppression resulting in multiple organ failure”.^(1,4) “Primary or familial HLH is diagnosed primarily in the pediatric population and is usually caused by homozygous mutations in the genes. About 40-60% of the mutations occur in PRF 1 and Unc-13 Homolog D (UNC13D) genes. Other genes involved are Syntaxin 11 (STX 11) and Syntaxin Binding Protein 2 (STXBP2), whereas secondary or acquired HLH is more frequent in adults and is a complex condition, the underlying cellular and molecular mechanisms of which are incompletely understood. Despite the fact that the precise etiology of secondary HLH is poorly recognized, it can be driven by a wide range of factors, depending on an individual's predispositions and environmental triggers such as Infections: mainly viral origin [Epstein-Barr virus (EBV), herpes simplex virus (HSV), cytomegalovirus (CMV), avian influenza] and others [bacterial, parasitic or fungal], Rheumatologic diseases: rheumatoid arthritis, systemic lupus erythematosus, Kawasaki syndrome, adult-onset Still's disease, and others, Malignancies: natural killer (NK)-cell leukemia, peripheral T-cell lymphoma, EBV in T-cell lymphoma, B-cell lymphoma, and others, Acquired immune deficiency states: after organ transplantation or other causes and Drugs such as lamotrigine, sulfamethoxazole, immunotherapies for cancer such as immune checkpoint inhibitors (ICI) or chimeric antigen receptor CAR-T cell therapy

that are generally associated with a hypersensitivity syndrome (DRESS)”.^(2,3,5,6,7) HLH carries an increased rate of morbidity and mortality. The diagnosis of HLH is challenging since there are numerous diagnostic mimics. The outcome is poor if the diagnosis of HLH is delayed or left untreated. Therefore, a high degree of clinical suspicion is paramount in diagnosing HLH. Our case report includes real-time clinical data of an HLH patient that aids in advancing our understanding of the diagnosis of HLH and provides guidance for future management strategies that will improve clinical outcomes.

Presentation of Case

A 70-year-old male patient came to the hospital with complaints of recurrent high-grade fever spikes and generalized fatigue for 3 months. The patient had a history of Chronic lymphocytic leukemia (CLL) and received multiple cycles of bendamustine/rituximab and achieved complete remission. During hospitalization, he was detected with EBV and CMV and was treated with Ganciclovir. He had fever-triggered seizures and is on antiepileptics. He was also detected with pulmonary aspergillosis infection which was treated with amphotericin B. He had a history of multiple episodes of severe chronic COVID-19, and he received a high dose of monoclonal antibodies (Casirivimab + Imdevimab 2400mg each) after which the fever gradually subsided. He thereafter developed a low-grade fever, and considering the possibility of persistent viremia and his severe immunocompromised status, he was administered another dose of monoclonal antibodies (1200mg each). After which his fever settled. Four months back he was diagnosed with disseminated Tuberculosis (TB) and was on Antitubercular therapy (ATT). While on therapy he got rifampicin-induced hepatomegaly and increased liver enzymes leading to the drug's withdrawal and the administration of levofloxacin instead.

Later the patient was diagnosed with prolonged pyrexia of unknown origin (PUO) and was initiated on Thalidomide 100mg in OPD. After 1 week of treatment with thalidomide, the patient did not tolerate the medicine and continued to have a high-grade fever with reduced appetite and a drop in blood counts. At this point, a probable paradoxical reaction was considered and in view of the possibility of thalidomide toxicity, it was stopped.

After a week, the counts dropped further, while a mild rise in transaminases was observed.

The patient was then admitted with complaints of persistent fever and pancytopenia.

On admission, his initial vitals were blood pressure of 110/60 mmHg, pulse rate of 120/min, SPO2 of 97%, and temperature of 102⁰ F. During physical examination, he was found to have axillary lymph node enlargement and tachycardia.

Table 1 Laboratory tests at admission showing pancytopenia, the elevation of liver tests, and CRP

[PCV: Packed cell volume, TLC: Total leukocyte count, CRP: C-reactive protein, AST: Aspartate transaminase, ALT: Alanine transaminase, GGT: Gamma-glutamyl transferase, PT: prothrombin time, INR: International normalized ratio, PTT: Partial thromboplastin time]

<i>Parameters</i>	<i>Observed values</i>		<i>Reference range</i>
<i>Haemoglobin</i>	6.8	↓	13.0 - 17.0 g/dL
<i>PCV</i>	22	↓	40 - 50 %
<i>TLC</i>	192	↓	4000 - 11,000 cells/mm ³
<i>Neutrophils</i>	83.3	↑	40 - 80 %
<i>Platelets</i>	1,33,000	↓	1,50,000 - 4,50,000 cells/mm ³
<i>CRP</i>	247	↑	< 0.5 mg/dL
<i>Sodium</i>	124	↓	136 - 145 mmol/L
<i>Potassium</i>	4.13		3.5 - 5.1 mmol/L

<i>Blood Urea</i>	31		13 - 43 mg/dL
<i>Creatinine</i>	0.74		0.9 - 1.3 mg/dL
<i>AST</i>	72	↑	< 35 U/L
<i>ALT</i>	49	↑	< 34 U/L
<i>GGT</i>	463	↑	< 55 U/L
<i>Total Protein</i>	5.4	↓	6.4 - 8.3 g/dL
<i>Albumin</i>	2.7	↓	3.5 - 5.2 g/dL
<i>Alkaline</i>			
<i>Phosphatase</i>	647	↑	53 - 128 U/L
<i>Ferritin</i>	13548	↑	20 - 291 ng/ml
<i>Triglycerides</i>	198	↑	< 150 mg/dL
<i>Lactate</i>			
<i>dehydrogenase</i>	318	↑	120 - 246 U/L
<i>Procalcitonin</i>	2.99	↑	< 0.5 ng/ml
<i>Plasma Fibrinogen</i>	600	↑	200 - 393 mg/dL
<i>D-dimer</i>	1448	↑	< 500 ng/dL
<i>PT</i>	14.2	↑	11.1 - 12.9 sec
<i>INR</i>	1.18	↑	0.8 - 1.2 sec
<i>PTT</i>	42	↑	26.3 - 32.2 sec

Routine clinical evaluation revealed pancytopenia and neutropenia. Because of the neutropenic sepsis possibility, the patient was started on empirical antibiotics (Inj. Meropenem 1gm and Inj. Teicoplanin 400mg), Inj. G-CSF 300mg and other supporting measures. The patient was also started on a combination of sulfamethoxazole 800mg and trimethoprim 160mg for prophylaxis of pneumocystis jirovecii, prophylactic antifungal (Inj.

Posaconazole 300mg), and antiviral (Inj. Valacyclovir 1gm). Dermatologic opinion was obtained for developing a single crusted lesion over the right angle of the mouth which was found to be herpes facialis which was treated with Mupirocin ointment for 5 days.

Initially, a provisional diagnosis was made taking into account both infectious possibilities - including sepsis, drug-resistant TB, invasive fungal infection and non-infectious possibilities -including malignancy, Kawasaki syndrome, HLH, and paradoxical thalidomide reactions.

However, the patient's clinical presentations like persistent fever, cytopenia, elevated liver enzymes, high serum ferritin levels, hypertriglyceridemia, hyponatremia, hyperfibrinogenaemia, natural killer (NK) cell depletion, and elevation of the soluble cluster of differentiation (CD)25 (>5000/uL), met the diagnostic criteria for HLH. Additionally, a biopsy of an axillary lymph node suggested HLH. The diagnosis of HLH was supported by further investigations of the bone marrow, which revealed a significant population of CD68+ macrophages with active hemophagocytosis. Because of the patient's active infective etiology and CLL, the patient was diagnosed with secondary HLH due to Malignancy or severe viral infection with EBV or COVID-19.

The patient was then initiated on pulse steroid therapy (Inj. Methylprednisolone) in view of severe inflammation and was changed to oral steroid. It showed a minimal response initially but the patient became symptomatic with total counts in decreasing trends. In view of persistent symptoms, active infective etiology, prior history of CLL, EBV, and multiple prolonged severe COVID-19 the patient was categorized as high-risk and was started on week 1 chemotherapy with Inj. Etoposide 200mg infusion (Day 1 and Day 2) and Tab. Dexamethasone 6mg - 4mg - 4mg (2 Days) after obtaining Informed consent from the patient.

Figure 1: Trend of Hematological parameters

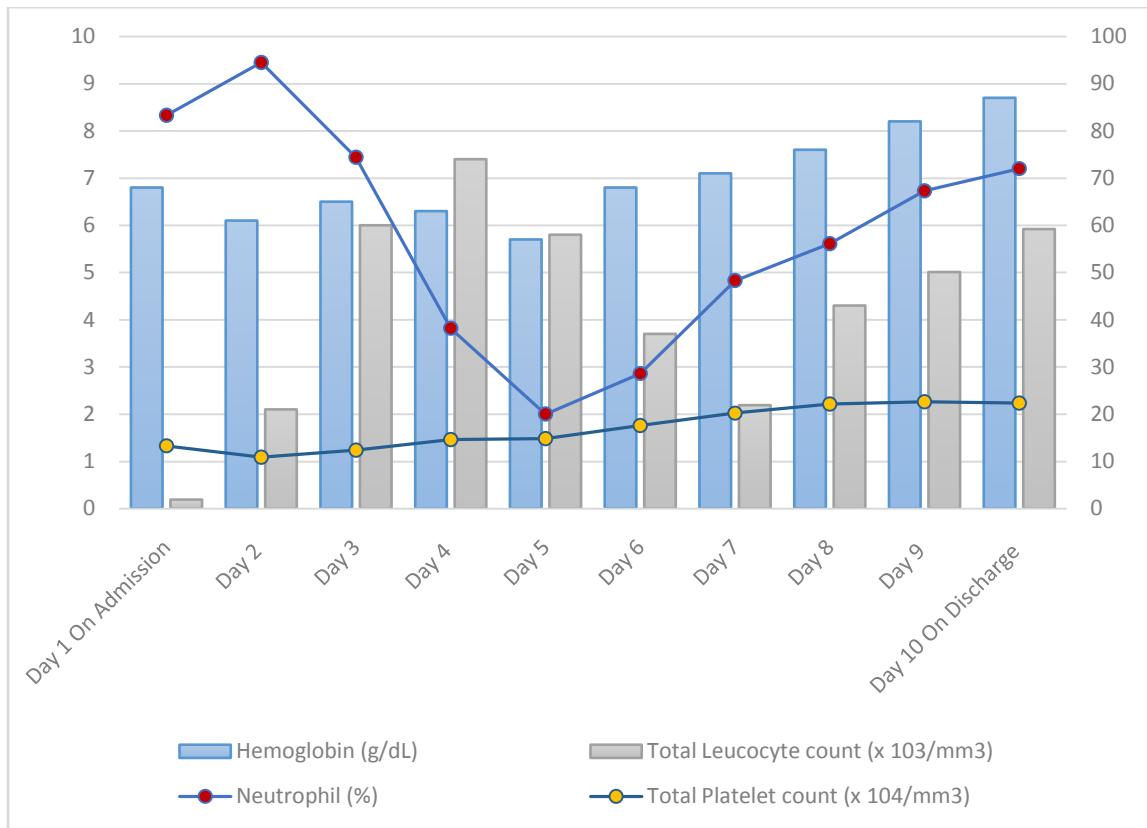


Figure 2: Trend of Ferritin

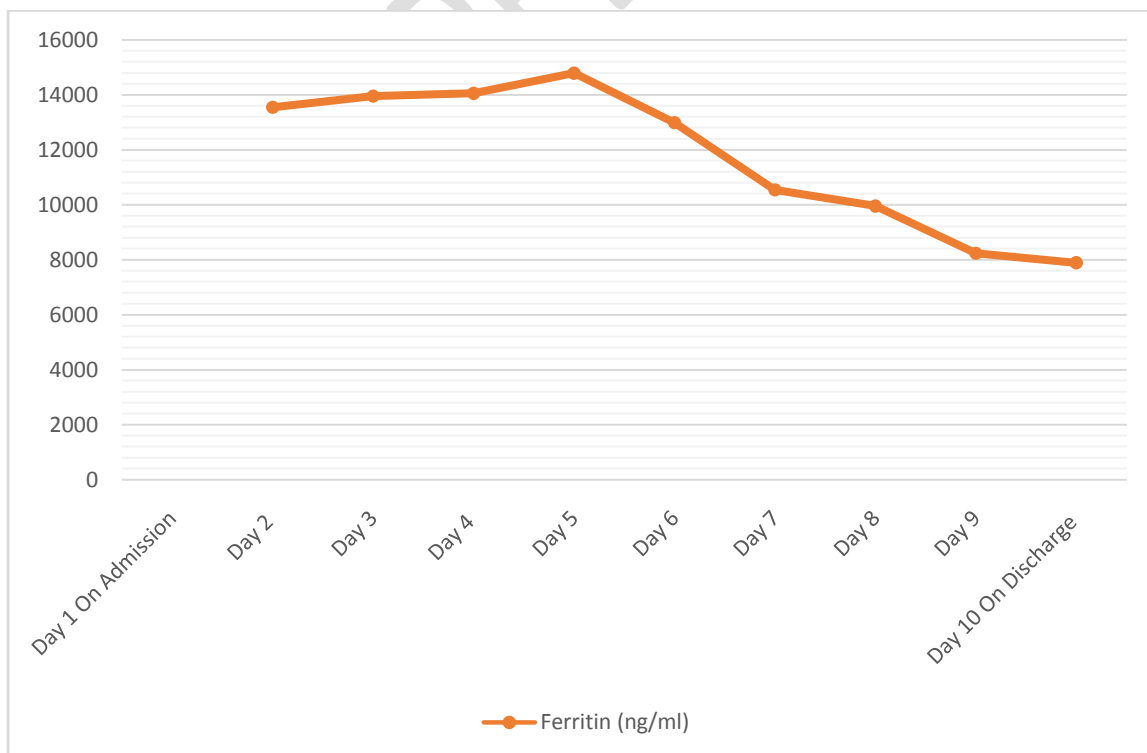


Figure 3: Trend of Triglyceride and Fibrinogen

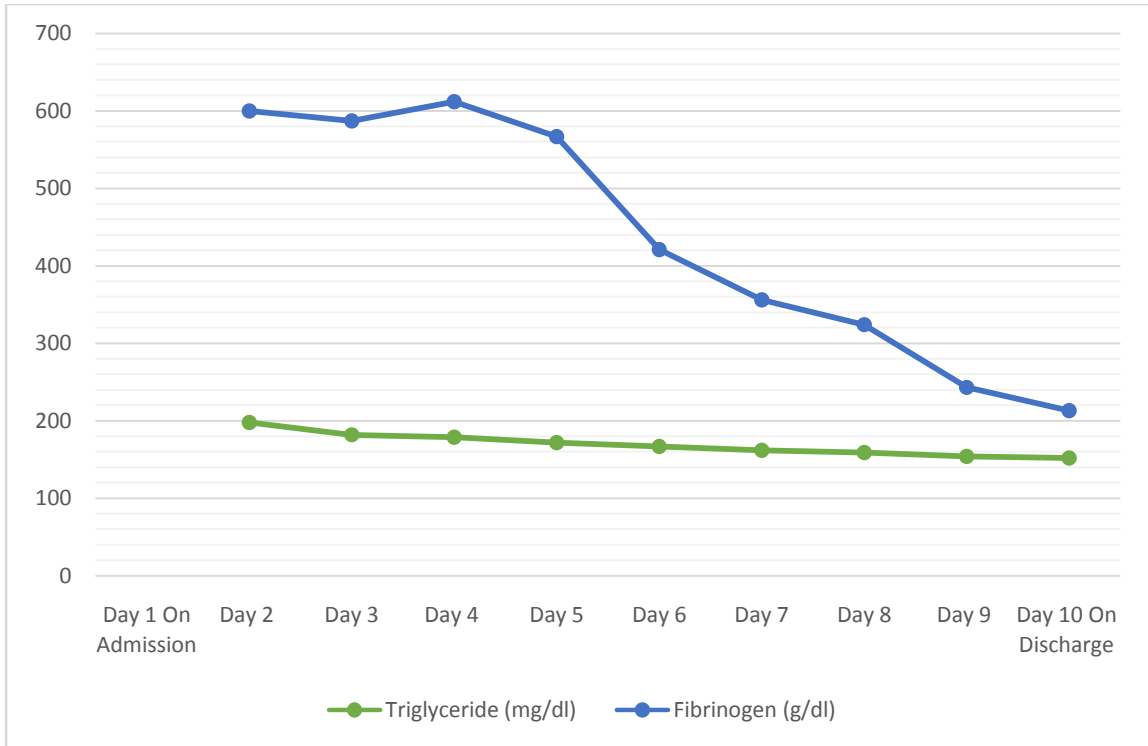
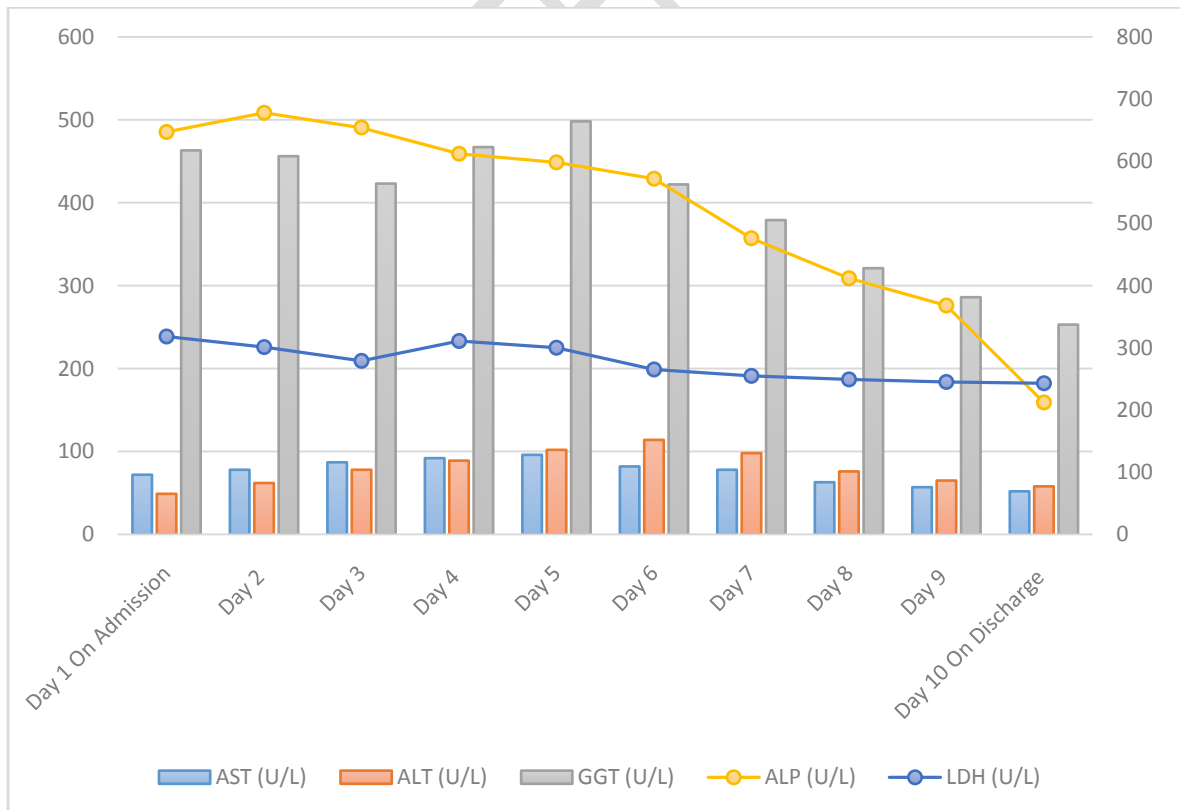


Figure 4: Trend of Hepatological parameters



The patient tolerated it well, his fever spikes settled and was clinically improved. Figure 1-4 displays the improving trend in the clinical course of the patient. The patient was discharged with Tab. Co-trimoxazole Double strength, Tab. Posaconazole 300mg, Tab. Valacyclovir 1gm, Tab. Dexamethasone 6mg - 4mg - 4mg and ATT drugs (Tab. Isoniazid 300mg, Tab. Levofloxacin 750mg, Tab. Pyridoxine 40 mg). Then he was advised to follow up in outpatient block with CBC reports and continuation of chemotherapy.

Discussion

“HLH is a highly detrimental syndrome characterized by a rapidly progressive clinical course and a high mortality rate, with a median survival of about two months. The disease is sporadic, with an incidence of about 1-2 cases per million in adults and a survival rate of <10% in the pre-immuno-chemotherapeutic era”.⁽⁸⁾

“The most common clinical manifestations include fever, hepatosplenomegaly, serous cavity effusion, and central nervous system (CNS) symptoms. Posterior reversible encephalopathy syndrome (PRES) is a possible neurological manifestation of HLH. Our patient had no clinical signs or symptoms of PRES, nor did they have any focal neurological deficits”.⁽⁹⁾

“With the progression of the disease, multiple organ infiltration by the activated T cells and macrophages occurs, ultimately leading to multiple organ damage”.⁽¹⁰⁾

The diagnosis is based on HLH-2004 diagnosis criteria in conjunction with clinical judgement and the patient’s history. The HLH-94 protocol proposed a standardized set of five diagnostic criteria for HLH. These were revised for the HLH-2004, and it was established that individuals need to meet five or more of the eight diagnostic criteria presented in Table 2.

Table 2 HLH-2004 Diagnostic Criteria ⁽¹¹⁾

If either condition A or condition B is true, the diagnosis of HLH can be made:

A. A molecular diagnostic that supports HLH

B. Any five out of the eight clinical and laboratory criteria for HLH listed below:

1. Fever ≥ 38.5 °C for ≥ 7 days

2. Splenomegaly ≥ 3 finger breadth below the left subcoastal margin

3. Cytopenias affecting about ≥ 2 of 3 lineages in peripheral blood

Hemoglobin < 9 g/dL

Neutrophils: $< 1.0 \times 10^9/L$

Platelets: $< 100 \times 10^9/L$

4. Hypertriglyceridemia and/or hypofibrinogenemia

Fasting triglycerides ≥ 265 mg/dL, fibrinogen ≤ 1.5 g/L

5. Hemophagocytosis in the lymph nodes, bone marrow, spleen, liver, or other tissues

6. Natural killer (NK) cell activity is either low or absent.

7. Ferritin concentration in serum ≥ 500 $\mu\text{g/L}$

8. Soluble CD25 (soluble IL-2 receptor) ≥ 2400 U/mL.

The diagnosis of HLH in our patient was based on the HLH-2004 criteria ^(12, 13) i.e., our patient presented seven out of eight criteria: persistent fever, cytopenia, hyperferritinemia, hyperfibrinogenaemia, altered liver enzymes, hypertriglyceridemia, CD68+ macrophages with active hemophagocytosis, diminished NK cell activity, and elevated soluble CD25.

Table 3 Parameters Included in the Adapted HLH-2004 Guidelines and H-Score and the Number of Points Associated with Each Criterion for Scoring

Parameter

H-Score

Known underlying	0 (no) or 18 (yes)
Immunosuppression*	
Temperature (°C)	0 (< 38.4), 33 (38.4 - 39.4), or 49 (> 39.4)
Organomegaly	0 (no), 23 (hepatomegaly or splenomegaly), or 38 (hepatomegaly and splenomegaly)
No. of cytopenias †	0 (1 lineage), 24 (2 lineages), or 34 (3 lineages)
Ferritin (mg/L)	0 (< 2000), 35 (2000 - 6000), or 50 (> 6000)
Triglyceride (mmol/L)	0 (<1.5), 44 (1.5 - 4), or 64 (> 4)
Fibrinogen (g/L)	0 (> 2.5) or 30 (≤ 2.5)
Aspartate aminotransferase (U/L)	0 (< 30) or 19 (≥ 30)
Hemophagocytosis on bone marrow aspirate	0 (no) or 35 (yes)

* *HIV positive or receiving long-term immunosuppressive therapy (i.e., glucocorticoids, cyclosporine A, azathioprine).*

† *Defined as a hemoglobin level of 9.2 g/L and/or a leukocyte count #5 3 10⁹/L and/or a platelet count #110 3 10⁹/L.*

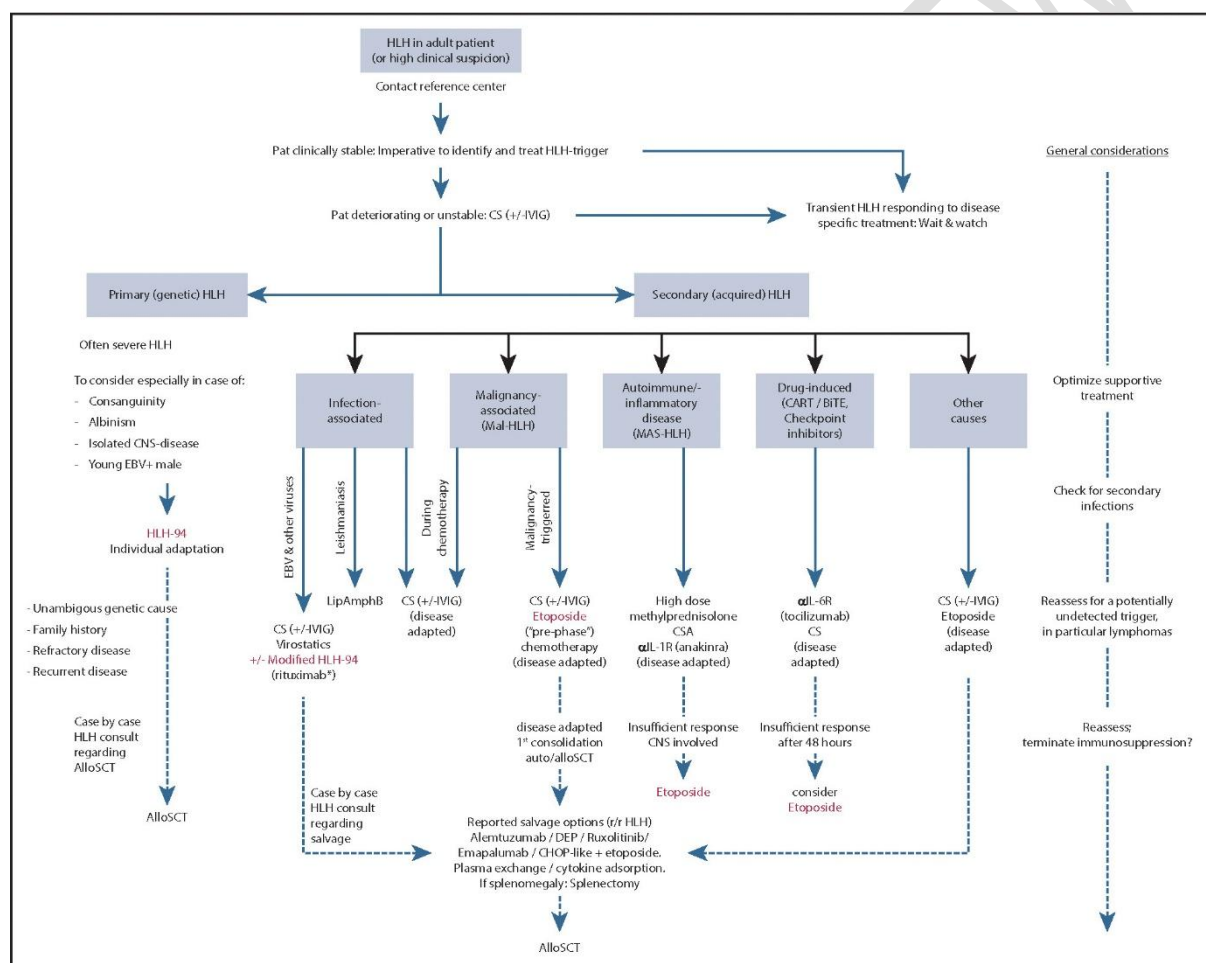
Our patient's H-score for reactive hemophagocytic syndrome was 246 points, which indicates that the probability of hemophagocytic syndrome was greater than 99%.

The HLH-94 pediatric treatment protocol is the generally accepted cornerstone treatment for infants, toddlers, and children up to the age of 18. Allogeneic hematopoietic stem cell

transplantation (alloSCT) can treat primary HLH and is an option for consolidation therapy or relapsed HLH following successful salvage therapy in patients with high-risk hematologic malignancies.

Treatment in adults cannot be standardized and requires individualized care according to the underlying issues and triggers that resulted in HLH (infection, malignancy, autoimmune/autoinflammatory, drug-induced, and other causes).

Figure 5 Treatment algorithm for patients with HLH

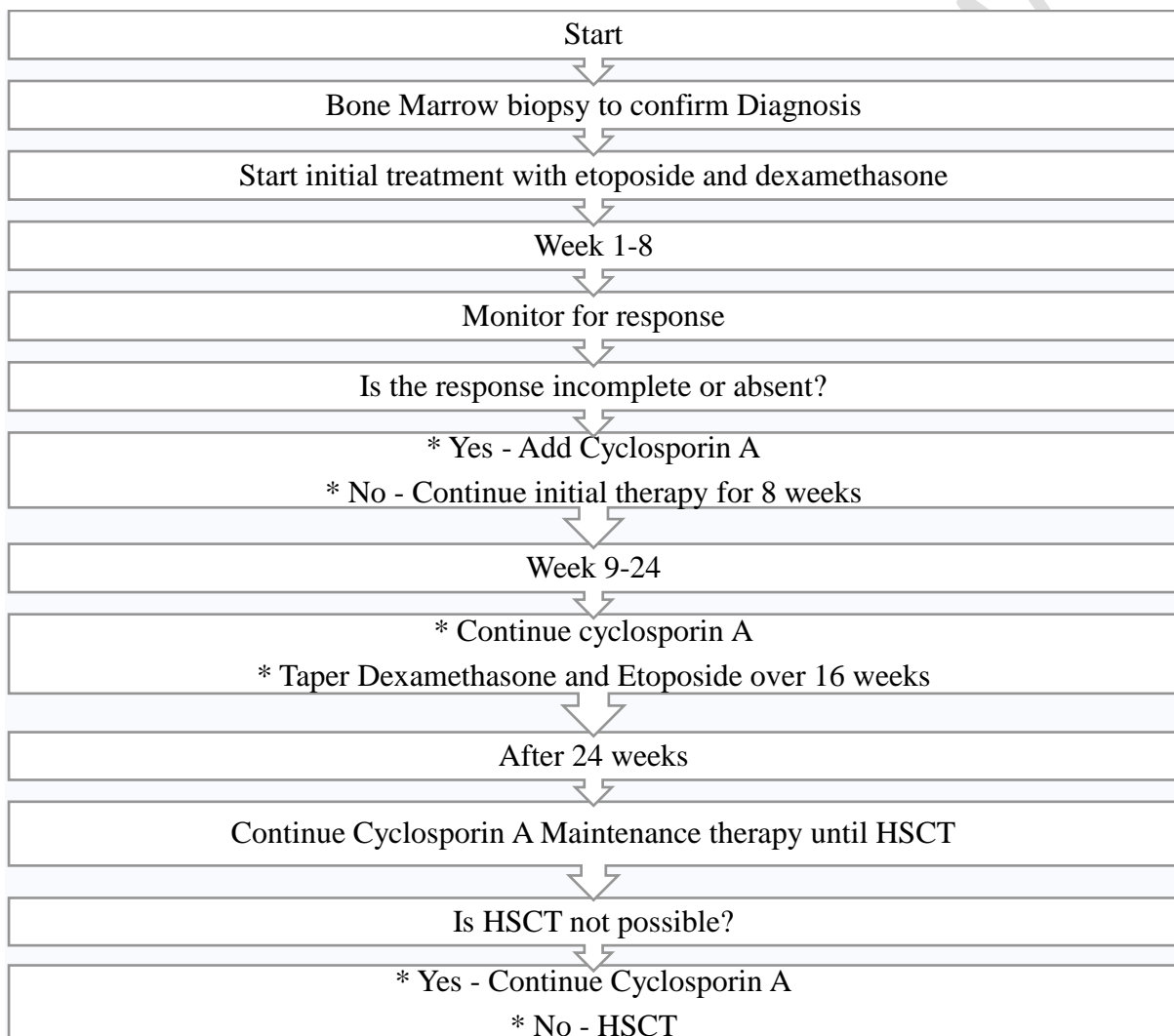


Adapted from # <https://www.sciencedirect.com/science/article/pii/S0006497120425005>

According to the HLH 2004 treatment protocol, the duration of treatment for HLH depends on the patient's response to therapy and the underlying cause of the disease. Patients with familial HLH typically require lifelong therapy. Patients with secondary HLH may be able to discontinue therapy once the underlying cause is treated.

The HLH-94 protocol consists of eight weeks of induction therapy with dexamethasone and etoposide, followed by eight weeks of continuous therapy with dexamethasone, etoposide, and cyclosporine, which is appropriate in the case of disease relapse or primary HLH. Cyclosporine was encouraged to be included during the induction phase of the procedure when it was amended in 2004. (11, 13,14)

Figure 6 Flowchart outlining the course of therapy



In this clinical scenario, our patient was initiated on chemotherapy with etoposide and dexamethasone according to protocol. Patrik A. Thompson et al. (15) reported that the treatment with cyclosporine for HLH can cause significant central nervous system (CNS) toxicity, elevated blood pressure (BP), and worsening renal and hepatic function. This risk

can be minimized by avoiding unnecessary use of cyclosporine and by carefully monitoring patients for response. In view of good tolerability and improvement in clinical signs, including TLC and ferritin levels, and other parameters, cyclosporine was not added to induction therapy.

Conclusion

Hemophagocytic lymphohistiocytosis is an acute hyperinflammatory disease associated with a high mortality rate and poor prognosis. So, we would like to emphasize the challenges of diagnosing and managing HLH, especially in elderly and frail patients. The physicians must possess a reasonable index of suspicion for HLH in any patients with fever, pancytopenia, high ferritin levels, or low fibrinogen levels. Management requires rapid diagnosis using a multidisciplinary strategy, including chemotherapy, immunosuppression, supportive care, and therapy for the underlying causes. Diagnostic criteria and treatment protocols specific to adult hemophagocytic syndrome (HPS) have not been established and are often extrapolated from the Histiocyte Society's HLH-94 or 2004 pediatric protocols. Several described manifestations of adult HPS, such as transaminitis, coagulopathy, elevated LDH, rash, hyponatremia, elevated CRP, and neurologic involvement, are not included in these criteria. It is unclear how well these therapy regimens work for adults. Priorities for future research include the development of diagnostic criteria and treatment protocols that accommodate those disease aspects unique to adults.

Consent

Written informed consent was obtained from the patient regarding the publishing of his anonymized clinical and Para clinical data in the current study.

Ethical Approval

As per international standards or university standards written ethical approval has been collected and preserved by the author(s).

Reference

1. Konkol S, Rai M. Lymphohistiocytosis [Internet]. PubMed. Treasure Island (FL): StatPearls Publishing; 2023 [cited 2023 Sep 6]. Available from: <https://pubmed.ncbi.nlm.nih.gov/32491708/>
2. Hayden A, Park S, Giustini D, Lee AYY, Chen LYC. Hemophagocytic syndromes (HPSs) including hemophagocytic lymphohistiocytosis (HLH) in adults: A systematic scoping review. *Blood Reviews*. 2016 Nov;30(6):411–20.
3. George M. Hemophagocytic lymphohistiocytosis: review of etiologies and management. *Journal of Blood Medicine* [Internet]. 2014 Jun;5:69. Available from: <https://www.ncbi.nlm.nih.gov/pmc/articles/PMC4062561/>
4. Bami S, Vagreacha A, Soberman D, Badawi M, Cannone D, Lipton JM, et al. The use of anakinra in the treatment of secondary hemophagocytic lymphohistiocytosis. *Pediatric Blood & Cancer*. 2020 Jul 29;67(11).
5. Acharya S, Shukla S, Sontakke T, VS I, Bagga C, Dronamraju S, et al. A Case Report of Hemophagocytic Lymphohistiocytosis (HLH) - An Unusual Complication of Dengue Infection. *Cureus*. 2022 Jul 1;14(6).
6. Swe Swe Hlaing, Christine Jane Kurian, Tan J, Behling E, Kamel A. Case Report: A unique case of secondary hemophagocytic lymphohistiocytosis from ehrlichiosis infection. *Frontiers in Hematology*. 2022 Dec 19;1.
7. Diaz L, Jauzelon B, Dillies AC, Le Souder C, Faillie JL, Maria ATJ, et al. Hemophagocytic Lymphohistiocytosis Associated with Immunological Checkpoint Inhibitors: A Pharmacovigilance Study. *Journal of Clinical Medicine* [Internet]. 2023 Jan 1 [cited 2023 Sep 21];12(5):1985. Available from: <https://www.mdpi.com/2077-0383/12/5/1985#:~:text=Drug%2Dinduced%20HLH%20have%20been>

8. Okobi TJ, Cautha S, Bhatt T, Atogwe ID, Schmidt P, Patel D, et al. Hemophagocytic Lymphohistiocytosis and Hodgkin Lymphoma in a Newly Diagnosed HIV Patient: A Diagnostic Dilemma. *Cureus* [Internet]. 2023 Jun 29 [cited 2023 Sep 6];15(6). Available from: https://assets.cureus.com/uploads/case_report/pdf/158553/20230729-12689-1idujk0.pdf
9. Lee G, Seung Eun Lee, Kyung Ha Ryu, Eun Sun Yoo. Posterior reversible encephalopathy syndrome in pediatric patients undergoing treatment for hemophagocytic lymphohistiocytosis: clinical outcomes and putative risk factors. 2013 Jan 1;48(4):258–8.
10. Jancar N, Sousa Gonçalves F, Duro JF, Aguiar P, Jacinto Correia C. Hemophagocytic Lymphohistiocytosis Secondary to Chronic Lymphocytic Leukemia Progression. *Cureus*. 2023 Jan 24;15(1).
11. Zhang K, Astigarraga I, Bryceson Y, Lehmborg K, Machowicz R, Marsh R, et al. Table 1. [HLH-2004 Diagnostic Criteria]. [Internet]. www.ncbi.nlm.nih.gov. 2021. Available from: https://www.ncbi.nlm.nih.gov/books/NBK1444/table/hlh.T.hlh2004_diagnostic_criteria/
12. Henter JI, Horne A, Aricó M, Egeler RM, Filipovich AH, Imashuku S, et al. HLH-2004: Diagnostic and therapeutic guidelines for hemophagocytic lymphohistiocytosis. *Pediatric blood & cancer* [Internet]. 2007;48(2):124–31. Available from: <https://www.ncbi.nlm.nih.gov/pubmed/16937360>
13. Schram AM, Berliner N. How I treat hemophagocytic lymphohistiocytosis in the adult patient. *Blood*. 2015 May 7;125(19):2908–14.
14. La Rosée P, Horne A, Hines M, von Bahr Greenwood T, Machowicz R, Berliner N, et al. Recommendations for the management of hemophagocytic lymphohistiocytosis in adults. *Blood* [Internet]. 2019 Jun 6;133(23):2465–77. Available from: <https://ashpublications.org/blood/article/133/23/2465/273833/Recommendations-for-the-management-of>

15. Thompson PA, Allen CE, Horton TM, Jones J, Vinks AA, McClain KL. Severe neurologic side effects in patients being treated for hemophagocytic lymphohistiocytosis. *Pediatric Blood & Cancer* [Internet]. 2009 May 1 [cited 2023 Sep 21];52(5):621–5. Available from: <https://www.ncbi.nlm.nih.gov/pmc/articles/PMC3660724/>

UNDER PEER REVIEW