

### **Two Swords in the Storm: Parvovirus B19 and COVID-19 Clash in a Myocardial Mayhem of Arrhythmias**

#### **Abstract**

Myocarditis can be caused by a variety of infectious and non-infectious illnesses [1]. Although viral infection remains the most commonly identified cause of myocarditis, the role of parvovirus B19 (B19V) from the Erythrovirus genus in the pathogenesis of myocarditis has been identified as a potentially important contributor to myocarditis because of the high prevalence of Parvovirus B 19 (B19V) DNA in hearts of patients with myocarditis [2]. Co-infections of cardiotropic viruses are rarely reported and the mechanisms of viral interactions remain unknown [3]. In this report, we present a case of acute myocarditis in a young male, precipitated by a co-infection of Parvovirus B19 and COVID-19, characterized by fulminant progression and the development of multiple arrhythmias.

#### **Introduction**

Myocarditis refers to any inflammation of the myocardium. Inflammation can be found after any form of injury to the heart, including ischemic damage, mechanical trauma, and genetic cardiomyopathies.

Classic myocarditis refers to inflammation of the heart muscle occurring because of exposure to either discrete external antigens, such as viruses, bacteria, parasites, toxins, or drugs, or internal triggers, such as autoimmune activation against self-antigens. Although viral infection remains the most commonly identified cause of myocarditis, drug hypersensitivity and toxic drug reactions, other infections, and peripartum cardiomyopathy also can lead to myocarditis.

Clinical myocarditis often is self-limited. In many cases the virus is cleared successfully, and the immune response is down modulated. In some patients, however, an autoimmune reaction to endogenous antigens lingers beyond this phase and can cause persistent cardiac dysfunction. Sometimes viral genomes persist in the heart with or without acute inflammation [4].

#### **Case presentation**

A 27 year old male, a manual labourer by occupation presented to the emergency department (ED) with fever and chills for 4 days, giddiness for 2 days and Chest pain for last 2 days.

Patient was alright 4 days back, when he suddenly developed high grade fever with chills for which he was admitted and treated . On the second day of treatment, he developed sudden onset dyspnoea with chest pain and collapsed. CPR was started and intubation done and patient was mechanically ventilated. BP was non-recordable , ECG was suggestive of Complete heart block (CHB) for which Temporary pacemaker was inserted immediately and inotrope started. Patient

was stabilized and extubated after 24 hours, maintained with oxygen delivery via nasal prongs at 4 litre per minutes for the next 24 hours and weaned off gradually over next 3 days.

On the fourth day of the ICCU stay, patient collapsed again. ECG done was suggestive of ventricular tachycardia which was reverted with 50 joules of DC shock. Patient was monitored vigilantly in the ICCU, and stabilized with Amiodarone drip for 24 hours.

Patient received standard care for myocarditis (Inotropes, Antibiotics, Methylprednisolone pulse therapy, Diuretics). Echocardiography was performed which revealed global Left ventricular hypokinesia with an ejection fraction of 30%. A Cardiac MRI was done after stabilisation which revealed the anteroseptal segments along apex, mid cavity and base appearing to be thinned out and hypokinetic. Apico-inferior, mid inferior, basal inferior, mid inferior septal, basal inferior septal segments also appeared hypokinetic. Left ventricular internal diastolic diameter was 54mm. Delayed subepicardial and mid myocardial enhancement was seen in the septum more towards base which was suggestive of fibrosis secondary to myocarditis[Figure 1 and 2].

Cardiac biopsy was done which revealed occasional foci of interstitial inflammatory infiltrated, which were suggestive of myocarditis. A viral myocarditis multiplex PCR profile detected Parvovirus B19. Patient's chest radiograph had features suggestive of an atypical pneumonia. A nasopharyngeal swab RTPCR turned out to be positive for COVID-19.

Patient was taken for coronary angiography which turned out to be normal. [Figure 3, 4 and 5]In view of recurrent hemodynamically unstable ventricular tachycardia, Implantable Cardioverter Defibrillator (ICD) was implanted. Guideline directed medical therapy started for Heart Failure with Reduced Ejection Fraction. Patient improved clinically and was discharged, and was asked to follow up regular.

Patient went into ventricular tachycardia twice within one month of discharge, which was defibrillated by the ICD. Echocardiography after 3 months of discharge showed increase in Left ventricular ejection fraction to 50%.

Table 1 : Pathological test result

Leucocyte Count (per mm <sup>3</sup> )	13,726	4,000 – 11,000
Creatinine (mg/dL)	1.3	0.4 – 1.4
CKMB (ng/mL)	11.5	0 – 4.9
CRP (mg/dL)	45	< 0.3
Troponin I (ng/mL)	5.68	0 – 0.04
D Dimer (ng/mL)	473	0 – 225
Myoglobin (ng/mL)	133	25 – 72
BNP (pg/mL)	338	< 100

## Discussion

Patients with myocarditis present with nonspecific symptoms related to the heart. Patients with clinically suspected myocarditis, the most common symptoms included fatigue (82%), dyspnoea on exertion (81%), arrhythmias (55%, both supraventricular and ventricular), palpitations (49%), and chest pain at rest (26%). These can be difficult to distinguish from acute ischemic syndromes because they result in release of troponin, ST-segment elevation on electrocardiography, and segmental wall motion abnormalities on echocardiography. Therefore, the symptoms can be quite nonspecific, although some symptoms indicate cardiac involvement. Fulminant myocarditis might be associated with a PVB19 infection because myocardial endothelial cells have been described as target cells of a PVB19 infection[5]. Approximately 10% of patients with biopsy-proven myocarditis display fulminant myocarditis. This entity is characterized by an abrupt onset, usually within 2 weeks of a viral illness. Patients have hemodynamic compromise and hypotension, often requiring vasopressors or mechanical support like in our case[6].

After carefully ruling out usual aetiologies of myocarditis such as common viruses, bacteria, autoimmune disease, giant cells, and hypereosinophilic syndrome, we hypothesized that SARS-CoV-2-mediated systemic inflammation could be the cause of this acute cardiac inflammatory response[7]. In patients with definite myocarditis, viral genomes may or may not be detected by molecular techniques (mainly polymerase chain reaction [PCR])[8]. Co-infections of cardiotropic viruses are rarely reported and the mechanisms of viral interactions remain unknown. Distinction between active viral infection in target organs and a bystander virus requires quantification of genomic viral load in frozen samples[3].

Our case raises the issue of the interaction of PVB19 and SARS-CoV-2 viruses in causing pneumonia and myocarditis. There may be possibility of reactivation of Parvovirus B 19 during COVID-19 infection. Immunosuppression or modulation are known to be the main factors of PVB19 reactivation[9,10].

Parvoviruses are small, non-enveloped viruses with single-stranded DNA that has approximately 5000 nucleotides [11]. Transmission is predominantly by respiratory secretions but can occur through blood transfusion. Adults typically present with arthralgia and possibly a macular rash. [12]. Chronic infection can occur, especially in immunocompromised patients. Positive IgG serology does not necessarily mean protection[13].

Parvovirus B19 infection is common throughout the world. The percentage of people with measurable levels of parvovirus B19-specific IgG increases with increasing age, with most individuals becoming infected during their school years. During school outbreaks, 25 to 50 percent of students and 20 percent or more of susceptible staff may become infected. Between 50 to 80 percent of adults have measurable parvovirus B19-specific IgG antibodies[14, 15]. Similarly to most DNA viruses, parvovirus B19 reactivation is possible in immunocompromised patients. Secondary symptomatic parvovirus B19 infection in the same patient is rare and its physiopathology is not always clear. Numerous COVID-19 case reports have described findings consistent with a diagnosis of "clinically suspected myocarditis", but there have been few cases of histologically confirmed myocarditis, and viral myocarditis caused

directly by SARS-CoV-2 has not been definitively confirmed[17, 18, 19, 20, 21, 22, 23,24, 25, 26, 27, 28].Detection of viral genome on EMB specimen may suggest a cause in the presence of histologic evidence of myocarditis. However, viral culture of myocardial samples for viruses is rarely successful[29].

Myocarditis and pericarditis, mainly in male adolescents and young adults, have been reported more frequently than expected following receipt of the mRNA vaccines, Pfizer COVID-19 vaccine and Moderna COVID-19 vaccine[30, 31].Cases were also noted in Novavax COVID-19 vaccine (a sub unit vaccine containing a purified recombinant spike (S) antigen of the SARS-CoV-2 virus)recipients during the phase III trials[32].Surveillance has also suggested a possible increased risk following receipt of Janssen/Johnson & Johnson COVID-19 vaccine. The adenovirus vector in the vaccine is a recombinant, replication-incompetent adenovirus vector that expresses the SARS-CoV-2 spike (S) antigen without virus propagation[33].

Given the occurrence of Parvovirus B19 and the possibility for infections to resurface during times of stress, such as in the case of COVID-19 infections, it is plausible that our patient experienced a reactivation of Parvovirus B19 due to COVID 19 pneumonia. To improve accuracy it is advisable to conduct both a Parvovirus B19 PCR and a COVID-19 RTPCR using the tissue sample from an endomyocardial biopsy. Further research is crucial in identifying the agent in cases of myocarditis among patients with co infections.

Considering the documented cases of myocarditis following COVID vaccination and the uncertainty surrounding its mechanism as well, as the lack of conclusive studies linking viral myocarditis to SARS CoV 2 it is important to investigate whether Parvovirus B19 reactivation could potentially explain myocarditis induced by COVID vaccination.

## **Conclusion**

Although it reports that the incidence of fulminant myocarditis in Parvovirus B19 is rare, but in this case, co-infection presented as severe fulminant myocarditis with episode of Cardiac arrest, which required immunosuppression, medical management and ICD.

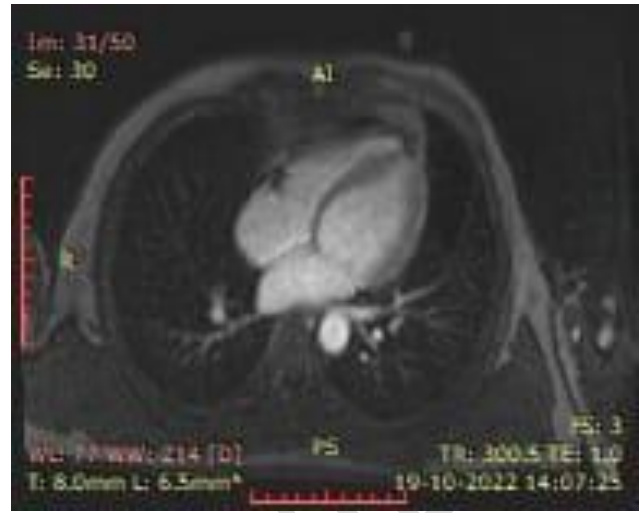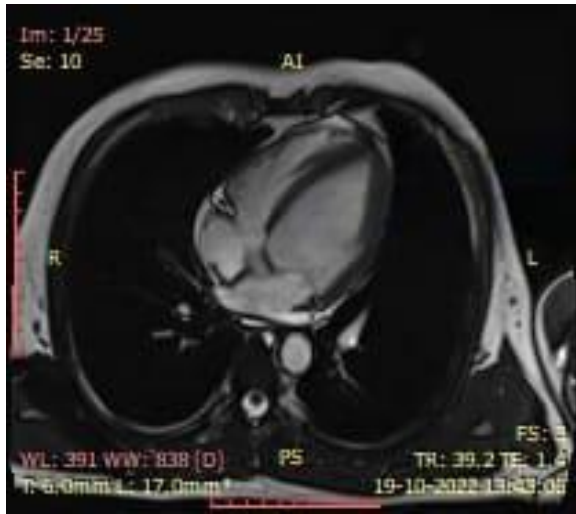


Figure 1 Figure 2

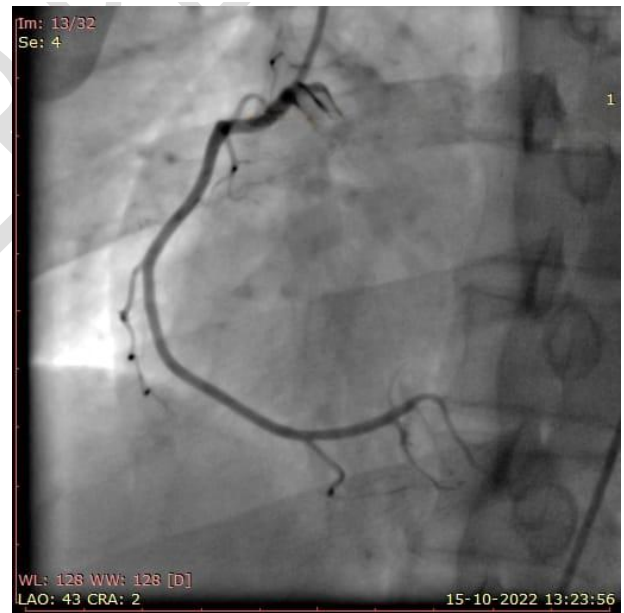
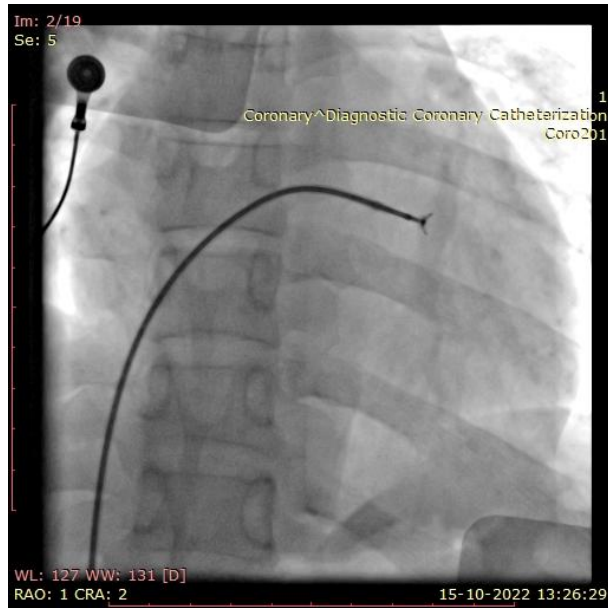


Figure 3 Figure 4

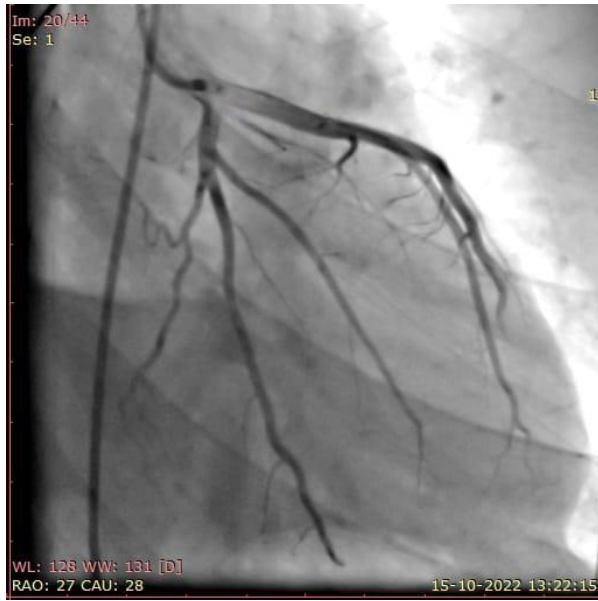


Figure 1-5. Scan report of patients (cases of myocarditis)

## Abbreviations

B19V: Parvovirus B19

COVID-19: Coronavirus Disease 2019

ICCU: Intensive Cardiac Care Unit

ECG: Electrocardiography

CHB: Complete Heart Block

PCR: Polymerase Chain Reaction

ICD: Implantable Cardioverter Defibrillator

CRP: C-Reactive Protein

SARS-CoV-2: Severe Acute Respiratory Syndrome Coronavirus 2

DNA : Deoxy-ribo Nucleic Acid

## References

1. Caforio AL, Pankuweit S, Arbustini E, Basso C, Gimeno-Blanes J, Felix SB, Fu M, Heliö T, Heymans S, Jahns R, Klingel K, Linhart A, Maisch B, McKenna W, Mogensen J, Pinto YM, Ristic A, Schultheiss HP, Seegewiss H, Tavazzi L, Thiene G, Yilmaz A, Charron P, Elliott PM; European Society of Cardiology Working Group on Myocardial and Pericardial Diseases. Current state of knowledge on aetiology, diagnosis, management, and therapy of myocarditis: a position statement of the European Society of Cardiology Working Group on Myocardial and Pericardial Diseases. *Eur Heart J*. 2013 Sep;34(33):2636-48, 2648a-2648d. doi: 10.1093/eurheartj/eh210. Epub 2013 Jul 3. PMID: 23824828.

2. Braunwald's Heart Disease Textbook of Cardiovascular Medicine, 13th edition, Page number 1078.
3. Bock C.-T., Klingel K., Kandolf R. Human Parvovirus B19-Associated Myocarditis. *N. Engl. J. Med.* 2010;362:1248–1249. doi: 10.1056/NEJMc0911362.
4. Braunwald's Heart Disease Textbook of Cardiovascular Medicine, 13th edition, Page number 1077.
5. Escher F, Kuhl U, Sabi I, et al. Immunohistological detection of parvovirus B19 capsid proteins in endomyocardial biopsies from dilated cardiomyopathy patients. *Med Sci Monit* 2008; 14:CR333-CR338.
6. Schultheiss HP, Kuhl U, Cooper LT. The management of myocarditis. *Eur Heart J.* 2011; 32:2616–2625.
7. Sala S, Peretto G, Gramegna M, Palmisano A, Villatore A, Vignale D, de Cobelli F, Tresoldi M, Cappelletti AM, Basso C, Godino C, Esposito A. Acute myocarditis presenting as a reverse Tako-Tsubo syndrome in a patient with SARS-CoV-2 respiratory infection. *Eur Heart J* 2020; 41: 1861–1862.
8. Tschöpe C, Ammirati E, Bozkurt B, Caforio ALP, Cooper LT, Felix SB, Hare JM, Heidecker B, Heymans S, Hübner N, Kelle S, Klingel K, Maatz H, Parwani AS, Spillmann F, Starling RC, Tsutsui H, Seferovic P, Van Linthout S. Myocarditis and inflammatory cardiomyopathy: current evidence and future directions. *Nat Rev Cardiol.* 2021 Mar;18(3):169-193. doi: 10.1038/s41569-020-00435-x. Epub 2020 Oct 12. PMID: 33046850; PMCID: PMC7548534.
9. Karrasch M., Felber J., Keller P.M., Kletta C., Egerer R., Bohnert J., Hermann B., Pfister W., Theis B., Petersen I., et al. Primary Epstein-Barr Virus Infection and Probable Parvovirus B19 Reactivation Resulting in Fulminant Hepatitis and Fulfilling Five of Eight Criteria for Hemophagocytic Lymphohistiocytosis. *Int. J. Infect. Dis.* 2014;28:143–146. Doi: 10.1016/j.ijid.2014.08.003.
10. Shehi E, Ghazanfar H, Fortuzi K, Gonzalez E, Zeana C. A Rare Case of Parvovirus B19 Infection Manifesting as Chronic Aplastic Anemia and Neutropenia in a Human Immunodeficiency Virus-Infected Patient. *Cureus.* 2020;12:e12174. doi: 10.7759/cureus.12174.

11. Ganaie SS, Qiu J. Recent advances in replication and infection of human parvovirus B19. *Front Cell Infect Microbiol.* 2018; 8:166.
12. Yu MY, Alter HJ, Virata-Theimer ML, et al. Parvovirus B19 infection transmitted by transfusion of red blood cells confirmed by molecular analysis of linked donor and recipient samples. *Transfusion.* 2010; 50:1712–1721.
13. Marano G, Vaglio S, Pupella S, et al. Human Parvovirus B19 and blood product safety: a tale of twenty years of improvements. *Blood Transfus.* 2015; 13:184–196. [PMC free article]
14. Cohen BJ, Buckley MM. The prevalence of antibody to human parvovirus B19 in England and Wales. *J Med Microbiol.* 1988 Feb;25(2):151-3. Doi: 10.1099/00222615-25-2-151. PMID: 3339634.
15. Kerr S, O'Keefe G, Kilty C, Doyle S. Undenatured parvovirus B19 antigens are essential for the accurate detection of parvovirus B19 IgG. *J Med Virol.* 1999 Feb;57(2):179-85. doi: 10.1002/(sici)1096-9071(199902)57:2<179::aid-jmv16>3.0.co;2-t. PMID: 9892405
16. Sterpu R, Ichou H, Mahé I, Mortier E. Réactivation d'une infection à parvovirus B19 chez une patiente infectée par le VIH [Reactivation of parvovirus B19 infection in an HIV-infected woman]. *Rev Med Interne.* 2014 Jun;35(6):396-8. French. Doi: 10.1016/j.revmed.2013.05.009. Epub 2013 Jun 20. PMID: 23791089.
17. [Inciardi RM, Lupi L, Zaccone G, et al. Cardiac Involvement in a Patient With Coronavirus Disease 2019 \(COVID-19\). \*JAMA Cardiol\* 2020; 5:819.](#)
18. Zeng JH, Liu YX, Yuan J, et al. First case of COVID-19 complicated with fulminant myocarditis: a case report and insights. *Infection* 2020; 48:773.
19. [Hu H, Ma F, Wei X, Fang Y. Coronavirus fulminant myocarditis treated with glucocorticoid and human immunoglobulin. \*Eur Heart J\* 2021; 42:206.](#)



20. [Fried JA, Ramasubbu K, Bhatt R, et al. The Variety of Cardiovascular Presentations of COVID-19. Circulation 2020; 141:1930.](#)
21. [Tavazzi G, Pellegrini C, Maurelli M, et al. Myocardial localization of coronavirus in COVID-19 cardiogenic shock. Eur J Heart Fail 2020; 22:911.](#)
22. [Kim IC, Kim JY, Kim HA, Han S. COVID-19-related myocarditis in a 21-year-old female patient. Eur Heart J 2020; 41:1859.](#)
23. [Daniels CJ, Rajpal S, Greenshields JT, et al. Prevalence of Clinical and Subclinical Myocarditis in Competitive Athletes With Recent SARS-CoV-2 Infection: Results From the Big Ten COVID-19 Cardiac Registry. JAMA Cardiol 2021; 6:1078.](#)
24. [Escher F, Pietsch H, Aleshcheva G, et al. Detection of viral SARS-CoV-2 genomes and histopathological changes in endomyocardial biopsies. ESC Heart Fail 2020; 7:2440.](#)
25. [Salah HM, Mehta JL. Takotsubo cardiomyopathy and COVID-19 infection. Eur Heart J Cardiovasc Imaging 2020; 21:1299.](#)
26. [Nicol M, Cacoub L, Baudet M, et al. Delayed acute myocarditis and COVID-19-related multisystem inflammatory syndrome. ESC Heart Fail 2020; 7:4371.](#)
27. [Caforio ALP, Baritussio A, Basso C, Marcolongo R. Clinically Suspected and Biopsy-Proven Myocarditis Temporally Associated with SARS-CoV-2 Infection. Annu Rev Med 2022; 73:149.](#)
28. Kawakami R, Sakamoto A, Kawai K, et al. Pathological Evidence for SARS-CoV-2 as a Cause of Myocarditis: JACC Review Topic of the Week. J Am Coll Cardiol 2021; 77:314.
29. Caforio AL, Pankuweit S, Arbustini E, Basso C, Gimeno-Blanes J, Felix SB, Fu M, Heliö T, Heymans S, Jahns R, Klingel K, Linhart A, Maisch B, McKenna W, Mogensen J, Pinto YM, Ristic A, Schultheiss HP, Seggewiss H, Tavazzi L, Thiene G, Yilmaz A, Charron P, Elliott PM; European Society of Cardiology Working Group on Myocardial and Pericardial Diseases. Current state of knowledge on aetiology, diagnosis, management, and therapy of myocarditis: a position statement of the European Society of Cardiology Working Group on Myocardial and Pericardial Diseases. Eur Heart J. 2013 Sep;34(33):2636-48, 2648a-2648d. doi: 10.1093/eurheartj/ehs210. Epub 2013 Jul 3. PMID: 23824828.
30. Meeting highlights from the Pharmacovigilance Risk Assessment Committee (PRAC) 3-6 May 2021 [Internet]. Available from: <https://www.ema.europa.eu/en/news/meeting-highlights>

lights-pharmacovigilance-risk-assessment-committee-prac-3-6-may-2021 (Accessed on May 26, 2021).

31. Gargano JW, Wallace M, Hadler SC, et al. Use of mRNA COVID-19 Vaccine After Reports of Myocarditis Among Vaccine Recipients: Update from the Advisory Committee on Immunization Practices - United States, June 2021. *MMWR Morb Mortal Wkly Rep* 2021; 70:977.
32. Vaccines and Related Biological Products Advisory Committee Meeting. FDA Briefing Document: Novavax COVID-19 Vaccine. June 7, 2022. Available from: <https://www.fda.gov/media/158912/download> (Accessed on June 16, 2022).
33. US Food and Drug Administration. Emergency use authorization (EUA) of the Janssen COVID-19 vaccine to prevent coronavirus disease 2019 (COVID-19). Available from: <https://www.fda.gov/media/146304/download> (Accessed on March 27, 2023).