

Original Research Article

New species of genus *Eimeria*(*Eimeria tarabaie*) in broiler chicken from Aurangabad Maharashtra state India

ABSTRACT:

Chicken coccidiosis cause huge economic loss in poultry industry. Genus *Eimeria* from phylum Apicomplexa shows extensive damage in poultry industry. In our investigation ten species of *Eimeria* was recorded among seven was previously recorded from various parts of the world. Three new species of *Eimeria* were recorded from Aurangabad district of Maharashtra. *Eimeria tarabai* is one of the species recorded as a new species due to its distinctness.

KEY WORDS: -Broiler Chicken, Coccidia, *Eimeria Sp.*

INTRODUCTION:-

Coccidiosis among commercial broiler poultry cause huge destruction and great economic loss. Study of such parasite is one of the challenge among veterinary and parasitologist and it is kind of addition to science. [1]Study of intestinal protozoan parasites and disease caused by *Eimeria* are studied all over world.[33]Now a day, billions of chicken produced annually and growth of poultry industry play a crucial role in fulfillment of food need of growing population of the world. For many years, anticoccidial feed and drugs has been a primary means of the controlling coccidiosis among poultry. now a day, many anticoccidial drugs and vaccines come in the market control the threat of coccidia in some instance. But total eradication of this disease is quite impossible due to lot of environmental conditions and microscopic nature of parasites. So, study of such medically important species is must for science.[1]. Since 17th century work on Coccidiosis is carried out by number of researchers. [2][4] [5] [8] [10] [11] [14] [23] [24][31] [32]. My research investigation work covers survey and species identification of coccidia i.e. various species of genus *Eimeria* from chicken.

MATERIAL AND METHODS:-

Chicken intestine were obtained from various slaughter shops of different tehsil of Aurangabad district. Various parts of chicken intestine were examined for coccidial infection in Protozoa laboratory of department of Zoology Dr. BAMU Aurangabad every day after collection.

The fecal materials from chicken intestine were examined for the presence of oocyst. If sample is positive for infection, oocyst is separated by centrifugation method and preserved in $K_2Cr_2O_7$ at NTP. Regular checkup for sporulation time and morphometric measurement is carried out every day after every 2 hr. [1],[23] [24].

RESULTS AND DISCUSSION

2524 total samples were examined for study of coccidial investigation from two year [2006 to 2008]. Among 2524, 734 were positive for coccidial infection and percentage prevalence is 29.08

percentages. All positive samples show prevalence of *E. tenella*, *E. necatrix*, *E. brunetti*, *E. acervulina*, *E. maxima*, *E. praecox*, *E. mitis*, and three new species *E. nikamae*, *E. tarabaie*, and *E. shivpuri*. Out of 734 positive samples 14 samples show presence of new species *E. tarabai*. Percentage prevalence is 1.90%.

DESCRIPTION OF THE OOCYSTS:-

The oocyst of *Eimeria tarabaie* is cylindrical, both ends are rounded and covered with double layered wall. The outer wall is thick and inner is thin whereas outer is brown and inner is bluish to brown in colour and measured about 0.9 μ m thick. Oocyst is without micropyle and micropylar cap. Oval to sub spherical sporoblasts fill the central portion of the unsporulated oocyst. At the anterior end of the sporulated oocyst, prominent polar granule is present close to oocyst wall. Oocystic residuum is absent but sporocystic residuum is present. Sporocysts are completely rounded and placed in the middle of the oocyst. Sporozoites are small bean shaped with very small refractive granules. Sporulation time is 14 to 18 hr.

Measurements of the sporulated oocysts:

1. Length of sporulated oocysts: 22.5-27.1 μ m (24.1 μ m)
2. Width of sporulated oocyst: 18.1-19.3 μ m (18.8 μ m)
3. Length width ratio : 1.2-1.3 μ m (1.1 μ m)
4. Length of sporocyst: 10-10 μ m (10 μ m)
5. Width of sporocyst: 10-10 μ m (10 μ m)
6. Length width ratio: 1-1 μ m (1 μ m)

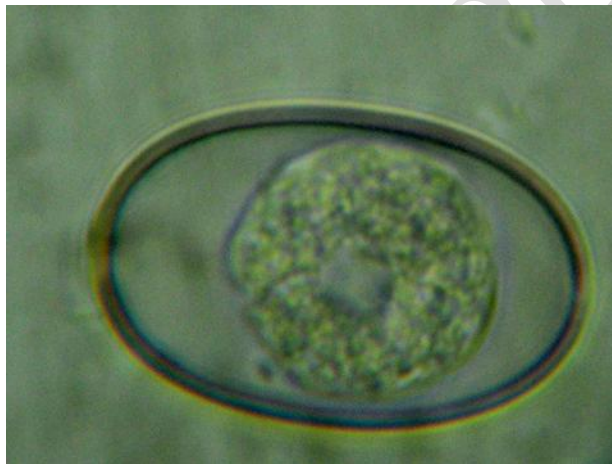


Fig 1: *Eimeria tarabaie*(n.sp.) (Unsporulated)

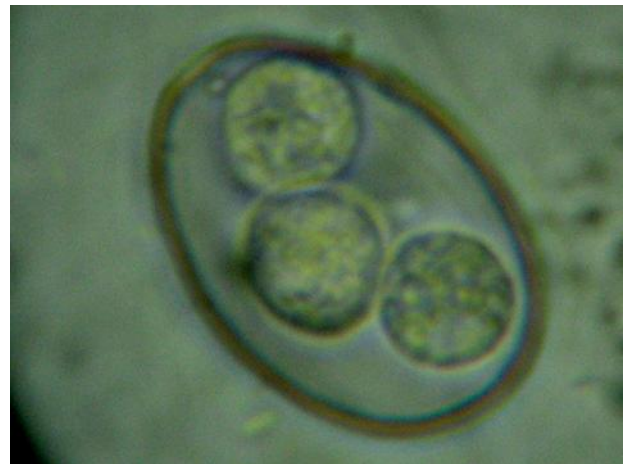

Fig 2: *Eimeria tarabaie* (n.sp.) (Sporulated)

COMMENTS:

Different *Eimeria* species are described from *Gallus gallus domesticus* in India as well as in various parts of the world. Eight species of *Eimeria* are described from the broiler chicken along with one new species are as follows-

E. tenella Railliet and Lucet 1891, *E. necatrix* Johnson, 1930, *E. brunette* Levine 1942, *E. acervulina* Tyzzer 1929, *E. praecox* Johnson 1930, *E. maxima* Tyzzer 1929, *E. mitis* Tyzzer 1929 and *Eimeria tarabaie* (n. sp.) by present author.

Eimeria tarabaie species is clearly distinct from previously described eight species. The shape of the oocyst and arrangement of sporocyst is completely differing from all above described species. Oocyst shape and size of *E. tarabaie* shows resemblance with *E. acervulina* but *E. tarabaie* is narrower than these species. Centrally placed spherical to sub spherical sporoblast is the key distinct character of unsporulated oocyst which is not seen in previously recorded species. In sporulated oocyst sporocysts are placed vertically one above another in the middle of the oocyst. Sporocysts are completely rounded and without stieda body. This feature is altogether different from the other previously recorded species by author except new species *Eimeria nikamae*.

Though the shape and size of sporocysts of *Eimeria nikamae* and present species are same but the shape of the oocyst are altogether different from each other. The shape of oocysts in *Eimeria nikamae* is broad, oval with rounded base and narrow top where as in present species oocyst is cylindrical with equally rounded ends.

CONCLUSION

From all distinctness recorded from unsporulated and sporulated oocysts, it is considered as *Eimeria tarabaie* (n. sp.) after Mrs. Tarabai Namdev Jadhav (beloved mother of present author).

ACKNOWLEDGEMENTS

I am thankful to my research guide Prof. SV Nikam and HOD Dept. of Zoology Dr. BAMU Chhatrapati Sambhajanagar

COMPETING INTERESTS

No any conflict of interest

REFERENCES:-

1. Jadhav BN, Nikam SV, Bhamre SN, Jaid EL. Study of *Eimeria necatrix* in broiler chicken from Aurangabad District of Maharashtra state India. *Int Multidiscip Res J.* 2011;1(11):11–12.
2. Tyzzer, E.E. Criteria and methods in the investigation of avian coccidiosis. *Science.* 1932 75 (1943): 324-328.
3. Ena A. Allen *Eimeria angustasp.* Nov. and *Eimeria bonasae* sp. Nov. from Grouse with a key to the species of *Eimeria* in birds. 1934 Vol. LIII. No. I; 1-5.
4. Chakravarthy, M. and Kar. A.B. Studies on the coccidia of Indian bird. IInd observations on several species of the coccidia of the sub families cyclosporinae and eimeriinae. 1944 proc. Ind. Acta. Sci. 20 (sec.B.); 102-104.
5. Ray D.K, Shivmani, G.A. Oomen, and Bhaskaran, R. A study on the coccidia of some Himalayan birds. 1952
6. Levine N. D. A review of the coccidia from the avian order Galliformes, Anseriformes and Charadriiformes with description of three new species *Am. Midl. Nat.* 1953 49; 696-719.

7. David S.F.M. Intestinal coccidiosis in chicken caused by *Eimeria necatrix* vet. Rec. 1956 853-857.
8. Burns, W.C. (1959):- The lethal effect of *Eimeria tenella* extracts on rabbits. J. Parasitol. 45: 38-46.
9. Dubey J.P. And Pande B.P. On a coccidian schizonts in the Indian domestic duck (*Anas palarhynchos domesticus*) J.Parasit 1963 749-770.
10. Sharma N.N. (1964):- Response of fowl (*Gallus domesticate*) to parental Administration of seven coccidial species. J. Parasitol 50 (4); 509-517
11. Edger S.A. and C.T.Seibold A new Coccidium of chickens *Eimeria mivati* sp. N. (protozoa; Eimeriidas) with details of its life history. J. parasitol, 1964 50,193-204.
12. Ray H. N. On a new Coccidium *Wenyonellagallinae* n. sp. from the gut of the domestic fowl. *Gallus gallus domesticus* Linn. Curr. Sci. 1965 14; 275.
13. Vetterling, J.M and D.J.Doran. Schizogony and gametogony in the life cycle of poultry coccidium, *Eimeria acervulina* (Tyzzer, 1929). J. Parasitol. 1966 52(6): 1150-1157.
14. Mandal A.K. Studies on some aspects of avian coccidia [protozoa –sporozoa], zool. Soc. Calcutta. 1966 19; 23-29.
15. Hein, H. The pathogenic effects of *Eimeria acervulina* in young chicks. *Expl.Parasit.* 1968 22: 1-11.
16. Mandal A.K. Studies on some aspect of avian coccidia [protozoa; sporozoa] part 4th. occurrence and distribution of coccidian parasite in Indian birds. Rec. Zool. Surv. India. 1970 63 (1-4).
17. Itagaki, K; M. Tsubokura and M. Taira Basic biological studies on the avian coccidium. Development of *Eimeria tenella*, *E. brunetti* and *E. acervulina* in chick's embryos Japanese J. Vet. Sci. 1972 34: 143-149
18. Joyner, L. P. The specific characteristics of *Eimeria* with special reference to the coccidia of the Fowl .Avian pathol. 1974 3, 145-157.
19. Ruff M. D. and Reid W.M. coccidiosis and intestinal pH in chicken Avium Dis, 1975 9, 343-348.
20. Mandal A.K. Fifty years program in the taxonomy of coccidia (protozoa; sporozoa) from India. Rec. Zool. Surv. India, 1975 68; 341-353.
21. Wayne I. Anderson. Et.al. Demonstration of *Eimeria tenella* in bursa of fabricius of chickens. Avian Disease 1976 20(4); 752-755.
22. Ryley, J.F., R. Meade, J. Hazelhurt and T.E. Robinson Methods in coccidiosis research: separation of Oocysts from faeces. Parasitol. 1976 73: 311-26.
23. Krishmurthy, R. and Bhosale, V.M. A preliminary report on a incidence of coccidia in bird of Mathura state .Symp.Mod. Trends in zool. Res, Calcutta, 1976 62 (Abstract).
24. Krishnamurthy and Kshirsagar, H.S. Incidence of coccidia in the Goat of the Marathwada region of Maharashtra state .Marathwada Univ. J.Sci. 1976 15; 153-156.

25. Ruff M.D. et.al. Effect of aging on survival and pathogenesis of *Eimeria acervulina* and *Eimeria tenella*, Avian Disease 1981 Vol.25, No.3.
26. Pablo S.Reyna et.al. Survival of coccidia in poultry litter and reservoirs of infection. Avian Disease 1982 27(2) 464-473.
27. Davis, P.J., M.E.J. Barrât, M. Morgan, S.H. Parry, LR. Mec Donald, L.P. Joyner and P.L. Long. Immune response of chickens to oral immunization by trickle infection with *Eimeria*. Research in Avian coccidiosis. Proc. Georgia Coccidiosis Conf. 18-20 November: 1985 618-633.
28. Al-Attar M.A. and Farnando M.A. (1987):- Transport of *Eimeria necatrix* sporozoites in the chicken; effect of irritant injected intraperitoneally. J. Parasit, 73(3) 494-502.
29. Vincent McDonald and M.Elaine Rose *Eimeria tenella* and *Eimeria necatrix*; A third generation of schizogony is an obligatory part of the developmental cycle. J.parasit, 1987 73(3); 617-622.
30. Shaker, S.A. Taxonomical study of prevalent spp. of *Eimeria* in broiler chicks and comparison of immunocox (imported vaccine) and locally prepared vaccine against coccidiosis. M.Sc. (Hons.) 1997 Thesis, University of Agriculture, Faisalabad-Pakistan.
31. McDougald L.R. et.al. A survey of coccidia on 43 poultry farms in Argentina, Avian disease 1997 41; 923-929.
32. GetachewGari, GetachewTilahun and Ph. Dorchies Study on Poultry Coccidiosis in Tiyo District, Arsi Zone, Ethiopia. International Journal of Poultry Science 2008 7 (3): 251-256.
33. Available on <https://www.sciencedirect.com/science/article/abs/pii/B9780128008799000536>