

## DIETARY *THEOBROMA COCAO* PREVENTS HEPATOTOXICITY SECONDARY TOMYOCARDIAL INJURY

### ABSTRACT

~~There is a correlation between myocardial injury and liver insufficiency.~~ Dietary products like cocoa with high flavonoids may play a role to boost the integrity of the liver against insults resulting from myocardial injury. 24 of Male Wistar rats (200-250g, n = 24) divided into four groups ~~of-where~~ 6 rats were used per group for the study. Group 1 ~~was the normal~~ as the control (placed on a placebo of 0.9% normal saline via oral gavage), Group 2 was the acute myocardial injury group, and received a subcutaneous injection of isoproterenol (100mg/kg body weight) twice at an interval of 24 hours to the end of the experiment. Group 3 was administered TC (100mg/kg body weight orally) only for 2 weeks. Group 4 was pretreated with TC (100mg/kg orally) for 2 weeks and then followed by a subcutaneous injection of isoproterenol (100mg/kg body weight) twice at an interval of 24 hours to the end of the experiment. All animals had free access to rat chow and water. At the end of the experimental period, the rats were sacrificed over ketamine anaesthesia, ans serum collected for laboratory investigations of lactate dehydrogenase, troponin, alanine aminotransferase, aspartate transaminase, and alkaline phosphatase. From the study, administration of ISO resulted in a significant ( $p < 0.001$ ) elevation in the serum concentrations of the cardiac biomarkers, troponins and LDH when compared with the normal control rats, depicting myocardial injury. Pretreatment with cocoa before MI induction preserved the myocardial cells to withstand the insult, with a consequent reduction in the concentrations of LDH and troponins, with values similar to the control group. The serum liver enzymes AST, ALT, and ALP concentration was also significantly elevated above the normal control, indicating hepatotoxicity in the ISO group. The increased serum liver enzymes were reversed in the cocoa treatment groups, indicating the hepatoprotective potentials of *T. cacao*. Result of this study has further strengthened the link between myocardial injury and the liver. It has also provided a support for the prophylactic use of dietary *Theobroma cacao* against hepatotoxicity.

Comment [HA1]: What is meaning? Mention it

Comment [HA2]: ?

Comment [HA3]: ?

Comment [HA4]: Mention the study conclusion in the end of abstract

## INTRODUCTION

Acute myocardial infarction (AMI) is one of the leading cardiovascular diseases with a high mortality rate<sup>1</sup>. It is diagnosed in every 1 out of 10 patients admitted in the Emergency Unit with a heart attack<sup>2</sup>. In developing countries, a change in lifestyle is considered a predisposing factor for the increased mortality rate due to AMI<sup>3</sup>. AMI causes distortion in the structural, mechanical, electrical, and biochemical properties of the heart<sup>4</sup>. It can be due to ischaemic heart disease and/or in conjunction with coronary artery disease with a resultant deterioration of ventricular function and myocardial necrosis<sup>5,6</sup>. Serum enzymes such as lactate dehydrogenase (LDH), ~~cardiac~~ Creatine kinase (CK), Aspartate aminotransferase (AST), malondialdehyde (MDA), and troponins are biomarkers used for the diagnosis of AMI<sup>7,8</sup>. This is because when there is a decreased coronary blood flow and a consequent deterioration of ventricular function due to myocardial necrosis, the serum concentrations of LDH, CK, AST, MDA, and troponins will significantly increase, indicating tissue damage<sup>9</sup>.

There is a correlation between myocardial injury and hepatic insufficiency<sup>10</sup>. The liver plays a vital role in metabolism, detoxification and excretion. It metabolizes substances via hydration, condensation, oxidation, reduction, hydrolysis or conjugation. An alteration in any of these processes may result in liver cell injury<sup>11</sup>.

Blockage of blood flow and congestion can manifest in liver damage<sup>12</sup>, and the damaging effect of the myocardial infarction on the liver are multifactorial including decrease in blood flow to the liver, reduced arterial saturation and increased hepatic vein pressure<sup>13</sup>. Liver disease possibly may be inflammatory, non-inflammatory and degenerative.

Nutraceuticals in the form of antioxidants, dietary fibres, omega-3 polyunsaturated fatty acids, vitamins and minerals also play a preventive and curative role in cardiovascular diseases<sup>14</sup>,

Comment [HA5]:

so do plants with antioxidant properties<sup>15,16</sup>. One such plant with high antioxidant properties is *Theobroma cacao*<sup>17</sup>. *Theobroma cacao* is reported to suppress the development of atherosclerotic lesions<sup>18</sup>, decrease platelet hyperactivity<sup>19</sup>, increase dermal blood flow<sup>20</sup>, decrease oxidation of LDL cholesterol<sup>21</sup>, and promote normal lipid profile<sup>22</sup>. It also inhibits the proliferation of human breast cancer cells and reduces circulating blood sugar levels<sup>23</sup>. There is however paucity of reports on the hepatoprotective potentials of *Theobroma cacao* secondary to myocardial injury.

## MATERIALS AND METHODS

### Plant Material and Extraction

Dry Trinitario variety of *Theobroma cacao* seeds were obtained from Cross River State, Nigeria. The variety was identified at the Herbarium unit of the Department of Botany, University of Calabar, Nigeria, and assigned a voucher number TCB/990123. 3kg de-coated dry cocoa seeds were ground into coarse powder yielding 1.65 Kg of the powder. This was suspended in two ~~litres~~liters of ethanol (BDH Ltd Poole, England) and left to percolate for 24 hours at room temperature. The suspension was thereafter filtered with Whatman No. I filter paper. The filtrate was evaporated by hot air oven treatment at 40-45 °C to a thick dark gummy crude extract giving a yield of 66g (4.8%). The extract was refrigerated at -4<sup>o</sup>C until required for use.

Formatted: Superscript

### Experimental Animals/Design

Approval was sought and the consent granted by the Faculty of Basic Medical sciences Animal Research Ethics Committee, the University of Calabar with Approval No: 019PY20401. Male Wistar rats (200-250g, n = 24) divided into four groups of 6 rats ~~which were~~used for the study. The animals were kept in plastic cages and controlled environment (12h light/dark cycles at 27 ± 2°C) one week for acclimatization before the commencement of the study. Group 1 was the normal control (placed on a placebo of 0.9% normal saline via oral gavage), Group 2 was the

AMI group, and received a subcutaneous injection of isoproterenol (100mg/kg body weight) twice at an interval of 24 hours to the end of the experiment. Group 3 was administered TC (100mg/kg body weight orally) only for 2 weeks. Group 4 was pretreated with TC (100mg/kg orally) for 2 weeks and then followed by a subcutaneous injection of isoproterenol (100mg/kg body weight) twice at an interval of 24 hours to the end of the experiment. All animals had free access to ratchow and water.

Comment [HA6]: What is meaning?

### Induction of Acute Myocardial Injury

Myocardial infarction was induced by subcutaneous injection of 100mg/kg isoproterenol once for two days with a 24 hours interval in between<sup>24,25</sup>. Isoproterenol acts by decreasing the blood flow to the myocardium with consequent hypoxia. The hypoxic state causes a fall in mitochondrial ATP, hence depleting cellular ATP. There is a generation of reactive oxygen species, calcium overload, and phospholipid depletion with attendant lipid peroxidation, tissue inflammation, and structural membrane damage. These result in an irreversible damage to the myocardium<sup>26</sup>. Myocardial infarction induced by isoproterenol is reported to show many metabolic and morphologic aberrations in the heart tissue of the experimental animals similar to those observed in human myocardial infarction<sup>27</sup>.

Liver function tests (LFTs) are commonly used in clinical practice to screen for liver disease, monitor the progression of known disease, and monitor the effects of potentially hepatotoxic drugs. The most common LFTs include the serum aminotransferases, alkaline phosphatase, bilirubin, albumin, and prothrombin time<sup>20</sup>. Aminotransferases, such as alanine aminotransferase (ALT) and aspartate aminotransferase (AST), measure the concentration of intracellular hepatic enzymes that have leaked into the circulation and serve as a marker of hepatocyte injury. Alkaline phosphatase (AP),  $\gamma$ -glutamyl transpeptidase (GGT), and bilirubin act

Comment [HA7]: ?

as markers of biliary function and cholestasis. Albumin and prothrombin reflect liver synthetic function. Increased serum activities/concentration of liver enzymes such as (AST), alanine aminotransferase (ALT) alkaline phosphatase (ALP) are indicators of hepatocellular injury.

Comment [HA8]: ?

Increased serum activity level of these markers is associated to type 2 diabetes mellitus with a higher incidence of liver function test abnormalities than individuals who do not have diabetes<sup>21</sup>. Mild chronic elevations of transaminases often reflect underlying insulin resistance. Anti-diabetic agents have generally been shown to decrease alanine aminotransferase levels as tighter blood glucose levels are achieved. The aminotransferases AST and ALT are normally < 30-40 units/l. Elevations of aminotransferases greater than eight times the upper limit of normal reflect either acute viral hepatitis, ischemic hepatitis, or drug- or toxin-induced liver injury.

#### **Determination of serum alanine aminotransferase (ALT)**

Serum Alanine aminotransferase (ALT), is measured by monitoring the concentration of pyruvate hydrozone formed with 2,4-dinitrophenylhydrazine<sup>24</sup>. The method is based on the principle that pyruvate (pyruvic acid) formed from the alanine aminotransferase catalysed reaction between  $\alpha$ -ketoglutarate (oxoglutarate) and L-alanine is coupled with chromogen solution (2,4-dinitrophenyl hydrazine) in an alkaline medium to form coloured hydrazone, the concentration of which is proportional to the alanine aminotransferase activity as measured with a colorimeter. To 0.05 ml of each serum sample in a test tube was added 0.25 ml of buffer/substrate solution. This was incubated at 37°C for 30 min in a water bath followed by the addition of 0.25 ml of chromogen solution. The content was mixed and allowed to stand for 20 min at room temperature. Then 2.5 ml of sodium hydroxide (0.4 N) was added and mixed. The absorbance was read after 5 min against the blank at 540 nm. The blanks were treated as the

samples but without the addition of chromogen solution used to stop all the enzymatic reactions. ALT activity (IU/L) was read off from the standard curve<sup>25</sup>.

#### **Determination of serum aspartate aminotransferase (AST)**

The determination of the blood serum of Aspartate aminotransferase (AST), is measured by monitoring the concentration of oxaloacetate hydrazone formed with 2,4-dinitrophenylhydrazine. The method is based on the principle that oxaloacetate (oxaloacetic acid) that is formed from the aspartate aminotransferase catalyzed reaction between alpha ketoglutarate and aspartate is coupled with chromogen (2,4-dinitrophenyl hydrazine) in alkaline medium to form colored hydrazone. The concentration of the coloured hydrazone is proportional to the aspartate aminotransferase activity and is measured with a colorimeter. To 0.05 ml of each serum sample in a test tube was added 0.25 ml of buffer/substrate solution. The content was incubated at 37°C for 60 min in a water bath followed by the addition of 0.25 ml of chromogen solution. The content was mixed and allowed to stand for 20 min at room temperature after which 2.5 ml of sodium hydroxide (0.4 N) was added and mixed. The absorbance was read after 5 min against blank at 540 nm. The blanks were treated as the samples but without the addition of chromogenic solution used to stop all enzymatic reactions. AST activity (IU/L) was read off from the standard curve.

#### **Determination of serum alkaline phosphatase (ALP)**

This measurement of alkaline phosphatase (ALP) followed standard procedure<sup>26</sup>. Principle: Phenol released by enzymatic hydrolysis from phenylphosphate under defined conditions of time, temperature and pH – is estimated colorimetrically. Technique Test:- 1ml of buffer was mixed with 1ml of phenylphosphate substrate in a test tube placed in water bath at 37°C for 3 minutes. 0.1ml of serum was added mixed gently and incubated for exactly 15 minutes, the reaction was stopped by addition of 0.8ml of 0.5N sodium hydroxide (NaOH).

Control:-In a test tube 1ml substrate was mixed with 0.8ml of 0.5N sodium hydroxide, followed by 0.1ml of serum. Standard:-1.1ml of buffer was mixed with 0.1ml of phenol standard(1mg/100ml) and 0.8ml of 0.5N sodium hydroxide. Blank:-1.1ml of buffer, 1.0ml of water and 0.8ml of 0.5N sodium hydroxide was mixed. To all tubes 1.2ml of 0.5N sodium bicarbonate (NaHCO<sub>3</sub>) was added with 1ml of Potassium Ferricyanide solution - K<sub>3</sub>(Fe(CN)<sub>6</sub>), mixing each tube well after each addition. The successive additions adjusted the pH to develop the color. The 0.0 of reddish –brown colors of 510 nanometer (nm), was read avoiding exposure to strong sunlight.

Calculation: *Serum alkaline phosphatase (King-Armstrong Units/100ml)* =

$$\frac{\text{Reading of an Unknown} - \text{Reading of Control}}{\text{Reading of Standard} - \text{Reading of Blank}} \times 100$$

### Data Analysis

Results are expressed as mean ± SEM. Data was analyzed using the GraphPad Prism software (version 6.0). Analysis of variance (ANOVA) followed by Turkey comparison test where F value was significant. Probability level of p<0.05 was accepted as significant.

## RESULTS

### Troponin and lactate dehydrogenase concentrations in isoproterenol-induced myocardial injury treated with cocoa

Serum concentrations of troponin and lactate dehydrogenase were measured to evaluate myocardial damage. The serum concentration of troponin in the control, MI, cocoa only, and cocoa + MI groups was 0.038 ± 0.00027ng/ml, 0.055 ± 0.0012ng/ml, 0.036 ± 0.00036ng/ml, and 0.036 ± 0.00035ng/ml respectively. The result showed a significant (p<0.01) increase in the serum concentration of troponin in the MI group compared to the control group. Administration

of cocoa before MI induction significantly ( $p < 0.01$ ) decreased troponin concentration when compared with the MI group. Similarly, the mean serum concentration of LDH in control, MI, cocoa only, and cocoa + MI groups was  $1465 \pm 3.97 \text{ IU/l}$ ,  $1653 \pm 3.53 \text{ IU/l}$ ,  $1430 \pm 8.33 \text{ IU/l}$ , and  $1422 \pm 18.0 \text{ IU/l}$ , respectively. This shows a significant ( $p < 0.01$ ) increase in the serum concentration of LDH in the MI group when compared to the control. This increase was attenuated ( $p < 0.01$ ) by pretreatment with cocoa before MI induction. This is presented in Table 1.

#### **Serum aspartate aminotransferase (AST) concentrations in isoproterenol-induced myocardial injury treated with cocoa**

The liver enzymes activity was measured to evaluate the integrity of the hepatocytes following isoproterenol-induced myocardial injury. Serum aspartate aminotransferase (AST) concentrations in the control, MI, cocoa only, and cocoa + MI groups was  $50.96 \pm 0.13 \text{ IU/L}$ ,  $82.65 \pm 0.22 \text{ IU/L}$ ,  $46.72 \pm 0.20 \text{ IU/L}$ , and  $57.98 \pm 0.34$  respectively. The result showed a significant ( $p < 0.001$ ) increase AST concentration in the MI group when compared with the control, indicating an injury to the hepatocytes following isoproterenol administration. However, pretreatment with cocoa before MI induction resulted in a decrease serum concentration of AST, with values similar to the control group. This is presented in Fig. 1.

#### **Serum alanine aminotransferase concentrations in isoproterenol-induced myocardial injury treated with cocoa**

Serum alanine aminotransferase (ALT) was also measured to evaluate the integrity of the hepatocytes. The serum ALT concentrations in the control, MI, cocoa only, and cocoa + MI groups was  $21.55 \pm 0.23 \text{ IU/L}$ ,  $38.13 \pm 0.32 \text{ IU/L}$ ,  $20.37 \pm 0.27 \text{ IU/L}$ , and  $29.83 \pm 0.25 \text{ IU/L}$  respectively. The MI group had an increased ( $p < 0.001$ ) ALT concentrations compared with the control, depicting injured hepatocytes following isoproterenol administration. Pretreatment with cocoa prevented increased surge in serum ALT, depicting less damage to the hepatocytes, Fig. 2.

### **Serum alkaline phosphatase concentrations in isoproterenol-induced myocardial injury treated with cocoa**

Serum alkaline phosphatase (ALP) was also measured to evaluate the integrity of the hepatocytes. The serum ALP concentrations in the control, MI, cocoa only, and cocoa + MI groups was  $57.29 \pm 0.22$  IU/L,  $125.19 \pm 0.55$  IU/L,  $53.51 \pm 0.30$  IU/L, and  $71.37 \pm 0.44$  IU/L respectively. The result followed a similar trend with other liver enzymes with a significantly higher ( $p < 0.001$ ) ALP concentration in the MI group when compared with the control. The Cocoa pretreatment group showed a lower concentration of ALP concentration when compared with the MI group. ALP values in the pretreated groups are similar with the control group. This is presented in Fig. 3.

**Table 1: Serum troponin and lactate dehydrogenase concentration in isoproterenol induced myocardial injury treated with cocoa.**

<b>Cardiac Markers</b>	<b>Control Group</b>	<b>MI Group</b>	<b>Cocoa Only</b>	<b>Cocoa + MI</b>
Troponin (ng/ml)	0.038 ± 0.00027	0.055 ± 0.0012**	0.036 ± 0.00036	0.036 ± 0.00042 <sup>c</sup>
Lactate dehydrogenase (IU/l)	1465 ± 3.97	1653 ± 3.53**	1430 ± 8.33	1422 ± 18.0 <sup>c</sup>

\*\* = p<0.01 compared with control; c = p<0.01 compared with MI group

UNDER PEER REVIEW

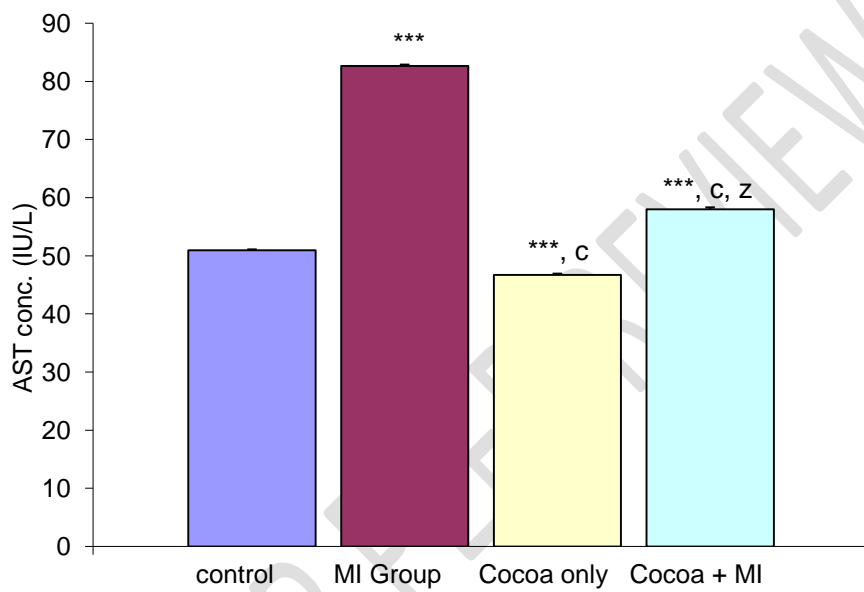


Figure 1: Comparison of aspartate aminotransferase concentrations in the different experimental groups.

Values are expressed as mean + SEM, n = 6.

\*\*\* =  $p < 0.001$  vs control;

c =  $p < 0.001$  vs MI;

z =  $p < 0.001$  vs cocoa only

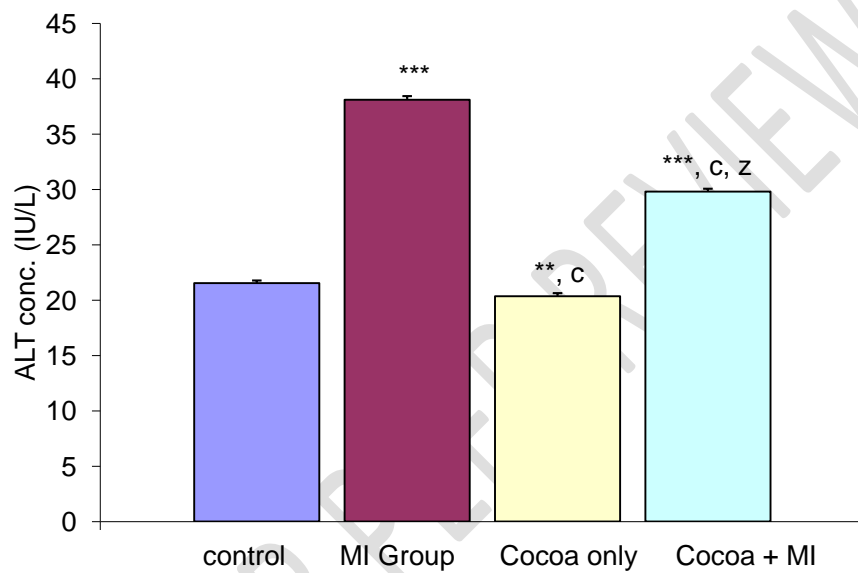


Figure 2: Comparison of alanine aminotransferase concentrations in the different experimental groups.

Values are expressed as mean + SEM, n = 6.

\*\* =  $p < 0.01$ , \*\*\* =  $p < 0.001$  vs control;

c =  $p < 0.001$  vs MI;

z =  $p < 0.001$  vs cocoa only

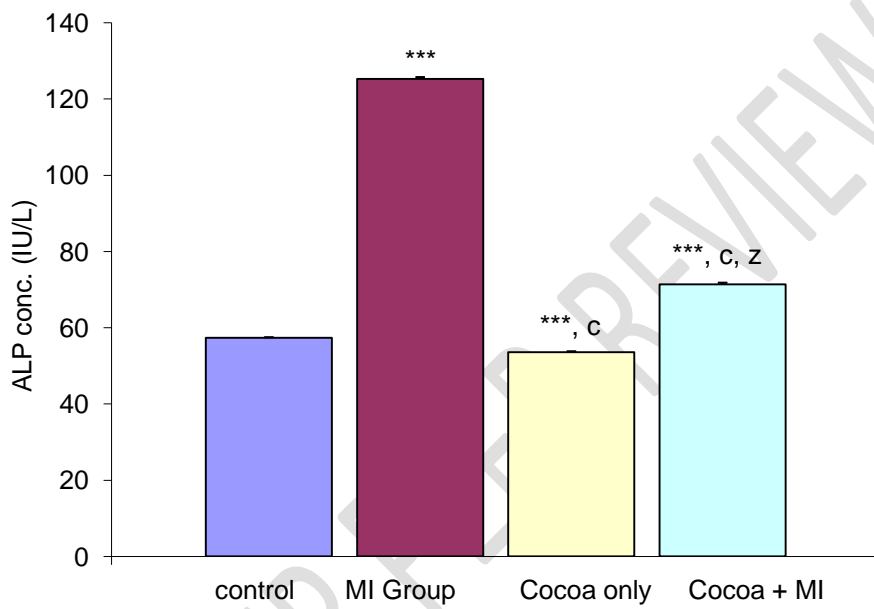


Figure 3: Comparison of alkaline phosphatase concentrations in the different experimental groups.

Values are expressed as mean + SEM, n = 6.

\*\*\* =  $p < 0.001$  vs control;

c =  $p < 0.001$  vs MI;

z =  $p < 0.001$  vs cocoa only

## DISCUSSION

Reports have shown a significant link between myocardial infarction, liver dysfunction, and risk of ischemic hepatitis; a condition that occurs as a result of decrease total hepatic blood flow secondary to low cardiac output, shock or cardiac arrest<sup>28,29</sup>. Blockage of blood flow and congestion can manifest to liver damage<sup>12</sup>. The damaging effect of the myocardial infarction on the liver includes decrease in blood flow to the liver, reduced arterial saturation and increased hepatic vein pressure<sup>13</sup>. The present study therefore evaluated the hepato-protective potentials of *Theobroma cacao* secondary to isoproterenol-induced myocardial injury in rats.

Dietary cocoa ameliorates non-alcoholic fatty liver diseases<sup>30</sup>. It also attenuates artemeter-lumefantrine induced hepatotoxicity in non-malarious Guinea pigs<sup>31</sup>. Due to its abundant presence of flavonoids epicatechin and procyanidin, cocoa is reported to cause increased flow-mediated vasodilation<sup>32</sup>. It has antioxidant and platelet anti-aggregation properties<sup>33,34</sup>. The flavonoids block the “suicide” enzyme cyclooxygenase which breaks down prostaglandins to prevent platelet aggregation<sup>35</sup>.

From the study, administration of ISO resulted in a drastic and significant elevation in the serum concentrations of the cardiac biomarkers, troponins and LDH when compared with the normal control rats, depicting myocardial injury<sup>36</sup>. Pretreatment with cocoa before MI induction preserved the myocardial cells to withstand the insult, with a consequent reduction in the concentrations of LDH and troponins, with values similar to the control group.

Following the myocardial injury caused by ISO administration, the serum liver enzymes AST, ALT, and ALP concentration was significantly elevated above the normal control, indicating hepatotoxicity in the ISO group. The increased serum liver enzymes were reversed in the cocoa treatment groups, indicating the hepatoprotective potentials of *T. cacao*.

Result of this study has further strengthened the link between myocardial injury and the liver. It has also provided a support for the prophylactic use of dietary *Theobroma cacao* against hepatotoxicity.

**Comment [HA9]:** Mention the conclusion of the study as separate part in the end

## REFERENCES

1. Marschang P; Metzler B. Acute myocardial infarction as a manifestation of systemic vasculitis. *Wien Klin Wochenschr*,2016; 128(21-22): 841-843.
2. Haasenritter J; Stanze D; Widera G; Wilimzig C; Abu Hani M; Sonnichsen AC, Bosner S, Rochon J, Donner-Banzhoff N. Does the patient with chest pain have a coronary heart disease? Diagnostic value of single symptoms and signs--a meta-analysis. *Croat Med J*, 2012; 53(5):432-441.
3. Rathore V, Singh N, Mahat R. Risk Factors for Acute Myocardial Infarction: A review. *Eurasian J Med Invest*,2018;2(1):1-7.
4. Richardson WJ, Clarke SA,Quinn TA, Holmes JW. Physiological Implications of Myocardial Scar Structure. *Compr. Physiol.*,2015; 5(4):1877-1909.
5. Liakos M. Parikh PB. Gender disparities in presentation, management, and outcomes of acute myocardial infarction. *Curr Cardiol Res*,2018; 20(8):64.
6. Aydin S, Aydin S. Irisin concentrations as a myocardial biomarker. *Biomarkers in Cardiovascular Disease*; Patel, V.B.; Preedy, V.R., Eds.; Springer: Dordrecht, 489-504, 2016..
7. Danese E, Montagnana M. An historical approach to the diagnosticbiomarkers of acute coronary syndrome. *Ann Transl Med*, 2016; 4(10):194.
8. Mythili S, Malathi N. Diagnostic markers of acute myocardial infarction. *Biomed. Rep*, 2015, 3(6), 743-748.
9. Feng QZ, Cheng LQ, Li YF. Progressive deterioration of left ventricular function in a patient with a normal coronary angiogram. *World J. Cardiol.*, 2012; 4(4):130-136
10. Ekaidem IS, Akpan HD, Uboh IF, Etim OE,Ebong PE. Effect of ethanolicextract of *Azadirachta indica* leaves on lipid profile peroxidation and serum lipids of diabetic Wistar rats. *Acta Bio Szeged*, 2007; 51(1):17-20.
11. Sriuasfava R, Sriuasfava P. Hepatotoxicity and role of some herbal hepatoprotective plants in present scenario. *Glo J Digest Dis*, 2018; 4(3):23-28.
12. Biegus J, Zymlinski R, Sokolski M. (2012). Liver function tests in patients with acute heart failure. *PolArch. Med*,2012; 122(10):471-479.
13. Ambrosy AP, Vaduganathan M, Huffman MD. Clinical course and predictive value of liver function tests in patients hospitalized for worsening heart failure with reduced ejection fraction: an analysis of the EVEREST trial. *Euro J Heart Fail*, 2012; 14(3):302-311

- 14 Choudhary M, Tomer V. Cardioprotective Effect of Nutraceuticals–The Emerging Evidences. *Proceedings of the Indian National Science Academy*, 2013;4:985-996.
- 15 Kumar A, Krishna G, Hullatti P, Akshara T. Indian plants with cardioprotective activity– a review *Systematic Reviews in Pharmacy*, 2017;8:8-12.
- 16 Viswanatha GLS, Vaidya SK, Ramesh C, Krishnadas N, Rangappa S. Antioxidant and antimutagenic activities of bark extract of *Terminalia arjuna*. *Asian Pac J Trop Med*, 2010;3: 965-970 .
- 17 Kris-Etherton PM, Keen CL. Evidence that the antioxidant flavonoids in tea and cocoa are beneficial for cardiovascular health. *Curr Opin Lipidol*, 2002;13(1):41-49.
- 18 Kurosawa T, Itoh F, Nozaki A, Nakano Y, Katsuda S, Osakabe N, Tsubone H, Kondo K, Itakura H. Suppressive effect of cocoa powder on atherosclerosis in Kurosawa and Kusanagi-hypercholesterolemic rabbits. *J Atheroscler Thromb*, 2005; 12(1):20-28.
- 19 Murphy KJ, Chronopoulos AK, Singh I, Francis MA, Moriarty H, Pike MJ, Turner AH, Mann NJ, Sinclair AJ. Dietary flavanols and procyanidin oligomers from cocoa (*Theobroma cacao*) inhibit platelet function. *Am J Clin Nutr*, 2003; 77(6):1466-1473.
- 20 Neukam K, Stahl W, Tronnier H, Sies H, Heinrich U. Consumption of flavanol-rich cocoa acutely increases microcirculation in human skin. *Eur J Nutr*, 2007; 46(1):53-56
- 21 Tomaru M, Takano H, Osakabe N, Yasuda A, Inoue K, Yanagisawa R, Ohwatari T, Uematsu H. Dietary supplementation with cacao liquor proanthocyanidins prevents elevation of blood glucose levels in diabetic obese mice. *Nutrition*, 2007; 23(4):351-355.
- 22 Agwupuye EI, Beshel JA, Anosike AC, Ezeanyika LU. Methanol Extract of Unfermented *Theobroma Cacao* Promotes Normal Lipid Profile of Wistar Rats. *Int J Trend Sci Res Dev*, 2019; 3(3):190-193
- 23 Ramljak D, Romanczyk LJ, Metheny-Barlow LJ, Thompson N, Knezevic V, Galperin M, Ramesh A, Dickson RB. Pentameric procyanidin from *Theobroma cacao* selectively inhibits growth of human breast cancer cells. *Mol Cancer Ther*, 2012; 4(4) 537-546.
- 24 Boarescu P, Chirila I, Bulboaca A, Parvu A, Gheban D, Bolboaca S. Isoproterenol Induced Myocardial Infarction in Rats: Dose Identification. *Clujul Med*, 2018; 91: 6
- 25 Gunjal MA, Shah AS, Wakade AS, Juvekar AR. Protective effect of *Moringa olifera* Lam stem bark on serum lipids marker enzymes and heart antioxidant parameters in isoproterenol induced cardiotoxicity in wistar rats. *Indian J Nat Prod Resour*, 2010; 1(4):485-492

- 26 Beshel JA, Beshel FN, Nwangwa JN, Asuquo IO, Ejim CI, Owu DU. Cardioprotective role of *Theobroma cacao* against isoproterenol-induced acute myocardial injury. *Cardiovascular and Hematological agents in Medicinal Chemistry*, 2020; 18:1-10.
- 27 Jialal I, Sokoll LJ. Clinical utility of lactate dehydrogenase: a historical perspective *Am J Clin Pathol*, 2015; 143(2):158-159.
- 28 Mason JE, Starke RD, Van-kirk JE. Gamma glutamyl transferase: a novel cardiovascular risk biomarker. *PrevenCardiol*, 2010; 13:36-41
- 29 Lightsey JM, Rockey DC. Current concepts in Ischemic hepatitis. *Cur Opin Gastroenterol*, 2017; 33(3):158-163
- 30 Rein D, Paglieroni TG, Wun T, Pearson DA, Schmitz HH, Gosselin R, Keen CL. Cocoa inhibits platelet activation and function. *Am J Clin Nutr*, 2020; 72(1):30-35.
- 31 Asdaq SM, Inamdar MN. Pharmacodynamic interaction of garlic with hydrochlorothiazide in rats. *Indian J Physiol Pharmacol*, 2009; 53(2):127-136.
- 32 Ottaviani JI, Heiss C, Spencer JPE, Kelm M, Schroeter H. Recommending flavanols and procyanidins for cardiovascular health: Revisited. *Mol Aspects Med*, 2018; 61:63-75.
- 33 Zhu QY, Holt RR, Lazarus SA, Orozco TJ, Keen CL. Inhibitory effects of cocoa flavanols and procyanidin oligomers on free radical-induced erythrocyte hemolysis. *Exp Biol Med (Maywood)*, 2018; 227(5):321-329.
- 34 Heiss C, Dejam A, Kleinbongard P, Schewe T, Sies H, Kelm M. Vascular effects of cocoa rich in flavan-3-ols. *JAMA*, 2003; 290(8):1030-1031.
- 35 Rice-Evans C. Flavonoid antioxidants. *Curr Med Chem*, 2001; 8(7):797-807.
- 36 Sudhakumari AH, Aamir J, Manish J, Muralidhar S. Cardioprotective Effects in Methanolic Extract of *Evolvulus Alsinoides* Linn on Isoproterenol-Induced Myocardial Infarction in Albino Rats *International Journal of Basic Medical Sciences and Pharmacy*. 2012; 2(2):2049-4963.