

Paronychia Its Diagnosis and current potential treatment-based Management: Brief schematic review

ABSTRACT

The inflammation of the tissue that immediately surrounds the nail is referred to as paronychia. Paronychia develops when the protective barrier between the nail plate and the neighbouring nail fold is disrupted, either by infectious or noninfectious reasons. It is possible for paronychia to be an acute or chronic illness. Acute paronychia is typically brought on by bacterial infections and results from the skin's decreased ability to protect itself. Pemphigus vulgaris, fungus, viruses, and trauma (finger sucking) are some more motives. Comparatively speaking to acute paronychia, chronic paronychia is multifactorial. Patients who have diabetes, psoriasis, maceration, or have been exposed to irritants or injuries that either compromise the integrity of the epidermal barrier or reduce local resistance are more likely to report this syndrome. The pathogenesis, aetiology, medical treatment, and diagnosis of paronychia are all covered in this review article.

Keywords: Paronychia, History, Etiology, Pathophysiology, Diagnosis, Management.

INTRODUCTION

Paronychia is a nail condition that typically affects the hand or foot, where the nail and skin touch the base or side of a finger. Bacteria or fungi cause it. It usually affects housewives and housemaids who are frequently pampered with water-related tasks. It is a very straightforward illness that, at most, heals itself gradually in a week. The trouble starts when the pus development persists and worsens after exposure to chemicals, water, or unclean objects. From a cosmetic standpoint, this medical disease impacts how hands seem, making it unsightly or even disfiguring, and making it difficult for the affected individual to go about their daily activities(1). The Greek words onyx, which means nail, which means condition, and para, which means beside of, are the roots of the English word paronychia. The lateral nail fold's edema and erythema are the initial indications of a paronychium. If treatment is not received, this could develop into an abscess that surrounds the lateral and proximal nail folds. Paronychia has a wide

range of etiologies, encompassing both infectious and noninfectious origins. In terms of clinical presentation, paronychia can be either acute or chronic(2). Common causes of paronychia, or inflammation of the tissue immediately around the nail, include acute or chronic infections. After a breakdown in the barrier between the nail plate and the adjacent nail fold, which is frequently brought on by bacterial or fungal infections, paronychia can be acute (\leq six weeks duration) or chronic (\geq six weeks duration). However noninfectious causes can also result in paronychia, including chemical irritants, too much dampness, systemic disorders, and drugs(3,4). An infection of the proximal, lateral, and toenail folds, encompassing the tissue bordering the nail's sides and base, is known as paronychia. This illness may develop on its own or as a result of trauma or manipulation. One of the most prevalent hand infections is paronychia. When the barrier that separates the nail from the nail fold is disrupted, bacteria are introduced, increasing the risk of infection and leading to paronychia. Acute paronychia often affects just one nail, but if it's brought on by drugs, it may affect multiple nails(5,6).

□ **The two kinds of paronychia that are classified**

❖ **Acute Paronychia**

The most prevalent cause of acute paronychia is mild trauma. The soft tissue of the nail folds may become contaminated by bites, vigorous manicures, and hanging nails. Patients usually arrive with a painful, swollen, and red region surrounding their nail. *Staphylococcus aureus*, *Streptococci*, and *Pseudomonas* are the most likely culprits. Herpes simplex virus, dermatophytes, yeasts, and other gram-negative organisms have also been implicated in the illness. In mild cases, three to four warm soaks a day may help; however, drainage is necessary as soon as a pus collection forms. The ideal tool for this is an 18-gauge needle or an 11-blade, softly placed between the nail plate and the proximal nail fold. Following the infection's clinical resolution, an antistaphylococcal penicillin or cephalosporin should be given. Acute paronychia that recurs frequently can result in chronic paronychia(7–9). This is an inflammation of the tissue just around the nail that develops suddenly (in less than six weeks), usually as a result of a bacterial infection(10). It is one of the most prevalent hand infections, and reports indicate that women are more likely than men to contract it (3:1)(4). After an initiating trauma and subsequent rupture of the protective fingertip barrier, organisms found in the skin flora, such as *Staphylococcus aureus* and *Streptococcus pyogenes*, are routinely injected into the nail folds, resulting in acute paronychia. About 25% of the cases are caused by other aerobic bacteria, such as gamma hemolytic streptococci and *Klebsiella pneumoniae*, whereas the remaining 25% are caused by anaerobic organisms. Interaction with oral secretions can put the fingers at risk of infection from both the skin and mouth flora, which include anaerobic (like *Fusobacterium*, *Peptostreptococcus*, *Prevotella*, and *Porphyromonas* spp.) and aerobic (like *Eikenella corrodens*) bacteria. Having contact with livestock may put one at risk of contracting *Pasteurella multocida*. *Proteus vulgaris*, Coliforms, and *Pseudomonas aeruginosa* have also been isolated. The nail bed may become discolored in a greenish manner, which is indicative of *pseudomonas*. Pathogens other than bacteria that cause disease are rare and include herpes simplex virus and *Candida albicans*(11–14).

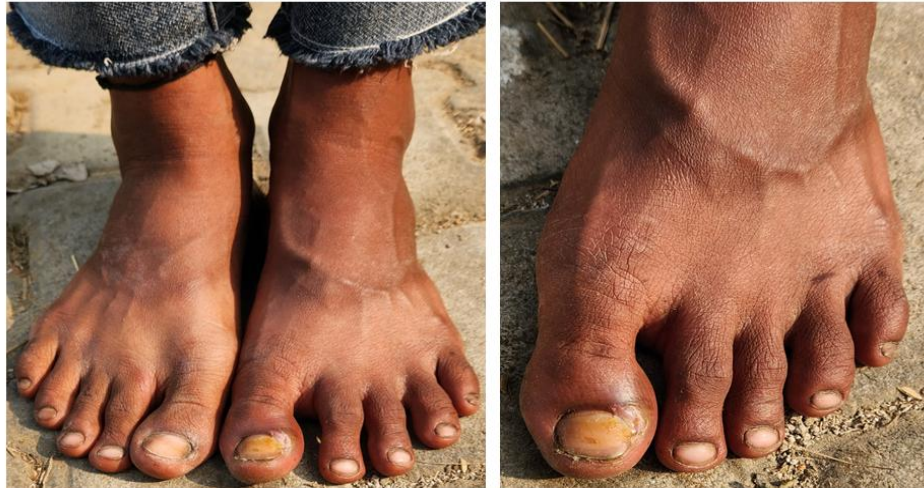

Fig.1:Acute Paronychia.

❖ Chronic Paronychia

The development of chronic paronychia is multifactorial, as opposed to acute paronychia. This syndrome is more common in patients with psoriasis, diabetes, maceration, or exposure to irritants or injuries that either disrupt the normal epidermal barrier or cause lower local resistance. Jobs including bartending, dishwashing, and baking have been linked to an increased risk of this illness. As a result, a complete history that includes employment exposures and interests must be acquired. Furthermore, exposure to specific foods has been suggested as a contributing factor. While foreign body reactions can be a non-infectious cause of paronychia, *Candida albicans* is typically the infectious etiologic agent of persistent paronychia. The pathogens responsible for secondary bacterial infections can be either gram-positive or gram-negative. Anything that makes it easier for the nail fold to separate from the nail plate, allowing pathogens and foreign objects to enter and disrupting normal barrier function, needs to be removed. Antimicrobial therapy might be beneficial as well(15–17). Chronic Paronychia is a stubborn dermatosis that lasts longer than six weeks and is defined by inflammation of the nail-surrounding tissue, which can be infected or not(18,19). It is now believed that chronic paronychia is a type of hand eczema in which exposure to external allergens is a major factor, while candida colonization of the nail sulcus happens only incidentally. The nail sulcus becomes more visible due to the fibrosis of PNF and LNF, which causes them to retract after repeated episodes of acute inflammation. The ability to heal the cuticle becomes less effective as a result of this vicious cycle, and the vascular supply of the inflammatory and fibrosed PNF gradually becomes impaired(20–23). Occupations linked to recurrent exposure to dampness, irritants, and allergens are prevalent among homemakers, bartenders, cooks, and medical professionals, and they are the most common cause of the condition. The likelihood of secondary colonization is increased by immunosuppressive conditions such as diabetes mellitus, HIV infection, and others. Infections include bacterial, fungal (*Candida albicans*), and viral infections are uncommon causes of secondary or congenital syphilis. Peri and/or subungual inflammation may also be

present. Painless paronychia which develops in medical professionals or patients infected with mycobacterium TB, is a kind of paronychia associated with tuberculosis (TB). There have also been reports of onychodystrophy with tubercular Painless paronychia, infection of the distal phalanx resulting in contiguous involvement of the PNF, and Chronic Paronychia linked to TB verrucosa cutis. Another uncommon form of cutaneous leishmaniasis is paronychia(10).

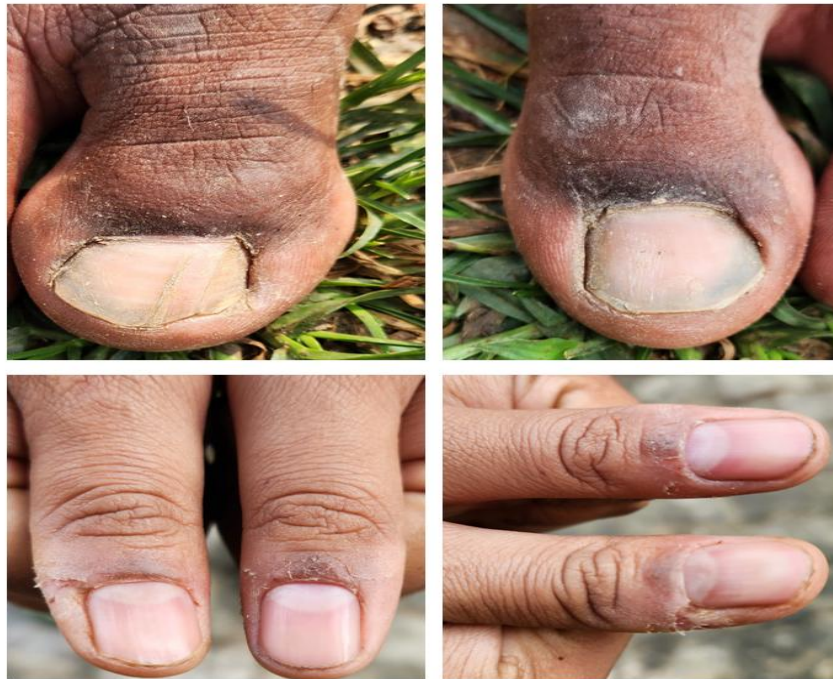

Fig.2 Chronic Paronychia.

HISTORY

Paronychia is mostly diagnosed based on clinical presentation and is most usually an acute inflammatory condition that causes painful redness and swelling to the lateral nail fold. The pain frequently causes the patient to show up within the first few days of the infection. A recent injury, infection, structural irregularity, or inflammatory illness could all be part of the history. Workplace and occupation are important historical results; dishwashers, bartenders, and homemakers appear to be more likely to acquire chronic paronychia. Any serious illnesses like diabetes and HIV should be included in the past medical history inquiry. The patient's current prescription list may be helpful in identifying the reason of their chronic paronychia(24,25). When acute paronychia is examined physically, a painful, swollen, and erythematous lateral nail fold will be seen. If there is a cavity, there can be a fluctuating region. A digital pressure test, in which the examiner applies pressure on the volar aspect of the affected digit, may be helpful if there is ambiguity regarding the presence of an abscess. An area of blanching at the paronychia that is bigger than expected indicates the presence of an abscess, and drainage is required. The nail fold may be red and swollen with chronic paronychia, but fluctuation is uncommon. The nail plate may thicken and darken, and the nail fold may seem

sloppy. Nail dystrophy, cuticle loss, and retraction of the proximal nail fold are other common signs in chronic paronychia(19,26).

ETIOLOGY

Acute paronychia: A purulent, painful ailment that lasts shorter than six weeks; usually brought on by a bacterial infection, particularly one that involves staphylococci. Chronic paronychia: Usually brought on by chemical or mechanical causes, however infectious etiologies, such as fungi, particularly *Candida* species, can also be at play. Risk factors include immunosuppression (diabetes, HIV, cancer), certain drugs, and vocation (housekeeper, bartender, dishwasher, etc.). Another method of classification is by etiology: germs, usually staphylococci usually the Herpes simplex virus fungi, most often species of *Candida* Paronychia can be caused by non-infectious factors such as drug reactions, contact irritants, and excessive wetness(19).The etiology is complex and includes factors such as trauma, candidiasis hypersensitivity, contact allergies, excessive wetness, and irritants in the environment. In patients with chronic paronychia, contact sensitization to allergens as indicated by positive patch test reactions is common. Additionally, there is a greater frequency of prick test reactions to the *Candida* allergen, indicating that *Candida* hypersensitivity plays a more significant role in the development of chronic paronychia than *Candida* infection. Most of the time, bacterial and/or fungal organisms may be secondary colonizers of this eczematous illness. Because this yeast was identified from 40 to 95% of cases, it was previously thought that *Candida* infection was the cause of the illness. Since *Candida* is merely a secondary colonizer, physiologic barrier restoration rather than eradication is linked to favorable clinical outcomes. Atypical mycobacteria, gram-negative rods, and gram-negative cocci have also been linked to chronic paronychia, in addition to *Candida*. Chronic paronychia may be brought on by retinoids (such as tretinoin), protease inhibitors (such as indinavir, lamivudine), and epidermal growth factor receptor inhibitors (such as cetuximab, gefitinib). Patients with immunosuppressive disorders and diabetes mellitus are also more likely to develop chronic paronychia(3,4,27–31).

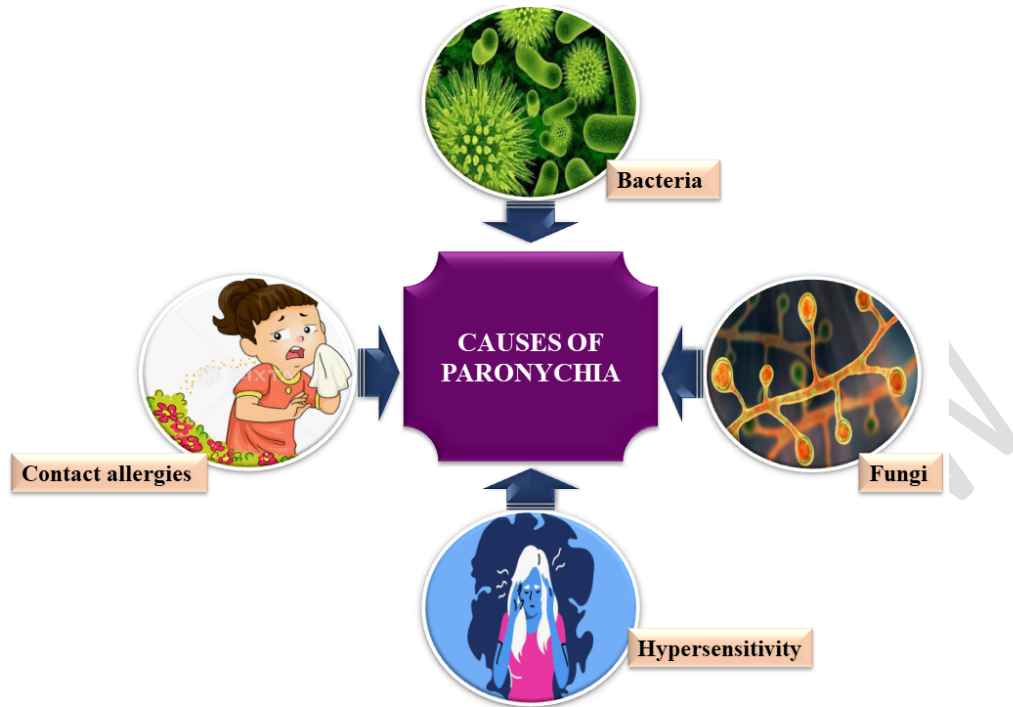


Fig.3: Certain Paronychia disease causes.

PATHOPHYSIOLOGY

The breakage of the cuticle, which acts as a barrier between the nail and the nail fold, causes paronychia. Predisposing variables include trauma (such as manicures and pedicures), infections (including bacterial, viral, and fungal), structural deformities, and inflammatory illnesses (such as psoriasis). The moist nail crevice will allow organisms to enter, which will cause the area to get colonized. Most cases of acute paronychias are caused by trauma, biting one's nails, vigorous manicures, artificial nails, and sometimes even a retained foreign body. *Staphylococcus aureus* is most often the cause of infections. *Pseudomonas* and streptococci are more prevalent in persistent infections. Yeast, dermatophytes, herpes simplex virus, and gram-negative organisms are less frequent causes. Children who bite their nails or suck their fingers frequently run the risk of developing an acute infection from the direct inoculation of oral flora, which includes both aerobic (*S. aureus*, streptococci, and *Eikenella corrodens*) and anaerobic (*Fusobacterium*, *Peptostreptococcus*, *Prevotella*, *Porphyromonas* spp.) bacteria(32,33).

DIAGNOSIS

As no laboratory test or imaging can definitively diagnose a paronychia, a good history and physical examination demonstrating a swollen and sensitive nail fold is necessary. The infection is normally easy to treat; however, an abscess may not always be visible. To help you determine whether an abscess is present, you can perform the previously mentioned digital pressure test(26). Physical examination of the nail unit is the basis for the diagnosis of chronic paronychia. The ailment predominantly impacts adult females and is typically observed in the hands as

opposed to the feet. The symptoms of chronic paronychia include erythema, edema, and nail fold soreness. The paronychium exhibits induration, rounding off, and cuticle loss. Periodic flare-ups could happen. Patients with persistent paronychia frequently experience alterations in their nail plates. Onychomadesis, pitting, Beau's lines, and nail plate thickening and discoloration are possible(34,35).Daniel et al. have proposed a clinical staging approach to provide a systematic description of persistent paronychia. This classification stage I describes the patient as having minor redness, edema in the nail folds, and cuticle disruption. The nail folds exhibit prominent redness and swelling in stage II of the disease. Cuticle loss, some pain, and some modifications to the nail plate are the hallmarks of stage III illness. Stage IV is characterized by significant nail plate alterations as well as soreness and pain.Acute exacerbation of chronic paronychia is represented by stage V(36).It is essential to get a thorough history that covers the risk factors, start, site, progression, and physical examination. It is not advised to routinely culture expressed fluid or drained pus because the results are frequently nondiagnostic. When an abscess or cellulitis is not clinically obvious, ultrasonography (USG) can help distinguish it by showing a widespread thickening of the periungual fold. In order to apply light pressure to the distal volar aspect of the afflicted digit, the patient is asked to oppose their thumb and index finger during the digital pressure test. There is a clearly defined area of blanching if there is an abscess(19,37–39).

❖ **Some of the differential diagnoses for paronychia are:**

Squamous cell carcinoma: Although it primarily affects the skin, this malignancy can also influence the nail bed. Sometimes mistaken for persistent paronychia, this unusual malignant subungual tumor is actually understood to be one.Cellulitis: A superficial infection, cellulitis manifests as erythema and swelling in the affected part of the body, with little fluctuation in the affected area. Antibiotics taken orally are the treatment. A felon is an infection of the digital pulp space that is administered subcutaneously. The confinement of the infection causes pressure in the distinct compartments that the finger pad's septa have produced, causing the area to become heated, red, tense, and extremely painful. In order to guarantee proper drainage, they normally require excision and blunt dissection followed by a longitudinal incision.Herpetic whitlow is a distal finger viral infection brought on by HSV. Typically, patients experience burning and itching before the illness manifests itself. A physical examination will reveal erythema, discomfort, and vesicles or vesicopustules. The incision and drainage of herpetic Whitlow should not be confused with a felon or a paronychia, since this could lead to a secondary bacterial infection and a failure to heal. A fungal infection of the nail that results in whitish-yellow discoloration is called onychomycosis. Treatment might be challenging at times and oral antibiotics are needed rather than topical ones. Psoriasis of the nails: Psoriasis can also affect the toenails and fingernails. It may result in pitted, ridged, unevenly shaped nails that are thicker, and in some cases, elevated nails over the nail bed(5,40).

MEDICATION-BASED MANAGEMENT FOR PARONYCHIA

Antibiotics or incision and drainage are the primary treatments for paronychias. Antibiotics, warm water soaks, and antiseptic solutions (povidone-iodine, chlorhexidine) can all be used as treatments if there is inflammation but no discernible abscess. Several times a day, for ten to fifteen minutes, warm soaks are recommended. Strong data does not support the use of topical

antibiotics over oral ones, and a doctor's judgment may be required based on experience. Any antibiotic administered ought to cover *Staph aureus*. Topical antibiotics such as bacitracin, mupirocin, or triple antibiotic ointment may be utilized. Patients who do not respond to topical treatment or whose conditions are more severe may consider oral antibiotics such as cephalexin (500 mg three to four times a day) or dicloxacillin (250 mg four times a day). Patients with a worry for oral inoculation are among the indications for antibiotics with anaerobic coverage; clindamycin or amoxicillin-clavulanate would need to be added in this case. Select an antibiotic with the right coverage if the patient has any risk factors for MRSA, such as recent surgery, ESRD on hemodialysis, HIV/AIDS, IVDU, or living in a long-term care facility. Options include clindamycin (300–450 mg four times a day), doxycycline (100 mg twice a day), and trimethoprim/sulfamethoxazole DS (1–2 tablets twice a day)(19,26,34). In the event of an abscess, drainage of the infection is necessary. A #11 scalpel is typically used for the incision and drainage; the blade is inserted beneath the eponychial fold, or lateral nail fold, until pus starts to drain. In general, a local or digital block anesthetic helps to achieve thorough drainage by allowing comfort. A large abscess and incision site can be packed with plain gauze by the practitioner to allow for continuous drainage. An abscess has to be irrigated with normal saline. It could be necessary to remove part of the nail plate if the abscess spreads to the nail bed or is connected to an ingrown nail. A "run-around abscess" can occur when an abscess spreads under the nail to the opposite side if it is not drained. In this case, total nail removal could be necessary to enable proper therapy and drainage. After the incision and drainage, warm soaks should be started to promote ongoing drainage, keep the site open, and stop secondary infection. Within the next 24 to 48 hours, the patient should see a provider again to make sure the infection is draining and to check for any signs of worsening infection(26). Acute paronychia is usually well treated with incision and drainage; however, oral antibiotics as previously mentioned may be recommended if there is a large extension of cellulitis. When dealing with chronic paronychia, the patient should be advised to minimize hand trauma. Gloves are recommended for manual laborers. When treating persistent paronychia, the fungus should be suspected as the cause. Since *Candida* species account for the majority of the etiological factors in the chronic type, topical and systemic antifungal medications like terbinafine and itraconazole are viable alternatives. Treatment for other inflammatory conditions affecting the fingers, such as psoriasis and ingrown nails, is also necessary. If you have chronic paronychia that is hard to treat, you should look into other possible reasons like cancer(26,41).

❖ **Surgical treatment for paronychia**

Patients with fully-formed abscess/fluctuance or a run-around abscess, as well as those who fail to respond to medicinal care and/or have significant involvement or fulminant infection of the eponychium, are eligible for surgical management in cases of acute paronychia. The idea behind surgical surgery for acute paronychia is to decompress any abscess that may be present and/or permit the purulent material to drain. When treating Chronic Paronychia, surgical intervention is indicated if the condition lasts longer than six months or if medication treatment is ineffective. Surgical techniques facilitate the excision of the persistently inflammatory surrounding tissue fibrosis, hence promoting medication penetration and cuticle regeneration(42–44). Only situations that are resistant to medical treatment and rigorous observance of preventative

measures should be considered for surgical procedures. The surgical approaches for treating chronic paronychia include the square flap technique, the Swissroll technique, en bloc excision of the proximal nail fold, and eponychial marsupialization with or without nail plate removal. A novel surgical method that preserves the proximal nail fold's epidermis while removing fibrous tissue is the square flap procedure. Nail plate length is maintained since the method prevents nail fold retraction. Every surgical procedure used to treat chronic paronychia aims to drain the inflammatory germinal matrix. It has been demonstrated that simultaneous nail removal generally yields superior clinical outcomes, particularly when concurrent nail alterations are occurring(21,34,42,45).

CONCLUSION AND FUTURE DIRECTION

Brief information regarding the aetiology, pathophysiology, diagnosis, treatment options, and symptoms of paronychia may be found in our review articles. Pharmacological medications offer benefits, but they also often come with drawbacks, like heart failure and renal damage. Surgical intervention is riskier but results in improved patient outcomes. Additional randomized controlled studies are needed to find out more about the optimal treatment plan for paronychia. We intend to investigate paronychia in more detail. In our nation or state, a second study involving counseling will be conducted with the support of our colleagues in order to evaluate the mental and physical well-being of patients and to offer a more thorough knowledge of paronychia and effective therapy.

ETHICAL STATEMENT

A discreet, considerate, and caring pharmacist seeks to improve each patient's well-being.

INFORMED CONSENT

Using websites, review articles, and other sources to produce research content.

References :

1. Sawarkar P, Sawarkar G. Contribution of Ayurveda for management of paronychia: A case report. *J Indian Syst Med.* 2019;7(4):240.
2. HOCHMAN LG. Paronychia: More Than Just an Abscess. *Int J Dermatol.* 1995;34(6):385–6.
3. Rigopoulos D, Larios G, Gregoriou S, Alevizos A. Acute and chronic paronychia. *Am Fam Physician.* 2008;77(3).
4. Rockwell PG. Acute and chronic paronychia. *Am Fam Physician.* 2001;63(6):1113–6.
5. Caitlyn M. Rerucha M. Acute Hand Infections. *Am Acad Fam Physicians.*

- 2019;99(4):228–36.
6. Sampson B, Lewis BKH. Paronychia associated with ledipasvir/sofosbuvir for hepatitis C treatment. *J Clin Aesthet Dermatol*. 2019;12(1):35–7.
 7. Moran TE, Freilich AM. Hand Infection [Internet]. StatPearls Publishing, Treasure Island (FL); 2022. Available from: <http://europepmc.org/books/NBK557849>
 8. Daniel CR III. Paronychia. In: Greer KE, ed. *Common problems in dermatology*. Chicago: Year Book, 1988: 249-255. 1988;1988.
 9. Daniel CR III. Nonfungal infections. In: Scher RK, Daniel CR III, eds. *Nails: therapy, diagnosis, surgery*. Philadelphia: WB Saunders, 1990:122-124. 1990;1990.
 10. Relhan V, Bansal A. Acute and chronic paronychia revisited: A narrative review. *J Cutan Aesthet Surg*. 2022;15(1):1–16.
 11. Biesbroeck LK, Fleckman P. Nail disease for the primary care provider. *Med Clin North Am* 2015;99:1213-26. 2015;2015.
 12. Brook I. Paronychia: a mixed infection. *Microbiology and management*. *J Hand Surg Br* 1993;18:358-9.
 13. Rigopoulos D, Larios G, Gregoriou S, Alevizos A. Acute and chronic paronychia. *Am Fam Physician* 2008;77:339-46. 2008;2008.
 14. Shafritz AB, Coppage JM. Acute and chronic paronychia of the hand. *J Am Acad Orthop Surg* 2014;22:165-74. 2014;2014.
 15. *Studies on Experimental Chronic Paronychia*. 2015;
 16. Zais N. *The nail in health and disease*. Norwalk, CT: Appleton and Lange, 1990:131, 222-223.
 17. Tosti A, Guerra L, Morelli R, Bardazzi F, Fanti PA. Role of foods in the pathogenesis of chronic paronychia. *J Am Acad Dermatol*. 1992;27(5):706–10.
 18. Relhan V, Goel K, Bansal S, Garg VK. Management of chronic paronychia. *Indian J Dermatol*. 2014 Jan;59(1):15–20.
 19. Rubin AI, Ralph Daniel C. Acute and chronic paronychia. *Scher Daniel’s Nails Diagnosis, Surgery, Ther Fourth Ed*. 2018;215–25.
 20. HAY RJ, BARAN R, MOORE MK, WILKINSON JD. Candida onychomycosis—an evaluation of the role of Candida species in nail disease. *Br J Dermatol*. 1988;118(1):47–58.
 21. Bednar MS, Lane LB. Eponychial marsupialization and nail removal for surgical

- treatment of chronic paronychia. *J Hand Surg Am* [Internet]. 1991;16(2):314–7. Available from: [http://dx.doi.org/10.1016/S0363-5023\(10\)80118-2](http://dx.doi.org/10.1016/S0363-5023(10)80118-2)
22. Tosti A, Piraccini BM, Ghetti E, Colombo MD. Topical steroids versus systemic antifungals in the treatment of chronic paronychia: An open, randomized double-blind and double dummy study. *J Am Acad Dermatol*. 2002;47(1):73–6.
 23. Garden BC, Wu S, Lacouture ME. The risk of nail changes with epidermal growth factor receptor inhibitors: a systematic review of the literature and meta- analysis. 2012. In: Database of Abstracts of Reviews of Effects (DARE): Quality-assessed Reviews [Int. 2012;66:37–9.
 24. Goto H, Yoshikawa S, Mori K, Otsuka M, Omodaka T, Yoshimi K, et al. Effective treatments for paronychia caused by oncology pharmacotherapy. *J Dermatol*. 2016;43(6):670–3.
 25. Kapellen TM, Galler A, Kiess W. Higher frequency of paronychia (nail bed infections) in pediatric and adolescent patients with type 1 diabetes mellitus than in non-diabetic peers. *J Pediatr Endocrinol Metab*. 2003;16(5):751–8.
 26. Dulski A, Edwards CW. Paronychia. [Updated 2023 Aug 7]. In: StatPearls [Internet]. Treasure Island (FL): StatPearls Publishing; 2023 Jan-. Available from: <https://www.ncbi.nlm.nih.gov/books/NBK544307/>. 2023;544307.
 27. Nakano J, Nakamura M. Paronychia induced by gefitinib, an epidermal growth factor receptor tyrosine kinase inhibitor [5]. *J Dermatol*. 2003;30(3):261–2.
 28. Relhan, Vineet, et al. “Management of chronic paronychia.” *Indian Journal of Dermatology* 59.1 (2014): 15. 2014;1:2014.
 29. Duhard É. [Paronychia]. *Presse Med* 2014; 43: 1216- 1222. PMID: 25441843.
 30. Bahunuthula, Rakesh Kumar, et al. “Evaluation of role of Candida in patients with chronic paronychia.” *Indian Journal of Dermatology, Venereology and Leprology* 81 (2015): 485. 2015;81:2015.
 31. Colson AE, Sax PE, Keller MJ, Turk BK, Pettus PT, Platt R, et al. Paronychia in association with indinavir treatment. *Clin Infect Dis*. 2001;32(1):140–3.
 32. Natsis NE, Cohen PR. Coagulase-Negative Staphylococcus Skin and Soft Tissue Infections. *Am J Clin Dermatol* [Internet]. 2018;19(5):671–7. Available from: <https://doi.org/10.1007/s40257-018-0362-9>
 33. Brook I. The role of anaerobic bacteria in cutaneous and soft tissue abscesses and infected cysts. *Anaerobe*. 2007;13(5–6):171–7.
 34. Harries E. Chronic Paronychia. *Br Med J*. 1975;3(5974):45.

35. Lomax A, Thornton J, Singh D. Toenail paronychia. *Foot Ankle Surg* 2016; 22: 219-223. PMID: 27810017.
36. Daniel CR 3rd, Iorizzo M, Piraccini BM, Tosti A. Grading simple chronic paronychia and onycholysis. *Int J Dermatol* 2006; 45: 1447-1448. PMID:17184257. 2006;17184257.
37. Turkmen A, Warner RM, Page RE. Digital pressure test for paronychia [2]. *Br J Plast Surg*. 2004;57(1):93-4.
38. Aluja Jaramillo F, Quiasúa Mejía DC, Martínez Ordúz HM, González Ardila C. Nail unit ultrasound: a complete guide of the nail diseases. *J Ultrasound*. 2017;20(3):181-92.
39. Raff AB, Kroshinsky D. Cellulitis a review. *JAMA - J Am Med Assoc*. 2016;316(3):325-37.
40. Patel DB, Emmanuel NB, Stevanovic M V., Matcuk GR, Gottsegen CJ, Forrester DM, et al. Hand infections: Anatomy, types and spread of infection, imaging findings, and treatment options. *Radiographics*. 2014;34(7):1968-86.
41. Pierrart J, Delgrande D, Mamane W, Tordjman D, Masméjean EH. Acute felon and paronychia: Antibiotics not necessary after surgical treatment. Prospective study of 46 patients. *Hand Surg Rehabil* [Internet]. 2016;35(1):40-3. Available from: <http://dx.doi.org/10.1016/j.hansur.2015.12.003>
42. Grover C, Bansal S, Nanda S, Reddy BSN, Kumar V. En bloc excision of proximal nail fold for treatment of chronic paronychia. *Dermatologic Surg*. 2006;32(3):393-9.
43. Shafritz AB, Coppage JM. Acute and chronic paronychia of the hand. *J Am Acad Orthop Surg*. 2014;22(3):165-74.
44. Carley SD. Towards evidence based emergency medicine: Best BETs from the Manchester Royal Infirmary. *Emerg Med J*. 2005;22(11):813.
45. Pabari A, Iyer S, Khoo CT. Swiss roll technique for treatment of paronychia. *Tech Hand Up Extrem Surg*. 2011;15(2):75-7.