

Schizencephaly: a case report

Abstract

Schizencephaly is a rare anomaly of embryonic development characterized by the presence of linear fissures containing cerebrospinal fluid and lined with dysplastic gray matter, extending from the pial surface of the cerebral hemisphere to the ependymal surface of the lateral ventricle. Schizencephaly can affect one or both cerebral hemispheres, leading to a variety of neurological symptoms such as epilepsy, motor deficits and psychomotor retardation. An antenatal diagnosis can be made; treatment is based on rehabilitation, antiepileptic drugs and supportive psychotherapy.

We report the case of a 3-year-old child admitted to our department for a generalized tonicoclonic convulsive seizure resistant to antiepileptic treatment. The child's antecedents included a well-monitored pregnancy carried to term, and a vaginal delivery with no evidence of neonatal distress. The parents are not consanguineous, but there have been two deaths in the siblings (at 15 days and 40 days) of unknown origin. The child also showed delayed psychomotor development.

An MRI scan revealed a type I right schizencephaly with a closed cleft, but biology revealed no abnormalities, and genetic studies are still in progress.

Management to date is based on antiepileptic drugs, psychomotor rehabilitation and sometimes surgery.

Introduction:

Schizencephaly is a rare congenital malformation of cerebral cortical development, characterized by a cleft extending from the surface of the pie-mother to the cerebral ventricles. Two anatomical types of schizencephaly are described: type I (closed cleft walls) and type II (open cleft walls with coexisting "hydrocephalus").

1. **Case Presentation:**

We report the case of a 3-year-old child admitted to our department for a generalized tonicoclonic convulsive seizure resistant to treatment and a hemorrhagic syndrome with rectal bleeding. The child's history included a well-monitored pregnancy carried to term, and a vaginal delivery with no evidence of neonatal distress. The parents are non-consanguineous, but there have been two deaths in the siblings (at 15 days and 40 days) of unknown origin.

The child had also undergone surgery for an inguinal hernia at the age of 5 months.

Since the age of 2, this child has suffered from generalized seizures resistant to treatment, and psychomotor retardation: walking and speech have not yet been acquired.

On clinical examination, the child was unable to stand, had muscle strength rated at 3/5 in both upper limbs, and was able to speak a few words. Osteotendinous reflexes were present in all 4 limbs.

Examination of the cranial pairs was difficult, given the patient's agitation.

The evolution was marked by persistent epileptic seizures that became increasingly resistant to treatment, complicated by a haemorrhagic syndrome with rectorrhagia.

PARACLINICAL EXAMINATIONS:

In view of this clinical symptomatology, a biological work-up was carried out, with normal results.

CT scan :

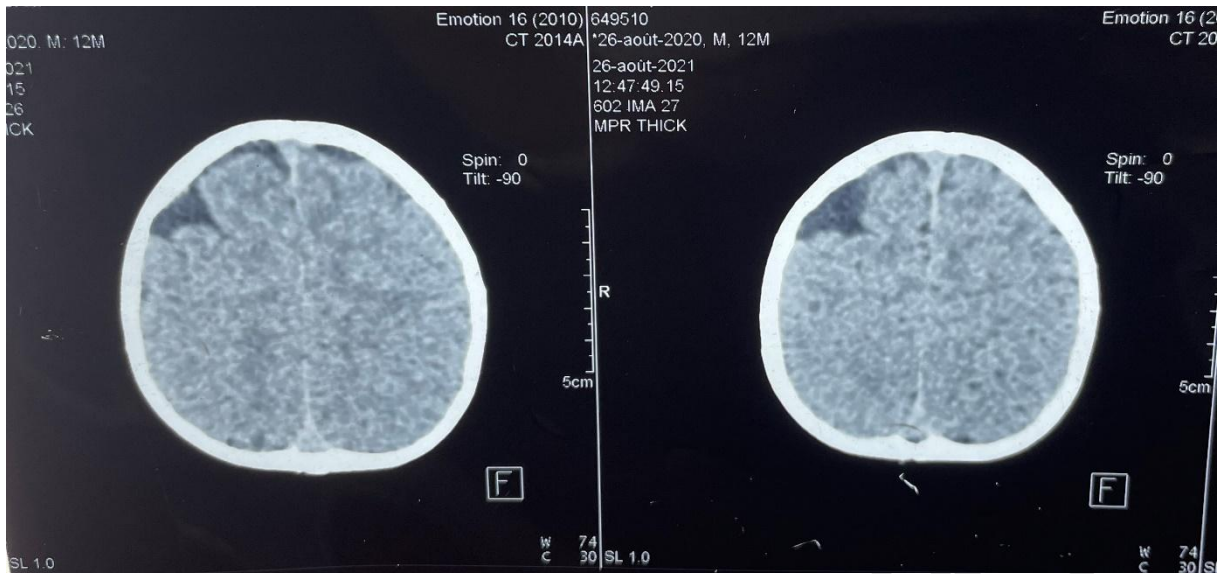


Figure 1: Cerebral CT in favor of right frontal schizencephaly with closed cleft.

Brain MRI:

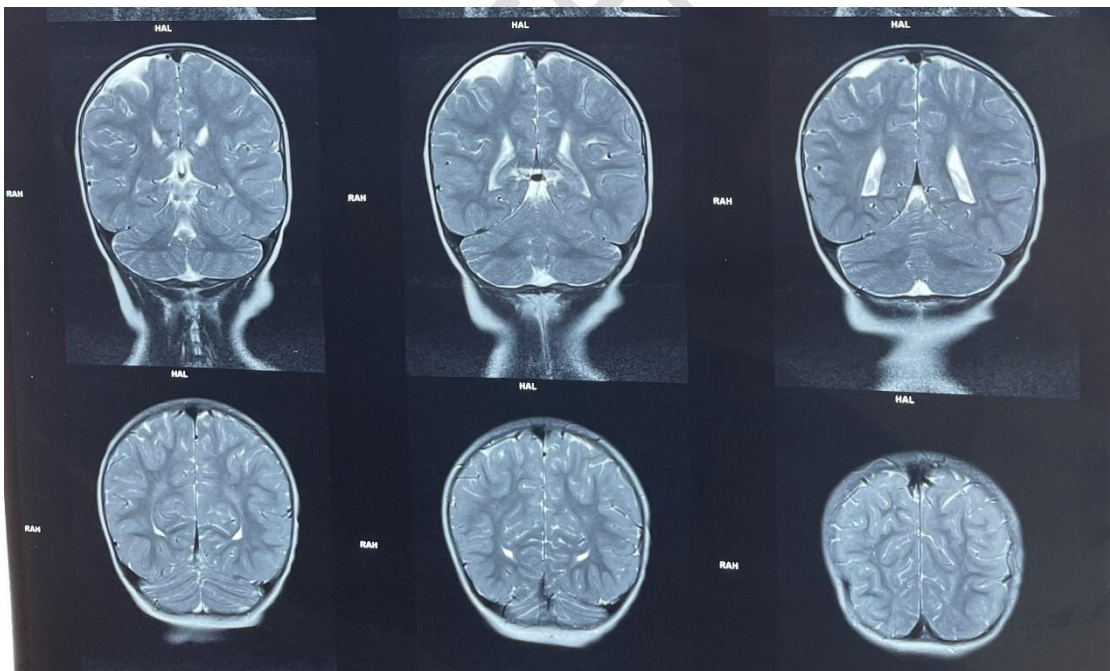


Figure 2: T2 MRI scan showing right frontal schizencephaly with closed cleft (type 1)

No other associated malformation .

MANAGEMENT :

The patient was put on oral antiepileptic treatment with dual therapy, psychomotor rehabilitation and follow-up with a speech therapist.

On the other hand, for his rectal bleeding problem, he underwent several check-ups that shows no abnormalities including : hemolysis test, Fecal calprotectin.

The colorectal biopsy with anatomopathological study showed normal appearance of colonic mucosa; an absence of granuloma; and an absence of dysplasia.

The diagnostic hypothesis is more in favour of a connective tissue anomaly explained by the initial pathology, schizencephaly.

2. Discussion:

Schizencephaly is a rare condition defined by an abnormality in the gyral formation, resulting from interruptions in neuronal migration early in pregnancy [1]. It is associated with mutations in the COL41 gene, which codes for the main chain of type IV alpha collagen in basement membranes, including vascular membranes. This could shed light on their susceptibility to embrittlement, hence the possible occurrence of a hemorrhagic syndrome.

The disease results in delayed psychomotor development and often severe and refractory epilepsy, influencing cognitive learning abilities. The prevalence of schizencephaly is estimated at 1.54 per 100,000 births [2], with an incidence of 1

in 1,650 children with epilepsy [3]. There is no clear distinction between the sexes, although Stopa et al [6] have reported a slight predominance in boys. Usually, the diagnosis is made in childhood or before the age of 10, when the cause of seizures or unexplained neurodevelopmental delays is sought [13]. Our patient was diagnosed at the age of 3.

The exact cause of schizencephalia remains undetermined.

Two main hypotheses have been put forward to explain the pathogenesis of schizencephaly. The first suggests the intervention of an exogenous agent during the embryonic period between the 12th and 17th weeks of gestation, leading to a defect in neuroblast migration. Mechanisms could include ischemia, often associated with the middle cerebral artery territory, linked to the mother's youth, or fetal distress following maternal trauma, fetal infection due to cytomegalovirus, prenatal exposure to substances such as cocaine or other alpha stimulants, or even carbon monoxide intoxication [Norman and McGillivray, 1995].

The second hypothesis suggests an endogenous cause. Indeed, family cases associated with a mutation in the EMX2 gene have been reported, highlighting a possible genetic component in the onset of schizencephalia. Maternal youth, as observed in a 16-year-old patient by Ondo Apo OF et al. in Gabon [8], has been highlighted. Although the evidence points to a possible genetic origin, the financial circumstances of our patient's parents precluded genetic testing.

Schizencephaly is known to present in two anatomical forms: types I and II [9]. Clefts can occur bilaterally, unilaterally, symmetrically or asymmetrically, usually predominating in the parietal and frontal lobes. Occipital localization is rare. Schizencephaly frequently coexists with other congenital anomalies, including polymicrogyria, heterotopia, agenesis of the septum pellucidum, agenesis of the corpus callosum and septo-optic dysplasia [10]. Our subject presented with unilateral type I schizencephaly, located in the left fronto-parietal region.

The clinical manifestation of schizencephaly depends mainly on the bilaterality of the cleft. The size and location of the cleft are also key prognostic factors. Type I usually presents later, with seizures occurring in 50-60% of cases [11]. Type II, on the other hand, manifests itself during the neonatal period, characterized by microcephaly, significant psychomotor retardation and epileptic seizures.

The semiology of seizures and the electroencephalographic abnormalities observed remain poorly documented in the literature.

Ondo Apo OF et al [8] reported a case in which the epileptic manifestations were essentially focal. Magnetic resonance imaging (MRI) is the preferred examination because of its ability to accurately distinguish gray matter and provide detailed information on cortical structure, while offering multiplanar views. Consequently, MRI is considered the diagnostic tool of choice, particularly when a disturbance of neuronal migration is suspected [12].

In our patient, signal irregularities in the bilateral occipital white matter were identified, suggesting a possible anoxic origin in relation to his illness.

The treatment strategy for schizencephaly is mainly conservative, whether type I or type II. It aims to treat motor deficits and cognitive delays. In addition, medication is often required to manage epileptic seizures. Because of the central location of lesions and the vast extent of epileptogenic regions, surgery is complicated. It is generally considered in specific situations, such as in the presence of associated hydrocephalus or intracranial hypertension [12].

In our case, the patient benefited from anti-epileptic treatment, as well as motor rehabilitation and psychotherapy. This approach is similar to that adopted by Ondo Apo et al [8] and Nang FG et al [4], both of whom observed comparable results, including cessation of seizures on treatment. However, cognitive and motor deficits remained. With regard to her haemorrhagic syndrome, regular follow-up was established, with hospitalization if necessary.

CONCLUSIONS.

Schizencephaly is a rare embryonic malformation, manifested by cerebrospinal fluid-filled clefts bordered by altered gray matter, connecting the lateral ventricle to the outer cortical surface. It can affect one or both hemispheres of the brain, giving rise to a variety of neurological symptoms, such as epileptic seizures, motor disorders and delayed psychomotor development. Diagnosis during pregnancy is possible. The treatment strategy is based mainly on rehabilitation, antiepileptic drugs and supportive psychotherapy.

Consent

As per international standards, parental written consent has been collected and preserved by the author(s).

References :

1. Cianfoni A : Schizencéphalie. Brain Imaging with MRI CT : An Image Pattern Approach. Rumboldt Z, Castillo M, Huang B, Rossi A (ed) : Cambridge University Press, Cambridge, Royaume-Uni ; 2012. 173-174.
2. Curry CJ, Lammer EJ, Nelson V, Shaw GM. Schizencephaly: Heterogeneous etiologies in a population of 4 million California births. Am J Med Genet A 2005;137:1819.
3. Kopyta I, Skrzypek M, Raczkiwicz D, Bojar I, SareckaHujar B. Epilepsy in pediatric patients with schizencephaly. Ann Agric Environ Med. 2020; 27(2): 279–283.
4. FG Niang, I Drady, A Athia, I Niang, AR Ndong, M Diedhiou, AN Diop. Bilateral wide open slit schizencephaly: about a case: Jaccr Africa 2020 (4), 4 :1-3.

5. Kamble V, Lahoti AM, Dhok A, Taori A, Pajnigara N. A rare case of schizencephaly in an adult with late presentation *Journal of Family Medicine and Primary Care. J Family Med Prim Care.* 2017 Apr-Jun; 6(2): 450–452.
6. Stopa J, Kucharska-Miasik I, Dziurzynska-Bialek E, Kostkiewicz A, Solinska A, Zajac-Mnich M, et al. Diagnostic imaging and problems of schizencephaly. *Pol J Radiol* 2014;79:4449.
7. Habib Bellamlih, Meryem Echchikhi, Mohammed Jiddane, Meriem Fikri. Schizencephaly of late discovery in an adult. *The Press Med Formation.* 2021 ; 2 :429–4
8. Paul D. Griffiths. Schizencephaly revisited. *Neuroradiology* (2018) 60:945–960.
9. Tiziana Granata, Elena Freri, Claudio Caccia et al. Schizencephaly: Clinical Spectrum, Epilepsy, and Pathogenesis. *J Child Neurol* 2005;20:313–318).
10. Vinícius Lopes Braga, Marcos Devanir Silva da Costa et al. Schizencephaly: A review of 734 cases. *Pediatric Neurology* (2018).
11. Ondo Apo OF1, Gnigone PM1, Nyangui Mapaga J1, Ongoly S1, I'm Not Afraid M1, I'm Not Afraid PH1 Open Slit Schizencephaly. *Health Sci. This: April* 2022 ; Vol 23(4):p 112–114
12. Halabuda, A. et Al. Schizencephaly diagnostic and clinical dilemmas. *Childs Nerv Syst* 2015 ; 31 :551–556 PubMed]
13. Leu-Semenescu S, Epelbaum S, de Broucker T. Open and closed schizencephaly. *Rev Neurol (Paris)* 2005; 161 : 3, 355–3