

Effect of *Vernonia amygdalina* and *Moringa oleifera* on some liver parameters in alloxan – induced diabetic rats

ABSTRACT

Aim: To assess the effect of *Vernonia amygdalina* and *Moringa oleifera* on some liver function parameters in Alloxan – induced diabetic rats.

Study design: Experimental study

Place and Duration of Study: Departments of Biochemistry and Histology, Imo State University, Owerri, Nigeria, between September 2014 and September 2016.

Methodology: Thirty (30) rats weighing between 180- 200g/kg body weight was divided into five groups of six rats each. Group 1 is the control group, received normal diet. Group 2 is the diabetic group, received Alloxan (150mg/kg body weight) and not treated with plant extract. Group 3 received Alloxan and treated with only one plant extract (VA). Group 4 received Alloxan and treated with only one plant extract (MO). Group 5 received Alloxan and treated with combined plant extracts of (VA and MO). Fasting blood glucose (FBG), Serum alanine aminotransferase (ALT), aspartate aminotransferase (AST), alkaline phosphatase (ALP) and histology of the liver analyzed after 28 days treatment.

Results: Results showed that there was significant increase in glucose levels of the rats in the group 2 (diabetes induced group). More so, the VA plant extract reduced the levels of glucose, ALT, AST and ALP in group 3. There was also a significant reduction in glucose, levels, ALT, AST and ALP in group 4. The combined therapy of aqueous plant extracts of VA and MO much more reduced the levels of glucose, ALT, AST and ALP in group 5 when compared with the diabetic group. The results were confirmed by histological studies which revealed marked distortions and degenerations of hepatic and renal tissues in the diabetic group and significant reduction and amelioration of the disorders in Alloxan + VA group, Alloxan + MO group, and Alloxan + VA + MO group.

Conclusion: The combined therapy of plant extracts of VA and MO had synergistic effects on hepatic tissues in diabetes and could provide a cheap alternative to treating diabetes associated hepatic disorders.

Keywords: *Vernonia amygdalina*, liver, alloxan – induced diabetic rats

1. INTRODUCTION

Diabetes Mellitus (DM) is a collection of metabolic disorders characterized by persistently elevated blood sugar levels. Diabetes results from either insufficient insulin production by the pancreas or improper insulin cellular response [1]. Polyuria, glucosuria, polydipsia, dehydration, and heightened hunger are among the symptoms [2].

Diabetes is linked to hepatitis, fibrosis, cirrhosis, and fatty liver (steatosis), among other liver pathologies and liver injury in diabetics [3]. The most measured sign of liver illness is elevated serum activity of the three main liver enzymes: alkaline phosphatase, alanine aminotransferase, and aspartate aminotransferase. This is more common among diabetics

than in the general population [4]. Overweight people without diabetes have also been shown to exhibit the same range of liver damage and alterations in enzyme levels as those with diabetes. It has been shown that hepatic fat accumulation occurs in between 70 and 80 percent of diabetic patients [5]. Moreover, research revealed that NIDDM patients had elevated liver enzyme activity, including AST, ALT, and ALP [6]. Hyperglycemia, a hallmark of diabetes mellitus, has been closely associated with nephropathy; individuals with diabetes are susceptible to end-stage renal disease [7].

Vernonia amygdalina, known as Barambo in Hausa, Ewele in Yoruba, and Odudu Oyibo in Igbo, is a member of the Asteraceae family and is a medicinal plant of great importance, with a focus on its medicinal properties. But the plant is also helpful to ecology because it releases oxygen during photosynthesis, which aids in the environment's attractiveness and cleansing. Additionally, *V. amygdalina* can be utilized as a dietary supplement when cooked with melon, a nutrient-dense African meal (egusi soup). According to FAO (2004), malnutrition affects 815 million people in developing nations, with babies and children being the most affected. Unfortunately, cereals, animal production, and roots/tubers have received disproportionate attention in the efforts to increase food production and accessibility in these areas. However, the often-ignored dark green leafy vegetables can significantly reduce malnutrition by supplementing other types of nutrients.

Although *Moringa oleifera* is a plant with several traditional uses, leaves are typically the most utilized portion of the plant [8]. They are utilized in traditional medicine as well as in the nourishment of humans and animals. Protein, minerals, beta-carotene, and antioxidant compounds—all of which are frequently deficient in populations in developing or undeveloped nations—are abundant in leaves. As dietary integrators, moringa leaves are added to food preparations. These leaves are used in traditional medicine to cure a variety of conditions, such as genito-urinary disorders, diabetes, arthritic conditions, typhoid fever, parasite illnesses, swollen areas, wounds, and skin conditions. Along with cardiac stimulants and contraceptive medication, they are also used to induce lactation and strengthen the immune system (to treat HIV/AIDS related symptoms) (Sivasankari et al., 2014). It is possible to ingest the extract of an aqueous infusion or raw, dried leaves directly.

A deficiency in β -cell mass appears to be the primary cause of hyperglycemia in non-insulin dependent diabetes mellitus (NIDDM), according to studies. While there is a 25–50% decrease in beta-cell mass at the time of NIDDM diagnosis, there are two possible explanations for the exceptionally high rate of beta-cell loss: either a reduced capacity for proliferation or an increased rate of cell division. The liver is a vital and central organ. Abnormal liver enzymes, cirrhosis, hepatocellular carcinoma, nonalcoholic fatty liver disease (NAFLD), and acute liver failure are among the complications of diabetes mellitus related to the liver. Hepatic disease is highly prevalent in patients with diabetes mellitus, and DM is highly prevalent in patients with liver disease. The medicinal benefits of plant extracts of *Vernonia amygdalina* (VA) and *Moringa oleifera* (MO) separately in various experimental models, such as diabetes-induced hepatotoxicity and nephrotoxicity, have been extensively documented in the literature. The combined effects of *Vernonia amygdalina* and *Moringa oleifera* extract on diabetes nephrotoxicity, hepatotoxicity, and histological changes in a diabetic model, however, have not been studied. This study evaluated the impact of *Moringa oleifera* and *Vernonia amygdalina* on a few liver function parameters in rats treated with alloxan.

2. MATERIALS AND METHODS

2.1 Plant Materials

Fresh matured *Vernonia amygdalina* (VA) and *Moringa oleifera* (MO) leaves were harvested from the neighborhood compound in Owerri metropolis. The leaves were rinsed severally with clean tap water to remove dust particles and debris and allowed to air dry completely. The plants were identified by Dr. Mbagwu V. of the department of plant science and biotechnology of Imo state University, Owerri.

2.1.1 Preparation of Plant Extract

The leaves of VA and MO were separately ground to a powdered form. 100grams of each powdered leave was dissolved in one litre of warm distilled water and left for 48hours in a refrigerator at 4°C to allow for thorough extraction of the plant's active components. These were then filtered with a cheese cloth and later with Whatman no 1 filter paper to obtain a homogenous filtrate. The filtrates were then concentrated, and the concentrates were allowed open in a water bath at 40°C to allow for complete dryness. A greenish brown substance of *Vernonia amygdalina* and *Moringa oleifera* were recovered and preserved separately.

2.2 Experimental Animals

Thirty adult male albino rats weighing between 180 and 200 grams obtained from the department of Anatomy Imo State University Owerri, Nigeria were used for this study. The animals were placed in standard cages maintained in 12 light; dark cycle under conditions of temperature and relative humidity.

2.2.1 Experimental Induction of Diabetes

Diabetes was induced in twenty - four overnight fasted rats by a single intraperitoneal injection of Alloxan (Sigma - Aldrich ST. Louis, USA) at a standard dose of 150 mg per kilogram body weight, dissolved in 0.85 gram per 100 ml normal saline solution. The Animals were confirmed diabetic if the glucose level of blood of fasted animals, collected from tail vein after 48 hours of injection of Alloxan was above 120 mg/dl (7.0 mmol/l) as determined with an automated glucose analyzer device (One touch glucometer, Acon Laboratories Inc, USA).

2.3 Experimental Design

Thirty (30) rats were divided into five experimental groups of six rats each:

Group 1: formed the normal control group (NC) and were fed with rat diet and distilled water only.

Group 2: formed the positive control group - diabetic group not treated with plant extracts. They were induced with diabetes using Alloxan and fed with rat diet and water.

Group 3: rats were induced diabetic rats and treated with only *Vernonia amygdalina* (VA) extract at a standard dose of 200 mg per kilogram body weight.

Group 4: were induced diabetic rats and treated with *Moringa oleifera* (MO) extract at a standard dose of 200 mg /kg body weight.

Group 5: were induced diabetic rats and treated with combined plant extracts of *Vernonia amygdalina* and *Moringa oleifera* at a standard dose of 200 mg/kg body weight of the rats.

The two plant extracts, reconstituted in distilled water were administered orally through gastric intubation, at a standard dose of 200 mg per kilogram body weight for a single extract

treatment, and 400mg per kilogram body weight for combined extracts treatment, the optimal dose. The duration of treatment was 28 days after induction of diabetes. At the end of the experimental periods, the rats were fasted for 12 hours, then anaesthetized under chloroform vapor and sacrificed. Whole blood was obtained by cardiac puncture into sterile plain tubes and allowed to clot for thereafter centrifuged to remove the cells. Serum removed was used for the biochemical assays. The Liver was also surgically removed for histological studies.

2.4 Laboratory Analysis

All reagents were purchased, and manufacturer's standard operational procedure (SOP) strictly adhered to.

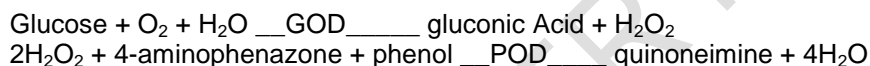
2.4.1 Determination of Glucose (Randox Kit Catlog No__ GL 364)

2.4.1.1 Method

Glucose Oxidase Method

2.4.1.2 Principle

Glucose is determined after enzymatic oxidation in the presence of glucose oxidase. The hydrogen peroxide formed, reacts under catalysis of peroxidase, with phenol and 4-aminophenazone to form a red violet quinoneimine dye as indicator.



2.4.2 Determination of ALT (Randox Kit Catlog No --- Al 100)

2.4.2.1 Method

Spectrophotometric method

2.4.2.2 Principle.

ALT is measured by monitoring the concentration of pyruvate hydrazone formed with 2,4 – dinitrophenylhydrazine. α - oxoglutarate + L – Alanine GPT L – glutamate + pyruvate
Method

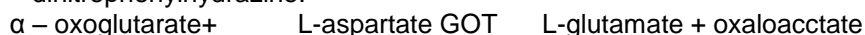2.4.3 Determination of AST (Randox Kit Catlog No---AS 101)

2.4.3.1 Method

Spectrophotometric method

2.4.3.2 Principle

AST is measured by monitoring the concentration of oxaloacetate hydrazone formed with 2,4 – dinitrophenylhydrazine.



(Normal values 0 -12 μ /L)

2.4.4 Determination ALP (Randox Kit Catlog NO –AP 542)

2.4.4.1 Method

Spectrophotometric method

2.4.4.2 Principle

The substrate, para-nitrophenyl phosphate (PNPP) is hydrolysed by ALP to para-nitrophenol and phosphoric Acid. The intensity of the yellow colour formed in alkaline medium measured at 405nm is directly proportional to the alkaline phosphate activity.



2.5 Tissue Preparation for Histological Study.

Dissected Liver tissues were immediately fixed in 10% formal saline and kept at 4°C. After fixing for 48 hours, a transverse section was made at the middle part of each Liver and kept immersed in the fixative for the completion of tissue fixation. The formal saline samples were then embedded in paraffin and sectioned into slices 6- 7 µm thick. The tissue slices were mounted onto Albumin-precoated glass slides, de-paraffined with xylene and stained with Hematoxylin and Eosin (H&E). The stained sections were studied under a light Microscope.

2.6 Statistical Analysis

Results were analyzed using SPSS 16. All data were reported as mean ± SD and test of significance was done using one-way ANOVA with 95% confidence limit.

3. RESULTS AND DISCUSSION

Table 1: Comparisons of glucose values for all groups

Parameter/Group	Glucose Urea (mmol/l)
Group 1 (N=6)	4.217 ± 0.584 ²
Group 2 (N=6)	16.22 ± 0.679 ^{3,4,5}
Group 3 (N=6)	9.867 ± 0.697 ^{4,5}
Group 4 (N=6)	8.283 ± 0.679
Group 5 (N=6)	5.300 ± 0.374
F-value	355.5
P-value	<0.0001
Remark	S

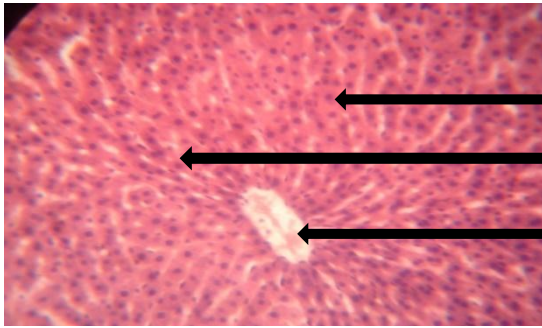
Key: S – significant (ANOVA), 2,3,4,5 significant compared to the number of group

Table 2: Comparisons of Liver enzymes levels for all groups

Parameter/Group	ALT (U/L)	AST (U/L)	ALP (U/L)
Group 1 (N=6)	7.017 ± 1.021 ²	6.200 ± 0.989 ²	8.067 ± 0.725 ²
Group 2 (N=6)	30.98 ± 2.368 ^{3,4,5}	27.17 ± 1.176 ^{3,4,5}	40.43 ± 1.391 ^{3,4,5}
Group 3 (N=6)	17.28 ± 2.724 ⁴	13.45 ± 0.717 ⁵	19.33 ± 0.983
Group 4 (N=6)	19.83 ± 1.209	13.13 ± 0.535	19.37 ± 1.143
Group 5 (N=6)	8.550 ± 0.671 ^{3,4}	8.217 ± 0.545 ⁴	20.32 ± 1.813
F-value	175.7	580.7	513.9
P-value	<0.0001	<0.0001	<0.0001
Remark	S	S	S

Key: S – significant (ANOVA), 2,3,4,5 significant compared to the number of group

Histological reports of the Liver and Kidney of control and treated rats

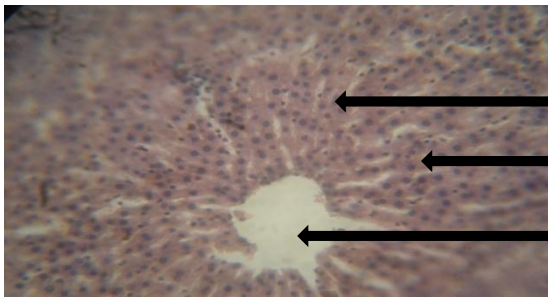


Normal polyhedral shaped hepatocytes

Normal acidophilic cytoplasm

Central vein

Plate 1: Photomicrograph of the section of the Liver of the normal control group. The section shows a hepatic lobule with the central vessel. The endothelium of the vessel is intact. The sinusoids radiate in its normal pattern. The hepatocytes appear in cords and lodged multi nuclei. Connective tissues are intact.

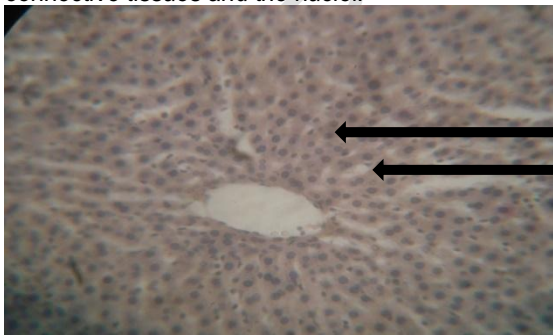


Distorted connective tissues

Deranged cytoplasm

Constricted central vessel

Plate 2: Photomicrograph of the hepatic lobule of rats not treated with plant extract after diabetes induction. The section shows a Liver lobule with a constricted central vessel, from which the sinusoids radiate out. The hepatocytes appear in cords with multi nuclei. There is marked degeneration of the connective tissues and the nuclei.



Normal polyhedral shaped hepatocytes

Plate 3: Photomicrograph of the section of the liver of diabetic rats treated with only Vernonia amygdalina (VA) plant extract. The section shows a hepatic lobule with slight distortion of the central vessels. The sinusoids are constricted by the dilated hepatocytes, though in hexagonal pattern. There are slight degenerations of the connective tissues.

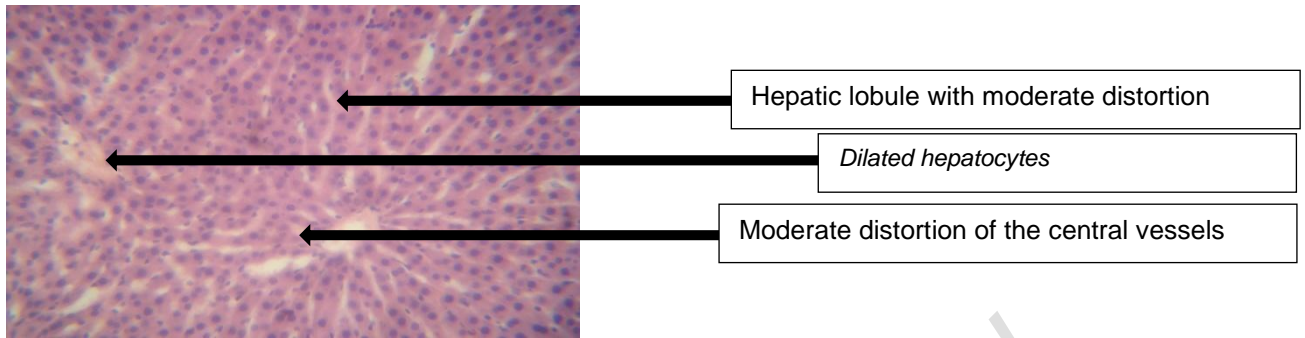


Plate 4: Photomicrograph of the section of the liver of diabetic rats treated with only *Moringa oleifera* (MO) plant extract. The section shows a hepatic lobule with moderate distortion of the central vessels. There is also moderate degeneration of the connective tissues. The sinusoids are constricted by the dilated hepatocytes.

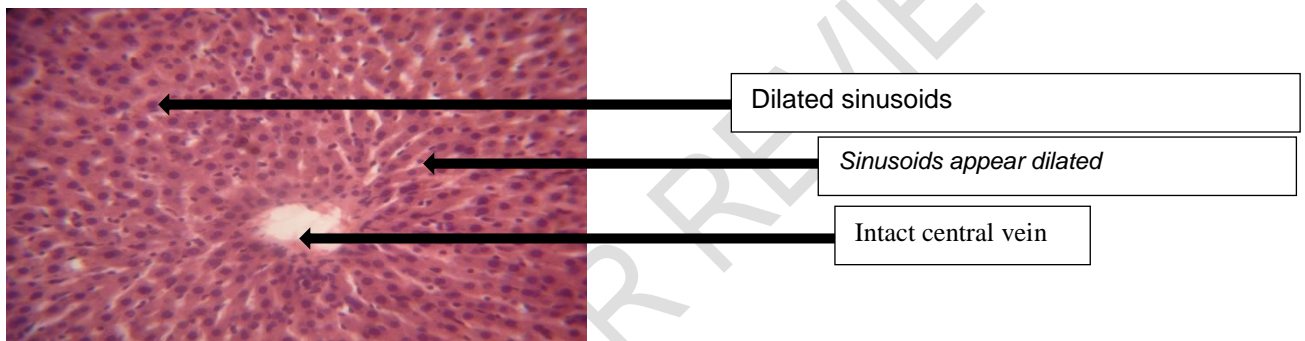


Plate 5: Photomicrograph of the section of the Liver of diabetic rats treated with combined *Vernonia amygdalina* and *Moringa oleifera* plant extracts. The section shows a hepatic lobule with its central vessel whose endothelium appeared intact. The sinusoids appear dilated and radiate in its normal pattern. There were hypertrophy of the hepatocytes and their multi nuclei. The connective tissues are intact.

In this study, the mean \pm SD values for rats in the normal control group that received rat diet and water were ALT (7.0 ± 1.02 U/L), AST (6.2 ± 1.03 U/L), ALP (8.1 ± 0.74 U/L) and glucose (4.3 ± 0.49 mmol/l). The mean \pm SD of values of glucose (13.7 ± 0.88 mmol/l) of rats not treated with plant extract after diabetes induction by Alloxan were significantly increased ($p < 0.05$) when compared with the normal control group (4.3 ± 0.49 mmol/l). This is probably due to the devastating effect of alloxan on the pancreatic islet cells, by destroying the insulin-secreting cells of the Islet of Langerhans. This report agrees with Kaneto *et al.* [9], who, in his report attributed such pathological changes to glucotoxicity, which arises from excessive uptake of glucose by islet beta cells in diabetes. The excess sugar drives glycation reactions and the mitochondrial electron chain, producing macromolecular damaging reactive oxygen species (ROS), at levels beyond the antioxidant capacities of the cells. The ensuing oxidative stress impairs insulin synthesis and secretion and initiates a cascade of cellular events that lead to beta cell cytotoxicity and death. Similar findings were observed and reported by Erhirhie *et al.*, [10] and Oluwole *et al.* [11] who reported in several experimental diabetic literatures that the standard dose of 150mg/kg body weight of Alloxan was adequate for induction of diabetes in rats through intraperitoneal route. According to their findings, this dose treatment of Alloxan induces a more rapid loss of insulin secretion and a more rapid onset of diabetes compared with low dose treatment. According to Dhanesha *et al.* [12] findings on the mechanism of Alloxan action, reported that the toxic action of Alloxan on pancreatic beta cells involves, oxidation of essential sulfhydryl(-SH) groups, inhibition of

glucokinase enzyme, generation of free radicals and disturbances in intra- cellular calcium homeostasis. Lenzen, [13] reported in his study that the underlying mechanism involves the selective up take of the compound due to its structural similarity to glucose as well as highly efficient up take mechanism of the pancreatic beta cells. Another mechanism reported by Ebel et al. [14] is the effect of reactive oxygen species (ROS) on the DNA of pancreatic islets. The fragmentation of DNA takes place on the beta cells exposed to Alloxan that causes DNA damage, which stimulates poly- ADP- ribosylation, a process participating in DNA repair.

In the present study, the mean \pm SD values of ALT (30.5 ± 2.77 U/L), AST (27.8 ± 1.73 U/L), and ALP (40.8 ± 1.16 U/L) of rats not treated with plant extract after diabetes induction by Alloxan were significantly increased when compared with the normal control group, ALT (7.0 ± 1.02 U/L), AST (6.2 ± 1.03 U/L) and ALP (8.1 ± 0.74 U/L). The increased activities of these enzymes in the diabetic group were probably because of increased concentration of these enzymes (ALT, AST and ALP) in the serum of diabetic rats, which could be attributed to reactive oxygen species (ROS) mediated lipid peroxidation that distorts the Liver cell architecture, thus releasing the Liver cell content into circulation. These findings agree with Burtis et al [15] who reported elevated levels of liver enzymes such as ALT, AST and ALP in acute hepatitis, viral hepatitis, and hepatocellular damage. In the present study, the mean \pm SD values of ALT (17.0 ± 3.03 U/L), AST (13.8 ± 1.08 U/L), ALP (19.6 ± 1.07 U/L) and glucose (8.9 ± 1.39 mmol/l) of rats treated with only one plant extract (VA) after diabetes induction by Alloxan were reasonably reduced when compared with the diabetic group. This could be attributed to the ameliorative effect of *Vernonia amygdalina* on the liver and glucose levels of the rats. These teams reported on the ameliorative and protective effects of VA which they discovered that oral administration of plant extract from VA could accelerate the reversion of liver damage through reduction of liver marker enzymes such as ALT, AST and ALP. In this study, the mean \pm SD values of ALT (19.4 ± 1.68 U/L), AST (13.1 ± 0.54 U/L), ALP (19.3 ± 1.08 U/L) and glucose (9.6 ± 0.87 mmol/l) of rats treated with only one plant extract (MO) after diabetes induction by Alloxan were moderately reduced when compared with the diabetic group. This could be attributed to the ameliorative effect of *Moringa oleifera* on the diabetic rats. These findings were confirmed by histological examinations which revealed an amelioration of the hepatic induced by drugs in animals treated with *Moringa oleifera* plant extract. Das et al. [16] observed a reduction of ALT, AST and ALP and a lower Liver damage in rats fed with high fat diet and co – treated with *Moringa oleifera* plant extract, suggesting a potential role of MO in the prevention of non- alcoholic fatty Liver disease (NAFLD). In the present study, the mean \pm SD values of ALT (8.5 ± 0.75 U/L), AST (8.0 ± 0.66 U/L), ALP (20.1 ± 1.41 U/L), Urea (6.4 ± 1.14 U/L), Creatinine (74.6 ± 7.23 U/L) and glucose (7.9 ± 0.78 U/L) of rats treated with combined plant extracts of *Vernonia amygdalina* and *Moringa oleifera* (VA +MO) after diabetes induction by Alloxan were much more reduced when compared with the diabetic group. This could be attributed to the synergistic potential of the combined plant extracts of VA and MO on the **liver** and glucose levels of Alloxan induced diabetic rats.

In the present study, the photomicrograph of the section of the liver of the normal control group showed intact and normal endothelium and connective tissues (Plate 1). In the diabetic group (Plate 2), the histological reports showed marked distortions and degenerations of liver tissues. These could be attributed to diabetic disorders and complications. In the Alloxan and VA group (Plate 3), the section of the liver showed a hepatic lobule with reduced distortion of the central vessels. This could be attributed to the ameliorative effect of VA plant extract on liver tissues. Also, in the Alloxan and MO group (Plate 4), the section of the liver showed a hepatic lobule with reduced distortions of the central vessels. There were decreased degeneration of the connective tissues. This could also be attributed to the ameliorative and protective effects of MO on the Liver tissues. This

was also in agreement with Kakey et al. [17] Pari and Kumari [18] Ouedraogo et al. [19] who reported on the ameliorative properties of MO plant extract.

In the Alloxan, VA and MO group ((Plate 5), the photomicrograph of the section of the liver showed a hepatic lobule with an intact central vessels, endothelium, and connective tissues. This could be attributed to the synergy provided by the combined therapy of the two plant extracts (VA + MO) in ameliorating and protecting Liver tissues. These findings agreed with Kakey et al. [17], Babalola et al. [19] and Atangwho et al. [20].

4. CONCLUSION

VA and MO extracts significantly reduced high levels of AST, ALT and ALP caused by alloxan induced diabetes in rats. The combined therapy of plant extracts of VA and MO had synergistic effects on hepatic tissues in diabetes and provided a cheap alternative to treating diabetes associated hepatic disorders.

ETHICAL APPROVAL

All authors hereby declare that Principles of laboratory animal care (NIH publication No. 85-23, revised 1985) were followed, as well as specific national laws where applicable. All experiments have been examined and approved by the appropriate ethics committee.

REFERENCES

1. Shoback, edited by David G. Gardner, Dolores "Chapter 17". Greenspan's basic & clinical endocrinology (9th ed.). New York: McGraw-Hill Medical. ISBN 0-07-162243-8. 2011.
2. Malik VS, Popkin BM, Bray GA, Després JP, Hu FB. "Sugar Sweetened Beverages, Obesity, Type 2 Diabetes and Cardiovascular Disease risk". *Circulation*, 2010; 121 (11):1356–64.
3. Erbey JR, Silberman C, Lydick E. Prevalence of abnormal serum alanine aminotransferase levels in Obese patients and patients with type 2 diabetes: *Am J. med*, 2002; 109:588-90.
4. Everhart J.E. Diabetes in America 2nd ed. National Institute of health. National Institute of diabetes and digestive and kidney diseases. Washington, DC: DPO; 457-83. 1995.
5. Gupte P, Amarapurkar D, Agal S, Kulshrestha P, Pramanik S. Non-alcoholic steatohepatitis in type 2 diabetes mellitus. *J. Gastroenterol, Hepatol*, 2004; 19:854 – 8.
6. Wannamethee Sg, Shaper AG, Lennon L, Whincup PH. Hepatic enzymes, the metabolic syndrome, the risk of type 2 diabetes in older men. *Diabetes, 2005; Care*, 28:2913-18.
7. Held PJ, Port FK, Webb RL, Garcia JR, Blagg CR, Agodoa Ly. The United States Renal data systems 1991 annual data report: an introduction. *AM. J Kidney Disr*, 18, 1-16.
8. Popoola, J.O.; Obembe, O.O. Local knowledge, use pattern and geographical distribution of *Moringa oleifera* Lam. (Moringaceae) in Nigeria. *J. Ethnopharmacol.* 150, 682–691.
9. Kaneto H, katakami N, kawamori D, Mijatsuka T, Sakamoto K, Mat-Suko TA, (2007). Involvement of Oxidative stress in the pathogenesis of diabetes. *Antioxid Redox signal*, 1991; 9:355- 66.
10. Erhirhie, E.O, Emudainohwo, J.O.T, Edefe, E.U. Effects of *Vernonia amygdalina* and *Ocimum gratissimum* combined leaf extracts on blood glucose and biochemical parameters in alloxan induced Diabetic rats. *Continental J. Pharmacology and Toxicology Research*, 2013; 6 (2); 13 -21.

11. Oluwole Akinola, Micheal Gabriel, Abdul- Azeez Suleiman and Felix Olorunsogbon. Treatment of alloxan induced diabetic Rats with Metformin or Glitazones is associated with Amelioration of hyperglycaemia and Neuroprotection. *The Open Diabetic Journal*, 2012; 5:8 – 12.
12. Dhanesha N, Joharapurkar A, Shah G, Dhote V, Kshirsagar S, Bahekar R, Jain M. Exendin-4 activates glucokinase. *J Diabetes in press*. 2012.
13. Lenzen S, Munday R. Thiol-group reactivity, hydrophilicity and stability of alloxan, its reduction products and its Nmethyl derivatives and a comparison with ninhydrin. Biochem Pharmacol xtract from *Cissus sicyoides*. *BMC Pharmacol* 2008.
14. Ebelt H, Peschke D, Bromme HJ, Morke W, Blume R, Peschke E. Influence of melatonin on free radical-induced changes in rat pancreatic beta-cells in vitro. *J Pineal Res*, 2000; 34: 65-72.
15. Burtis, C.A., Ashwood, E.R., Bruns, D.E. *Tietz fundamentals of clinical chemistry*, 6th Ed. Saunders Publishers, Philadelphia. 2008; Pp 322 –7.
16. Das J, Vasan V, Sil PC. Taurine exerts hypoglycemic effect in alloxan-induced diabetic rats, improves insulin-mediated glucose transport signaling pathway in heart and ameliorates cardiac oxidative stress and apoptosis. *Toxicol Appl Pharmacol*, 2012; 258:296-308.
17. Kakey, Ismial S, Sarmad R, Kareem and Kamal Ahmad. Role of green tea extrac in the improvement of Liver and renal functions in Alloxan induced diabetes mellitus in male albino rats. *International journal of medicine and medical science Research*, 2014; 2(3): 024- 038.
18. Kumar, A.R.; Prabhu, M.; Ponnuswami, V.; Lakshmanan, V.; Nithyadevi, A. (2010). Scientific seed production techniques in moringa. *Agric. Rev.* 2014, 35: 69–73.
19. Babalola O.O, Anetor J.I, Adeniyi F.A. Amelioration of carbon tetrachloride-induced hepatotoxicity from leaves of *Vernonia amygdalina*. *Afri J-med.sci*, 2001; 30:91-3.
20. Atangwho I.J, Ebong P.E, Egbuna G.E, Eteng M.U Effect of *Vernonia amygdalina* on Liver function in alloxan-induced hyperglycaemic rats. *Journal of pharmacy and bio resources*. 4, Retrieved Jan, 2007; 13.110-6.