

Original Research Article

Effect of *Vernonia amygdalina* and *Moringa oleifera* on some liver parameters in alloxan – induced diabetic rats

ABSTRACT

Aim: To assess the effect of *Vernonia amygdalina* and *Moringa oleifera* on some liver function parameters in Alloxan – induced diabetic rats.

Study design: Experimental study

Place and Duration of Study: Departments of Biochemistry and Histology, Imo State University, Owerri, Nigeria, between September 2014 and September 2016.

Methodology: Thirty (30) rats weighing between 180- 200g/kg body weight was divided into five groups of six rats each. Group 1 is the control group, received normal diet. Group 2 is the diabetic group, received Alloxan (150mg/kg body weight) and not treated with plant extract. Group 3 received Alloxan and treated with only one plant extract (VA). Group 4 received Alloxan and treated with only one plant extract (MO). Group 5 received Alloxan and treated with combined plant extracts of (VA and MO). Fasting blood glucose (FBG), Serum ALT, AST, ALP and histology of the liver analyzed after 28 days treatment.

Results: Results showed that there was significant increase in glucose levels of the rats in the group 2 (diabetes induced group). More so, the VA plant extract reduced the levels of glucose, ALT, AST and ALP in group 3. There was also a significant reduction in glucose, levels, ALT, AST and ALP in group 4. The combined therapy of aqueous plant extracts of VA and MO much more reduced the levels of glucose, ALT, AST and ALP in group 5 when compared with the diabetic group. The results were confirmed by histological studies which revealed marked distortions and degenerations of hepatic and renal tissues in the diabetic group and significant reduction and amelioration of the disorders in Alloxan + VA group, Alloxan + MO group, and Alloxan + VA + MO group.

Conclusion: The combined therapy of plant extracts of VA and MO had synergistic effects on hepatic tissues in diabetes and could provide a cheap alternative to treating diabetes associated hepatic disorders.

Keywords: *Vernonia amygdalina* liver, parameters, alloxan – induced diabetic rats

1. INTRODUCTION

Diabetes Mellitus (DM) is a group of metabolic diseases in which there is high blood sugar level over a prolonged period. Diabetes is due to either the pancreas not producing enough or the cells of the body not responding properly to the insulin produced [1]. Symptoms include polyuria, glucosuria, polydipsia, dehydration, and increased hunger [2].

An association exists between diabetes and liver injury and liver pathology among diabetics including fatty liver (steatosis), steatohepatitis, fibrosis, and cirrhosis [3]. Elevated serum activity of the three major liver enzymes aspartate aminotransferase, alanine aminotransferase and Alkaline phosphatase are the most frequently measured indicator of

liver disease and occurs in diabetics more frequently than in the general population [4]. The same spectrum of liver injury and enzyme changes in DM has also been described among overweight individuals without diabetes. Nearly 70 to 80% of the diabetic subjects have been reported to have hepatic fat accumulation [5]. Furthermore, studies showed that activities of liver enzymes such as AST, ALT and ALP have increased in NIDDM patients[6]. Diabetes mellitus is characterized by hyperglycaemia, which has been strongly linked to nephropathy; diabetics are at risk for end-stage renal disease [7].

Vernonia amygdalina is a medicinal plant of Asteraceae family and has a vast importance concentrating majorly on medicinal aspect. However, the plant is also useful in ecology as it helps in the beautification and purification of the environment by releasing oxygen during photosynthesis. *V. amygdalina* can also be used as food supplements when prepared with Melon (egusi soup) a nutritious African food.

An estimated 815 million people in developing countries suffer from malnutrition, and infants and children are the worst hit (FAO, 2004). Unfortunately, efforts at improving food production and accessibility in these regions have been directed lope-sidedly to roots/tubers, cereals, and animal production. The largely ignored dark green leafy vegetables can however augment the nutrients derivable from other sources, thereby reducing malnutrition tremendously.

All plant parts of *Moringa oleifera* are traditionally used for different purposes, but leaves are generally the most used [8]. They are used in human and animal nutrition and in the traditional medicine. Leaves are rich in protein, mineral, beta-carotene, and antioxidant compounds, which are often lacking among the populations of underdeveloped or developing countries. *Moringa* leaves are added to food preparations as integrators of the diet. In traditional medicine, these leaves are used to treat several ailments including malaria, typhoid fever, parasitic diseases, arthritis, swellings, cuts, diseases of the skin, genito-urinary ailments, hypertension, and diabetes. They are also used to elicit lactation and boost the immune system (to treat HIV/AIDS related symptoms) (Sivasankari *et al*, 2014), as well as cardiac stimulants and contraceptive remedy. One can directly consume either raw and dried leaves or the extract of an aqueous infusion.

Studies suggest that the hyperglycemia in NIDDM is in large part a consequence of a deficit in β -cell mass. Although a 25-50% reduction in beta-cell mass is found at the time of diagnosis of NIDDM, the remarkably high level of beta-cell loss could result from either an impaired proliferative capability or an elevated rate of cell. The liver is a central and essential organ and DM related complications of liver includes, abnormal liver enzymes, nonalcoholic fatty liver disease (NAFLD), cirrhosis, hepatocellular carcinoma, and acute liver failure. Patients with DM have a high prevalence of liver disease, and patients with liver disease have a high prevalence of DM. There have been extensive literatures on the medicinal benefits of plant extracts of *Vernonia amygdalina* (VA), and *Moringa oleifera* (MO) individually in different experimental models such as diabetes induced hepatotoxicity and nephrotoxicity. However, no work has been done on the combinatorial effects of *Vernonia amygdalina* and *Moringa oleifera* on diabetes nephrotoxicity, hepatotoxicity, and histological alterations in a diabetic model. The aim of this study was to assess the effect of *Vernonia amygdalina* and *Moringa oleifera* on some livers function parameters in Alloxan – induced diabetic rats.

2. MATERIALS AND METHODS

2.1 Plant Materials

Fresh matured *Vernonia amygdalina* (VA) and *Moringa oleifera* (MO) leaves were harvested from the neighborhood compound in Owerri metropolis. The leaves were rinsed severally with clean tap water to remove dust particles and debris and allowed to air dry completely. The plants were identified by Dr.Mbagwu V. of the department of plant science and biotechnology of Imo state University, Owerri.

2.1.1 Preparation of Plant Extract

The leaves of VA and MO were separately ground to a powdered form. 100grams of each powdered leaf was dissolved in one litre of warm distilled water and left for 48hours in a refrigerator at 4°C to allow for thorough extraction of the plant's active components. These were then filtered with a cheese cloth and later with Whatman no 1 filter paper to obtain a homogenous filtrate. The filtrates were then concentrated, and the concentrates were allowed open in a water bath at 40°C to allow for complete dryness. A greenish brown substance of *Vernonia amygdalina* and *Moringa oleifera* were recovered and preserved separately.

2.2 Experimental Animals

Thirty adult male albino rats weighing between 180 and 200grams obtained from the department of Anatomy Imo State University Owerri, Nigeria were used for this study. The animals were placed in standard cages maintained in 12 light; dark cycle under conditions of temperature and relative humidity.

2.2.1 Experimental Induction of Diabetes

Diabetes was induced in twenty - four overnight fasted rats by a single intraperitoneal injection of Alloxan (Sigma - Aldrich ST. Louis, USA) at a standard dose of 150mg per kilogram body weight, dissolved in 0.85gram per 100ml normal saline solution. The Animals were confirmed diabetic if the glucose level of blood of fasted animals, collected from tail vein after 48hours of injection of Alloxan was above 120mg/dl (7.0mmol/l) as determined with an automated glucose analyzer device (One touch glucometer, Acon Laboratories Inc,USA).

2.3 Experimental Design

Thirty (30) rats were divided into five experimental groups of six rats each:

Group 1:formed the normal control group (NC) and were fed with rat diet and distilled water only.

Group 2:formed the positive control group - diabetic group not treated with plant extracts. They were induced with diabetes using Alloxan and fed with rat diet and water.

Group 3: rats were induced diabetic rats and treated with only *Vernonia amygdalina*(VA) extract at a standard dose of 200mg per kilogram body weight.

Group 4: were induced diabetic rats and treated with *Moringa oleifera* (MO) extract at a standard dose of 200mg /kg body weight.

Group 5: were induced diabetic rats and treated with combined plant extracts of *Vernonia amygdalina* and *Moringa oleifera* at a standard dose of 200mg/kg body weight of the rats.

The two plant extracts, reconstituted in distilled water were administered orally through gastric intubation, at a standard dose of 200mg per kilogram body weight for a single extract

treatment, and 400mg per kilogram body weight for combined extracts treatment, the optimal dose. The duration of treatment was 28 days after induction of diabetes. At the end of the experimental periods, the rats were fasted for 12 hours, then anaesthetized under chloroform vapor and sacrificed. Whole blood was obtained by cardiac puncture into sterile plain tubes and allowed to clot for thereafter centrifuged to remove the cells. Serum removed was used for the biochemical assays. The Liver was also surgically removed for histological studies.

2.4 Laboratory Analysis

All reagents were purchased, and manufacturer's standard operational procedure (SOP) strictly adhered to.

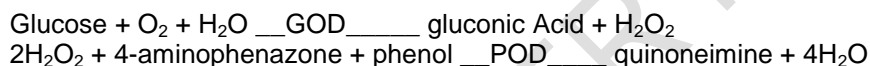
2.4.1 Determination of Glucose (Randox Kit Catlog No__ GL 364)

2.4.1.1 Method

Glucose Oxidase Method

2.4.1.2 Principle

Glucose is determined after enzymatic oxidation in the presence of glucose oxidase. The hydrogen peroxide formed, reacts under catalysis of peroxidase, with phenol and 4-aminophenazone to form a red violet quinoneimine dye as indicator.



2.4.2 Determination of ALT (Randox Kit Catlog No --- Al 100)

2.4.2.1 Method

Spectrophotometric method

2.4.2.2 Principle.

ALT is measured by monitoring the concentration of pyruvate hydrazone formed with 2,4 – dinitrophenylhydrazine. α - oxoglutarate + L – Alanine GPT L – glutamate + pyruvate
Method

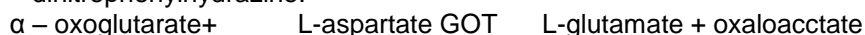2.4.3 Determination of AST (Randox Kit Catlog No---AS101)

2.4.3.1 Method

Spectrophotometric method

2.4.3.2 Principle

AST is measured by monitoring the concentration of oxaloacetate hydrazone formed with 2,4 – dinitrophenylhydrazine.



(Normal values 0 -12 μ /L)

2.4.4 Determination ALP (Randox Kit Catlog NO –AP 542)

2.4.4.1 Method

Spectrophotometric method

2.4.4.2 Principle

The substrate, para-nitrophenyl phosphate (PNPP) is hydrolysed by ALP to para-nitrophenol and phosphoric Acid. The intensity of the yellow colour formed in alkaline medium measured at 405nm is directly proportional to the alkaline phosphate activity.



2.5 Tissue Preparation for Histological Study.

Dissected Liver tissues were immediately fixed in 10% formal saline and kept at 4°C. After fixing for 48 hours, a transverse section was made at the middle part of each Liver and kept immersed in the fixative for the completion of tissue fixation. The formal saline samples were then embedded in paraffin and sectioned into slices 6- 7 µm thick. The tissue slices were mounted onto Albumin-precoated glass slides, de-paraffined with xylene and stained with Hematoxylin and Eosin (H&E). The stained sections were studied under a light Microscope.

2.6 Statistical Analysis

Results were analyzed using SPSS 16. All data were reported as mean ± SD and test of significance was done using one-way ANOVA with 95% confidence limit.

3. RESULTS AND DISCUSSION

Table 1: Comparisons of glucose values for all groups

Parameter/Group	Glucose Urea (mmol/l)
Group 1 (N=6)	4.217 ± 0.584 ²
Group 2 (N=6)	16.22 ± 0.679 ^{3,4,5}
Group 3 (N=6)	9.867 ± 0.697 ^{4,5}
Group 4 (N=6)	8.283 ± 0.679
Group 5 (N=6)	5.300 ± 0.374
F-value	355.5
P-value	<0.0001
Remark	S

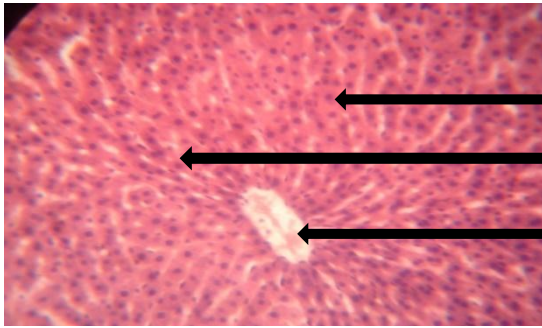
Key: S – significant (ANOVA), 2,3,4,5 significant compared to the number of group

Table 2: Comparisons of Liver enzymes levels for all groups

Parameter/Group	ALT (U/L)	AST (U/L)	ALP (U/L)
Group 1 (N=6)	7.017 ± 1.021 ²	6.200 ± 0.989 ²	8.067 ± 0.725 ²
Group 2 (N=6)	30.98 ± 2.368 ^{3,4,5}	27.17 ± 1.176 ^{3,4,5}	40.43 ± 1.391 ^{3,4,5}
Group 3 (N=6)	17.28 ± 2.724 ⁴	13.45 ± 0.717 ⁵	19.33 ± 0.983
Group 4 (N=6)	19.83 ± 1.209	13.13 ± 0.535	19.37 ± 1.143
Group 5 (N=6)	8.550 ± 0.671 ^{3,4}	8.217 ± 0.545 ⁴	20.32 ± 1.813
F-value	175.7	580.7	513.9
P-value	<0.0001	<0.0001	<0.0001
Remark	S	S	S

Key: S – significant (ANOVA), 2,3,4,5 significant compared to the number of group

Histological reports of the Liver and Kidney of control and treated rats

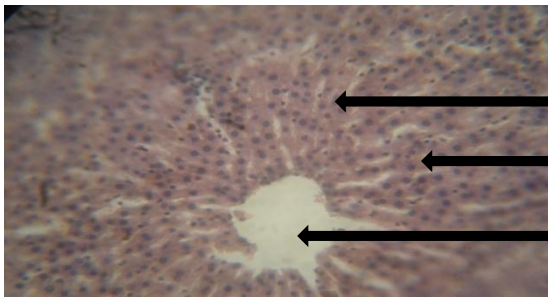


Normal polyhedral shaped hepatocytes

Normal acidophilic cytoplasm

Central vein

Plate 1: Photomicrograph of the section of the Liver of the normal control group. The section shows a hepatic lobule with the central vessel. The endothelium of the vessel is intact. The sinusoids radiate in its normal pattern. The hepatocytes appear in cords and lodged multi nuclei. Connective tissues are intact.

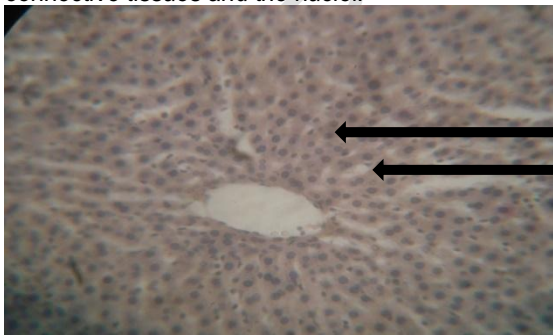


Distorted connective tissues

Deranged cytoplasm

Constricted central vessel

Plate 2: Photomicrograph of the hepatic lobule of rats not treated with plant extract after diabetes induction. The section shows a Liver lobule with a constricted central vessel, from which the sinusoids radiate out. The hepatocytes appear in cords with multi nuclei. There is marked degeneration of the connective tissues and the nuclei.



Normal polyhedral shaped hepatocytes

Plate 3: Photomicrograph of the section of the liver of diabetic rats treated with only Vernonia amygdalina (VA) plant extract. The section shows a hepatic lobule with slight distortion of the central vessels. The sinusoids are constricted by the dilated hepatocytes, though in hexagonal pattern. There are slight degenerations of the connective tissues.

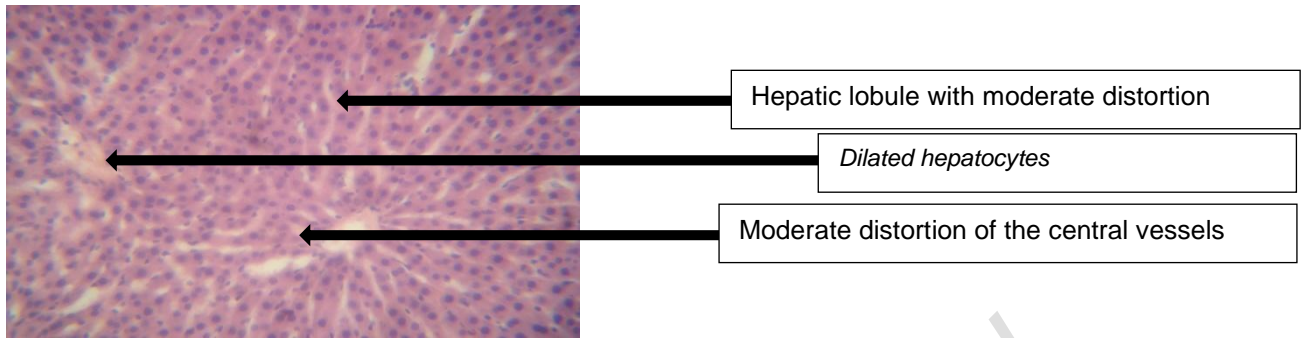


Plate 4: Photomicrograph of the section of the liver of diabetic rats treated with only *Moringa oleifera* (MO) plant extract. The section shows a hepatic lobule with moderate distortion of the central vessels. There is also moderate degeneration of the connective tissues. The sinusoids are constricted by the dilated hepatocytes.

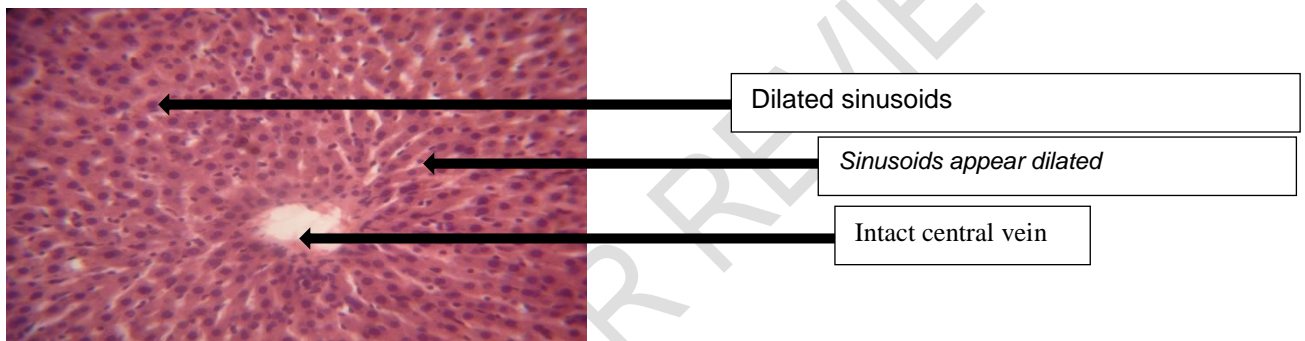


Plate 5: Photomicrograph of the section of the Liver of diabetic rats treated with combined *Vernonia amygdalina* and *Moringa oleifera* plant extracts. The section shows a hepatic lobule with its central vessel whose endothelium appeared intact. The sinusoids appear dilated and radiate in its normal pattern. There were hypertrophy of the hepatocytes and their multi nuclei. The connective tissues are intact.

In this study, the mean \pm SD values for rats in the normal control group that received rat diet and water were ALT (7.0 ± 1.02 U/L), AST (6.2 ± 1.03 U/L), ALP (8.1 ± 0.74 U/L) and glucose (4.3 ± 0.49 mmol/l). The mean \pm SD of values of glucose (13.7 ± 0.88 mmol/l) of rats not treated with plant extract after diabetes induction by Alloxan were significantly increased ($p < 0.05$) when compared with the normal control group (4.3 ± 0.49 mmol/l). This is probably due to the devastating effect of alloxan on the pancreatic islet cells, by destroying the insulin-secreting cells of the Islet of Langerhans. This report agrees with Kaneto *et al.* [9], who, in his report attributed such pathological changes to glucotoxicity, which arises from excessive up take of glucose by islet beta cells in diabetes. The excess sugar drives glycation reactions and the mitochondrial electron chain, producing macromolecular damaging reactive oxygen species (ROS), at levels beyond the antioxidant capacities of the cells. The ensuing oxidative stress impairs insulin synthesis and secretion and initiates a cascade of cellular events that lead to beta cell cytotoxicity and death. Similar findings were observed and reported by Erhirhie *et al.*, [10] and Oluwole *et al.* [11] who reported in several experimental diabetic literatures that the standard dose of 150 mg/kg body weight of Alloxan was adequate for induction of diabetes in rats through intraperitoneal route. According to their findings, this dose treatment of Alloxan induces a more rapid loss of insulin secretion and a more rapid onset of diabetes compared with low dose treatment. According to Dhanesha *et al.* [12] findings on the mechanism of Alloxan action, reported that the toxic action of Alloxan on pancreatic beta cells involves, oxidation of essential sulfhydryl (-SH) groups, inhibition of

glucokinase enzyme, generation of free radicals and disturbances in intra- cellular calcium homeostasis. Lenzen,[13] reported in his study that the underlying mechanism involves the selective up take of the compound due to its structural similarity to glucose as well as highly efficient up take mechanism of the pancreatic beta cells. Another mechanism reported by Ebel et al. [14] is the effect of reactive oxygen species (ROS) on the DNA of pancreatic islets. The fragmentation of DNA takes place on the beta cells exposed to Alloxan that causes DNA damage, which stimulates poly- ADP- ribosylation, a process participating in DNA repair.

In the present study, the mean \pm SD values of ALT(30.5 ± 2.77 U/L), AST(27.8 ± 1.73 U/L), and ALP(40.8 ± 1.16 U/L) of rats not treated with plant extract after diabetes induction by Alloxan were significantly increased when compared with the normal control group, ALT(7.0 ± 1.02 U/L), AST(6.2 ± 1.03 U/L) and ALP(8.1 ± 0.74 U/L). The increased activities of these enzymes in the diabetic group were probably because of increased concentration of these enzymes (ALT, AST and ALP) in the serum of diabetic rats, which could be attributed to reactive oxygen species (ROS) mediated lipid peroxidation that distorts the Liver cell architecture, thus releasing the Liver cell content into circulation. These findings agree with Burtis et al [15] who reported elevated levels of liver enzymes such as ALT, AST and ALP in acute hepatitis, viral hepatitis, and hepatocellular damage. In the present study, the mean \pm SD values of ALT(17.0 ± 3.03 U/L), AST(13.8 ± 1.08 U/L), ALP(19.6 ± 1.07 U/L) and glucose (8.9 ± 1.39 mmol/l) of rats treated with only one plant extract (VA) after diabetes induction by Alloxan were reasonably reduced when compared with the diabetic group. This could be attributed to the ameliorative effect of *Vernonia amygdalina* on the liver and glucose levels of the rats. These teams reported on the ameliorative and protective effects of VA which they discovered that oral administration of plant extract from VA could accelerate the reversion of liver damage through reduction of liver marker enzymes such as ALT, AST and ALP. In this study, the mean \pm SD values of ALT(19.4 ± 1.68 U/L), AST(13.1 ± 0.54 U/L), ALP(19.3 ± 1.08 U/L) and glucose (9.6 ± 0.87 mmol/l) of rats treated with only one plant extract (MO) after diabetes induction by Alloxan were moderately reduced when compared with the diabetic group. This could be attributed to the ameliorative effect of *Moringa oleifera* on the diabetic rats. These findings were confirmed by histological examinations which revealed an amelioration of the hepatic induced by drugs in animals treated with *Moringa oleifera* plant extract. Das et al. [16] observed a reduction of ALT, AST and ALP and a lower Liver damage in rats fed with high fat diet and co – treated with *Moringa oleifera* plant extract, suggesting a potential role of MO in the prevention of non- alcoholic fatty Liver disease (NAFLD). In the present study, the mean \pm SD values of ALT(8.5 ± 0.75 U/L), AST(8.0 ± 0.66 U/L), ALP(20.1 ± 1.41 U/L), Urea(6.4 ± 1.14 U/L), Creatinine(74.6 ± 7.23 U/L) and glucose(7.9 ± 0.78 U/L) of rats treated with combined plant extracts of *Vernonia amygdalina* and *Moringa oleifera* (VA +MO) after diabetes induction by Alloxan were much more reduced when compared with the diabetic group. This could be attributed to the synergistic potential of the combined plant extracts of VA and MO on the Liver and glucose levels of Alloxan induced diabetic rats.

In the present study, the photomicrograph of the section of the liver of the normal control group showed intact and normal endothelium and connective tissues (Plate 1). In the diabetic group (Plate 2), the histological reports showed marked distortions and degenerations of liver tissues. These could be attributed to diabetic disorders and complications. In the Alloxan and VA group (Plate 3), the section of the liver showed a hepatic lobule with reduced distortion of the central vessels. This could be attributed to the ameliorative effect of VA plant extract on liver tissues. Also, in the Alloxan and MO group (Plate 4), the section of the liver showed a hepatic lobule with reduced distortions of the central vessels. There were decreased degeneration of the connective tissues. This could also be attributed to the ameliorative and protective effects of MO on the Liver tissues. This

was also in agreement with Kakey *et al.* [17] Pari and Kumari [18] Ouedraogo *et al.* [19] who reported on the ameliorative properties of MO plant extract.

In the Alloxan, VA and MO group ((Plate 5), the photomicrograph of the section of the liver showed a hepatic lobule with an intact central vessels, endothelium, and connective tissues. This could be attributed to the synergy provided by the combined therapy of the two plant extracts (VA + MO) in ameliorating and protecting Liver tissues. These findings agreed with Kakey *et al.* [17], Babalola *et al.* [19] and Atangwho *et al.* [20].

4. CONCLUSION

VA and MO extracts significantly reduced high levels of AST, ALT and ALP caused by alloxan induced diabetes in rats. The combined therapy of plant extracts of VA and MO had synergistic effects on hepatic tissues in diabetes and provided a cheap alternative to treating diabetes associated hepatic disorders.

ETHICAL APPROVAL

All authors hereby declare that Principles of laboratory animal care (NIH publication No. 85-23, revised 1985) were followed, as well as specific national laws where applicable. All experiments have been examined and approved by the appropriate ethics committee.

REFERENCES

1. Shoback, edited by David G. Gardner, Dolores "Chapter 17". Greenspan's basic & clinical endocrinology (9th ed.). New York: McGraw-Hill Medical. ISBN 0-07-162243-8. 2011.
2. Malik VS, Popkin BM, Bray GA, Després JP, Hu FB. "Sugar Sweetened Beverages, Obesity, Type 2 Diabetes and Cardiovascular Disease risk". *Circulation*, 2010; 121 (11):1356–64.
3. Erbey JR, Silberman C, Lydick E. Prevalence of abnormal serum alanine aminotransferase levels in Obese patients and patients with type 2 diabetes: *Am J. med*, 2002; 109:588-90.
4. Everhart J.E. Diabetes in America 2nd ed. National Institute of health. National Institute of diabetes and digestive and kidney diseases. Washington, DC: DPO; 457-83. 1995.
5. Gupte P, Amarapurkar D, Agal S, Kulshrestha P, Pramanik S. Non-alcoholic steatohepatitis in type 2 diabetes mellitus. *J. Gastroenterol, Hepatol*, 2004; 19:854 – 8.
6. Wannamethee Sg, Shaper AG, Lennon L, Whincup PH. Hepatic enzymes, the metabolic syndrome, the risk of type 2 diabetes in older men. *Diabetes, 2005; Care*, 28:2913-18.
7. Held PJ, Port FK, Webb RL, Garcia JR, Blagg CR, Agodoa Ly. The United States Renal data systems 1991 annual data report: an introduction. *AM. J Kidney Disr*, 18, 1-16.
8. Popoola, J.O.; Obembe, O.O. Local knowledge, use pattern and geographical distribution of *Moringa oleifera* Lam. (Moringaceae) in Nigeria. *J. Ethnopharmacol.* 150, 682–691.
9. Kaneto H, Katakami N, Kawamori D, Mijatsuka T, Sakamoto K, Mat-Suko TA, (2007). Involvement of Oxidative stress in the pathogenesis of diabetes. *Antioxid Redox signal*, 1991; 9:355- 66.
10. Erhirhie, E.O, Emudainohwo, J.O.T, Edefe, E.U. Effects of *Vernonia amygdalina* and *Ocimum gratissimum* combined leaf extracts on blood glucose and biochemical parameters in alloxan induced Diabetic rats. *Continental J. Pharmacology and Toxicology Research*, 2013;6 (2); 13 -21.

11. Oluwole Akinola, Micheal Gabriel, Abdul- Azeez Suleiman and Felix Olorunsogbon. Treatment of alloxan induced diabetic Rats with Metformin or Glitazones is associated with Amelioration of hyperglycaemia and Neuroprotection. *The Open Diabetic Journal*, 2012;5:8 – 12.
12. Dhanesha N, Joharapurkar A, Shah G, Dhote V, Kshirsagar S, Bahekar R, Jain M. Exendin-4 activates glucokinase. *J Diabetes in press*. 2012.
13. Lenzen S, Munday R. Thiol-group reactivity, hydrophilicity and stability of alloxan, its reduction products and its Nmethyl derivatives and a comparison with ninhydrin. *BiochemPharmacol* extract from *Cissus sicyoides*. *BMC Pharmacol* 2008.
14. Ebelt H, Peschke D, Bromme HJ, Morke W, Blume R, Peschke E. Influence of melatonin on free radical-induced changes in rat pancreatic beta-cells in vitro. *J Pineal Res*, 2000; 34: 65-72.
15. Burtis, C.A., Ashwood, E.R., Bruns, D.E. *Tietz fundamentals of clinical chemistry*, 6th Ed. Saunders Publishers, Philadelphia. 2008; Pp 322 –7.
16. Das J, Vasan V, Sil PC. Taurine exerts hypoglycemic effect in alloxan-induced diabetic rats, improves insulin-mediated glucose transport signaling pathway in heart and ameliorates cardiac oxidative stress and apoptosis. *Toxicol Appl Pharmacol*, 2012; 258:296-308.
17. Kakey, Ismial S, Sarmad R, Kareem and Kamal Ahmad. Role of green tea extract in the improvement of Liver and renal functions in Alloxan induced diabetes mellitus in male albino rats. *International journal of medicine and medical science Research*, 2014; 2(3): 024- 038.
18. Kumar, A.R.; Prabhu, M.; Ponnuswami, V.; Lakshmanan, V.; Nithyadevi, A. (2010). Scientific seed production techniques in moringa. *Agric. Rev.*2014, 35: 69–73.
19. Babalola O.O, Anetor J.I, Adeniyi F.A. Amelioration of carbon tetrachloride-induced hepatotoxicity from leaves of *Vernonia amygdalina*. *Afri J-med.sci*, 2001; 30:91-3.
20. Atangwho I.J, Ebong P.E, Egbuna G.E, Eteng M.U Effect of *Vernonia amygdalina* on Liver function in alloxan-induced hyperglycaemic rats. *Journal of pharmacy and bio resources*. 4, Retrieved Jan, 2007; 13.110-6.