

1
2
3
4
5
6
7

Abdominal cocoon : a forgotten diagnosis

8 **ABSTRACT**

9 **Aims:** Sclerosing Encapsulating Peritonitis (SEP), also known as cocoon syndrome, is a rare pathological condition characterized by the complete or partial encapsulation of the small bowel by a fibro-collagenous membrane.

Study design: Case report

Presentation of Case: We present a case of a 38-year-old woman with subacute intestinal obstruction, ultimately diagnosed with SEP. The patient exhibited chronic abdominal pain, bloating, nausea, vomiting, and an 8 kg weight loss. Clinical examination revealed ascites, gross abdominal distension, and mildly elevated C-reactive protein. Imaging studies demonstrated massive ascites, omental cake appearance, and a right latero-uterine mass. Laparoscopy initially revealed clear ascites, but subsequent laparotomy unveiled a dense membrane encapsulating the small intestine and parts of the colon. Adhesiolysis and partial membrane excision were performed, leading to a successful outcome with the patient discharged on the seventh postoperative day.*

Discussion:SEP, a rare condition, can be primary (abdominal cocoon syndrome) or secondary, associated with factors like peritoneal dialysis or abdominal surgeries. Diagnosis, challenging and often intraoperative, relies on CT imaging showcasing peritoneal changes. Conservative treatment, emphasizing bowel rest and nutrition, is recommended for minor symptoms. Severe cases may require surgical intervention, including adhesiolysis and membrane excision. SEP carries mortality rates of 26 to 58 percent, with malnutrition and sepsis as common causes of death.

Conclusion:SEP poses diagnostic challenges, often requiring surgical exploration. Preoperative diagnosis through a combination of imaging guides appropriate management, avoiding unnecessary surgeries and optimizing patient outcomes.

- 10
11 1. *Keywords: [Sclerosing Encapsulating Peritonitis ; Abdominal Cocoon Syndrome ,Diagnosis ,CT Imaging*
12 *,Conservative Treatment ,Surgical Intervention, ,Preoperative Diagnosis}*

13
14 **1. INTRODUCTION**

15
16 Sclerosing encapsulating peritonitis (SEP) is a rare clinical entity and is often encountered unexpectedly in patients
17 admitted with other different diagnosis .called also cocoon syndrome because of the existence of an abnormal membrane
18 that contains part or the entire small intestine.The diagnosis is difficult and made generally during the surgical procedure ,
19 so a high index of clinical suspicion in susceptible patients is necessary to achieve a preoperative diagnosis.

20 We report a case of a 38-year old woman who presented with features of subacute intestinal obstruction due to an
21 abdominal cocoon who was treated successfully by surgery.

2. PRESENTATION OF CASE

A 38-year-old woman was referred to our hospital for chronic intermittent abdominal pain, bloating, with recurrent episodes of nausea, vomiting and weight loss of 8 kg.

The patient had no history of tuberculosis or any positive contacts. and had no symptom of fever, chronic cough or night sweats

On physical examination, the woman was extremely thin with a BMI of 14.58. Vital signs were normal, and abdominal examination revealed gross abdominal distension, ascites without tenderness, the per rectal examination was not significant except serum C-reactive protein (CRP) which was mildly elevated (15 mg/l, normal range < 5mg/l). The other laboratory blood analysis including others serum tumor markers (Carcinoembryonic Antigen Test, CA19-9, CA-125), liver functions test, renal functions test, were all within normal limits.

Ascitic fluid obtained by paracentesis were exudates in nature and negative for bacteria culture.

Contrast-enhanced computed tomogram of the abdomen revealed massive ascites in perihepatic space, perisplenic space and between the loops associated with an infiltration of the greater omentum realizing the aspect of <omental cake>, with right latero-uterine mass, measuring 32 x 28mm. (FIGURE 1)

For a better study, we have completed by a pelvic Magnetic resonance imaging (FIGURE 2) which highlights: right ovary measuring 25 mm with physiological follicles, uterus and left ovary were without abnormality, presence of abundant ascites with diffuse peritoneal enhancement

Unfortunately, we did not evoke the diagnosis at the time of the analysis of the imaging, because we were focused looking for a cancer, and during the review of the CT and MRI in postoperative period the abnormalities were evident with peritoneal thickening and marked in addition to small bowel abnormalities such as the wall thickening and the encapsulation,

Due to the absence of orientation in front of this exudative ascites and by fear of not knowing a tumoral origin, we decided to practice an exploratory laparoscopy

A diagnostic laparoscopy using 10 mm supraumbilical port, showed in addition to clear ascites that the entire small bowel was all plastered and encapsulated in a membrane, then laparoscopic approach became unsafe and dangerous. Hence, a decision was made for midline laparotomy, in which a dense membrane was found encapsulating the small intestine and part of the ascending and descending colon, the appendix and ovaries were free. (FIGURE 3)

We retain the final diagnosis of encapsulating peritonitis.

Adhesiolysis was done and the membrane was partially excised, releasing the small bowel loops. The entire small intestine was viable, without serosal tears.

Postoperatively she remained well and was discharged on the seventh postoperative.

Histopathological examination revealed nonspecific features in the fibrous membrane, including fibro-connective tissue growth, dilated lymphatics, and inflammatory infiltrates. No presence of giant cells, foreign body granulomas, or birefringent material was observed

3. DISCUSSION

Sclerosing encapsulating peritonitis (SEP) is an uncommon illness in which the small bowel is completely or partially encapsulated either by fibro-collagenous membrane with either a local inflammatory infiltration, causing acute or chronic intestinal blockage. [7]

Initially called Peritonitis chronica fibrosa incapsulata and was described first time by Owtschinnikow in 1907..[9]

EPS occurs in 0.5 percent to 7.3 percent of people worldwide, but it can reach 17.2 percent in patients who have had peritoneal dialysis for fifteen years or over.[6]

The etiology and pathological features of the trapping membrane determine whether SEP is primary or secondary..

Primary SEP, also known as the abdominal cocoon syndrome, is categorized depending on the level of membrane encasement in three types

The first and the second involves the partial or the complete encasement of the intestine, respectively. In the third one, in addition to the small intestine, adjacent organs such as ovaries, caecum, the appendix, colon, stomach, and liver are also encased. [8]

Primary SEP is idiopathic, meaning it has no clear etiology. [8]

Secondary SEP is much more frequent because it is linked to a variety of factors. Peritoneal dialysis is the most common cause of secondary SEP.

Other factors that may lead to secondary SEP involve:

83 autoimmune disease, intestinal tuberculosis , recurrent peritonitis , beta-blocker treatment or chemotherapy or ,
84 peritoneal shunts,abdominal surgery ,and fibrogenic foreign material [8]. Secondary SEP can also be associated with
85 conditions such as primary sclerosing cholangitis (PSC), which is characterized by cholestasis due to multifocal bile duct
86 strictures. PSC can lead to liver fibrosis, cholangiocarcinoma, and end-stage liver disease. SEP may also be a
87 complication of PSC [11]

88 The differentiation between primary and secondary SEP can be made based on the underlying etiology and associated
89 conditions [12] .

90
91 SEP symptoms include intense abdominal pain, gastrointestinal obstruction, nausea,or vomiting that are irregular and
92 persistent .

93 In addition to losing weight and, in certain cases, the requirement for parenteral feeding that result from an inability to
94 maintain a sufficient diet. [6]

95
96 There are two crucial clinical signs to look for in order to diagnose this condition.

97 "Fixed, asymmetrical distension of the abdomen and difference in the consistency of the abdominal wall to palpation."

98 The flat area is hard due to the tight fibrous capsule, whereas the distended part is soft because to the thin-walled swollen
99 small intestine without a fibrous layer covering it. [3]

100
101 **Computed tomography** (CT) scanning is an effective way to diagnose SEP ,and a high index of suspicion in
102 susceptible patients is necessary to achieve a preoperative diagnosis.

103
104 Recognition of characteristic CT findings helps in accurate diagnosis preoperatively and can help in appropriate clinical
105 management.

106 ,The principal CT findings of EPS can be categorized into four categories.:

107 "(1) peritoneal findings (peritoneal thickening, calcification, and marked enhancement);

108 (2) small bowel abnormalities (wall thickening, encapsulation, and dilation, leading to obstructive ileus with or without
109 systemic inflammation);

110 (3) fluid collection (loculated fluid collection and recurrent hemorrhagic ascites);

111 (4) calcification (liver and splenic capsule calcification, bowel calcification, and posterior peritoneal wall calcification)" [1]

112
113 Although magnetic resonance imaging is less commonly utilized for diagnosis, it is likely to produce similar results that
114 CT , in addition Ionizing radiation is avoided, and the intestinal encasement and peritoneal thickness are better delineated
115 [10]

116
117 Histopathological examination is no longer necessary because the appearance of SEP on CT imaging, combined with
118 clinical characteristics, allows for a clear diagnosis.[9]

119 The histologic features in SEP are non-specific, and they may mimic those seen in infectious peritonitis or simple
120 peritoneal sclerosis [10] It displays fibro-connective tissue growth, dilated lymphatics and inflammatory infiltrates
121 ,however no giant cells ,foreign body granulomas, or birefringent material. [9]

122
123
124
125 Regretfully, no guidelines or therapies for SEP exist. There is a lack of solid scientific evidence, and evaluating the various
126 SEP therapies is difficult and relies solely on observational data. [6]

128 **conservative treatment**

129
130 The literature suggests that individuals with minor abdominal symptoms should be treated conservatively, with bowel rest,
131 nasogastric decompression, and then enteral or parenteral nutritional supplementation [8]

132 Nutritional disorders affect the majority of patients , thus addressing them is an important part of treatment. optimizing
133 the patients' nutritional status is critical because it can help them respond better to conservative treatment and prevent
134 surgical complications like infection or fistulas.[8]

135
136 People who do not respond to conservative treatment could be placed on drugs in order to inhibit fibroblastic production
137 by inhibiting collagen syntheses ,such as steroids tamoxifen, azathioprine,colchicine, or mycophenolic acid ,However,
138 their effectiveness requires further investigation [4]

140 **surgical interventions**

141 Patients with significant complaints of intestinal obstruction, those who have virgin abdomens, and those who do not
142 respond to conservative treatment may be surgical candidates. .[8]

143

144 Surgical options include adhesiolysis in addition to membrane excision , for patients with a gut injury, and resection
145 plus anastomosis with or without a protective enterostomy in case of gut injury .
146 Technical difficulties may arise from fibrotic membrane sacs that wrap and encapsulate the intestinal loops such as thick
147 plastic bags. Many transverse and longitudinal incisions may be required to separate these sacs from the underlying
148 intestinal loops;[8]

149
150 This could make the membrane easier to remove, allowing the underlying intestines to resume their usual function and
151 length.[8]

152 Gut perforation can occur if these membranes are not peeled off or excised, or if the removal process is hard..[8]

153 In most situations, an enterotomy is the primary repair, although intestinal resection is only used in cases of severe
154 injuries and suspected or proven loss of gut vascular integrity..

155 Resection, especially when not clearly needed, may raise mortality rates in these patients. [8]

156
157 The outcomes of SEP vary, with some cases recovering well after surgery and being clinically unremarkable for years,
158 while others may show unsatisfactory improvement [13] .Early detection of SEP is essential for better outcomes .

159 Patients with SEP have a significant death rate, ranging from 26 to 58 percent, which rises with peritoneal dialysis
160 vintage.

161 Malnutrition with sepsis are the most common causes of death in people with SEP [6]

162 .

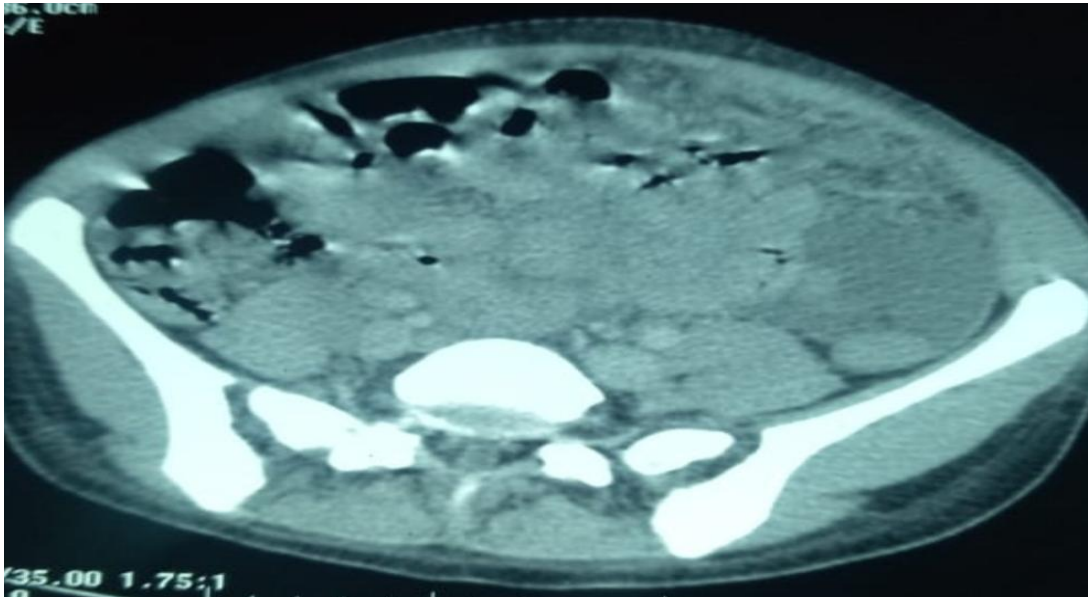
163 .

164 .

165 .

166 .

167 .



168 **Figure 1 : axial CT of the abdomen showing ascite and latero-uterine mass**

168

169

170

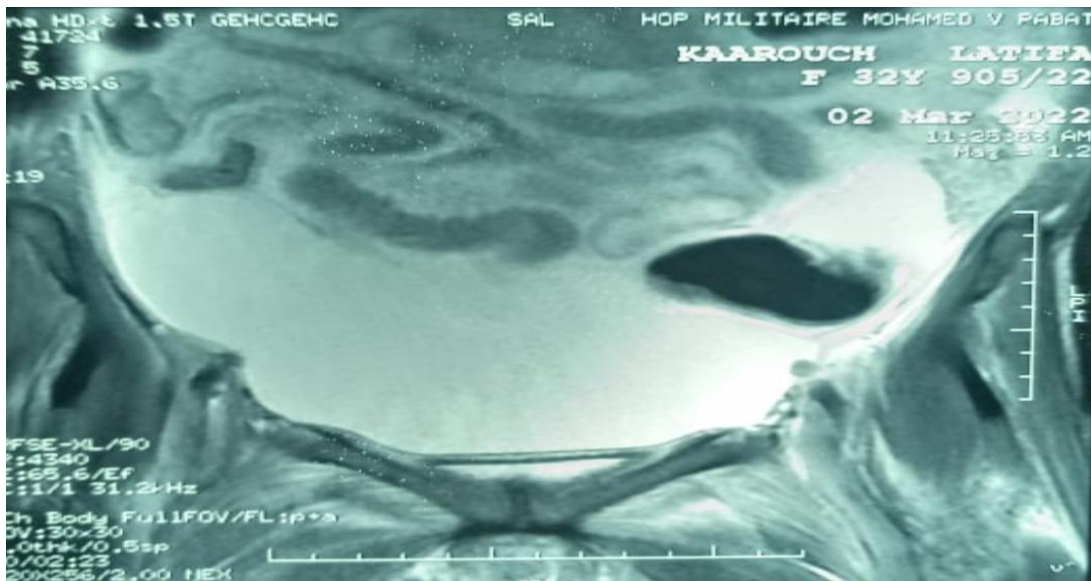


Figure 2 : coronal MRI of the abdomen showing ascite and diffuse peritoneal enhancement

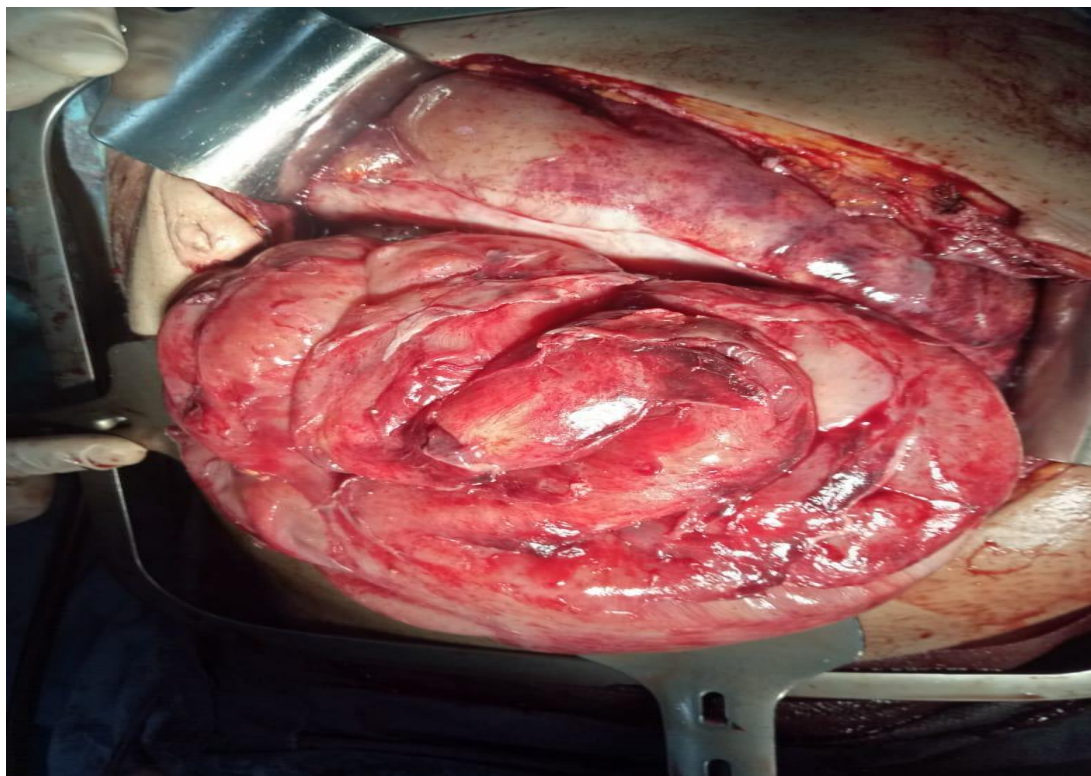


Figure 3 : operative view of the cocoon abdomen

4. CONCLUSION

the diagnosis of abdominal cocoon is difficult to make before surgery, however it should be considered whenever a patient complains of abdominal pain, nausea, or vomiting that's also accompanied by weight loss.

Preoperative diagnosis of this entity using a combination of diagnostic modalities such as sonography and Computed tomography scan can avoid unnecessary surgery and enable conservative management which is the ideal approach for patients who present with mild symptoms .

188
189
190 **COMPETING INTERESTS**

191 : "Authors have declared that no competing interests exist."
192

193 **AUTHORS' CONTRIBUTIONS**

194
195 : All the authors contributed to the care of the patient and also to the drafting of the manuscript
196 All authors read and approved the final manuscript."
197

198 **CONSENT**

199
200 All authors declare that 'written informed consent was obtained from the patient (or other approved parties) for publication
201 of this case report and accompanying images. A copy of the written consent is available for review by the Editorial
202 office/Chief Editor/Editorial Board members of this journal.
203

204
205
206
207
208 **REFERENCES**
209
210

211 [1] : Basara Akin I, Altay C, Celik A, Secil M. Computed Tomography Features of Encapsulating Peritoneal Sclerosis. *Can*
212 *Assoc Radiol J.* 2019 Aug;70(3):233-238. doi: 10.1016/j.carj.2018.11.005. Epub 2019 Mar 25. PMID: 30922787.

213
214 [2] Asghar H, Raza R, Niazi IK, Siddiqui K. Encapsulated peritoneal sclerosis. *J Pak Med Assoc.* 2022 Jan;72(1):192-
215 193. doi: 10.47391/JPMA.22-007. PMID: 35099469.

216 [3] Sureka B, Mittal MK, Sinha M, Mittal A, Thukral BB. Abdominal cocoon. *Avicenna J Med.* 2013 Oct;3(4):103-5. doi:
217 10.4103/2231-0770.120502. PMID: 24327969; PMCID: PMC3841479.

218
219 [4] Sghair A, Debaibi M, Kchaou M, Talbi S, Sridi A, Chouchen A. Idiopathic sclerosing encapsulating peritonitis: An
220 uncommon cause of intestinal obstruction in a virgin abdomen. *Clin Case Rep.* 2022 Mar 15;10(3):e05603. doi:
221 10.1002/ccr3.5603. PMID: 35317068; PMCID: PMC8922953.
222

223 [5] Aziz W, Malik Y, Haseeb S, Mirza RT, Aamer S. Abdominal Cocoon Syndrome: A Laparoscopic Approach. *Cureus.*
224 2021 Jul 31;13(7):e16787. doi: 10.7759/cureus.16787. PMID: 34513394; PMCID: PMC8405409
225

226 [6] Jagirdar RM, Bozikas A, Zarogiannis SG, Bartosova M, Schmitt CP, Liakopoulos V. Encapsulating Peritoneal
227 Sclerosis: Pathophysiology and Current Treatment Options. *Int J Mol Sci.* 2019 Nov 16;20(22):5765. doi:
228 10.3390/ijms20225765. PMID: 31744097; PMCID: PMC6887950.
229

230 [7] Sharma D, Nair RP, Dani T, Shetty P. Abdominal cocoon-A rare cause of intestinal obstruction. *Int J Surg Case Rep.*
231 2013;4(11):955-7. doi: 10.1016/j.ijscr.2013.08.004. Epub 2013 Aug 20. PMID: 24055916; PMCID: PMC3825929.
232

233 [8] Machado NO. Sclerosing Encapsulating Peritonitis: Review. *Sultan Qaboos Univ Med J.* 2016 May;16(2):e142-51. doi:
234 10.18295/squmj.2016.16.02.003. Epub 2016 May 15. PMID: 27226904; PMCID: PMC4868512.

235 [9] Tannoury JN, Abboud BN. Idiopathic sclerosing encapsulating peritonitis: abdominal cocoon. *World J Gastroenterol.*
236 2012 May 7;18(17):1999-2004. doi: 10.3748/wjg.v18.i17.1999. PMID: 22563185; PMCID: PMC3342596.
237

238 [10] Danford CJ, Lin SC, Smith MP, Wolf JL. Encapsulating peritoneal sclerosis. *World J Gastroenterol.* 2018 Jul
239 28;24(28):3101-3111. doi: 10.3748/wjg.v24.i28.3101. PMID: 30065556; PMCID: PMC6064970.
240

241 [11].Mishra, S., Chaudhary, K., Tyagi, S., Mishra, P., & Misra, V. (2023). Primary sclerosing encapsulating peritonitis.
242

243 [12] Wetherell, J., Woolley, K., Chadha, R., Kostka, J., Adilovic, E., & Nepal, P. (2021). Idiopathic sclerosing
244 encapsulating peritonitis in a patient with atypical symptoms and imaging findings. *Case Reports in Gastrointestinal*
245 *Medicine*, 2021.

246 [13] Fujiwara, S., Akaishi, R., & Yokosawa, T. (2023). Sclerosing Encapsulating Peritonitis: Abdominal
247 *Cocoon. Cureus*, 15(1).