

Case study

Abdominal cocoon : a forgotten diagnosis

ABSTRACT

Aims: Sclerosing Encapsulating Peritonitis (SEP), also known as cocoon syndrome, is a rare pathological condition characterized by the complete or partial encapsulation of the small bowel by a fibro-collagenous membrane.

Study design: Case report

Presentation of Case: We present a case of a 38-year-old woman with subacute intestinal obstruction, ultimately diagnosed with SEP. The patient exhibited chronic abdominal pain, bloating, nausea, vomiting, and an 8 kg weight loss. Clinical examination revealed ascites, gross abdominal distension, and mildly elevated C-reactive protein. Imaging studies demonstrated massive ascites, omental cake appearance, and a right latero-uterine mass. Laparoscopy initially revealed clear ascites, but subsequent laparotomy unveiled a dense membrane encapsulating the small intestine and parts of the colon. Adhesiolysis and partial membrane excision were performed, leading to a successful outcome with the patient discharged on the seventh postoperative day.*

Discussion: SEP, a rare condition, can be primary (abdominal cocoon syndrome) or secondary, associated with factors like peritoneal dialysis or abdominal surgeries. Diagnosis, challenging and often intraoperative, relies on CT imaging showcasing peritoneal changes. Conservative treatment, emphasizing bowel rest and nutrition, is recommended for minor symptoms. Severe cases may require surgical intervention, including adhesiolysis and membrane excision. SEP carries mortality rates of 26 to 58 percent, with malnutrition and sepsis as common causes of death.

Conclusion: SEP poses diagnostic challenges, often requiring surgical exploration. Preoperative diagnosis through a combination of imaging guides appropriate management, avoiding unnecessary surgeries and optimizing patient outcomes.

1. *Keywords: [Sclerosing Encapsulating Peritonitis ; Abdominal Cocoon Syndrome ,Diagnosis ,CT Imaging ,Conservative Treatment ,Surgical Intervention, ,Preoperative Diagnosis]*

1. INTRODUCTION

Sclerosing encapsulating peritonitis (SEP) is a rare clinical entity and is often encountered unexpectedly in patients admitted with other different diagnosis .called also cocoon syndrome because of the existence of an abnormal membrane that contains part or the entire small intestine. The diagnosis is difficult and made generally during the surgical procedure , so a high index of clinical suspicion in susceptible patients is necessary to achieve a preoperative diagnosis.

We report a case of a 38-year old woman who presented with features of subacute intestinal obstruction due to an abdominal cocoon who was treated successfully by surgery.

2. PRESENTATION OF CASE

A 38-year-old woman was referred to our hospital for chronic intermittent abdominal pain, bloating, with recurrent episodes of nausea, vomiting and weight loss of 8 kg.

The patient had no history of tuberculosis or any positive contacts. and had no symptom of fever, chronic cough or night sweats

On physical examination, the woman was extremely thin with a BMI of 14.58. Vital signs were normal, and abdominal examination revealed gross abdominal distension, ascites without tenderness, the per rectal examination was not significant except serum C-reactive protein (CRP) which was mildly elevated (15 mg/l, normal range < 5mg/l). The other laboratory blood analysis including others serum tumor markers (Carcinoembryonic Antigen Test, CA19-9, CA-125), liver functions test, renal functions test, were all within normal limits.

Ascitic fluid obtained by paracentesis were exudates in nature and negative for bacteria culture.

Contrast-enhanced computed tomogram of the abdomen revealed massive ascites in perihepatic space, perisplenic space and between the loops associated with an infiltration of the greater omentum realizing the aspect of <omental cake>, with right latero-uterine mass, measuring 32 x 28mm. (FIGURE 1)

For a better study, we have completed by a pelvic Magnetic resonance imaging (FIGURE 2) which highlights: right ovary measuring 25 mm with physiological follicles, uterus and left ovary were without abnormality, presence of abundant ascites with diffuse peritoneal enhancement

Unfortunately, we did not evoke the diagnosis at the time of the analysis of the imaging, because we were focused looking for a cancer, and during the review of the CT and MRI in postoperative period the abnormalities were evident with peritoneal thickening and marked in addition to small bowel abnormalities such the wall thickening and the encapsulation,

Due to the absence of orientation in front of this exudative ascites and by fear of not knowing a tumoral origin, we decided to practice an exploratory laparoscopy

A diagnostic laparoscopy using 10 mm supraumbilical port, showed in addition to clear ascites that the entire small bowel was all plastered and encapsulated in a membrane, then laparoscopic approach became unsafe and dangerous. Hence, a decision was made for midline laparotomy, in which a dense membrane was found encapsulating the small intestine and part of the ascending and descending colon, the appendix and ovaries were free. (FIGURE 3)

We retain the final diagnosis of encapsulating peritonitis.

Adhesiolysis was done and the membrane was partially excised, releasing the small bowel loops. The entire small intestine was viable, without serosal tears.

Postoperatively she remained well and was discharged on the seventh postoperative.

3. DISCUSSION

Sclerosing encapsulating peritonitis (SEP) is an uncommon illness in which the small bowel is completely or partially encapsulated either by fibro-collagenous membrane with either a local inflammatory infiltration, causing acute or chronic intestinal blockage. [7]

Initially called Peritonitis chronica fibrosa incapsulata and was described first time by Owtschinnikow in 1907. [9]

EPS occurs in 0.5 percent to 7.3 percent of people worldwide, but it can reach 17.2 percent in patients who have had peritoneal dialysis for fifteen years or over. [6]

The etiology and pathological features of the trapping membrane determine whether SEP is primary or secondary.

Primary SEP, also known as the abdominal cocoon syndrome, is categorized depending on the level of membrane encasement in three types

The first and the second involves the partial or the complete encasement of the intestine, respectively. In the third one, in addition to the small intestine, adjacent organs such as ovaries, caecum, the appendix, colon, stomach, and liver are also encased. [8]

Primary SEP is idiopathic, meaning it has no clear etiology. [8]

Secondary SEP is much more frequent because it is linked to a variety of factors. Peritoneal dialysis is the most common cause of secondary SEP.

Other factors that may lead to secondary SEP involve:

autoimmune disease, intestinal tuberculosis, recurrent peritonitis, beta-blocker treatment or chemotherapy or, peritoneal shunts, abdominal surgery, and fibrogenic foreign material [8]

SEP symptoms include intense abdominal pain, gastrointestinal obstruction, nausea, or vomiting that are irregular and persistent.

In addition to losing weight and, in certain cases, the requirement for parenteral feeding that result from an inability to maintain a sufficient diet. [6]

There are two crucial clinical signs to look for in order to diagnose this condition.

"Fixed, asymmetrical distension of the abdomen and difference in the consistency of the abdominal wall to palpation."

The flat area is hard due to the tight fibrous capsule, whereas the distended part is soft because of the thin-walled swollen small intestine without a fibrous layer covering it. [3]

Computed tomography (CT) scanning is an effective way to diagnose SEP, and a high index of suspicion in susceptible patients is necessary to achieve a preoperative diagnosis.

Recognition of characteristic CT findings helps in accurate diagnosis preoperatively and can help in appropriate clinical management.

The principal CT findings of EPS can be categorized into four categories.:

(1) peritoneal findings (peritoneal thickening, calcification, and marked enhancement);

(2) small bowel abnormalities (wall thickening, encapsulation, and dilation, leading to obstructive ileus with or without systemic inflammation);

(3) fluid collection (loculated fluid collection and recurrent hemorrhagic ascites);

(4) calcification (liver and splenic capsule calcification, bowel calcification, and posterior peritoneal wall calcification)" [1]

Although magnetic resonance imaging is less commonly utilized for diagnosis, it is likely to produce similar results that CT, in addition, ionizing radiation is avoided, and the intestinal encasement and peritoneal thickness are better delineated [10]

Histopathological examination is no longer necessary because the appearance of SEP on CT imaging, combined with clinical characteristics, allows for a clear diagnosis. [9]

The histologic features in SEP are non-specific, and they may mimic those seen in infectious peritonitis or simple peritoneal sclerosis [10] It displays fibro-connective tissue growth, dilated lymphatics and inflammatory infiltrates, however, no giant cells, foreign body granulomas, or birefringent material. [9]

Regrettably, no guidelines or therapies for SEP exist. There is a lack of solid scientific evidence, and evaluating the various SEP therapies is difficult and relies solely on observational data. [6]

conservative treatment

The literature suggests that individuals with minor abdominal symptoms should be treated conservatively, with bowel rest, nasogastric decompression, and then enteral or parenteral nutritional supplementation [8]

Nutritional disorders affect the majority of patients, thus addressing them is an important part of treatment. Optimizing the patients' nutritional status is critical because it can help them respond better to conservative treatment and prevent surgical complications like infection or fistulas. [8]

People who do not respond to conservative treatment could be placed on drugs in order to inhibit fibroblastic production by inhibiting collagen syntheses, such as steroids, tamoxifen, azathioprine, colchicine, or mycophenolic acid. However, their effectiveness requires further investigation [4]

surgical interventions

Patients with significant complaints of intestinal obstruction, those who have virgin abdomens, and those who do not respond to conservative treatment may be surgical candidates. [8]

Surgical options include adhesiolysis in addition to membrane excision, for patients with a gut injury, and resection plus anastomosis with or without a protective enterostomy in case of gut injury.

Technical difficulties may arise from fibrotic membrane sacs that wrap and encapsulate the intestinal loops such as thick plastic bags. Many transverse and longitudinal incisions may be required to separate these sacs from the underlying intestinal loops; [8]

This could make the membrane easier to remove, allowing the underlying intestines to resume their usual function and length.[8]

Gut perforation can occur if these membranes are not peeled off or excised, or if the removal process is hard..[8]

In most situations, an enterotomy is the primary repair, although intestinal resection is only used in cases of severe injuries and suspected or proven loss of gut vascular integrity..

Resection, especially when not clearly needed, may raise mortality rates in these patients. [8]

Patients with SEP have a significant death rate, ranging from 26 to 58 percent, which rises with peritoneal dialysis vintage.

Malnutrition with sepsis are the most common causes of death in people with SEP [6]

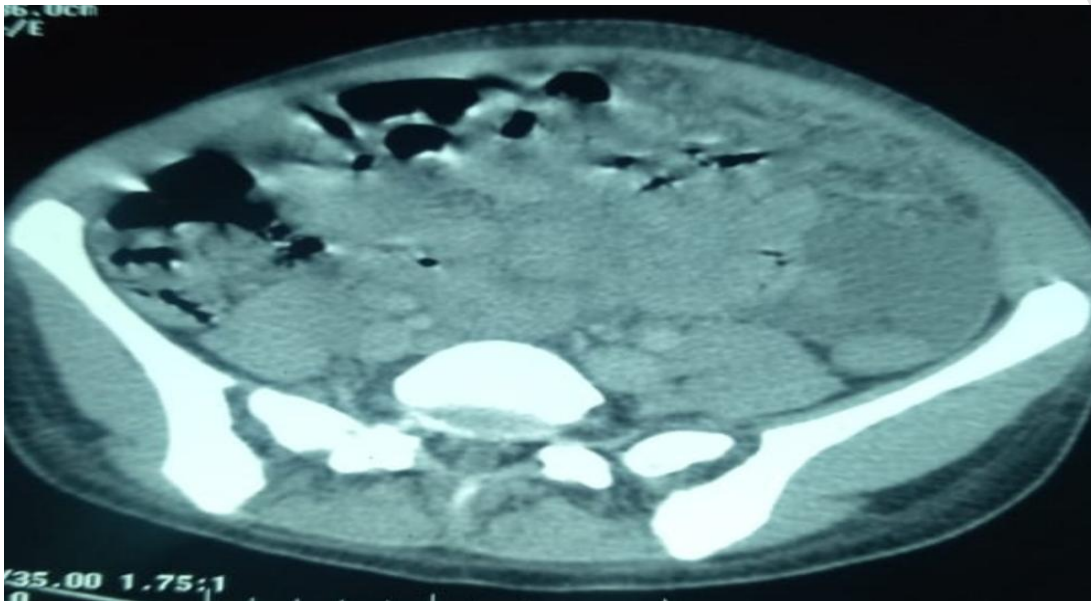


Figure 1 : axial CT of the abdomen showing ascite and latero-uterine mass

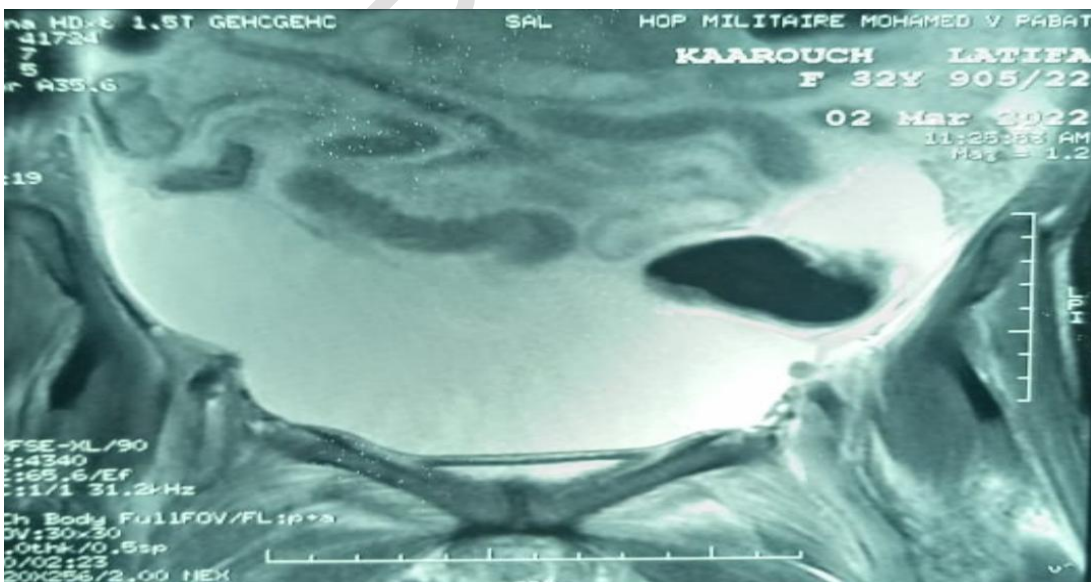


Figure 2 : coronal MRI of the abdomen showing ascite and diffuse peritoneal enhancement

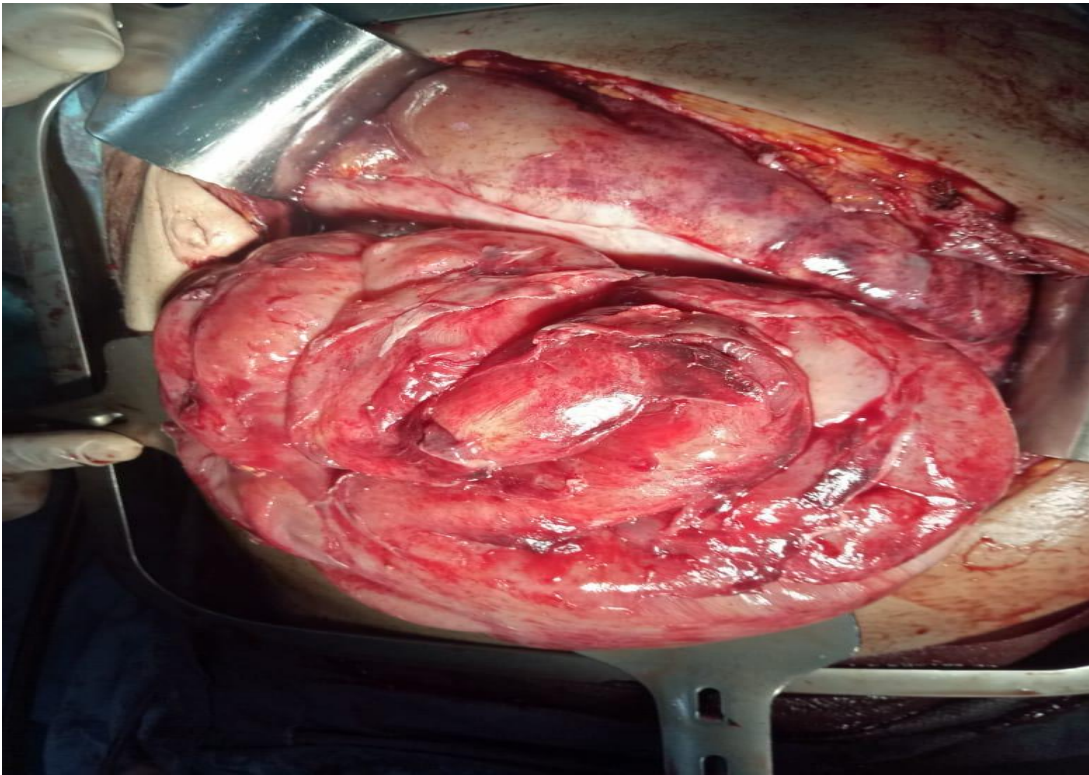


Figure 3 : operative view of the cocoon abdomen

4. CONCLUSION

the diagnosis of abdominal cocoon is difficult to make before surgery, however it should be considered whenever a patient complains of abdominal pain, nausea, or vomiting that's also accompanied by weight loss.

Preoperative diagnosis of this entity using a combination of diagnostic modalities such as sonography and Computed tomography scan can avoid unnecessary surgery and enable conservative management which is the ideal approach for patients who present with mild symptoms .

CONSENT

All authors declare that 'written informed consent was obtained from the patient (or other approved parties) for publication of this case report and accompanying images. A copy of the written consent is available for review by the Editorial office/Chief Editor/Editorial Board members of this journal.

REFERENCES

[1] :Basara Akin I, Altay C, Celik A, Secil M. Computed Tomography Features of Encapsulating Peritoneal Sclerosis. Can Assoc Radiol J. 2019 Aug;70(3):233-238. doi: 10.1016/j.carj.2018.11.005. Epub 2019 Mar 25. PMID: 30922787.

- [2] Asghar H, Raza R, Niazi IK, Siddiqui K. Encapsulated peritoneal sclerosis. *J Pak Med Assoc.* 2022 Jan;72(1):192-193. doi: 10.47391/JPMA.22-007. PMID: 35099469.
- [3] Sureka B, Mittal MK, Sinha M, Mittal A, Thukral BB. Abdominal cocoon. *Avicenna J Med.* 2013 Oct;3(4):103-5. doi: 10.4103/2231-0770.120502. PMID: 24327969; PMCID: PMC3841479.
- [4] Sghair A, Debaibi M, Kchaou M, Talbi S, Sridi A, Chouchen A. Idiopathic sclerosing encapsulating peritonitis: An uncommon cause of intestinal obstruction in a virgin abdomen. *Clin Case Rep.* 2022 Mar 15;10(3):e05603. doi: 10.1002/ccr3.5603. PMID: 35317068; PMCID: PMC8922953.
- [5] Aziz W, Malik Y, Haseeb S, Mirza RT, Aamer S. Abdominal Cocoon Syndrome: A Laparoscopic Approach. *Cureus.* 2021 Jul 31;13(7):e16787. doi: 10.7759/cureus.16787. PMID: 34513394; PMCID: PMC8405409
- [6] Jagirdar RM, Bozikas A, Zarogiannis SG, Bartosova M, Schmitt CP, Liakopoulos V. Encapsulating Peritoneal Sclerosis: Pathophysiology and Current Treatment Options. *Int J Mol Sci.* 2019 Nov 16;20(22):5765. doi: 10.3390/ijms20225765. PMID: 31744097; PMCID: PMC6887950.
- [7] Sharma D, Nair RP, Dani T, Shetty P. Abdominal cocoon-A rare cause of intestinal obstruction. *Int J Surg Case Rep.* 2013;4(11):955-7. doi: 10.1016/j.ijscr.2013.08.004. Epub 2013 Aug 20. PMID: 24055916; PMCID: PMC3825929.
- [8] Machado NO. Sclerosing Encapsulating Peritonitis: Review. *Sultan Qaboos Univ Med J.* 2016 May;16(2):e142-51. doi: 10.18295/squmj.2016.16.02.003. Epub 2016 May 15. PMID: 27226904; PMCID: PMC4868512.
- [9] Tannoury JN, Abboud BN. Idiopathic sclerosing encapsulating peritonitis: abdominal cocoon. *World J Gastroenterol.* 2012 May 7;18(17):1999-2004. doi: 10.3748/wjg.v18.i17.1999. PMID: 22563185; PMCID: PMC3342596.
- [10] Danford CJ, Lin SC, Smith MP, Wolf JL. Encapsulating peritoneal sclerosis. *World J Gastroenterol.* 2018 Jul 28;24(28):3101-3111. doi: 10.3748/wjg.v24.i28.3101. PMID: 30065556; PMCID: PMC6064970.