

1
2
3
4
5
6
7
8
9

Double rarity right Bochdalek’s hernia with intrathoracic kidney : A case report

ABSTRACT

Introduction:Bochdalek diaphragmatic hernia, a rare condition typically diagnosed before adulthood, presents diagnostic and therapeutic challenges. An even rarer occurrence involves the association of an intrathoracic right kidney with Bochdalek hernia. This article explores the complexities of treating such cases, considering both operative and non-operative options.

Aims: This study aims to present an exceptional case of a 75-year-old woman with a developing right-sided Bochdalek hernia and an acquired intrathoracic kidney. The chosen approach was conservative, and through observation, we highlight the diagnostic and therapeutic intricacies of this entity.

Presentation of Case: The patient, aged 75, diabetic, and hypertensive, presented to the emergency department with influenza-like illness. Clinical examination revealed stability but with a right basithoracic mass syndrome. Imaging, including thoracic radiograph and CT scan , confirmed a Bochdalek hernia and an intrathoracic right kidney. Given the fortuitous discovery, correct renal function, age, and comorbidity, a watch-and-see strategy was employed. The patient remained complaint-free during a 6-month follow-up.

Discussion:Bochdalek hernia, characterized by a posterolateral diaphragmatic defect, is relatively rare but often asymptomatic. Right-sided defects, affecting 10-20% of cases, pose diagnostic challenges due to their infrequency. Surgical intervention is recommended, with options ranging from minimally invasive to open surgery. The management of an intrathoracic ectopic kidney remains debated, with some advocating for mobilization into the abdomen, while others opt for reduction without direct manipulation.

Conclusion:Bochdalek hernias, particularly those associated with intrathoracic right renal ectopia, present diagnostic and management challenges. A high index of suspicion is crucial for timely diagnosis and treatment, leading to low morbidity and mortality rates. Clinicians should consider this condition in the differential diagnosis of lower intrathoracic masses.

Keywords: [Bochdalekhernia ;Diaphragmatic hernia ;Intrathoracic kidney ;Rare congenital condition]

1. INTRODUCTION

Bochdalek diaphragmatic hernia is a rare condition and is typically diagnosed prior to adulthood. Furthermore, right-sided defects are uncommon .

Intrathoracic right kidney associated with bochdalek hernia is extremely rare , and in addition to the diagnostic difficulty, this double association presents a challenge for the treatment. with the operative and non-operative options available.

10
11
12
13
14
15
16
17
18
19
20
21
22
23

24 However, nonoperative treatment has only been documented in a few number of patients to
25 far, with negligible morbidity and consequences. In this article, we describe an exceptional
26 case of an 75-year-old woman who came with a developing right-sided Bochdalek hernia
27 and an acquired intrathoracic kidney. We used a conservative strategy to treat the
28 patient. Through its observation, we recall the diagnostic and therapeutic particularities of this
29 entity.

30 **2. PRESENTATION OF CASE**

31

32

33 the patient was 75 years old, diabetic, hypertensive, had never undergone surgery and
34 denied any history of road accident or serious thoraco-abdominal trauma. admitted to the
35 emergency department for influenza-like illness 3 days previously, the clinical examination
36 found the patient to be hemodynamically stable with a febrile temperature of 38°C, and the
37 pleuropulmonary examination revealed a right basithoracic mass syndrome.

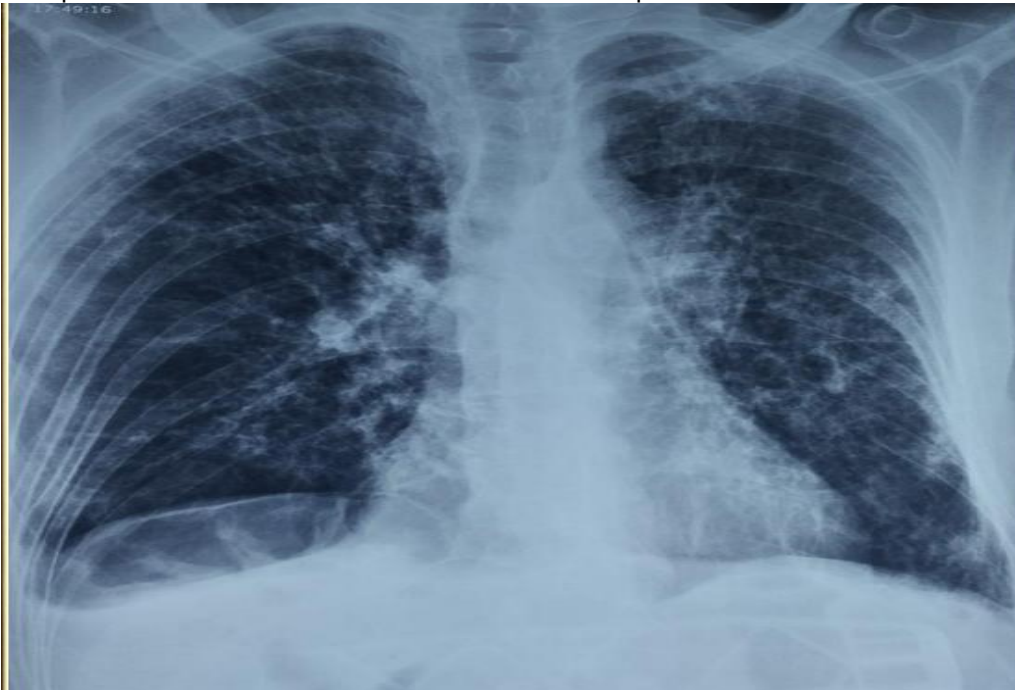38 thoracic radiograph (Figure N°1) shows an elevation of the right diaphragmatic cupola with
39 an opacity opposite

40 to better characterize this opacity, we performed a thoracic CT scan (Figure N°2), which
41 revealed a bochdalek hernia in addition to an ectopic right kidney located intrathoracically.

42 apart from an inflammatory syndrome, the biological work-up was without anomaly, i.e.
43 correct renal function with creatinemia at 10 mg/l.

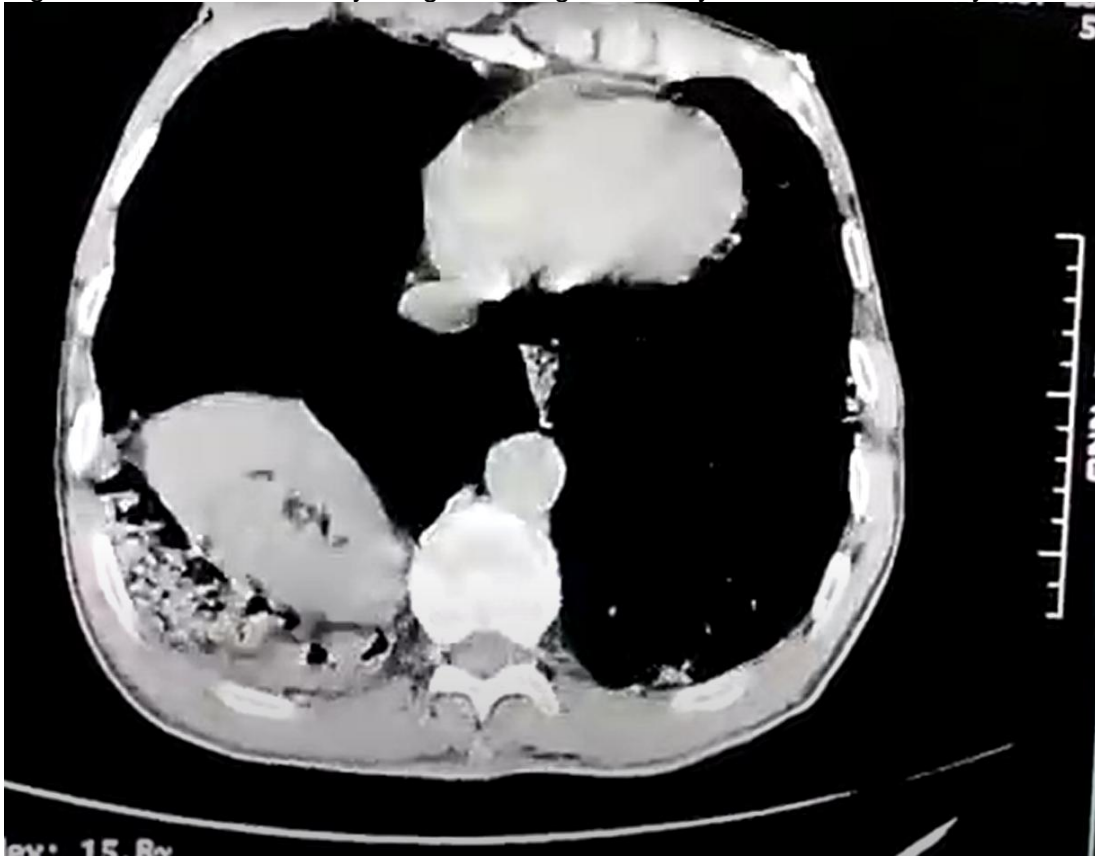
44 in view of the fortuitous discovery, and the correct renal function in addition to the patient's
45 advanced age and comorbidity, we opted not to operate on the patient with a watch-and-see
46 strategy.

47 The patient was reviewed 6 months later with no complaints.



48

49 Figure No1 : standard X-ray image showing the kidney in the thoracic cavity



50 Figure No2 : CT axial section showing the right kidney intra thoracically,
51

52 3. RESULTS AND DISCUSSION

53 Bochdalek hernia (BH) is named after VincenzAlexanerBochdalek since he originally
54 characterised it in 1848.[\[1\]](#)

55 Bochdalek hernia (BH) is a herniation via a posterolateral diaphragmatic defect, while
56 Morgagni hernia is a herniation over an anterior retrosternal or parasternal diaphragmatic
57 defect.[\[2\]](#)

58 It is believed that the pleuroperitoneal canal's incapacity to close at eight weeks of gestation
59 is what causes it. [\[3\]](#)

60 With a frequency of 0.08 to 0.45 per 1000 births, bochdalek diaphragmatic hernia is a
61 relatively rare disorder. [\[4\]](#)

62 Most often, it is discovered soon after delivery. In 5% of instances, it is discovered
63 incidentally during regular exams for stomach or respiratory issues, as was the case in our
64 observation. It stays asymptomatic in many individuals. [\[5\]](#)

65 between 80 and 90% of the time it affects the left side, whereas 10 to 20 percent of the time
66 it affects the right side.[\[2\]](#)

69 Due to liver support for the right hemidiaphragm and quicker closure of the right
70 pleuroperitoneal canal, right-sided hernias are uncommon. [3] On the left side of the body,
71 BH can affect the omentum (92%), splenic flexure of the colon (58%), stomach (25%), and
72 spleen. On the right side, BH can affect the liver or the small intestine. Kidney herniation
73 can occur in only 1% of cases [4]

74 The intrathoracic kidney is frequently asymptomatic.[6] because ectopic kidneys often
75 function normally and show no observable symptoms. [7].However, it happens extremely
76 infrequently for people to experience an acute emergency as a result of the herniated
77 abdomen contents being strangled..[6]

78 Typically, it is unintentionally discovered. These people's symptoms and X-ray images might
79 be misconstrued for pleuritis, pneumothorax, or pulmonary tuberculosis.[6]

80 Diaphragm abnormalities cannot be diagnosed using chest radiography; instead, a
81 computed tomography (CT) scan or magnetic resonance imaging (MRI) is far more
82 effective.. [6]

83 On thoracic radiographs, intrathoracic ectopic kidneys appear as lesions that resemble
84 paravertebral masses in the posterior mediastinum. There are a number of other differential
85 diagnoses, such as esophageal duplication cysts, bronchogenic cysts, pulmonary
86 sequestration, and descending aortic aneurysms. [4]

87 Despite the lack of agreement about the best strategy for action, the majority recommend a
88 surgical approach. [6]

89 Surgery is used to treat BH, using minimally invasive surgery or open surgery.[2]

90 When the diaphragmatic borders may be approached effortlessly, interrupted, non-
91 absorbable sutures are recommended; nevertheless, mesh should be utilized when the
92 diaphragmatic defect exceeds beyond 20 to 30 cm2[8-9].

93 **Watchful waiting may be a suitable strategy in selected cases. [6] especially in**
94 **asymptomatic patients or those with advanced age and multiple diseases, as in the**
95 **case of our patient.**

96 However, there is still debate on how to treat the ectopic kidney. While some surgeons
97 chose to mobilize the intrathoracic kidney into the abdomen and position it in a location that
98 was close to normal, others just reduced other contents into the abdominal cavity without
99 touching the kidney. [7]

100 Additionally, isolated intrathoracic ectopic kidney patients who have had long-term follow-up
101 have not experienced any problems. [10]

102 Nevertheless, these individuals would benefit from regular monitoring and follow-up because
103 of the kidney's unusual location and the possibility of complications.

104 which makes the choice of a standard treatment derisory, the choice will have to take into
105 account local conditions as well as the patient's free and informed consent to the benefits
106 and risks of each therapeutic option. Individualized, multidisciplinary management should be
107 used.[6]

108

109

110

111 **4. CONCLUSION**

112

113 Bochdalekhernia are rare clinical entities that pose many diagnostic and management
114 challenges for clinicians. its association with intrathoracic right renal ectopia is extremely
115 rare.

116 Only in cases when the treating physician has a very high level of suspicion may a diagnosis
117 be made for both of these diseases.

118 It is highlighted that this condition should be taken into account while making a lower
119 intrathoracic mass differential diagnosis. Low morbidity and death rates can be achieved
120 with rapid detection and timely treatment when there is a high index of suspicion.

121

122

123

124

125 **CONSENT**

126 As per international standard or university standard, patient(s) written consent has been
127 collected and preserved by the author(s).

128 **ETHICAL APPROVAL**

129 As per international standard or university standard written ethical approval has been
130 collected and preserved by the author(s).

131 **COMPETING INTERESTS**

132 Authors have declared that no competing

133 **REFERENCES**

134

135 1. Sutedja, B. and Muliani, Y. (2015), Laparoscopic repair of Bochdalek hernia. Asian

136 J Endosc Surg, 8: 354-356. <https://doi.org/10.1111/ases.12179>

137 2. Kumar N, Gupta A, Rajput D. Bochdalek hernia in an adult female with intrathoracic

138 left kidney and splenic flexure of the colon: a rare case report with literature review.

139 Pol PrzeglChir. 2019 Jun 16;92[3]:60–3.

140 3. Karaoglanoglu N, Turkyilmaz A, Eroglu A, Alici HA. Right-sided Bochdalek hernia

141 with intrathoracic kidney. PediatrSurg Int. 2006 Dec;22(12):1029–31.

142 4. Chen B, Finnerty BM, Schamberg NJ, Watkins AC, DePizzo J, Zarnegar R.

143 Transabdominal robotic repair of a congenital right diaphragmatic hernia containing
144 an intrathoracic kidney: a case report. J Robot Surg. 2015 Dec 1;9[6]:357–60.

145 5. Topor L, Pătrăncuș T, Caragața R, Moga A. Left congenital diaphragmatic

146 hernia -- case report. Chirurgia (Bucur). 2015 Jan-Feb;110[2]:84-7. PMID:

147 25800323.

148

149

- 150 6. Salcedo G, Velez F, Posada M, Barragan C, Vorwald P. Right-sided Bochdalek
151 hernia associated with an intrathoracic kidney in an adult. Surgery. 2021
152 Oct;170[6]:e13–4.
- 153 7 Yu M, Chen F, Wei S, Xie H. Treatment for Right-sided Intrathoracic Kidney With
154 Congenital Diaphragmatic Hernia by Combined Thoracoscopic and Laparoscopic
155 Approach: A Case Report and Literature Review. Urology. 2022 Jul;165:e36–8.
- 156 8. Palanivelu C., Rangarajan M., Rajapandian S. et al.: Laparoscopic repair of adult
157 diaphragmatic hernias and eventration with primary sutured closure and pro-
158 sthetic reinforcement: a retrospective study. SurgEndosc, 2009; 23[7]: 978–985
159 9. Kitano Y., Lally K.P., Lally P.A.: Late-presenting congenital diaphragmatic her-
160 nia. J PediatrSurg, 2005; 40(12): 1839–1843.*
161
162
163
- 164 10. Sarac M, Bakal U, Tartar T, Canpolat S, Kara A, Kazez A. Bochdalek hernia
165 and intrathoracic ectopic kidney: Presentation of two case reports and review of the
166 literature. Niger J ClinPract. 2018 May;21[7]:681–6.
167
168
169