

Eclipse Solar Retinopathy : A Case Report

Abstract

Solar retinopathy is a rare clinical disturbance, for which spectral-domain optical coherence tomography (SD-OCT) findings are not always consistent. This study reports on one case affected by a solar eclipse and discusses its differential diagnosis. Methods: In 2019, A 30-year-old male was referred to an ophthalmology clinic for sudden blurred vision. Visual acuity was 20/100 in Right eye, and 20/50 in left eye. When measuring intraocular pressure, it was 18 in both eyes. Anterior segment the examination was unremarkable in each eye. The foveal reflex was reduced on dilated fundus examination, and Dull Pigment Macula OD was reduced. Within normal limits in OS. Maculopathy "Solar Retinopathy in OD", Posterior vitreous detachment (PVD) in OD. Conclusions: Solar retinopathy has a subtle presentation and leads to ocular diseases such as cataracts, and posterior vitreous detachment, SD-OCT, and fundus examination are useful tools for its diagnosis.

Keywords: Solar Eclipse Retinopathy, Phototoxicity, Retinal injury.

Introduction

A condition known as solar retinopathy explains retinal damage brought on by solar rays that affect eyes after sunbathing, watching a solar eclipse, or engaging in other activities that could expose the macular area to direct sunlight [1]. Welders' operating microscope, maculopathy, and endo illuminator-induced retinal injuries are a few further examples of photo retinal damage. All of these cases of retinal phototoxicity happen when rapid intraretinal photochemical reactions caused by strong light overwhelm the retina's normal defense and repair mechanisms [2]. The most prevalent type of solar retinal injury brought on by unprotected direct sun gazing during an eclipse is solar eclipse retinopathy[3]. Photochemical damage or thermally accelerated photochemical damage is the main factor in solar retinopathy[4,5]. When photons of light are absorbed by retinal chromophores like melanin, hemoglobin, xanthophyll, and other absorbers like lipofuscin, melanopsin, rhodopsin, cytochrome c oxidase, cone-pigments, and porphyrins, both photochemical damage and photothermal damage are triggered. Some of these compounds exhibit distinct wavelength-dependent absorption peaks, whilst others have a linear inverse relationship with wavelength (i.e., absorption spectra broaden as wavelength shrinks). Through several mechanisms, including oxygen-derived toxicity and free-radical damage, the ultraviolet spectrum plays a critical part in causing photochemical toxicity to the retinal tissue [6]. The photoreceptors and retinal pigment epithelium (RPE) in the outer retina are particularly vulnerable to photochemical deterioration. When electrons return to the ground state after being excited to higher energy levels by the absorbed

photons of incident solar radiation, the excess energy is lost. It then starts a chain reaction that results in the creation of free radicals (such as superoxide and hydrogen peroxide radicals), the oxidation of cellular lipids and proteins, the disruption of lysosomes, and ultimately tissue destruction [2,5]. When exposed to UV light, lipofuscin, a substance found in RPE, specifically damage RPE due to its absorption spectrum, which progressively increases with decreasing wavelength [2]. Despite virtually invariably being bilateral, asymmetrical solar retinopathy has the propensity to involve the dominant eye more severely. Acute solar burns and solar eclipse burns are characterized by chromatopsia, metamorphopsia, impaired vision, photophobia, and central and paracentralscotomas in the affected patients. However, a sizable portion of individuals can continue to be asymptomatic, and retinal abnormalities might be discovered by chance during a routine ocular exam. Visual acuity is typically just slightly worse (between 20/40 and 20/60), yet it can even be as low as 20/20 [2,5]. The fundus may initially appear normal or have retinal edema that goes away gradually, but after a few days, a yellow-white foveal lesion surrounded by patchy black pigmentation will form. Over several weeks to months, the lesion progressively transforms into a rounded, oval red foveal reflex. In almost all circumstances, visual acuity gets better over time gradually [7]. The outer retinal alterations, which can range in severity from a slight disruption of the ellipsoid zone (EZ) and interdigitation zone (IZ) to an outer retinal defect, tend to lessen throughout the disease with the restoration of architecture in the majority of instances. A generally worse end-visual function is invariably linked to the outer retinal abnormality. However, in the majority of cases, the visual function returns to a state close to normal; some people, however, have modest, permanent central or paracentralscotomas[2]. Systemic corticosteroids have been described by some writers to restore visual and anatomical function [3]. It's interesting to note that in certain cases, corticosteroid therapy led to the development of central serous chorioretinopathy[5,7]. The evidence for the benefits of corticosteroids is limited, and as retinal structure and function tend to improve over time without treatment, it is possible that their administration is not necessary. In recent years, the public has frequently received updates about upcoming solar and lunar eclipses through mainstream and social media due to increased access to media and the internet. As a result, there has been a rise in the incidence of solar retinopathy due to the general public's increased interest in viewing and photographing eclipses. The general people do not adopt these safety measures despite widespread social media advertisements by eye care professionals and health officials about the ocular risks of eclipse watching. This study examines the obstacles to utilizing proper safety gear to see the solar eclipse, including danger awareness, understanding of proper eclipse gear, and other relevant aspects.

Review of the Literature:

DishitaChawda and colleagues looked at how sun radiation impacts the eyes in their study. It was reported that both the onset of the condition solar retinopathy and retinal damage from high-intensity visible light, such as direct sun exposure. This also occurs

when people see eclipses without the proper eye protection. Intense light, especially blue light, damages the retina similarly in experimental mice.

It also demonstrated how light strikes the retina, a light-sensitive layer of tissue in the back of the eye, and how special cells known as photoreceptors transform light into electrical signals. These electrical transmissions from the retina to the brain travel along the optic nerve. The signals are then translated into images by the brain [8].

The outer layers of the retina are harmed by continuous, unprotected exposure to ultraviolet (UV) light from sources including arc welding, lasers, and sunlight, according to a study by TediBegaj et al[9].

Photoreceptors and the retinal pigment epithelium in the posterior pole are particularly sensitive to this radiation. This illness, historically known as solar retinopathy, typically affects young people with clear lenses who like watching solar eclipses.

Per G. Söderberg looked into the connection between optical radiation and the eyes. It has been proven that radiation does not hurt living things; only photochemical mechanisms do. Although to a lesser extent and depending on the child's age, the retina is also at risk when a child's eyes are exposed to UV radiation.

Over threshold exposure to UVR with brief delays in the beginning of damage results in a toxic reaction on the eye's surface, snow blindness, and cataracts. Eye lid cancer is among the ocular surface conditions that are connected to years of sub-threshold daily UVR exposure. Visible radiation puts the retina at danger. Instantaneous photochemical Type II retinal damage, sometimes referred to as sun blindness, is caused by a single above-threshold dosage that causes a slight delay in the onset of retinal damage.

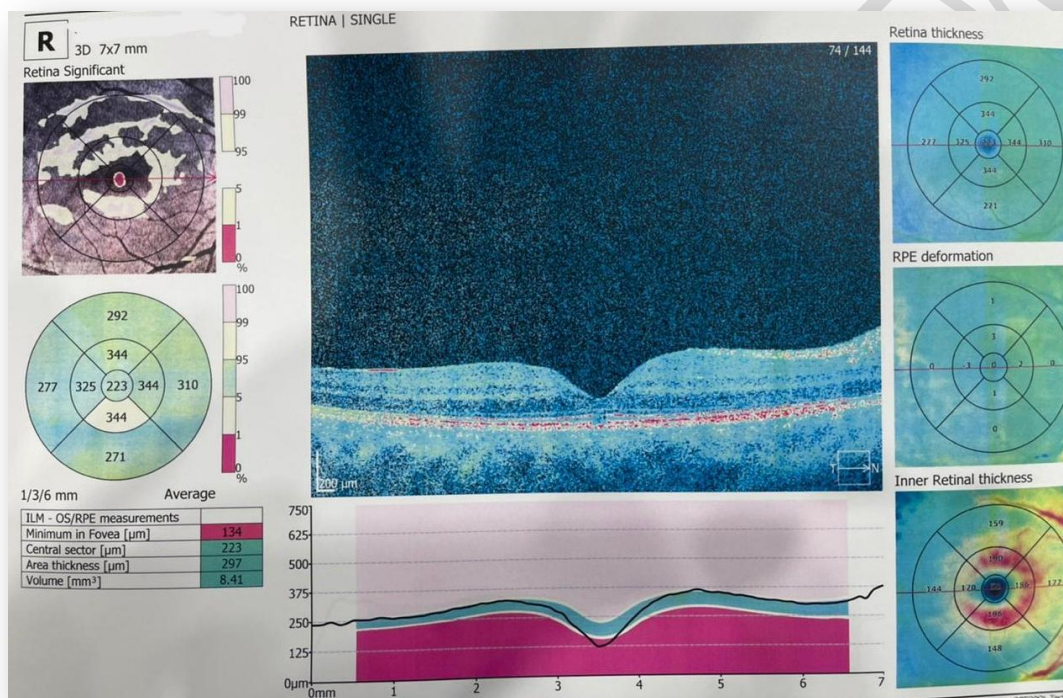
The retina could be thermally or mechanically harmed by a single, intense laser beam exposure. When a youngster is near a location with a lot of optical radiation, their eyes should be covered. Laws must be passed and the public must be informed if high intensity laser systems are to be protected from harm. More research is urgently needed in order to rule out any potential risks posed by near infrared radiation[10].

Case Report

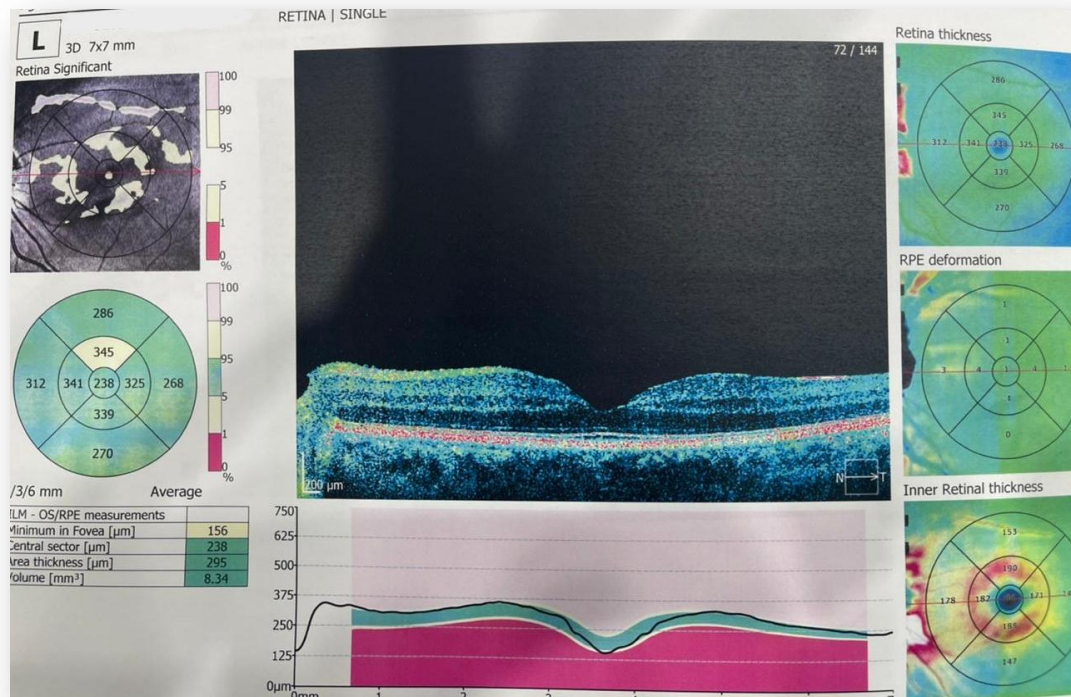
In the next day of the solar eclipse that occurred at December 2019, A 30-year-old Saudi male came to the eye clinic with complaints of sudden severe headache, nausea feeling, and blurry vision in both eyes. black lines and dots in front of right eye. He reported looking at the sun for a few seconds at the sun, without sunglasses and without wearing a hat. The patient denied using systemic and topical drugs and any previous medical and ocular history. His visual acuity was 20/100 in Right eye, and 20/50 in left eye. When measuring intraocular pressure, it was 18 in both eyes. Anterior segment the examination was unremarkable in each eye. On dilated fundus examination, the foveal reflex was reduced, and Dull Pigment Macula OD. Within normal limits in OS. Maculopathy "Solar Retinopathy in OD", Posterior vitreous detachment (PVD) in OD. After one year and 5 months had passed, the patient came to

the clinic complaining of blurry vision for a distance and near vision, and the vision in left eye was more blurred than right eye, after the examination, he found that he had cataracts, it was removed. The glasses were prescribed for distance for OD: +0.50 - 2.75 @60 NI, OS: -1.25@125 improved into 20/25, with ADD +2.25 OU. In addition to artificial tears, and follow up every 6 months. In all follow-ups the vision was stable and there was no change in the macula.

Figure 1. (a,b) OCT image shows a slight interruption of the external limiting membrane and of the inner and outer segment (IS/OS) junctions, RE appears affected more than LE.



(a)



(b)

DISCUSSION

A total solar eclipse is an incredibly awe-inspiring astronomical event that is often considered the most remarkable experience many individuals will encounter in their lifetime. It garners significant interest from both amateur and professional astronomers worldwide, who eagerly travel to different locations across the globe to observe and capture photographs of this phenomenon.

From an educational perspective, a solar eclipse offers students a unique opportunity to witness a natural occurrence that effectively exemplifies fundamental principles of mathematics and science taught throughout primary and secondary education. The observation of solar eclipses can serve as a practical demonstration of how the laws of motion and mathematical concepts related to orbital motion can accurately predict the incidence of eclipses. Additionally, by employing pinhole cameras, telescopes, or binoculars to view an eclipse, students can gain an understanding of the optical principles underlying these devices. The fluctuation in environmental light levels during an eclipse can further illustrate the principles of radiometry and photometry, while biology classes can witness the corresponding behavioral changes in plants and animals. Moreover, students of school age can actively contribute to scientific research by making observations of contact timings at various locations along the path of the eclipse. These observations are valuable in refining our understanding of the orbital motions of the Moon and Earth. Sketches and photographs capturing the solar

corona during an eclipse can be utilized to construct a three-dimensional representation of the Sun's extended atmosphere [13].

However, it is crucial to recognize the potential dangers associated with observing the Sun without taking proper precautions. The solar radiation reaching the Earth's surface spans from ultraviolet (UV) radiation with wavelengths longer than 290 nm to meter-range radio waves. The tissues in the eye transmit a significant portion of radiation between 380 and 1400 nm to the light-sensitive retina at the back of the eye. While environmental exposure to UV radiation is known to contribute to the premature aging of the outer eye layers and the development of cataracts, the primary concern during an eclipse is the occurrence of "eclipse blindness" or retinal burns [13].

It was observed in this case that the solar eclipse led to the occurrence of cataracts, and this is consistent with the study conducted by DishitaChawda et al [11].

It was observed in this case that the solar eclipse led to the occurrence of posterior retinal detachment, and this is consistent with the study conducted by Borroni D et al[12].

When the retina is exposed to intense visible light, it undergoes damage to its light-sensitive cells, including the rods and cones. This damage is caused by a series of intricate chemical reactions within the cells that impair their ability to respond to visual stimuli. In severe cases, these reactions can lead to the destruction of the cells themselves. Consequently, the result is a loss of visual function that can be either temporary or permanent, depending on the extent of the damage. Looking directly at the Sun for prolonged periods or repeatedly, without proper eye protection, can cause this photochemical retinal damage along with a thermal injury. The high levels of visible and near-infrared radiation emitted by the Sun can generate heat that effectively "cooks" the exposed tissue, leading to thermal injury or photocoagulation. This process further destroys the rods and cones, resulting in the formation of a small blind spot. The significant risk to vision lies in the fact that photic retinal injuries occur without any pain sensation, as the retina lacks pain receptors. Furthermore, the visual effects of such injuries may not manifest until several hours after the damage has occurred[14].

It is important to emphasize that the only time it is safe to view the Sun with the naked eye is during a total eclipse when the Moon completely obscures the solar disk[14]. Looking at a partial or annular eclipse, or even the partial phases of a total solar eclipse, without appropriate equipment and techniques is never safe. Even when 99% of the Sun's surface (photosphere) is blocked during the partial phases of a solar eclipse, the remaining crescent of the Sun still emits sufficient intensity to cause retinal burns, despite illumination levels resembling twilight. Failure to employ proper observing methods can lead to permanent eye damage or severe visual impairment, which can have significant adverse effects on career choices and earning potential. It has been noted that most individuals who sustain eclipse-related eye injuries are children and young adults[14].

Conclusions

Solar retinopathy has a subtle presentation and leads to ocular diseases such as cataracts, and posterior vitreous detachment, SD-OCT, and fundus examination are useful tools for its diagnosis.

Ethical Approval:

As per international standard or university standards written ethical approval has been collected and preserved by the author(s).

Consent

As per international standards or university standards, patient(s) written consent has been collected and preserved by the author(s).

References :

- [1]L. J. A. eclipse retinopathy: a small case series. *J. of optometry*. 2014;7(4):225-8. Khatib N, Knyazer B, Lifshitz T,
- [2]https://www.researchgate.net/publication/273866350_Acute_Solar_Retinopathy,
- [3]<https://pubmed.ncbi.nlm.nih.gov/31233157/>,
- [4]diagnosis and treatment. *R. P.* 2013;10:46-50. Chen KC, Jung JJ, Aizman A. Solar retinopathy: Etiology,
- [5]A. P. P. damage of the retina. *S. O.* 2006;51(5):461-81. doi:10. 1016/j. survophthal. 2006. 06. 009. Wu J, Seregard S.
- [6]W. D. T. susceptibility of the retina to photochemical damage from visible light. *P. in R. and E. R.* 2012;31(1):28-42. Hunter JJ, Morgan JIW, Merigan WH, Sliney DH, Sparrow JR.
- [7]A. D. U. findings in solar retinopathy. *E.* 1993;7(1):29-33. doi:10.1038/eye. 1993. 7. Hope-Ross MW, Mahon GJ, Gardiner TA.
- [8]E. Chawda, D., & Shinde, P. (2022). Effects of Solar Radiation on the Eyes. *Cureus*, 14(10).
- [9] Begaj, T., & Schaal, S. (2018). Sunlight and ultraviolet 174-192. radiation—pertinent retinal implications and current management. *Survey of ophthalmology*, 63(2).
- [10] Bergmanson, J. P. G., & Söderberg, P. G. (1995). The significance 83-91. of ultraviolet radiation for eye diseases: a review with comments on the efficacy of UV-blocking contact lenses. *Ophthalmic and Physiological Optics*, 15(2).

[11] Chawda, D., & Shinde, P. (2022). Effects of Solar Radiation on the Eyes. *Cureus*, 14(10).

[12] Semes, L. (2020). When a retinal detachment isn't a retinal detachment. *Optometry Times Journal*, 12(10).

[13] Espenak, F. (2012). Eye Safety During Solar Eclipses. *National Aeronautics and Space Administration*. Accessed from <https://eclipse.gsfc.nasa.gov/SEhelp/safety.html>.

[14] Chou, B. R. (2016). Solar eclipse eye safety. *Am Astron Soc*, 1, 1-9.

UNDER PEER REVIEW