

Docetaxel-induced bilateral cystoid macular edema with a low cumulative dose: A case report

Abstract:

Docetaxel and paclitaxel are taxanes. They are widely used chemotherapeutic agents that have been shown to be effective for various types of solid malignancies. Docetaxel-related bilateral toxic cystoid macular edema (T-CME) has been reported as a rare and unusual adverse reaction. We report a case of 43-year women treated for breast cancer with docetaxel and developed T-CME. She was treated with two cycles of Docetaxel 150 mg, Pertuzumab 420 mg and Trastuzumab 360mg. Three days after 2nd cycle she complained of diminution of vision. Her both eye visual acuity was 20/200. Fundus examination showed macular edema which was confirmed with SD-OCT and fluorescein angiography. After fourth cycle Docetaxel was stopped by treating physician. CME was completely resolved by three months. Several studies suggest that a cumulative dose seems necessary for the onset of the toxic effect of this drug. To our knowledge, we report the first case of Docetaxel-induced T-CME occurring within less than 1 month, with a very low cumulative dose. This suggests that no cumulative dose is needed for macular edema to appear.

Key Words: cystoid macular edema, docetaxel, ocular toxicity, chemotherapy.

Introduction:

“Taxanes as cytotoxic drugs have been commonly used in chemotherapy for over 20 years. The mechanism of action of taxanes is based on inhibition of the mitotic spindle. They bind to beta-tubulin subunits of microtubules, inhibit depolymerization and cause mitotic arrest of cells”[1]. “Docetaxel, one of the taxanes, was obtained from a non-cytotoxic precursor called *Taxus baccata*, approved for medical use in 1995”[2]. “This drug is used for the treatment of breast cancer, non-small cell lung cancer, prostate cancer, head and neck cancer and stomach cancer”[3-4-7].

Cystoid macular edema (CME) is a rare complication caused by Docetaxel. The exact mechanism is unclear, and the best treatment is to stop this causative agent.

We report here an interesting case of bilateral CME caused by docetaxel occurring within one month after starting the drug with a low cumulative dose of 300mg.

Case Report:

This case study is based on the case of a woman with no history of high blood pressure, diabetes, ocular or systemic inflammatory disease, followed for breast cancer. The patient has already received three cycles of chemotherapy, every three weeks based on Docetaxel 150mg, Pertuzumab 420mg and Trastuzumab

360mg. Three days after her second cycle of chemotherapy, she reported a decrease in her visual acuity and was referred by her attending physician for an ophthalmological opinion.

On the ophthalmological examination, the best corrected visual acuity was 20/200 in both eyes. Slit-lamp anterior segment examination and intraocular pressure were normal in both eyes. Fundus examination revealed a loss of foveal reflex in both eyes with no evidence of hyalitis or associated retinal vasculitis.

Spectral domain optical coherence tomography (SD-OCT) demonstrated bilateral macular edema (foveolar cystic cavities with macular thickening of 447um in the left eye and 434um in the right eye) (figure 1).

Fluorescein angiography showed normal filling of the choroidal and retinal vessels and an unremarkable parafoveal capillary network and no fluorescein leakage on the late angiograms phases (figure 2).

Hence, we diagnosed her as a toxic maculopathy, related to either Herceptin or Docetaxel, and notified her treating physician.

However, she received her fourth cycle of chemotherapy as routine. After fourth cycle Docetaxel was stopped by treating physician. Rest of chemotherapeutic cycles included only Pertuzumab and Trastuzumab every 3 weeks.

One month after stopping Docetaxel, visual acuity began to improve to reach 20/20 in both eyes at the third month. Macular control SD-OCT shows total resorption of the macular edema without sequelae (figure 3).

The good clinical and tomographic improvement after discontinuation of Docetaxel, allowed us to diagnose the macular toxicity effect of this product in this patient.

Discussion:

“Docetaxel is one of the taxanes that inhibit mitosis in cancer cells. Neutropenia, peripheral sensory neuropathy, muscle pain, arthralgia and alopecia are the most common systemic side effects of taxanes” [5]. “Cardiovascular complications include fluid retention (especially during Docetaxel treatment), arrhythmias or heart failure” [6]. Ophthalmologic side effects of taxane chemotherapy are less common or not frequently reported. They include cataract [7], obstruction of lacrimal punctum and/or ducts; excessive lacrimation (epiphora), Meibomian gland dysfunction, blepharitis, Chalazion [7], optic neuropathies; papilledema and cystoid macular edema [3-4-7-8].

Toxic cystoid macular edema (T-CME) is a rare side effect of taxanes, with an approximately incidence of 0.3 and 0.5% [4-7]. The first case of CME linked to the use of Docetaxel was reported in 2003 by Teitelbaum and Tresley [9]. It was angiographically silent and partially reversible after stopping treatment. Since then, 57 cases of T-CME linked to taxanes (Paclitaxel) have been reported in the literature in the form of cases or small case-series [7]. It is bilateral in more than 92% of cases [7-9]. In their recent literature review, Ya-Ting Ye & al [7], the average time to onset

of macular edema after taking the drug was 4.25 months. However, in another review, it is 9.3 months with a range: from 1.5 to 42 months [10].

For some authors, a 3-month therapy is sufficient to induce T-CME [8], and others [11-12], suggest that a cumulative dose seems responsible for the toxic effects of this therapy. "Indeed, when a cumulative dose of Docetaxel reached 200 mg/m², a significant decrease in the colloid osmotic pressure values of plasma (Plasma COP) and interstitial fluid (Interstitial COP), hemoglobin, hematocrit, albumin and total proteins decrease significantly"[14]. These authors suggested that an increase in plasma volume was followed by an accentuation of fluid filtration towards the interstitial medium [12]. "The cumulative dose of Docetaxel needed for this side effect is 300–400 mg/m² and increases with additional corticosteroid therapy to 746 mg/m²"[12].

For our patient, the macular syndrome appeared three days after the second course of Docetaxel chemotherapy, which corresponds to 24 days after starting this medication with a cumulative dose of only 300mg (120 mg/m²).

This leaves us to propose that taxanes toxicity can appear early and does not depend on cumulative dose. To our knowledge, our patient is the first case reported in the literature with a time to onset of macular edema not exceeding one month. We suggest further studies which may help us to find the answer.

"Fluorescein angiography has an important contribution in the diagnosis, showing a normal filling of the choroidal and retinal vessels and an intact parafoveal capillary network"[12-3-7-11]. Late images show no significant leaks. This appearance resembles that of macular edema encountered in degenerative pathologies such as Goldmann-Favre syndrome, certain types of retinitis pigmentosa, phototoxicity, and the use of drugs such as niacin [13]. "It eliminates other causes of CME with diffusion of fluorescein such as diabetes, age-related macular degeneration (AMD), Irvine-Gass syndrome, uveitis, central vein occlusion (CRVO) or branch retinal vein occlusion (BRVO) and the use of drugs such as thiazolidinediones, tamoxifen, topical medications: epinephrine, prostaglandins E₂, timolol"[3-9].

SD-OCT images show larger hyporeflexive cysts located in the outer nuclear layer and smaller cysts in the inner nuclear layer, with an intact outer retinal layer. The involvement is focal and symmetrical, centered around the fovea [8-15]. These same SD-OCT results were found in our patient. The absence of hyperreflective plaques associated with exudation seen in central retinal vein occlusion and diabetes edema, does not establish the outcome of vascular degeneration or vascular occlusion [10]. The study by Joel M. Perez & al [15] is the first to publish the results of A-OCT in the case of T-CME. She reports no flow disturbance in a normal foveal avascular area supporting the hypothesis that this is not a vascular-mediated phenomenon.

"To date, the exact pathophysiological mechanism underlying taxane maculopathy remains unclear"[8]. "Several possible mechanisms have been advocated, and the most accepted one is retinal pigment epithelium (RPE) dysfunction, causing fluid accumulation in the retinal layers"[7-8].

Acetazolamide, prednisolone, triamcinolone, dorzolamide and intravitreal injection of anti-Vascular endothelial growth factor (anti-VGEF) [10-15], have been used in the treatment of these T-CME, however, none of these products has proven effective. In most reported cases, resorption of macular edema occurs spontaneously after discontinuation of taxanes without any ocular treatment within 1.5 weeks to 6 months) [10-14-15].

Conclusion:

Toxic cystoid macular edema (T-CME) is a rare complication caused by Docetaxel. The exact mechanism is unclear. In most cases T-CME is self-resolving after stopping the drug.

It can be associated with a low dose of Docetaxel (300mg only (120 mg/m²)) than reported in literature. We suggest further studies which may help us to find the answer.

Consent:

As per international standards, parental written consent has been collected and preserved by the author(s).

Ethical Approval:

As per international standard or university standard written ethical approval has been collected and preserved by the author(s).

Competing Interests:

Authors have declared that no competing interests exist.

Figures:

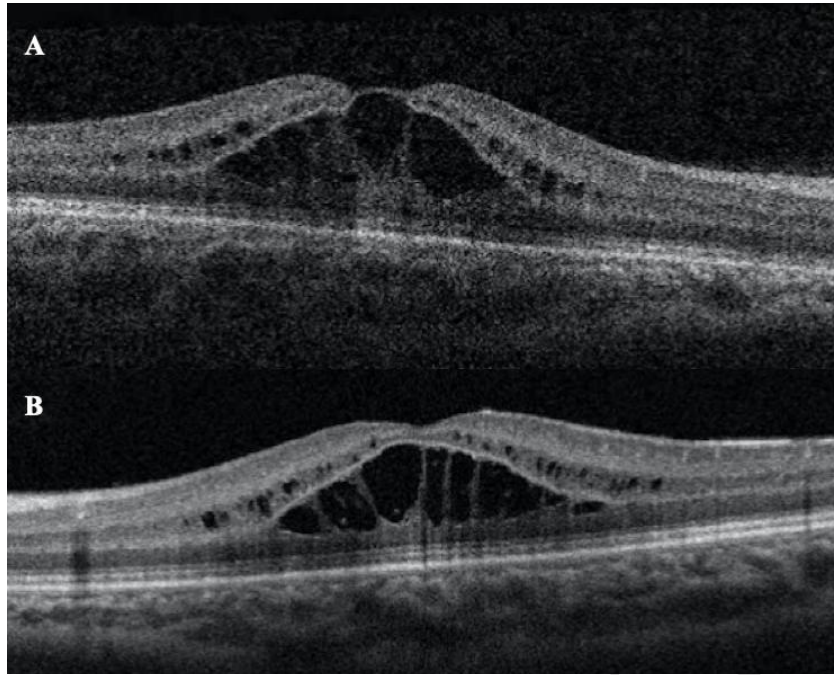


Figure 1 (A: Right eye, B: Left eye): Spectral domain optical coherence tomography (SD-OCT) demonstrating bilateral macular edema with foveolar cystic cavities.

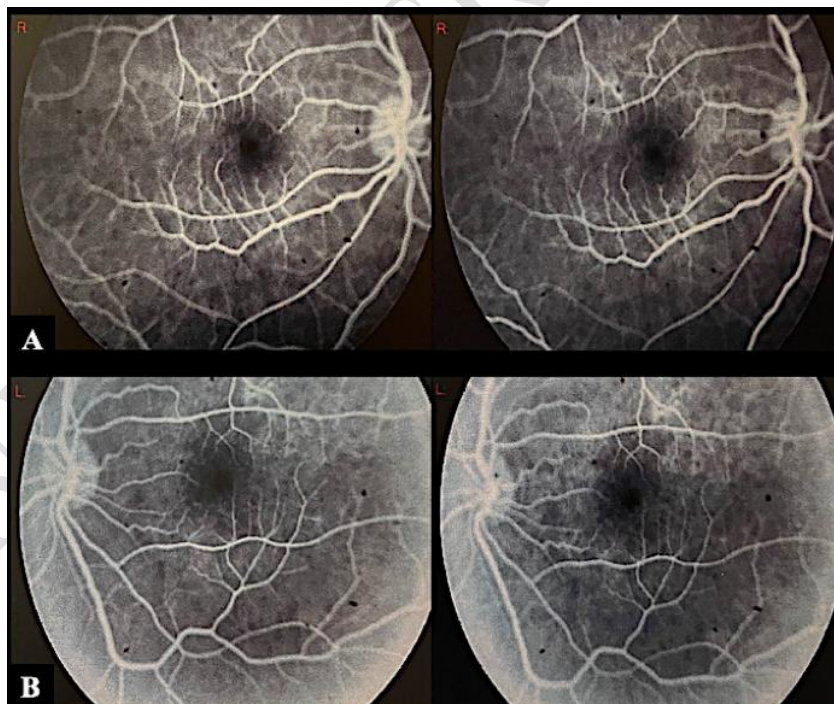

Figure 2 (A: Right eye, B: Left eye): Fluorescein angiography photography showing normal filling of the choroidal and retinal vessels, an unremarkable parafoveal capillary network and no fluorescein leakage on the late angiograms phases.

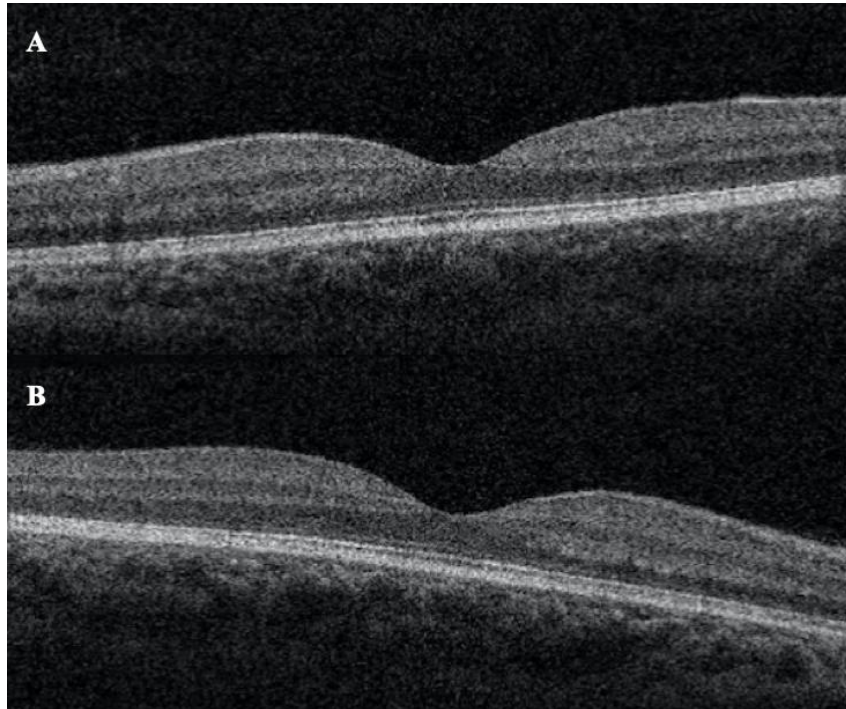


Figure 3 (A: Right eye, B: Left eye): Macular control with SD-OCT (3months after stopping Docetaxel) showing total resorption of the macular edema without sequelae.

References:

- 1) Mutschler E, Geisslinger G, Kroemer HK. Farmakologia i toksykologia. Wyd. IV. (ed. pol. Drożdżik M). MedPharm Polska, Wrocław 2016 : 882-884.
- 2) Fumoleau, P., Seidman, A. D., Trudeau, M. E., Chevallier, B., & Ten Bokkel Huinink, W. W. (1997). Docetaxel: a new active agent in the therapy of metastatic breast cancer. *Expert opinion on investigational drugs*, 6(12), 1853–1865. <https://doi.org/10.1517/13543784.6.12.1853>
- 3) Rzeszotarska A, Stodolska-Nowak A, Kufel-Grabowska J, Nowakowski B, Kocięcki J. Ocular side effects of the taxane-based chemotherapy – do only vascular disorders matter? *OncoReview* [Internet]. 2019Sep.30 [cited 2023Nov.15];9(3(35):59-3. Available from: <https://www.journalsmededu.pl/index.php/OncoReview/article/view/1088>
- 4) Fortes, B. H., Liou, H., & Dalvin, L. A. (2022). Ophthalmic adverse effects of taxanes: The Mayo Clinic experience. *European journal of ophthalmology*, 32(1), 602–611. <https://doi.org/10.1177/1120672120969045>
- 5) Pazdur, R., Kudelka, A. P., Kavanagh, J. J., Cohen, P. R., & Raber, M. N. (1993). The taxoids: paclitaxel (Taxol) and docetaxel (Taxotere). *Cancer treatment reviews*, 19(4), 351–386. [https://doi.org/10.1016/0305-7372\(93\)90010-o](https://doi.org/10.1016/0305-7372(93)90010-o)
- 6) Peroukides, S., Alexopoulos, A., Kalofonos, H., & Papadaki, H. (2012). Cardiovascular effects of treatment with taxanes. *Journal of cardiovascular medicine (Hagerstown, Md.)*, 13(5), 319–324. <https://doi.org/10.2459/JCM.0b013e3283529060>
- 7) Ye, Y. T., Zhou, Z. Y., Wen, L. S., Sun, Y., Chu, Z. J., & Dou, G. R. (2022). The Significance of the Ocular Adverse Effect Induced by Systemic Taxane Application. *Frontiers in bioscience (Landmark edition)*, 27(6), 171. <https://doi.org/10.31083/j.fbl2706171>
- 8) Kuznetcova, T. I., Cech, P., & Herbort, C. P. (2012). The mystery of angiographically silent macular edema due to taxanes. *International ophthalmology*, 32(3), 299–304. <https://doi.org/10.1007/s10792-012-9558-9>
- 9) Teitelbaum, B. A., & Tresley, D. J. (2003). Cystic maculopathy with normal capillary permeability secondary to docetaxel. *Optometry and vision science: official publication of the American Academy of Optometry*, 80(4), 277–279. <https://doi.org/10.1097/00006324-200304000-00004>
- 10) Ye, S., Fang, Q., Yao, J., Xing, J., Tang, S., & Ma, J. H. (2021). Intravitreal Ranibizumab Had Limited Effect on Cystoid Macular Edema Due to Albumin-Bound Paclitaxel: A Case Report and Literature Review. *Frontiers in oncology*, 11, 773540. <https://doi.org/10.3389/fonc.2021.773540>
- 11) Michaud, L. B., Valero, V., & Hortobagyi, G. (2000). Risks and benefits of taxanes in breast and ovarian cancer. *Drug safety*, 23(5), 401–428. <https://doi.org/10.2165/00002018-200023050-00005>
- 12) Béhar, A., Pujade-Lauraine, E., Maurel, A., Brun, M. D., Chauvin, F. F., Feuilhade de Chauvin, F., Oulid-Aissa, D., & Hille, D. (1997). The pathophysiological mechanism of fluid retention in advanced cancer patients treated with docetaxel, but not receiving corticosteroid comedication. *British journal of clinical pharmacology*, 43(6), 653–658. <https://doi.org/10.1046/j.1365-2125.1997.00613.x>
- 13) Semb, K. A., Aamdal, S., & Oian, P. (1998). Capillary protein leak syndrome appears to explain fluid retention in cancer patients who receive docetaxel treatment. *Journal of clinical oncology: official journal of the American Society*

of Clinical Oncology, 16(10), 3426–3432.

<https://doi.org/10.1200/JCO.1998.16.10.3426>

- 14) Yokoe, T., Fukada, I., Kobayashi, K., Shibayama, T., Miyagi, Y., Yoshida, A., Iwase, T., Ohno, S., & Ito, Y. (2017). Cystoid Macular Edema during Treatment with Paclitaxel and Bevacizumab in a Patient with Metastatic Breast Cancer: A Case Report and Literature Review. *Case reports in oncology*, 10(2), 605–612. <https://doi.org/10.1159/000477897>
- 15) Perez, J. M., Teo, K., Ong, R., Maruyama-Inoue, M., Freund, K. B., & Tan, A. C. S. (2020). Optical coherence tomography characteristics of taxane-induced macular edema and other multimodal imaging findings. *Graefes archive for clinical and experimental ophthalmology = Albrecht von Graefes Archiv fur klinische und experimentelle Ophthalmologie*, 258(8), 1607–1615. <https://doi.org/10.1007/s00417-020-04755-z>

UNDER PEER REVIEW