

Two-year-old boy with gross hematuria

Abstract:

Ureteric calculus in pediatric age group is rare. Most common cause of pediatric hydronephrosis is PUJ (pelvi-ureteric junction) obstruction, but hydronephrosis due to VUJ (vesico-ureteric junction) obstruction by ureteric calculus is rare in this population. Recently we diagnosed such an unusual case of unilateral hydronephrosis due to VUJ calculi in a 2-year old boy by trans-abdominal ultrasound.

Introduction:

Urolithiasis is a disorder frequently seen in adults, whereas its occurrence in children is rare. There are significant differences between the pediatric and the adult population regarding clinical presentation, etiology and treatment which presents as a challenge for diagnosis. Prompt diagnosis of the condition in pediatric population using modalities such as Ultrasound can prevent further complications in patients.

Case Report:

Master Jakariya, 2 years of age, hailing from Shuagaji, Cumilla came to OPD (Out Patient Department), Cumilla Medical College Hospital with the complaints of gross hematuria for 4 months. The bleeding occurred intermittently, at the start of micturition, continued throughout the process and was associated with occasional colicky right sided abdominal pain but not associated with fever. There was no history of trauma or previous bleeding disorders. On examination, the patient was mildly anemic, non-icteric, non-edematous and no purpura, petechiae or bruise was seen on the skin. His blood pressure was normal, pulse was 88 beats/min, temperature was normal. Abdominal examination revealed a soft non-tender abdomen without any mass. Other systemic examination revealed no abnormality. Patient was referred to Institute of Nuclear Medicine and Allied Sciences (INMAS), Cumilla for KUB ultrasound scan. Ultrasonogram revealed two bright echogenic shadow-casting structures (12mm&8mm) at right vesico-ureteric junction (VUJ) with mildly dilated right ureter along with pelvi-calyceal system. On Doppler study VUJ calculi shows characteristic “twinkling” artifact. The left kidney and ureter appeared normal. Urinary bladder was filled with internal low-level echoes but normal

wall thickness. The patient was further evaluated with plain X-ray of KUB region which revealed two radiopaque stones at the region of right VUJ.

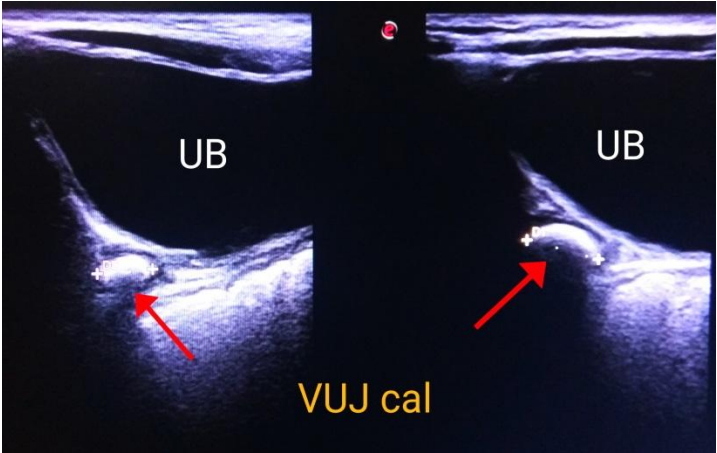


Figure 1: Ultrasound image showing ureteral calculi.

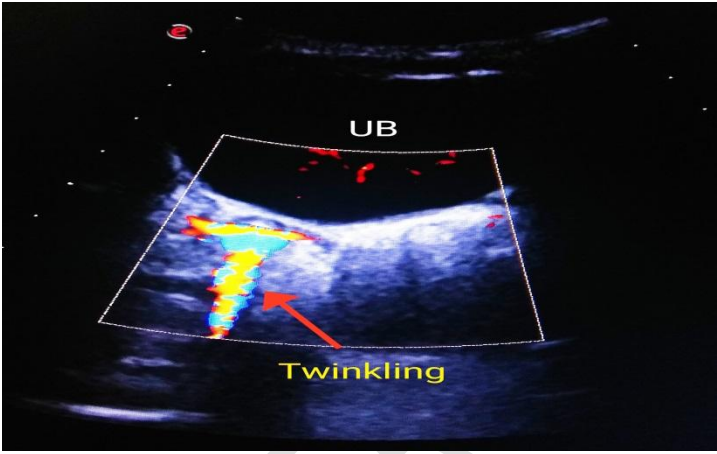


Figure 2: Ultrasound image showing 'Twinkling' artifact of calculus on color Doppler.

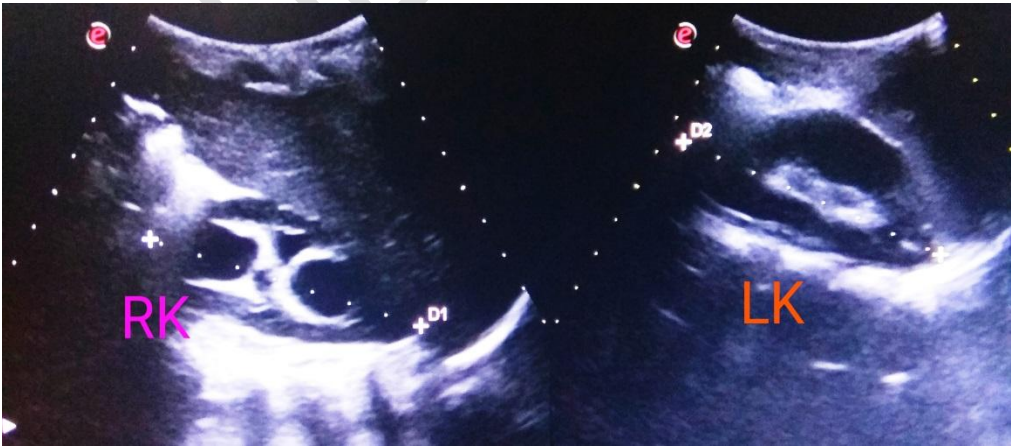


Figure 3: Ultrasound image showing mild hydronephrosis in right kidney compared to normal left kidney.

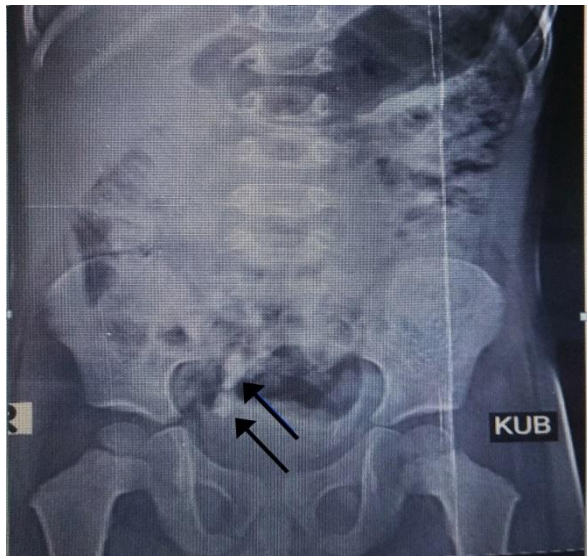


Figure 4: Plain X-ray KUB region showing two radiopaque shadows in right pelvis

Discussion:

Young children with urolithiasis do not often present with the classic acute onset of flank pain commonly seen in adults. As a result, children are frequently evaluated for other conditions before the diagnosis of urolithiasis is made. In those with symptomatic presentation, the most common symptom is pain. Gross hematuria occurred in 30-55% of pediatric cases.¹⁻³ Other potential manifestations include dysuria and urgency, and nausea/vomiting.

Several types of stones have been identified among pediatric populations. Based upon case series, the frequency of different stone composition in children is as follows- calcium oxalate (45-65%), calcium phosphate (14-30%), struvite (13%), cystine (5%), uric Acid (4%), mixed or miscellaneous (4%).²⁻⁴ These stones usually occur as a result of three factors: supersaturation of stone-forming compounds in urine, presence of chemical or physical stimuli in urine that promote stone formation, inadequate amount of compounds in urine that inhibits stone formation (e.g. magnesium, citrate). In two case series of children with stones approximately 90% had at least one metabolic risk factor.^{5,6} These stones may obstruct one of the three points of narrowing along the ureter which are pelvi-ureteric junction (PUJ), the crossing of the ureter over the area of the pelvic brim at the level of the iliac vessels, and the vesico-ureteric junction (VUJ). This may lead to subsequent accumulation of the urine along the urinary tract proximal to the obstruction resulting in dilatation of the ureter and subsequently the pelvicalyceal system of the kidneys. Untreated cases may then lead to urinary tract infection and in late stages chronic kidney failure.

Ultrasonography is the recommended primary imaging modality for suspected kidney or ureteral stone, as it is effective in detection of renal and ureteral stones while avoiding radiation.⁷ Ultrasonography can detect radiolucent stones, such as uric acid stones, and urinary

obstruction.⁸ However, it is limited in its ability to uncover small stones (eg. <5 mm), papillary or calyceal stones, or ureteral stones. Ultrasound is more sensitive than plain X-ray KUB (84% versus 54%) in detecting renal calculus. However, X-ray KUB is superior to diagnose ureteral stones.⁹ Experience and expertise of the sonologist is an important factor to detect small renal or ureteric calculus.

Conclusion:

As most cases of urolithiasis in pediatric population presents with a varied symptoms, prompt diagnosis with imaging has been an essential part of management of this condition. Ultrasound has a major role for diagnosing this condition and is preferred over CT scan due to its superior ability of detecting stones without exposing the pediatric population to unnecessary radiation which may have detrimental effects on them. Diagnosing urolithiasis on time can prevent potential complications in children.

References:

1. Gearhart JP, Herzberg GZ, Jeffs RD. Childhood urolithiasis: experiences and advances. *Pediatrics*. 1991 April;87(4):445-50.
2. Milliner DS, Murphy ME. Urolithiasis in pediatric patients. *Mayo Clin Proc*. 1993 Mar;68(3):241-48.
3. Coward RJ, Peters CJ, Duffy PG, Corry D, Kellett MJ, Choong S, van't Hoff WG. Epidemiology of paediatric renal stone disease in the UK. *Arch Dis Child*. 2003 Nov;88(11):962-65.
4. Stapleton FB, McKay CP, Noe HN. Urolithiasis in children: the role of hypercalciuria. *Pediatr Ann*. 1987 Dec;16(12):980-1,984-92.
5. Penido MG, Srivastava T, Alon US. Pediatric primary urolithiasis: 12-year experience at a Midwestern Children's Hospital. *J Urol*. 2013 Apr;189(4):1493-97.
6. Spivacow FR, Del Valle EE, Boailchuk JA, Sandoval Díaz G, Rodríguez Ugarte V, Arreaga Álvarez Z. Metabolic risk factors in children with kidney stone disease: an update. *Pediatr Nephrol*. 2020 Nov;35(11):2107-12.
7. Colleran GC, Callahan MJ, Paltiel HJ, Nelson CP, Cilento BG Jr, Baum MA, Chow JS. Imaging in the diagnosis of pediatric urolithiasis. *Pediatr Radiol*. 2017 Jan;47(1):5-16.
8. Smith SL, Somers JM, Broderick N, Halliday K. The role of the plain radiograph and renal tract ultrasound in the management of children with renal tract calculi. *Clin Radiol*. 2000 Sep;55(9):708-10.
9. Diamant MJ, Malekzadeh M. Ultrasound and the diagnosis of renal and ureteral calculi. *J Pediatr*. 1986 Dec;109(6):980-83.