

Ethylacetate Flavonoid Bio-compounds of Honey with Mitigating Anti-hyperlipidemic and Antioxidant Properties in Carbohydrate and Lipid Enriched Diets – Obese Rats

Abstract

Honey is a rich material source of medicinal nutrients. This study investigated the hypolipidemic and antioxidant effects of honey, 50% fresh lime juice, and 50% honey (MIX) and ethylacetate flavonoid-rich fraction of honey (EAFH) in carbohydrate and lipid-enriched diets-obese rats.

At phase 1, 54 male neonate Wistar albino rats were, divided into 3 groups of 18 rats. Groups 2 and 3 were fed a carbohydrate-enriched diet (CHD) and lipid-enriched diet (LP) for 14 days, and rats with Lee index ≥ 0.3 were considered obese. Rats (phase-2) were regrouped into 7 groups of 6 rats, and treated with honey, MIX, and EAFH. Flavonoids bio-compounds in EAFH characterized by HPLC (High-performance liquid chromatography) include; gallic acid, epigallocatechin, naphthoresorcinol, and quercetin. Lee's index after obesity induction was ≥ 0.3 . Adiposity index, diet intake, and body and organ weight of obese rats were significantly ($p < 0.05$) reduced after honey, MIX, and EAFH treatments compared to control. Significant ($p < 0.05$) decreased concentrations of glucose, leptin, insulin, low-density lipoprotein (LDL), total cholesterol (TC), triacylglycerol (TAG), very low-density lipoprotein (VLDL), 3-Hydroxy-3-methylglutaryl (HMG) coenzyme A (CoA) reductase activity (HMGCOARA), atherogenic risk index (ARI) and coronary risk index (CRI) and increase in high-density lipoprotein (HDL) after treatment with honey, MIX and EAFH was observed compared control and AOI. Antioxidant parameters of obese rats were significantly ($p < 0.05$) improved compared to control and AOI rats. Honey could serve as a model pharmacotherapy for treating dyslipidemia and oxidative stress linked to obesity.

Keywords: hypolipidemic, hyperlipidemic, flavonoids, obesity, hypoglycemic, hyperglycemia

1. INTRODUCTION

Several plants and herbs are known for their medicinal and pharmacotherapeutic benefits due to the large number of phytochemicals and phytonutrients they contain. Such benefits include; renal protection [1], antioxidant and anti-inflammatory functions [2], weight loss and anti-obesity benefits [3], hepatic and cardiovascular protection [4, 5] and anti-diabetic potential [6]. Flavonoids are bioactive phytochemical compounds, known to exert their pharmacological effects due to their antioxidant capacity [2]. The antioxidant ability of flavonoid compounds is demonstrated when they scavenge free radical molecules such as reactive oxygen species (ROS) and reactive nitrogen species (RNS) [2]. Free radicals are capable of preventing biochemical processes through enzyme inhibition. However, their elimination by flavonoids' antioxidant activity could confer protection on tissues and cells [2, 7]. Several health benefits are associated with flavonoids; Catechin inhibits plasma oxidation in humans[8] compared with other antioxidants [9]; gallic acid exerts anti-obesity effect and enhances learning in high-fat diet obese rats [3]; quercetin possessed anti-diabetic [10] and anti-obesity [11] effects in rats, epigallocatechin exhibited anti-obesity and cardiovascular protection on rats [12] and hypoglycemic, anti-inflammatory, hypolipidemic and anticancer properties of caffeic acid are reported [2]. These flavonoids were reported to be the most significant antioxidant compounds, coordinating antioxidant activity in Southern grape seeds [13]. The mechanism of flavonoids' anti-inflammatory activity is considered to be due to their free radical's direct scavenging ability, resulting in the protection of the cell and the prevention of cellular damage [14]. In carrying out

their direct scavenging function against peroxynitrite (ONOO•) or superoxide, they are easily oxidized by the attacking free radicals, to generate less reactive free radicals and stable flavonoid radicals. The reactivity of flavonoids against reactive nitrogen species (RNS) and reactive oxygen species (ROS) is enhanced by the presence of OH groups in their structure. Thus, the number of hydroxyl molecules in a flavonoid, improves the effectiveness of the flavonoid as antioxidant [15]. The underlying mechanism involving honey's ability to reduce blood glucose is associated with its inhibitory effect on α -glucosidase and α -amylase activities [16, 17]. The enzyme, α -glucosidase is responsible for the hydrolysis of oligosaccharides, disaccharides, and trisaccharides to monosaccharides end products and α -amylase converts complex sugars (starch) to oligosaccharides by hydrolysis [18].

Atherogenic hyperlipidemia results in high triacylglycerol (TAG) and apolipoprotein B (apo B) serum levels containing lipoproteins that include low-density lipoprotein (LDL) and very low-density lipoprotein (VLDL) and a significant low level of serum high-density lipoprotein (HDL) [19]. In obese individuals, superfluous visceral fat forms ectopic fat, dumped in the hepatic tissues, skeletal muscle, and heart, promoting lipolysis and insulin resistance [20]. This significantly permits the elevated flow of free fatty acid from the adipose tissue into hepatic tissue [19]. A mixture of lime juice and honey in cholesterol-enriched diet-fed rats showed Hypolipidemic and hypoglycemic effects [21], honey alone reduced cardiovascular and coronary risk indexes in diabetic rats [16], reduced concentrations of TAG, TC and glucose in high-fat diet-induced obese rats [22]. The hormone leptin is a protein that majorly partakes in food intake regulation, by controlling appetite. Leptin consists of 167 amino acids and is secreted by cells of the adipose tissue. Leptin controls appetite by sending signals to the hypothalamus, which then stimulates a reduced desire for food [23]. The ineffectiveness of leptin hormone has been reported as leptin resistance in diet-induced obesity even when leptin concentration is increased. Meanwhile, it is reported that diet-induced leptin resistance can be corrected with a change in dietary pattern, which could also serve as a measure of correction for insulin resistance. Leptin concentration may rise due to non-sensitization of leptin signal through elevated insulin concentration in a high-energy diet [24, 25]. In obesity, unhealthy expansion of adipocytes results in inflammation and subsequent recruitment of TNF- α (tumor necrotic factor – alpha), which restrains signal transduction for insulin sensitivity, inducing insulin resistance [25]. This study investigated the anti-hyperlipidemic and antioxidant functions of honey, 50% fresh lime juice, and 50% honey (MIX) and ethylacetate flavonoid-rich fraction of honey (EAFH) in carbohydrate and lipid-enriched diets-obese rats.

2. MATERIALS AND METHODS

2.1 Collection of Citrus Fruit

Fresh lime fruits were harvested from an orchard in Imezi-Owa in Ezeagu Local Government Area in Enugu state, Nigeria. Lime fruits were identified and authenticated by Mr. Onyeukwu John Chijioke in the Department of Plant Sciences, University of Nigeria Nsukka, Enugu state, with a voucher (authentication) number of the University of Nigeria Herbarium (UNH number) 622a.

2.3 Collection of Honey

Freshly harvested honey was collected with the comb from divine favor Bee-keeping and honey production farm, Ezikolo Abbi, Uzo-Uwani Local Government Area of Enugu state, Nigeria.

2.4 Animals

This study made use of fifty-four (54) male neonate albino Wistar rats (weighing 23 g on average), immediately weaned after twenty-five (25) days old. Neonates could serve as a model of early induction of obesity and in order to have accurate and pure responses, male rats were chosen to eliminate problems of hormonal imbalances in females. Rats were obtained from the University of Nigeria, Department of Zoology and Environmental Studies, and housed in well-ventilated colony cages at an ambient temperature and relative humidity were allowed to acclimatize for one week prior to the experiment and given standardized palletized feed and clean water within the period of acclimatization.

2.5 Equipment and Instruments

The following are the equipment used: Spectrophotometer, UV-Vis (752N, Lemfield Medical England), Electro-thermostatic water cabinet (Model DK-8A, Shanghai Yuejin Medical Instrument Factory), Weighing balance (DHaus) Laboratory dry oven (Model-9101, Sanfa), Centrifuge (Hospibrand USA), Digital Photo Colorimeter (Erma Inc.), Refrigerator (haier thermocool), Counting chamber (MC Quijing, China), Separating funnel, Milling machine, Microscope, Micro-pipette (Perfect, USA), Microscope slides, Capillary tube, Test tube, Graduated cylinder, One touch glucometer (Lifescan, USA), Test strips (Pyrex, England), Beakers (Pyrex, England) and rotary evaporator (Steroglass, Strike 202, Padua, Italy).

2.6 Chemicals and Reagents

All chemicals and reagents used in this study were of analytical grade and products of Sigma Aldrich, USA, British Drug House (BDH) England, Burgoyne, Clinical Lancet Laboratory, India, Harkin and Williams, England, Qualikems India, Fluka Germany, May and Baker England. Reagents used for the assays were commercial kits and products of Randox, USA, and Teco (TC), USA.

2.7 Solvent Extraction of Flavonoid Rich Fraction of Honey

This was carried out according to the method of Soria *et al.* [26]. Briefly, into a 2000 ml separating funnel was 200 g of honey sample transferred. The honey was then diluted with 100 ml distilled water and was extracted with 200 ml of chloroform each. Two layers were formed: the upper chloroform layer and the lower aqueous layer after the mixture settled. Into a separating funnel was the aqueous layer retransferred and n-hexane (200 ml) was added and mixed thoroughly. Three layers were formed after the mixture was left to stand for 1 hour, giving rise to the n-hexane layer with bubbles, the n-hexane dark brown layer, and the n-hexane orange-colored layer respectively. A qualitative phytochemical test was done on all layers and the second layer (n-hexane dark brown layer) was found to be richest in flavonoid. The second layer was then transferred into the separating funnel and after separation, ethylacetate and water in the ratio of 1: 1 were added and mixed thoroughly and allowed to settle for 1 hour. Two layers were formed: an upper layer with viscous bubbles and a lower layer of yellowish liquid solution. The lower layer was collected and concentrated in a hot water bath at 40⁰C. Qualitative phytochemical test of the concentrated fraction confirmed flavonoid to be very high, and terpenoid and glycoside, to be slightly present. Using the separating funnel, the concentrated fraction was mixed with ethylacetate and water in the ratio of 1.7:0.3 for the final extraction of flavonoid fraction, and this was tagged as the ethylacetate flavonoids rich fraction of honey (EAFH) used in this research.

2.8 High-Performance Liquid Chromatography (HPLC)

A high-performance liquid chromatography Diode array (DA) detector was used to analyze the amount and types of flavonoids in the ethylacetate flavonoid-rich fraction of honey (EAFH) using an N200 chromatography software [27]. HPLC was performed on Agilent LC-8518 with a

low-pressure gradient and solvent delivery LC-8518 pump with a high-pressure switching valve, a high-sensitivity LC-8518 Diode array (DA) detector, with a micro syringe for sample injection. The column size is 150 x 4.6 mm, sample volume used was 40 μ L. The system made use of an acetonitrile/Water/Formic acid 25:74:1 mixture as a mobile phase, with a maximum Wavelength of 254 nm, column temperature of 40⁰C, and a run time of 25 minutes.

2.9 Animal Handling

The principles of laboratory animal care and ethical guidelines for investigation of experimental pain in conscious animals as prescribed by [28, 29] were followed.

2.10 Induction of Obesity and Adiposity Index Determination

On day 32, the study commenced, and the body weight of rats on days 25 (arrival day), 32, 34, 36, 38, 40, and 42 were calculated. Induction of obesity was achieved by feeding groups 2 and 3 with a carbohydrate-enriched diet (CHD) and lipid-enriched diet (LP) respectively for two weeks. After induction of obesity, body weight and length of rats were measured and used for the determination of Lee indices by the method of Nakagawa et al. [30], using the formula;

$$\text{Lee indices of animal} = \frac{\sqrt[3]{\text{Body weight (g)}}}{\text{Nose to Anus Length (CM)}}$$

A rat with a Lee index ≥ 0.3 was considered obese.

Rat body weight was measured using a weighing balance while a standard measuring tape was used to measure their nasal to anal length (cm).

The adiposity index was determined by the total weight of epididymal, visceral, and retroperitoneal fat divided by body weight $\times 100$ and expressed as adiposity percentage (% AI). Blood samples and tissues were collected for analysis before treatment with honey, MIX, and EAFH.

2.11 Ethical Issues

The Ethical Committee for Conduction of Animal Studies at the Faculty of Biological Sciences, University of Nigeria Nsukka with the reference number: UNN/FBS/EC/1051 approved the experimental protocol and all animals were cared for in accordance with the principles and guidelines of the committee.

2.12 Experimental Design

The experimental design was carried out in two phases. Fifty-four male neonates Wistar albino rats were used in this study, divided into three groups of 18 rats each at phase I (induction of obesity) and regrouped into 7 groups of 6 rats each at phase II (treatment with honey, MIX, and EAFH). At the end of Phase I, two rats were picked at random, and after Phase II, the remaining rats were sacrificed and blood samples and organs were collected for biochemical analysis.

2.13 Animal Grouping

The route of administration of extracts was via oral route with the aid of an oral intubation tube. The groups and doses administered are summarized below;

Phase I

Group 1: Normal control, consisting of 18 rats, fed a normal diet.

Group 2: Consist of 18 rats, fed a carbohydrate-enriched diet

Group 3: Consists of 18 rats, fed lipid enriched diet.

At the end of phase I, two rats were picked at random and sacrificed, and blood samples and organs were collected for biochemical analysis.

Phase II

At phase II (treatment with honey, MIX, and EAFH), rats were regrouped into 7 groups of 6 rats each as follows;

Group 1: Control, fed normal feed + clean water.

Group 2: Carbohydrate-enriched diet obese rats¹ + 250 mg/kg oral administration of honey

Group 3: Carbohydrate-enriched diet obese rats² + 250 mg/kg oral administration of 50% FLJ and 50% honey mixture (MIX)

Group 4: Carbohydrate-enriched diet obese rats³ + 200 mg/kg oral administration of ethylacetate flavonoid-rich fraction of honey (EAFH)

Group 5: Lipid-enriched diet-obese rats¹ + 250 mg/kg oral administration of honey

Group 6: Lipid-enriched diet-obese rats² + 250 mg/kg oral administration of 50% FLJ and 50% honey mixture (MIX)

Group 7: Lipid-enriched diet-obese rats³ + 200 mg/kg oral administration of ethylacetate flavonoid-rich fraction of honey (EAFH)

2.14 Blood and Tissue collection

Blood was collected into plain and EDTA tubes by cardiac puncture under light chloroform anesthesia after an overnight fast. The serum was separated by a retro fraction. The plasma was separated from the erythrocytes by centrifuging the whole blood at 5000 rpm for 10 minutes. The liver organ and adipose tissue were excised, rinsed with normal saline, blotted dry, and weighed immediately. All samples were stored at -20°C until analyzed.

2.15 Composition of diet in g/1000 g

A diet mixture for Carbohydrate enriched diet and lipid enriched diet was formulated according to the method of Rotimi *et al.* [31], with a little modification.

Carbohydrate-rich diet mix contains the following in g/1000 g: Starter feed 136, sweet potatoes 128, processed cassava 147, maize 200, and yam 389.

Lipid enriched diet mix contains the following in g/1000 g: Starter feed 300, chicken's skin 84, pork's skin 161, margarine 85, and Egg yoke 370.

2.16 Histopathological Examination of Adipose Tissue

A thorough observation was done on the adipose tissue harvested. This was observed for signs of abnormality and for the presence of lesions [22]. Then, organs were carefully washed in 10% formaldehyde solution, blotted dry, and weighed. The relative organ weight (ROW) was calculated for each organ using the equation:

$ROW = \text{absolute organ weight (g)} \times 100 / \text{body weight of rat on sacrifice day (g)}$.

After weighing, 10% buffered formalin was used to preserve organs for later histopathological examination. The tissue was embedded in paraffin, and then sectioned; the sections were cut at 4-5 microns with the rotary microtome, stained with hematoxylin and examined microscopically [32].

3. RESULTS

3.1 Percentage Yield of ethylacetate flavonoid rich fraction of honey (EAFH)

Table 1 shows the percentage yield of an ethylacetate flavonoid-rich fraction of honey (EAFH). Two hundred grams (200 g) of treated honey was extracted with 100% ethylacetate. After extraction, the percentage yield was calculated and shown in Table 1.

3.2 HPLC analysis of ethylacetate flavonoid rich fraction of honey (EAFH)

In Table 2, the HPLC analysis of the ethylacetate flavonoid-rich fraction of honey (EAFH) result revealed the presence of four different flavonoid compounds. These include gallic acid, epigallocatechin, naphthoresorcinol and quercetin. Epigallocatechin had the highest peak area, with a concentration of 73.45 mg/100g, followed by gallic acid with a concentration of 23.98 mg/100g.

3.3 The chromatogram profile of the HPLC result of ethylacetate flavonoid rich fraction of honey (EAFH)

Figure 1 shows the chromatogram profile of the HPLC result of the ethylacetate flavonoid-rich fraction of honey (EAFH). The molecules with the highest peak are epigallocatechin and gallic acid, with concentrations of 73.45 mg/100g and 23.98 mg/100g respectively.

Table 1: Percentage yield of ethylacetate flavonoid rich fraction of honey (EAFH)

Sample	Weight of Sample (g)	Weight of Extract (g)	Percentage Yield (%)
EAFH	200	181	90.47

Key: **EAFH**: ethylacetate flavonoid rich fraction of honey.

Table 2: HPLC – analyzed flavonoid compounds in ethylacetate flavonoid-rich fraction of honey (EAFH).

Peak No	Peak ID	Ret Time	Height	Area	Conc (mg/100g)
1	Gallic acid	1.007	58989.625	1227905.375	23.9781
2	Epigallocatechin	1.873	84653.148	3761383.750	73.4511
3	Naphthoresorcinol	7.615	761.316	24346.453	0.4754
4	Quercetin	6.032	2468.652	107303.359	2.0954

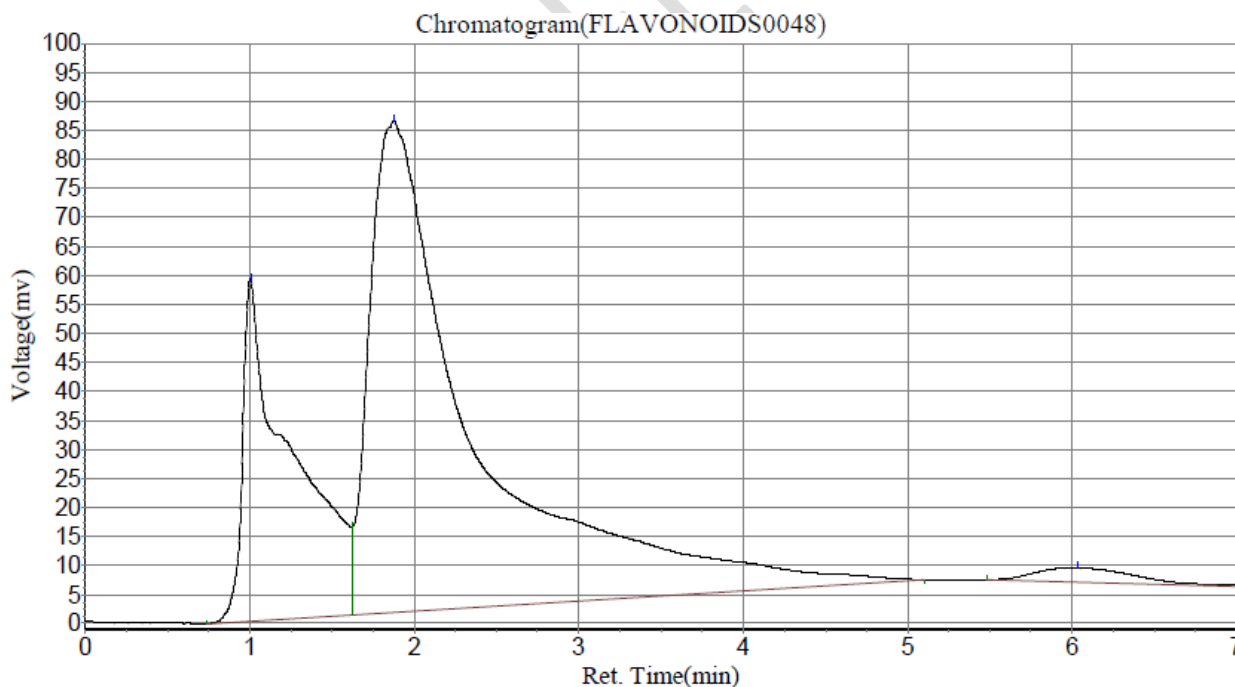


Figure 1: Result of chromatogram profile of ethylacetate flavonoid rich fraction of honey (EAFH) in HPLC analysis.

3.4 Body Weight, Feed Intake, Lee Indices, Adiposity Indices and Weight of Rats' Organs

Figure 2 shows the body weight of rats both after obesity induction (AOI) and treatment with honey, MIX, and EAFH fractions of CHD – obese treated rats and LP-enriched diet – obese treated rats. In both CHD – obese treated rats and LP – obese treated rats, the effects of honey, MIX, and EAFH treatments on the body weight of rats revealed that there was significant ($p < 0.05$) difference when each treatment group was compared with control and AOI. The body weight of rats was significantly ($p < 0.05$) reduced (especially on day 11) when each treatment group was compared with either the control group or the AOI group. Figure 3 shows the weight gain after treatment with honey, MIX, and EAFH; Table 3 shows the Lee indices of rats before and after obesity was induced, adiposity indices (AI%), weight of organs (liver, kidney, and heart), and diet intake (in gram) after obesity was induced.

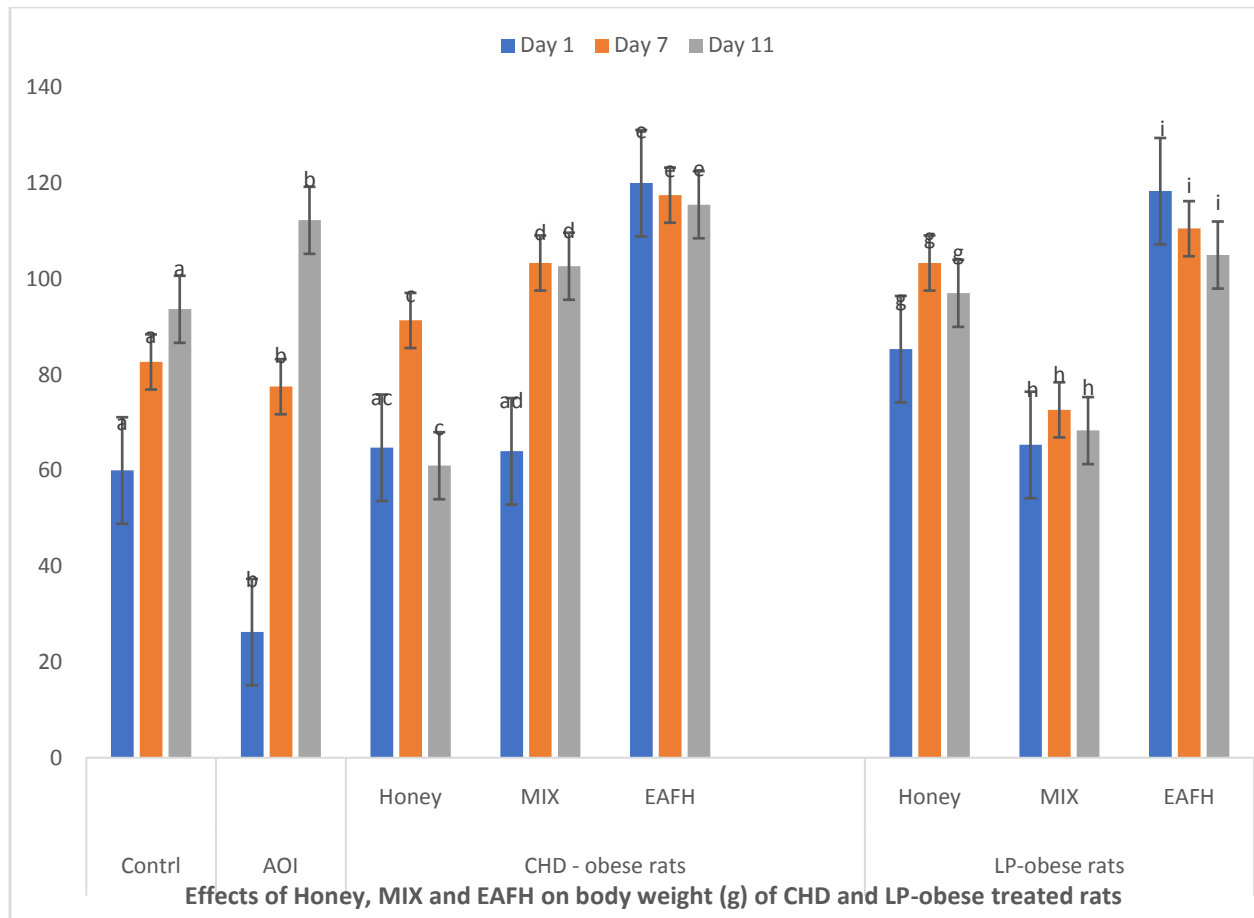
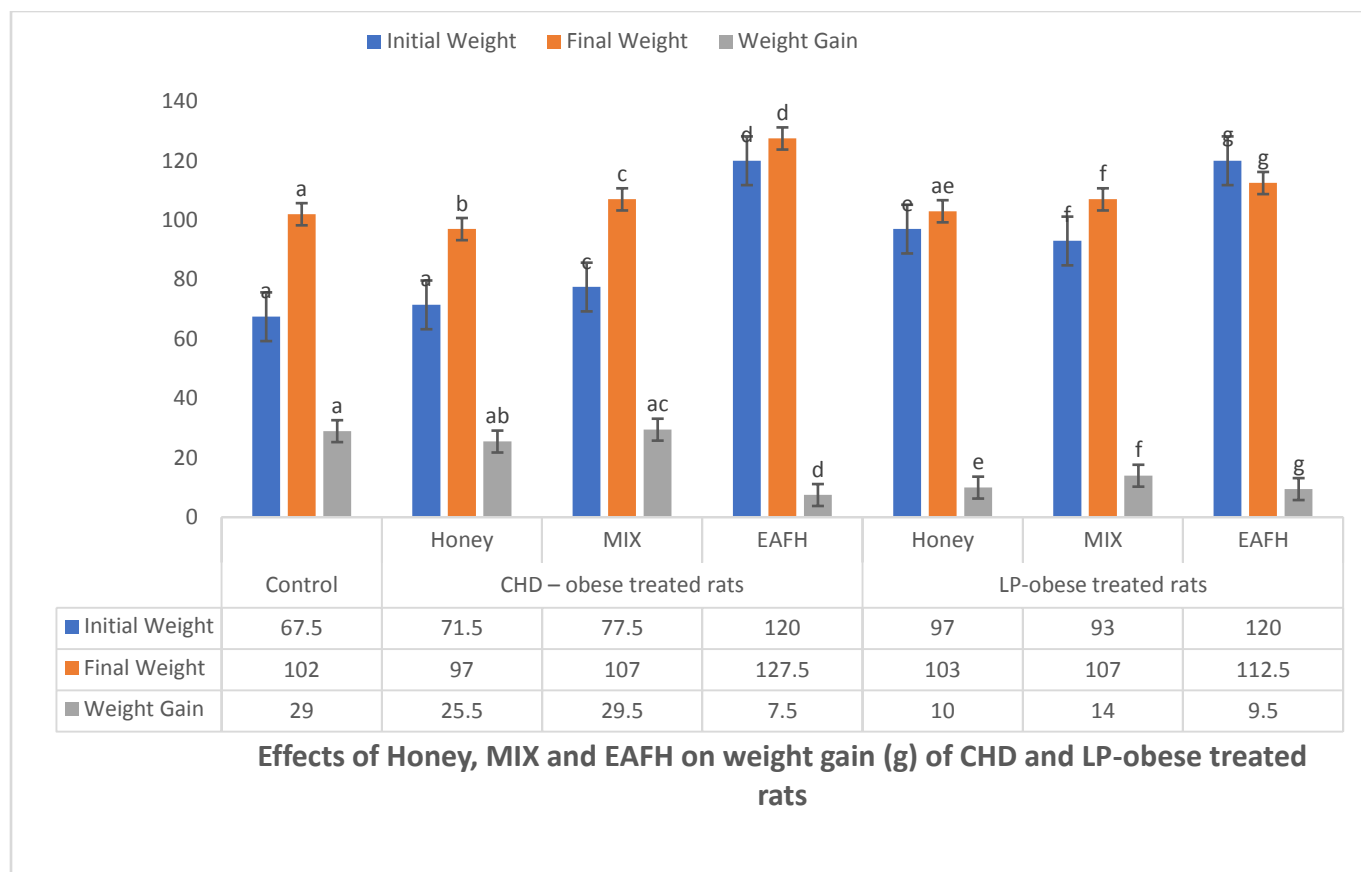


Figure 2: Effects of honey, MIX and EAFH on body weight (g) of CHD – obese treated rats and LP enriched diet treated rats for two weeks

Results are Mean \pm SEM; Comparing normal control with AOI group, CHD-obese treated rats and LP-obese treated rats, treated honey, MIX, and EAFH at the level of significant ($p < 0.05$), Bars with different alphabets comparing control and a group are significantly ($p < 0.05$) different and ($n=6$). Key: AOI: After obesity induction; CHD-obese rats: Carbohydrate obese rats group 2; LP-obese rats: Lipid enriched diet obese rats group 3; MIX: 50% fresh lime juice and 50% honey EAFH: Ethylacetate Flavonoid-rich fraction of Honey.



Effects of Honey, MIX and EAFH on weight gain (g) of CHD and LP-obese treated rats

Figure 3: Effects of Honey, MIX and EAFH on weight gain of CHD – obese treated rats and LP enriched diets obese treated rats

*Weight gain is the difference between the weight at the beginning of the treatment and the weight at the end of the treatment (two weeks). Results are Mean \pm SEM; Comparing normal control with AOI group, CHD-obese treated rats and LP- obese treated rats, treated honey, MIX and EAFH at level of significant ($p < 0.05$), Bars with different alphabets comparing control and a group are significantly ($p < 0.05$) different and ($n=6$). Key: AOI: After obesity induction; CHD-obese rats: Carbohydrate obese rats group 2; LP-obese rats: Lipid enriched diet obese rats group 3; MIX: 50% fresh lime juice and 50% honey EAFH: Ethylacetate Flavonoid-rich fraction of Honey.

Table 3: Lee index before (LIB) and Lee index after (LIA) Obesity induction, weight (g) of Rat's Organ, and diet intake after Induction of Obesity (AOI)

	LIB	LIA	Liver ^A	Adipose Tissue ^A	Kidney ^A	Heart ^A	Diet intake
Control	0.25 \pm 0.035 ^a	0.28 \pm 0.01 ^a	2.85 \pm 0.78 ^a	1.30 \pm 1.13 ^a	1.35 \pm 0.21 ^a	0.42 \pm 0.15 ^a	46.07 \pm 9.04 ^a
Group 2	0.25 \pm 0.01 ^a	0.47 \pm 0.02 ^b	6.03 \pm 0.66 ^c	2.90 \pm 0.84 ^a	1.57 \pm 0.01 ^a	0.85 \pm 0.09 ^g	216.07 \pm 15.49 ^f
Group 3	0.26 \pm 0.01 ^a	0.51 \pm 0.00 ^c	9.97 \pm 0.53 ^d	5.93 \pm 0.58 ^d	2.63 \pm 0.02 ^e	1.25 \pm 0.42 ^f	184.00 \pm 13.39 ^h

Results are Mean \pm SEM; Comparing normal control with Group 2 and Group 3; $n = 14$. Values within the same column with different alphabets are significantly ($p < 0.05$) different from each other.

A: Values expressed in organ weight/100 g Body Weight

Group 2: Carbohydrate enriched diet obese rats; Group 3: Lipid enriched diet obese rats.

3.5 Serum and Tissue Lipid Profile

Figures 4 - 7 revealed the effects of honey, MIX, and EAFH on serum and tissue lipid profile. In both CHD – obese treated rats and LP – obese treated rats, there was significant ($p < 0.05$) difference in serum and tissue lipid profile when a treated group was compared with control group or with AOI group. Generally, treatment of obese rats with honey, MIX and EAFH significantly ($p < 0.05$) reduced the concentrations of serum and tissue TC, LDL, VLDL and TAG and significantly ($p < 0.05$) increased HDL concentration when compared to control and AOI rats.

UNDER PEER REVIEW

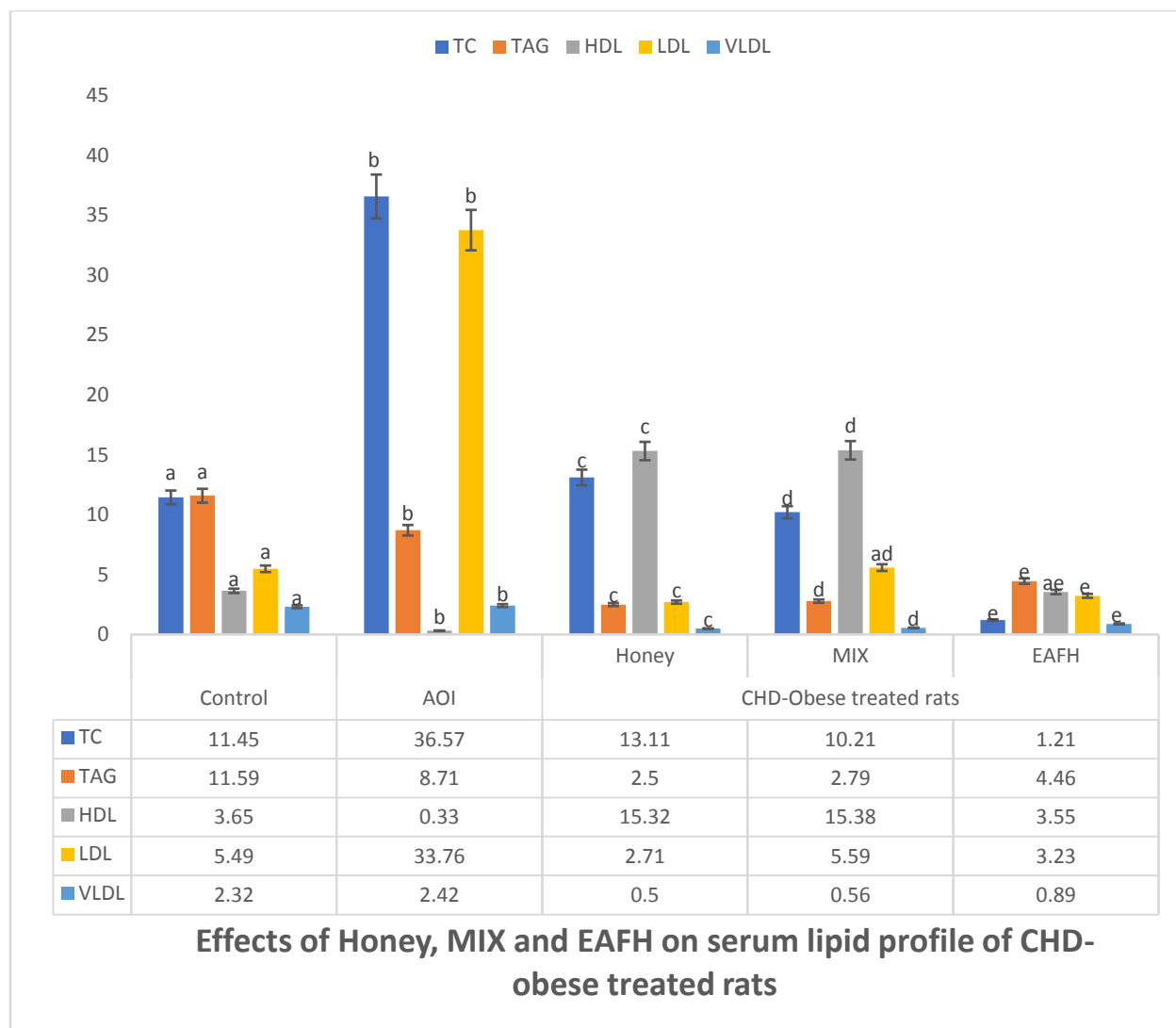
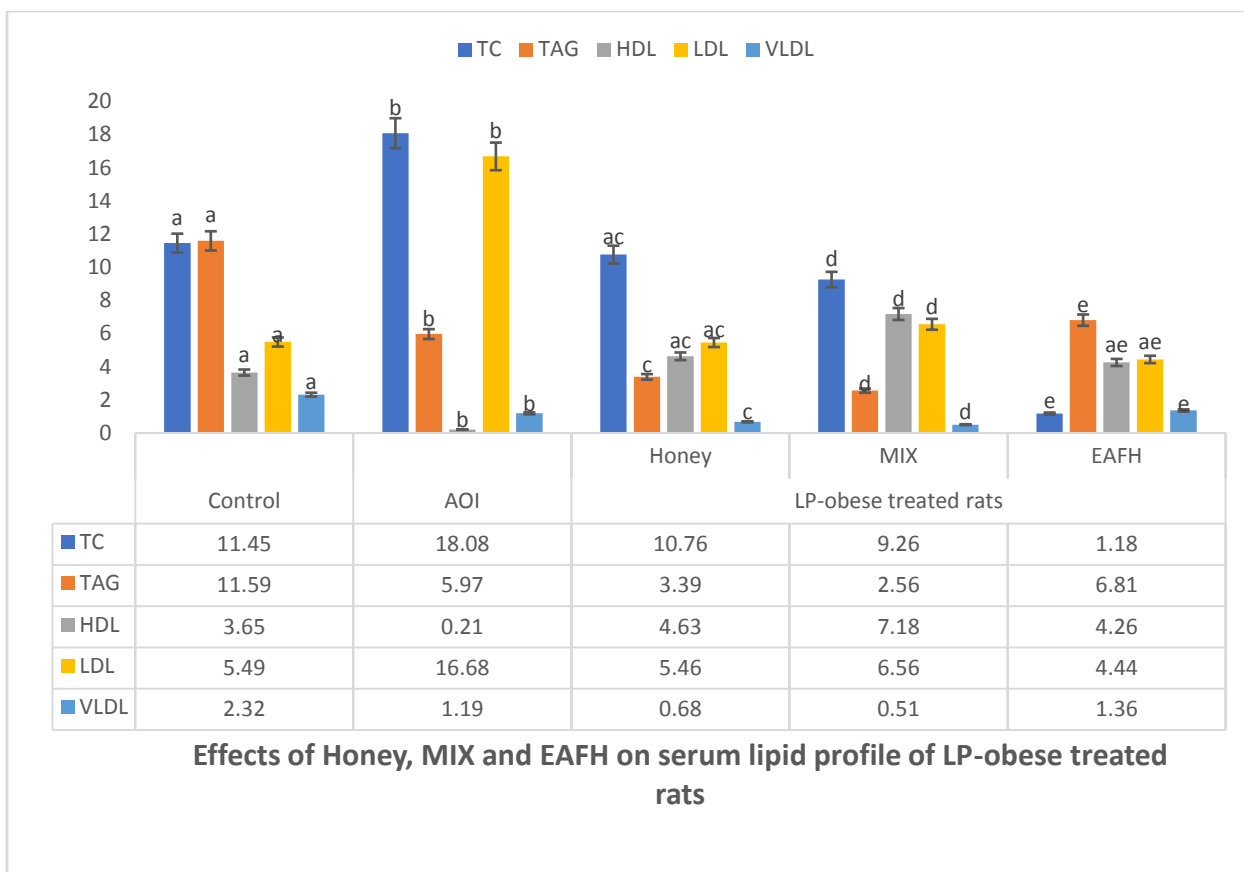


Figure 4: Effects of honey, MIX and EAFH on serum lipid profile of CHD – obese treated rats

Results are Mean \pm SEM; Comparing normal control with AOI group, CHD-obese treated rats, treated honey, MIX, and EAFH at the level of significance ($p < 0.05$), Bars with different alphabets comparing control and a group are significant ($p < 0.05$) different and ($n=6$). Key: AOI: After obesity induction; CHD-obese rats: Carbohydrate obese rats group 2; MIX: 50% fresh lime juice and 50% honey EAFH: Ethylacetate Flavonoid-rich fraction of Honey.



Effects of Honey, MIX and EAFH on serum lipid profile of LP-obese treated rats

Figure 5: Effects of honey, MIX and EAFH on serum lipid profile of LP – obese treated rats

Results are Mean ± SEM; Comparing normal control with AOI group, LP-obese treated rats, treated honey, MIX, and EAFH at the level of significance ($p < 0.05$), Bars with different alphabets comparing control and a group are significantly ($p < 0.05$) different and ($n=6$). Key: AOI: After obesity induction; LP-obese rats: Lipid enriched diet obese rats group 3; MIX: 50% fresh lime juice and 50% honey EAFH: Ethylacetate Flavonoid-rich fraction of Honey.

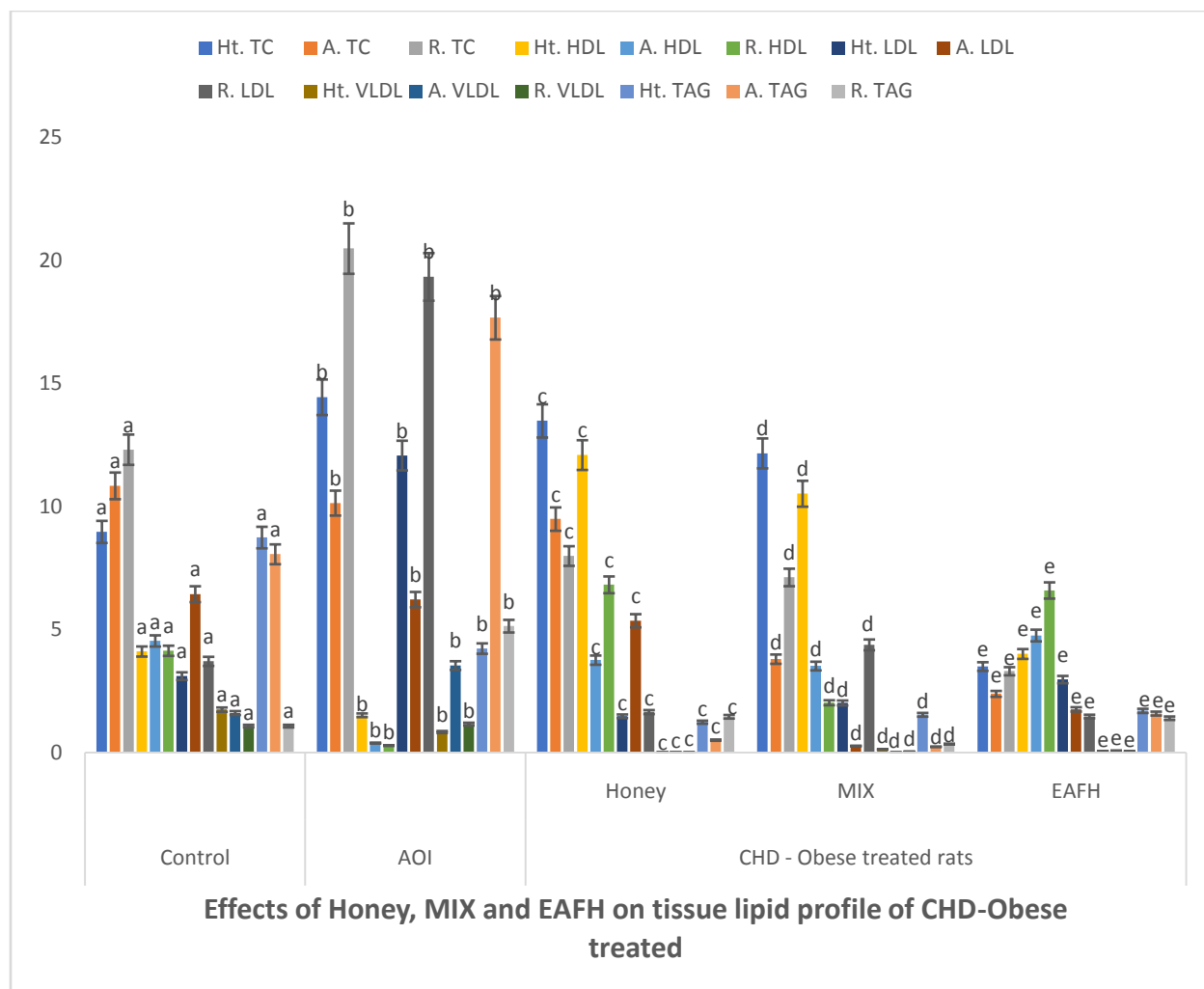


Figure 6: Effects of honey, MIX and EAFH on tissue lipid profile of CHD – obese treated rats

Results are Mean \pm SEM; Comparing normal control with AOI group, CHD-obese treated rats, treated honey, MIX, and EAFH at the level of significance ($p < 0.05$), Bars with different alphabets comparing control and a group are significantly ($p < 0.05$) different and ($n=6$). Key: AOI: After obesity induction; CHD-obese rats: Carbohydrate obese rats group 2; MIX: 50% fresh lime juice and 50% honey EAFH: Ethylacetate Flavonoid-rich fraction of Honey.

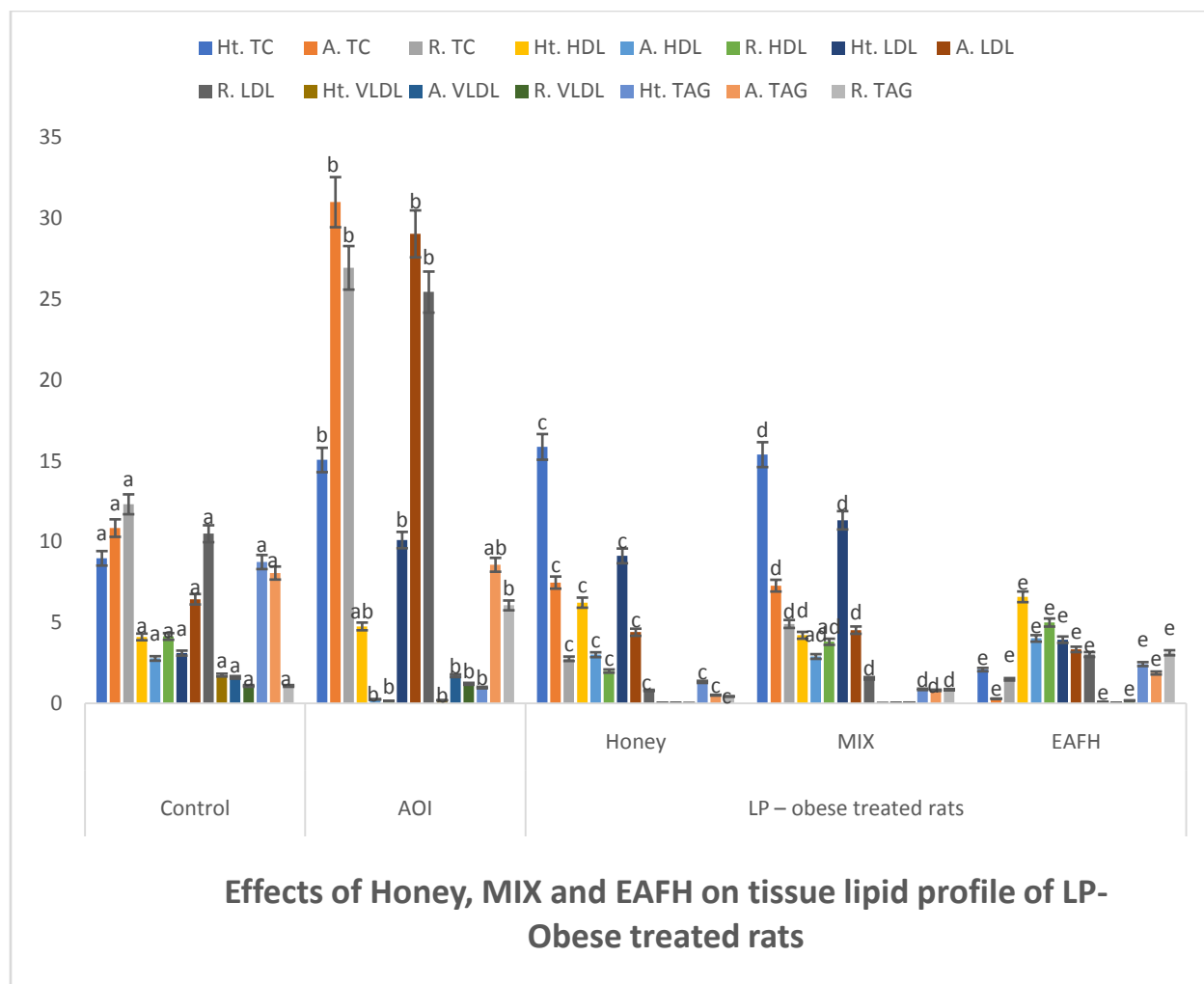


Figure 7: Effects of honey, MIX, and EAFH on tissue lipid profile of LP–obese treated rats
 Results are Mean \pm SEM; Comparing normal control with AOI group, LP-obese treated rats, treated honey, MIX, and EAFH at the level of significance ($p < 0.05$), Bars with different alphabets comparing control and a group are significantly ($p < 0.05$) different and ($n=6$). Key: AOI: After obesity induction; LP-obese rats: Lipid enriched diet obese rats group 3; MIX: 50% fresh lime juice and 50% honey EAFH: Ethylacetate Flavonoid-rich fraction of Honey.

3.6 Determination of Leptin, Insulin, and Blood Glucose

In both, CHD and LP – obese treated rats (Figures 8 and 9), the elevated concentrations of leptin, insulin, and glucose in obese rats were significantly ($p < 0.05$) reduced after treatment with honey, MIX, and EAFH. When compared with control and AOI rats, treatment with MIX and EAFH in CHD-obese treated rats and LP-obese treated rats significantly ($p < 0.05$) reduced leptin concentration.

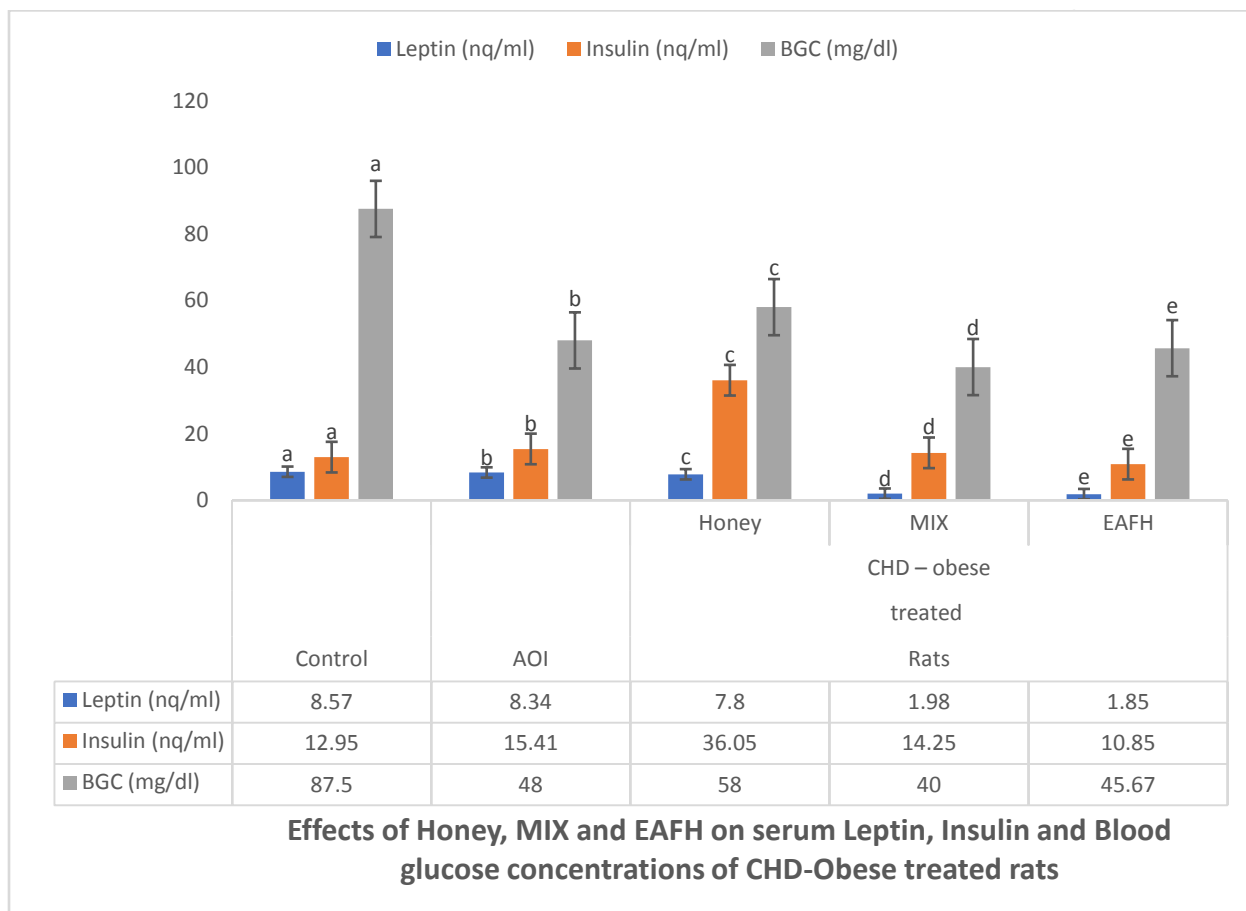


Figure 8: Effects of honey, MIX, and EAFH on serum Leptin, Insulin, and blood glucose concentrations of CHD – obese treated rats

Results are Mean \pm SEM; Comparing normal control with AOI group, CHD-obese treated rats, treated honey, MIX, and EAFH at the level of significance ($p < 0.05$), Bars with different alphabets comparing control and a group are significantly ($p < 0.05$) different and ($n=6$). Key: AOI: After obesity induction; CHD-obese rats: Carbohydrate obese rats group 2; MIX: 50% fresh lime juice and 50% honey EAFH: Ethylacetate Flavonoid-rich fraction of Honey BGC: Blood glucose concentration.

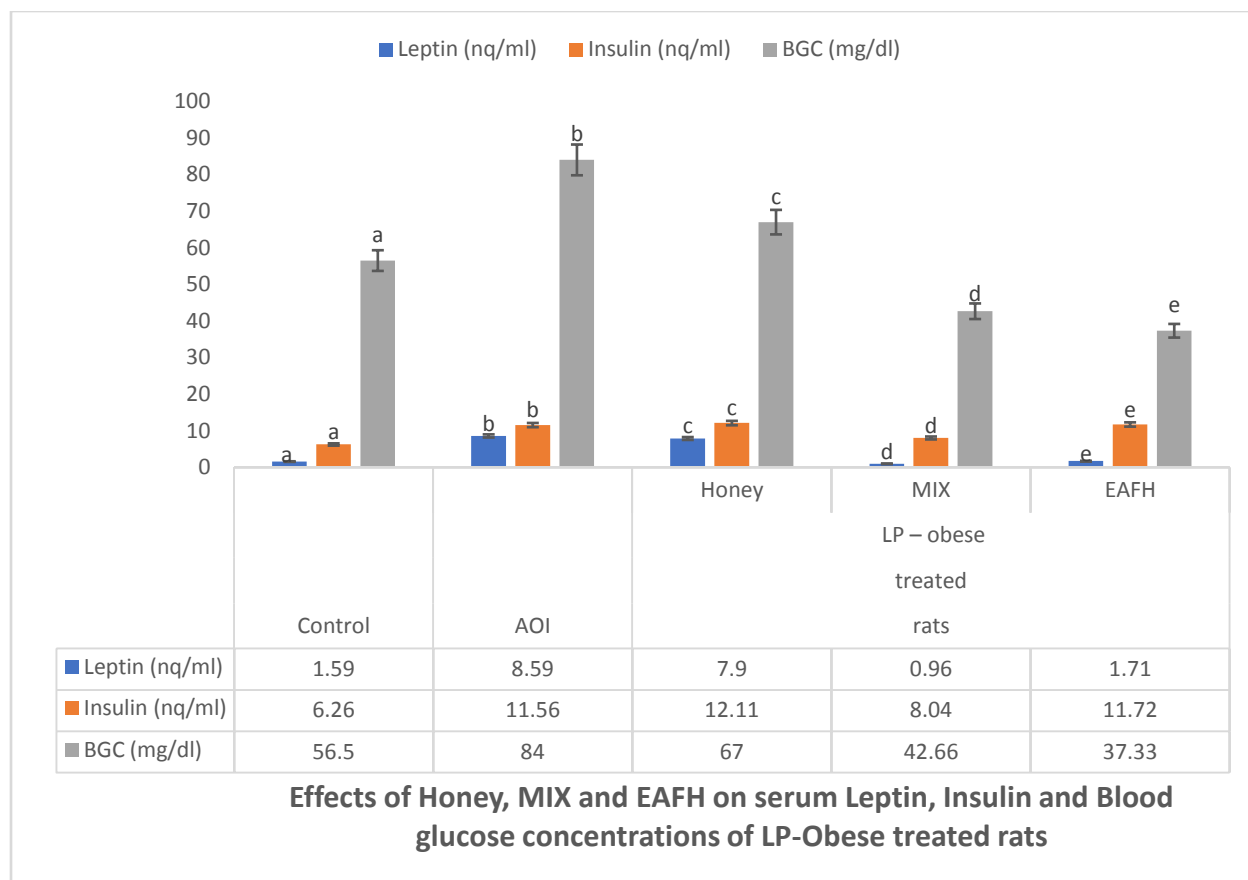


Figure 9: Effects of honey, MIX, and EAFH on serum Leptin, Insulin, and blood glucose concentrations of LP – obese treated rats

Results are Mean \pm SEM; Comparing normal control with AOI group, LP-obese treated rats, treated honey, MIX, and EAFH at the level of significance ($p < 0.05$), Bars with different alphabets comparing control and a group are significantly ($p < 0.05$) different and ($n=6$). Key: AOI: After obesity induction; LP-obese rats: Lipid enriched diet obese rats group 3; MIX: 50% fresh lime juice and 50% honey EAFH: Ethylacetate Flavonoid-rich fraction of Honey BGC: Blood glucose concentration.

3.7 3-Hydroxy-3-methylglutaryl (HMG) coenzyme A (CoA) reductase activity, Atherogenic Risk Index (ARI) and Coronary Risk Index (CRI)

Figure 10 represents the effects of honey, MIX, and EAFH treatments on HMGCR activity, ARI, and CRI in CHD- obese treated rats and LP- obese treated rats. In both CHD – obese treated rats and LP – obese treated rats, HMGCR activity, ARI, and CRI concentrations were significantly ($p < 0.05$) decreased than those of control and AOI groups, after treatment with honey, MIX, and EAFH, with EAFH having the most significant ($p < 0.05$) decreasing effect.

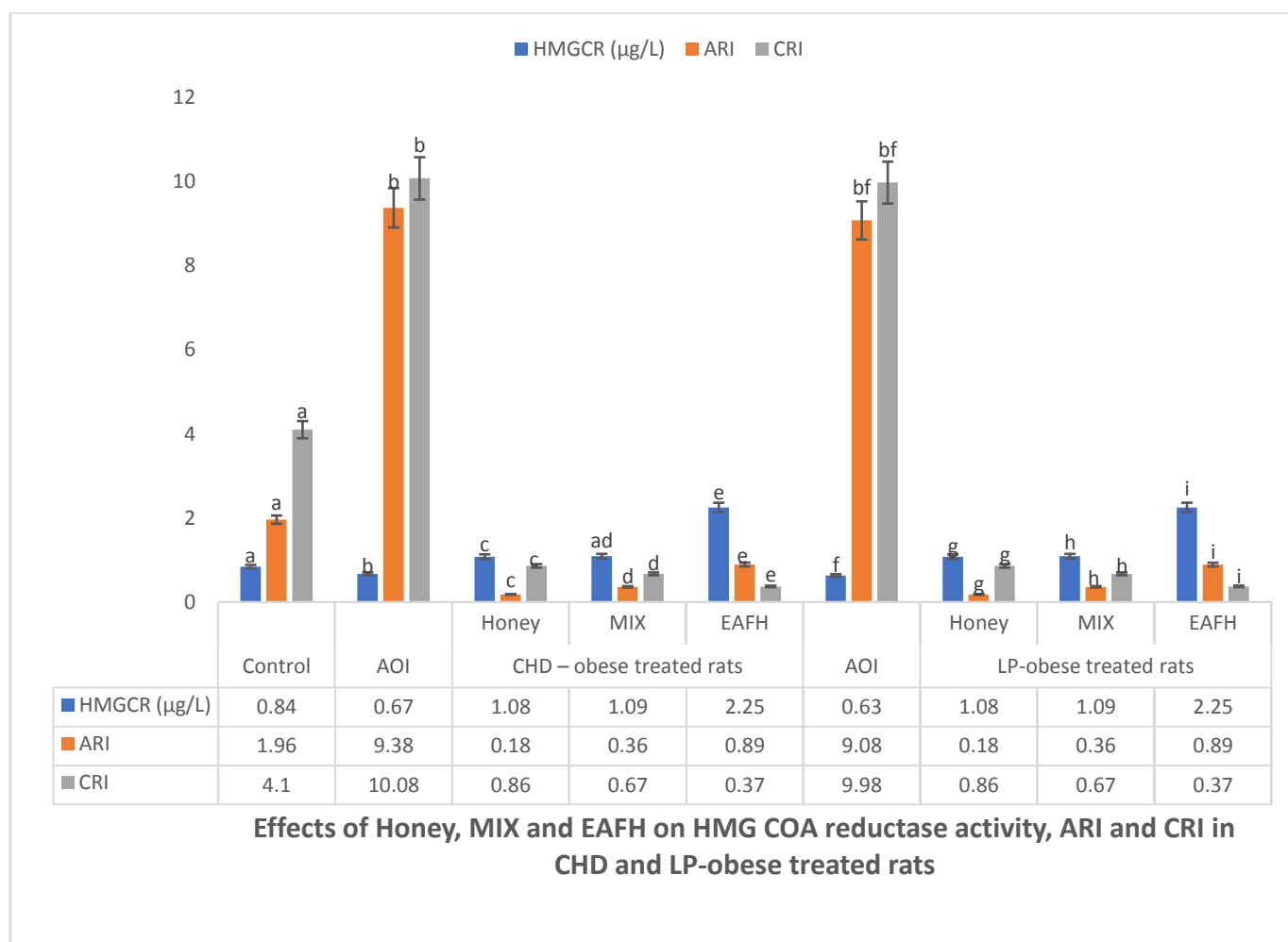


Figure 10: Effects of honey, MIX, and EAFH on HMG COA reductase activity, atherogenic risk index, and coronary risk index of CHD and LP enriched diets obese treated rats

Results are Mean ± SEM; Comparing normal control with AOI group, CHD-obese treated rats and LP-obese treated rats, treated honey, MIX, and EAFH at the level of significant ($p < 0.05$), Bars with different alphabets comparing control and a group are significantly ($p < 0.05$) different and ($n=6$). Key: AOI: After obesity induction; CHD-obese rats: Carbohydrate obese rats group 2; LP-obese rats: Lipid enriched diet obese rats group 3; MIX: 50% fresh lime juice and 50% honey EAFH: Ethylacetate Flavonoid-rich fraction of Honey; HMGCR: 3-Hydroxy-3-methylglutaryl coenzyme A reductase; ARI: atherogenic Risk Index; CRI: Coronary Risk Index.

3.8 Antioxidant Enzymes Assay, Malondialdehyde, and Vitamins C and E

The treatment of CHD – obese rats and LP–obese rats with honey, MIX, and EAFH (Figures 11 and 12) significantly ($p < 0.05$) increased the concentrations of GSH, vitamins C and E, and activities of GPx and SOD. In CHD – obese treated rats and LP-obese-treated rats, the activity of

GST was significantly ($p < 0.05$) reduced in MIX and EAFH but significantly ($p < 0.05$) increased in honey-treated rats when compared with the control group and AOI group. In both CHD – obese treated rats and LP – obese treated rats, catalase activity was significantly ($p < 0.05$) increased in rats treated with honey, EAFH, and MIX when compared with either the control group or AOI group. While the concentration of MDA was significantly ($p < 0.05$) reduced.

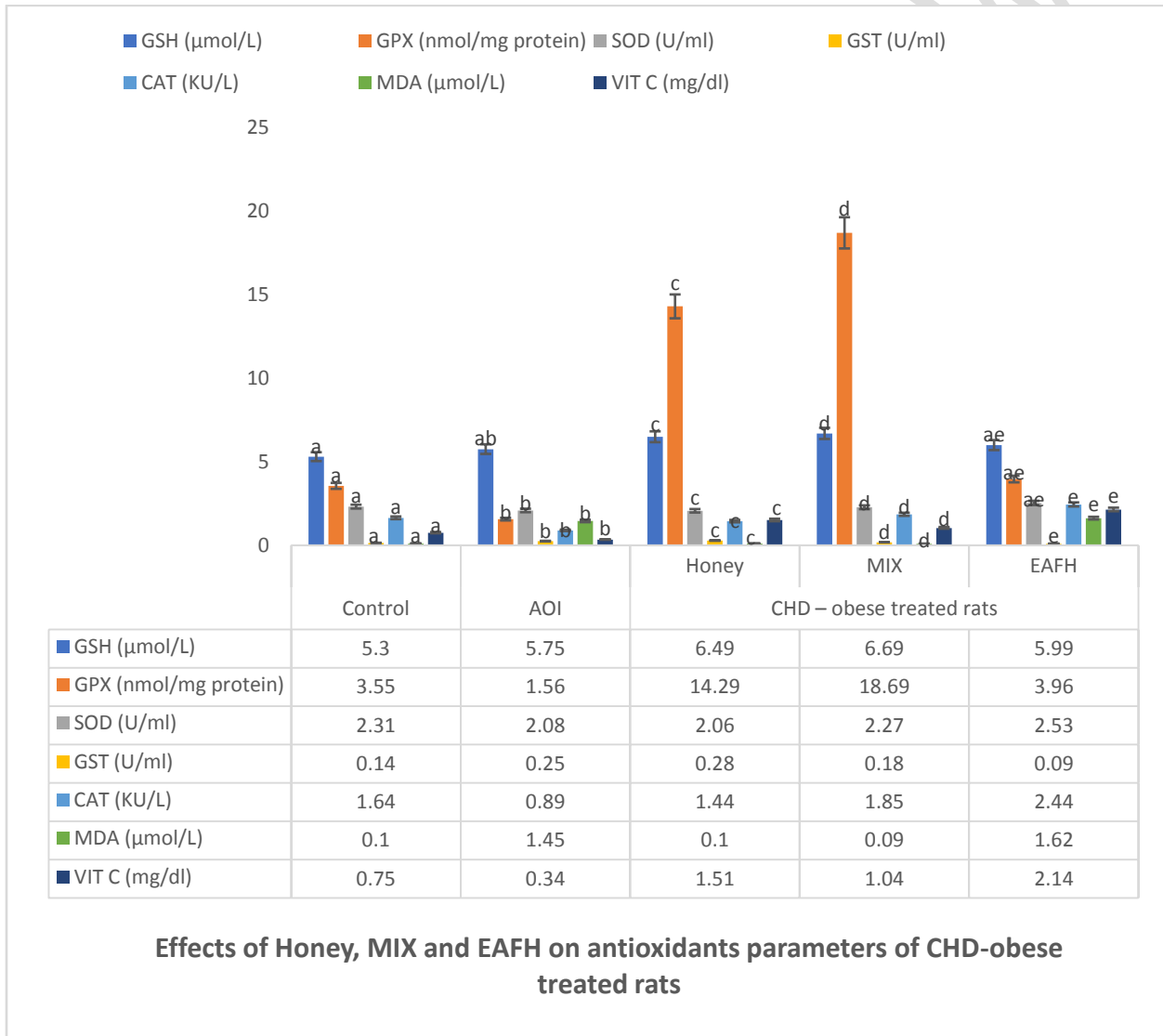


Figure 11: Effects of honey, MIX, and EAFH on antioxidant parameters of CHD – obese treated rats

Results are Mean \pm SEM; Comparing normal control with AOI group, CHD-obese treated rats, treated honey, MIX, and EAFH at the level of significance ($p < 0.05$), Bars with different alphabets comparing control and a group are significantly ($p < 0.05$) different and ($n=6$). Key:

AOI: After obesity induction; CHD-obese rats: Carbohydrate obese rats group 2; MIX: 50% fresh lime juice and 50% honey EAFH: Ethylacetate Flavonoid-rich fraction of Honey; GSH: Reduced Glutathione; GPX: Glutathione peroxidase; SOD: superoxide dismutase; GST: Glutathione S- Transferase; MDA: Malondialdehyde; CAT: Catalase; VIT C: Vitamin C.

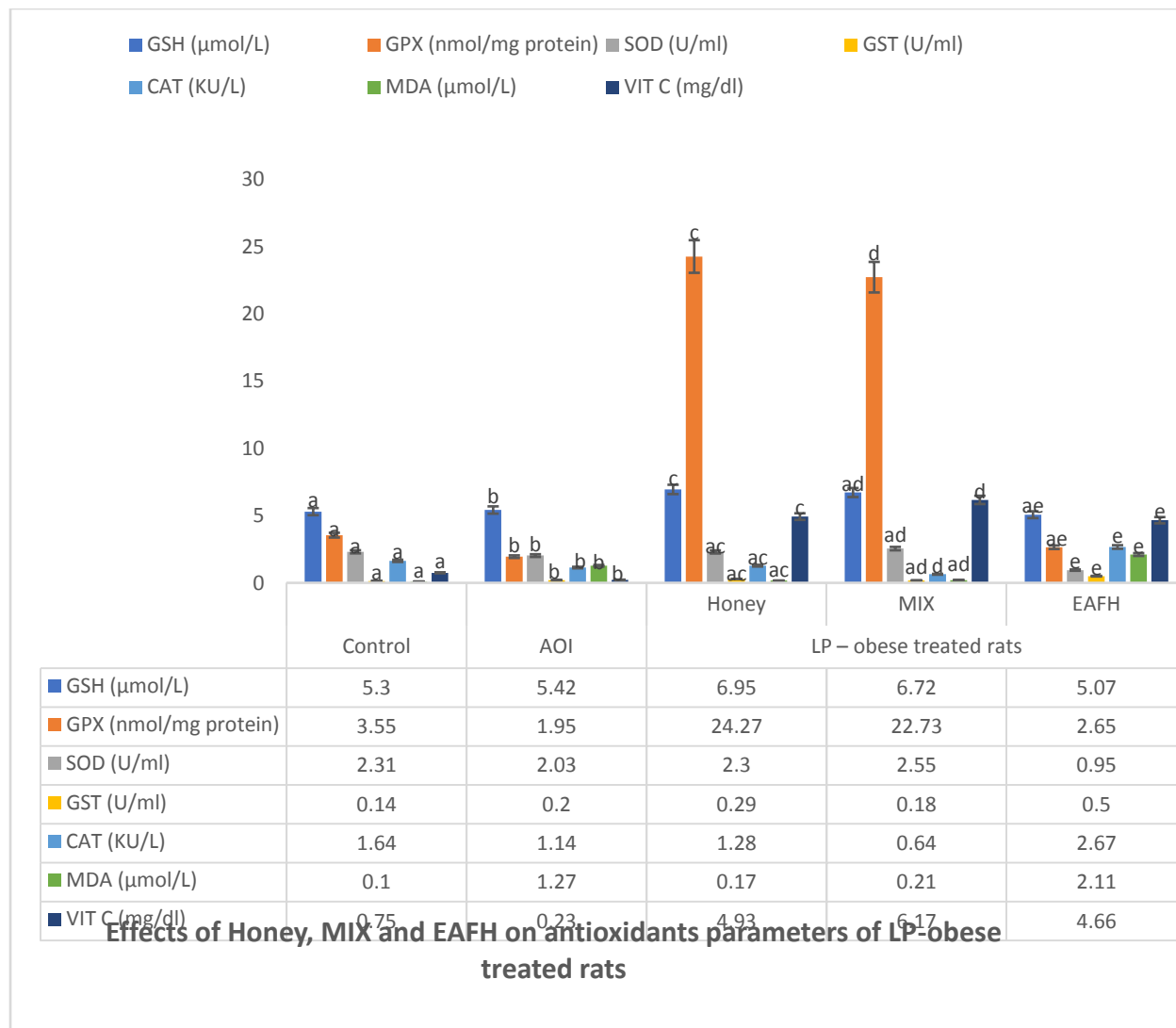


Figure 12: Effects of honey, MIX, and EAFH on antioxidant parameters of LP – obese treated rats

Results are Mean ± SEM; Comparing normal control with AOI group, LP-obese treated rats, treated honey, MIX, and EAFH at the level of significance ($p < 0.05$), Bars with different alphabets comparing control and a group are significantly ($p < 0.05$) different and ($n=6$). Key: AOI: After obesity induction; LP-obese rats: Lipid enriched diet obese rats group 3; MIX: 50% fresh lime juice and 50% honey EAFH: Ethylacetate Flavonoid-rich fraction of Honey; GSH: Reduced Glutathione; GPX: Glutathione peroxidase; SOD: superoxide dismutase; GST: Glutathione S- Transferase; MDA: Malondialdehyde; CAT: Catalase; VIT C: Vitamin C.

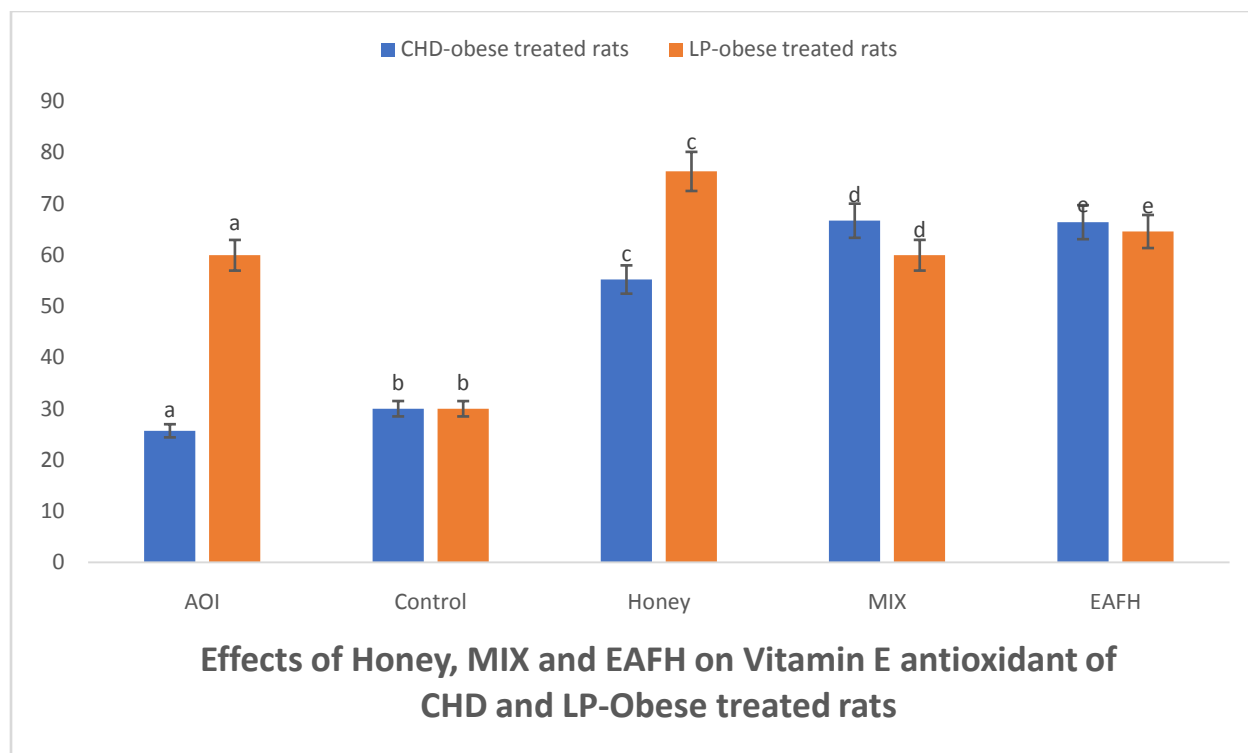
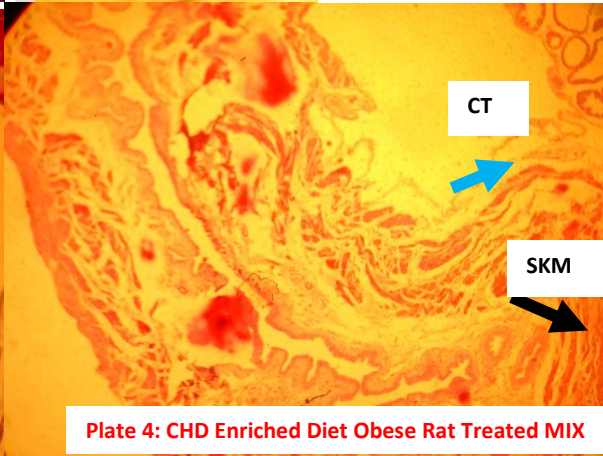
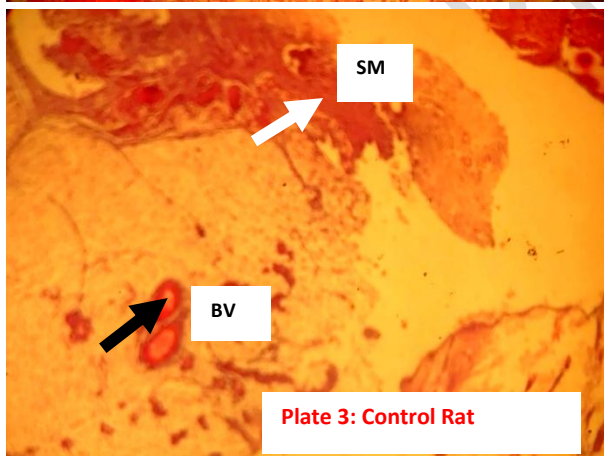
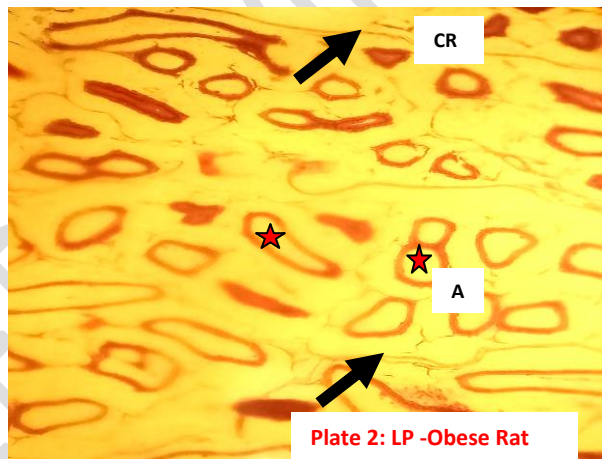
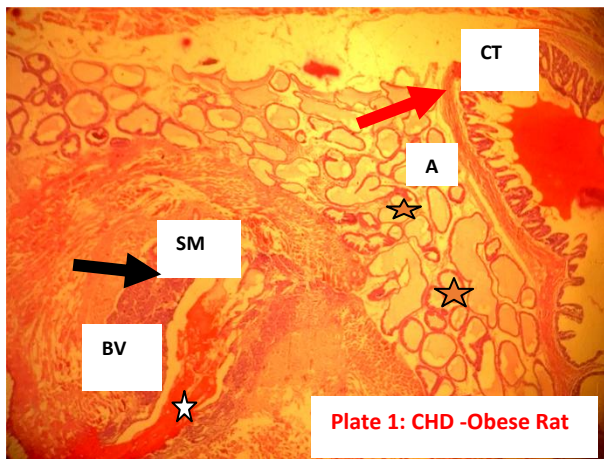


Figure 13: Effects of honey, MIX, and EAFH on vitamin E antioxidant parameters of CHD and LP-obese treated rats

Results are Mean \pm SEM; Comparing normal control with AOI group, LP-obese treated rats, treated honey, MIX, and EAFH at the level of significance ($p < 0.05$), Bars with different alphabets comparing control and a group are significantly ($p < 0.05$) different and ($n=6$). Key: AOI: After obesity induction; LP-obese rats: Lipid enriched diet obese rats group 3; MIX: 50% fresh lime juice and 50% honey EAFH: Ethylacetate Flavonoid-rich fraction of Honey.

3.9 Histological Examination of Adipose Tissue

Histopathological examination showed that adipose tissue from carbohydrate-enriched diet-obese rats and lipid-enriched diet-obese rats (Figure 14 plates 1 and 2) presented an increase in varied sizes of adipocytes due to the fat droplets accumulated within them. Meanwhile, adipose section from rats fed normal diet (control group-Figure 14 plates 3) and those treated with MIX: Mixture of FLJ (50%) and RH (50%) and EAFH: Ethylacetate Flavonoid-rich fraction of Honey (Figures 14, plates 4 – 7), showed completely absent adipocytes (control group-Figure 14 plates 3) and scanty adipocytes with a loss of organization mostly in small lobules. A few univacuolated small-size adipocytes were present and a partially filled lipid droplet was seen. The presence of skeletal muscles, smooth muscles, and connective tissues was observed with a normal presentation of tissue architecture. Blood vessels were observed and vascularized (Figures 14 plates 4 – 7).



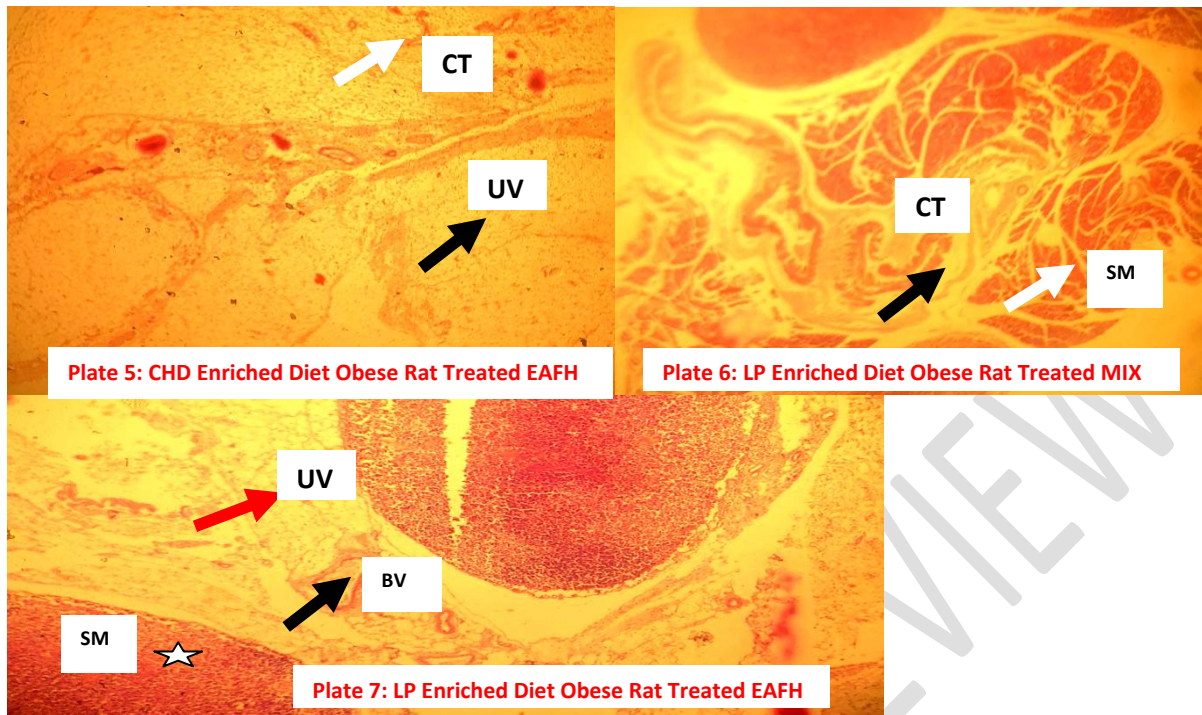


Figure 14: Effects of MIX and EAFH on Adipose Tissue of carbohydrate and lipid-enriched diets in obese treated rats (Plates 1 – 7).

Plate 1-Carbohydrate enriched diet-obese rat: Photomicrograph of the adipose tissue: Presence of skeletal muscles (SM)(black arrow) and connective tissues (CT)(red arrow) were observed with a normal presentation of tissue architecture. The adipocytes (star) were adequately filled lipid droplets with a packaged tissular organization mostly in small lobules and a signet ring appearance (red star) in a few. The shapes varied mainly unilocular and a few ovoid-shaped adipocytes (A). Blood vessels (white star) were observed and vascularized. Nuclei appeared decentralized or absent in the adipocytes due to nuclei pushed to the size of large fat droplets.H&E. mag. X100.

Plate 2-Lipid enriched diet-obese rat:Photomicrograph of Adipose tissue showed unarranged adipocytes due to variable sizes of adipocytes (A) (star). A few lipid droplets are seen accumulated within. Nuclei absent. No vascularization was seen. Cytoplasm rim (CR) (black arrow) seen. H&E. mag. X100.

Plate 3-Control (GROUP A): Photomicrograph of adipose tissue: connective tissue (CT) (Black arrow), smooth muscle (SM) (white arrow), and a few vascularized blood vessels (VBV) (red arrow) observed. Adipocytes are grossly absent. H&E./ mag. X100.

Plate 4 (CHD Enriched Diet Obese rat treated MIX): Photomicrograph of the adipose tissue: The adipocytes are scanty. Presence of skeletal muscles (SKM) (black arrow),) and connective tissues (CT) (blue arrow) were observed with normal presentation of tissue architecture. Blood vessels (BV) absent H&E. mag. X100.

Plate 5 (CHD Enriched Diet Obese rat treated EAFH): Photomicrograph of adipose tissue. A few univacuolated (UV) small-size adipocytes (black arrow) are present. Connective tissue (CT) present (white arrow) H&E.mag. X100.

Plate 6 (LP Enriched Diet Obese Rat Treated MIX):Photomicrograph of the adipose tissue: The presence of smooth muscles (SM) (black star) and connective tissues (CT) (white arrow)

were observed with a normal presentation of tissue architecture. Adipocytes (A) completely absent H&E. mag. X100.

Plate 7 (LP Enriched Diet Obese Rat Treated EAFH):Photomicrograph of the adipose tissue: The unilocular adipocytes (UA) (red arrow)), are mostly in small lobules, but filled with large lipid droplets. The presence of smooth muscles (SM) (white star) was observed with the normal presentation of tissue architecture. Blood vessels (BV) (black arrow) were observed and vascularized. Nuclei absent in the adipocytes.H&E. mag. X40.

4.DISCUSSION

The effects of honey, MIX, and EAFH on the serum and tissue lipid profile of the treated obese rats are shown in Figures 4, 5, 6, and 7. The approach of obesity induction in this study, using carbohydrate enriched diet and lipid (fat) enriched diet, is essential to mimic the usual route of obesity development in humans via diet [22, 33]. The concentrations of serum and tissue total cholesterol (TC), triacylglycerol (TAG), very low-density lipoprotein (VLDL), and low-density lipoprotein (LDL) in both carbohydrate and lipid-enriched diet-obese rat model of this study were higher; and the concentration of high-density lipoprotein (HDL) was decreased than the control. However, treatment of the obese rats with honey, MIX, and EAFH reduced the concentrations of serum and tissues LDL, TC, VLDL, and TAG that were high in the obese state when compared with normal control; and raised the concentration of HDL that was low at obese state, when compared with normal control (Figures 4 - 7). This is consistent with the study of Idoko et al. [21], who reported that the administration of FLJ, honey, and the mixture of FLJ and honey to lipid-enriched diet-obese rats, reduced body weight of rats, reduced the concentrations of LDL, TC, VLDL, and TAG; and increased HDL concentration. In support of this study, Daniel et al. [33] reported the reduction of phospholipids, TAG, total lipids, and TC in MSG-obese rats after treatment with extracts of African walnuts. Citrus flavonoids are essential in the prevention of hyperglycemia [34, 21], to a certain extent by their ability to bind with starch in order to improve glucose oxidation and glycogen levels and simultaneously reduce gluconeogenesis in hepatic tissues [35]. Consumption of flavonoids is well reported to exert cardioprotective and anti-obesity ability [36], and hold anti-tumor, anti-adhesive, anticarcinogenic, and anti-aggregation against clumping of erythrocytes, thereby maximizing their flavor-therapeutic effects [37]. Flavonoids essentially activate the impasse of enzymes involved in lipid and carbohydrate metabolism in the digestive system, directly impeding their digestion and absorption, which consequently prevents the development of obesity [38]. Digestive enzymes such as α -glucosidase, α -amylase, and lipase have been reported to be inhibited by flavonoids and most phenolic acids; such inhibition ultimately results in reduced digestion and absorption of fats and carbohydrates, and consequent reduction in adipocyte accumulation [39]. As honey is consumed, through their antioxidant function, flavonoids hamper the activity of the acyl-CoA cholesterol acyltransferase 2 (ACAT2) enzyme and activate LDL receptors for the removal of LDL from the blood [40]. Flavonoid's ability to scavenge free radicals enables them to hinder the oxidation of LDL and inhibit plaque buildup for atherosclerosis development in the artery [41]. Flavonoids exhibited a powerful anti-inflammatory potential against chronic low-grade inflammation secreted by adipose tissue in an obese state [42, 36], associated with insulin resistance and diabetes [43, 44]. Another advocated mechanism through which flavonoids in honey and lime juice reduce LDL, VLDL, TC, and TAG; and increase HDL in blood and tissues is linked with niacin-associated substance properties of flavonoids [40]; as their bioavailability potentially alters fats, by reducing free fatty acid mobilization from the adipose tissue and drastically decreasing the concentrations of TAG

[45]. Honey flavonoids enhance the metabolism of lipids by the liver to secret reduced concentrations of TAG and VLDL in circulation as VLDL is rapidly catabolized. Niacin-associated molecules in honey include benzene derivatives and norisoprenoid compounds [40]. The elevated concentrations of leptin, insulin and blood glucose (Figures 8 and 9) in obese rats were significantly ($p < 0.05$) reduced after treatment with honey, MIX, and EAFH. This study is consistent with Kumaraswamy et al. [46], who reported that the elevated leptin concentration of high-fat diet obese rats was significantly ($p < 0.05$) reduced after administration of aqueous extract of aerial parts of *Achyranthes aspera* L treatment. Leptin concentration may rise due to non-sensitization of leptin signal through elevated insulin concentration in a high-energy diet [24, 25]. Downregulation of leptin receptors mediates central leptin resistance due to diminished leptin signaling in neuron shortfall [25, 47]. Leptin resistance is a common occurrence in obesity, resulting in elevated leptin synthesis and circulation in the blood (hyperleptinaemia), but at the same time, low leptin sensitivity and availability to the brain, and leptin plasma concentrations are strongly associated with adiposity [48]. Thus, the flavonoid in honey and lime juice of this study could have exerted their neuroprotective potential by stimulating the leptin gene for uptake of leptin, reducing the concentration of leptin in the blood [47]. In leptin-resistant individuals, leptin transport across the blood-brain barrier to the hypothalamus for satiety signal relay is hampered [49]. This result in excessive elevation of blood leptin level while the concentrations in the brain are very low, leading to weight gain due to overeating, and in this condition, the brain judges that there is starvation and signals continual fat storage [50, 49].

The elevated concentration of insulin (Figures 8 and 9) in obese rats was significantly ($p < 0.05$) reduced after treatment with honey, MIX, and EAFH. In agreement with the result of this study, Item et al. [25] reported a significantly higher concentration of insulin in sugar-sweetened diet-fed obese female and male rats than in the honey-fed and normal control female and male rats. Similarly, Kumaraswamy et al. [46] also reported a significant ($p < 0.05$) reduction of insulin after obese rats were treated aqueous extract of aerial parts of *Achyranthes aspera* L. Insulin concentration was significantly ($P < 0.01$) higher in obese adolescent than normal control [51]. In obesity, unhealthy expansion of adipocytes results in inflammation and subsequent recruitment of TNF- α (tumor necrotic factor – alpha), which restrains signal transduction for insulin sensitivity, inducing insulin resistance [25].

The elevated blood glucose concentration (Figures 8 and 9) of the obese rats was significantly ($p < 0.05$) reduced after treatment with honey, MIX, and EAFH when compared with control and AOI. In obese rats, fasting blood glucose was found to be reduced after treatment with honey [25] and Ajibola et al. [52] findings reported that no significant change was observed after 13 weeks of dietary supplementation with honey. In a similar report, in Herin et al. [53], treatment with *C. aurantifolia* and *C. burmannii* reduced blood glucose concentration. The hypoglycaemic potential of honey-fed healthy and diabetic patients was reported by Nemseck et al. [54]; on the high-fat diet, obese rats, administration of aqueous extract of aerial parts of *Achyranthes aspera* L reduced the high blood glucose concentration [46]; and Hyperglycaemia in obese rats was effectively reduced by guava extracts [55]. In obesity, elevated blood glucose concentration could result in hyperlipoproteinemia and dyslipidemia [56]. Thus, flavonoid in honey and FLJ seem to have demonstrated antiobesity, hypoglycaemic and glucose-stabilizing abilities, since the estimated blood glucose of rats in this study falls within the reference value of fasting blood glucose concentration of a disease post absorptive state is 70 – 100 mg/dl or 120-140 mg/dl after a meal, especially carbohydrate meal [57, 56].

Figure 10 represents the effects of honey, MIX, and EAFH treatments on HMGCR activity, ARI, and CRI in CHD- obese treated rats and LP- obese treated rats' models. HMGCR activity was determined by an indirect method described by Rotimi et al. [31], in which the ratio of HMG-CoA/mevalonate was taken as an index of the activity of HMG-CoA reductase. An increase in the ratio indicates inhibition of HMGCR activity whereas a decrease in the ratio indicates increased HMG-CoA reductase activity. Thus, in the various obese treated models, HMGCR activity was significantly inhibited by honey, MIX, and EAFH treatments. The inhibitive effects of EAFH and MIX on HMGCR activity, atherogenic risk index (ARI), and coronary risk index (CRI) observed in this study are consistent with the report of Erejuwa et al. [6], Olukanni et al. [58] and Zaidatul et al. [59]. Erejuwa et al. [6] reported that honey-rich flavonoids such as quercetin, apigenin, chrysin, and luteolin [60] possess the anti-hyperlipidemic ability to physiologically regulate and inhibit HMGCR activity by controlling cholesterol synthesis and degradation and maintain the level of mevalonate derived products [61]. Olukanni et al. [58] reported that honey evidently reduced ARI and CRI and thus could also enhance the prevention of coronary heart diseases and cardiovascular diseases. Zaidatul et al. [59] reported that bee bread (honey product) administered at 0.5 g/kg/day for 6 weeks, significantly reduced ARI, Lee obesity index, LDL and TC. Regulation of serum cholesterol concentrations has become essential for therapeutic intervention for the prevention of hypercholesterolemia which could put the individual at high risk of atherosclerosis and cardiovascular issues such as stroke and myocardial infarction [62]. HMGCR enzyme is a rate-limiting enzyme in the biosynthesis of sterol (cholesterol) and thus its inhibition by either honey, MIX, or EAFH will prevent the circulation and accumulation of cholesterol in the body, especially LDL cholesterol [58]. The mechanism by which honey, MIX, and EAFH were able to inhibit HMGCR and reduce CRI and ARI could be associated with flavonoids' ability to peculate through the arteries or veins of the heart, clearing clogs of lipid deposits in the coronary arteries and permit blood circulation to the myocardium [62, 60]. These actions could prevent coronary thrombosis or heart attack, atherosclerosis, and cardiovascular diseases [58]. Hyperlipidemic and diabetic rats at high risk of atherosclerotic cardiovascular diseases were fed honey for 3 weeks and serum HDL was significantly increased, while TAG, TC, LDL, VLDL, atherogenic risk index and coronary risk index were significantly reduced [63]; and the activity of HMG-CoA reductase was inhibited, revealing the anti-hyperlipidemic property of flavonoids in honey [6]. An *in vitro* study of citrus aurantium L. blossom (CAB) total phenolic extract was reported to possess outstanding ability to reduce HMG-CoA reductase activity and free radical scavenging; this is consistent with the observation of EAFH flavonoids rich fraction treatment of obese rats in this study as it effectively inhibits HMG-CoA reductase activities [64, 65]. Prolong use of inhibitors of HMG-CoA reductase such as statin drugs are reported to exert potentially harmful side effects to the liver and heart such as myopathy, and this necessitates the novel use of honey, MIX, and EAFH as phyto or natural alternative inhibitors of HMG-COA reductase [66].

The effects of honey, MIX, and EAFH on antioxidant enzymes defense parameters such as GPx, SOD, GST, and CAT and the none enzymatic antioxidants GSH, VIT C and VIT E, and MDA (the lipid peroxidation and oxidative stress marker) of Carbohydrate enriched diet-obese treated rats and Lipid enriched diet-obese treated rats are shown in Figures 11 – 13. The finding of Suleiman et al. [67] is in agreement with this study which reported that the activities of GSH, GST, SOD, GPx, and CAT antioxidant enzymes were significantly reduced in the obese group relative to the control group; but the treatment of the obese rats with bee bread significantly increased these antioxidants activities. The therapeutic effect of MIX on enzymatic and non-

enzymatic antioxidants in this study, for the management of obesity is consistent with the report of Sani et al. [68]; who reported that a combination of gelam honey and ginger increased GSH level and decreased concentration of MDA when compared to the diabetic control group. As a main non-enzymatic antioxidant (reducing agent) of endogenous intracellular origin, glutathione is directly involved in the mop-up of free radicals and ROS, it essentially functions in catalysis, transport, and metabolism; and it confers cellular defense against peroxides and other harmful compounds [69, 70]. Daniel et al. [33] similarly agree with this study that in an MSG-obese rat study, the diminished activities of SOD, GSH, GST, and GPx were attenuated after treatment with extracts of African walnuts. Honey could have conferred on SOD the ability to convert superoxide anion free radical (O_2^-) produced by NADPH to H_2O_2 and O_2 [71, 72] and flushing out superoxide anion, protecting the bone from bone wasting and free radical damage [73]. The H_2O_2 generated by SOD can be neutralized to H_2O and O_2 by GPx, and catalase can further mop up any residual H_2O_2 present [74, 75]. SOD activity could have improved due to observed rich sources of Zn, Cu, Fe, and Mn in honey and lime juice, which are essential cofactors for its enzymatic function [76, 77]. In order to detoxify and neutralize the effect of H_2O_2 , generated by SOD, catalase which requires Mn and Fe cofactors to combine with GPx to catalyze the conversion and decomposition of H_2O_2 to H_2O and O_2 [78]. Elevated cellular concentration of H_2O_2 is reported to trigger the rise of catalase concentration in obese men, and catalase in return protects the cell against reactive oxygen species damage [79]. Membrane lipid peroxidation and production of MDA may result from reduced concentration of catalase, SOD, and GPx due to over-accumulation of H_2O_2 , resulting in oxidative stress [80, 81]. A mechanism of obesity linked to oxidative stress is reported to be associated with the production of reactive oxygen species and reactive nitrogen species, which stimulate the peroxidation of lipid and subdues the antioxidant defense mechanism [74, 82]. This results in unhealthy adipocyte enlargement (hypertrophy), which accommodates the production of chronic inflammation of low intensity in the white adipose tissue, characterized by up-regulation of pro-inflammatory adipokines such as TNF α , and decreased concentration of anti-inflammatory adipokines such as adiponectin [83, 84].

GST a phase II enzyme, function in drug metabolism, detoxify phase I metabolites (electrophilic compounds) and reactive oxygen species produced from the peroxidation of lipids, by conjugating with GSH [72], and protect the cell against oxidative damage to membrane lipid and DNA and prevented the development of obesity [85, 86] among population of aging Indians [87]. Serum vitamin C (ascorbic acid) and vitamin E (α – tocopherol) concentrations in all obese treated rats with honey, MIX, and EAFH, were higher than in obese rats (AOI) and control; this could be due to the fact that citrus aurantifolia and honey are good sources of vitamins C and E [49]. Thus, intake of honey alone or in a mixture with other therapy might be helpful in the management of hypercholesterolemia [21], obesity and obesity-associated complications [88], and coronary heart diseases through mechanistic flavonoid prevention of LDL oxidation [40, 89]. The effectiveness of vitamin C in the management of obesity was investigated and revealed that vitamin C prevented inflammation in tissue by blocking TNF- α and C-reactive protein (CRP) pathways [90]; and defending the cells from free radical damage and lipid peroxidation through its mechanistic adipose tissue hypoxia stoppage [91], reduced lipolysis and slow down the production and maturity of adipocyte growth [92]. The mechanism through which vitamin E impact healthy adipose tissue expansion [93], is linked to its antioxidant capacity to prevent lipid peroxidation in adipocyte by breaking free radical chain reaction system such as NADPH oxidase and neutralizing their deleterious effects on health [94, 95].

Figure 14 shows the histopathological examination of adipose tissue of the various obese models of this study. Obese rats (plates 1 and 2) had increased and enlarged varied sizes of adipocytes due to fat droplets accumulated within them. The enlarged adipocytes as a result of obesity in the various obese animal models in this study seem to have resulted from adipocyte hypertrophy (enlargement of adipose cells) [84] and hyperplasia (increase in adipose cell number) [96], due to unhealthy accumulation of fats and unhealthy expansion of white adipose tissue. This subsequently results in the generation of local inflammation of the adipose tissue, upregulation of the pro-inflammatory markers (TNF- α and IL-6) [97], and oxidative stress markers such as elevated MDA and reduced catalase, GPx, SOD and GST activities [74, 84]. However, the adipose section from control (Figure 14 plate 3) and treated rats (Figure 14, plates 4 – 7), showed completely absent adipocytes (control Figure 14 plate3) and scanty adipocytes with a loss of organization mostly in small lobules (Figure 14, plates 4 – 7). Flavonoids such as epigallocatechins are reported to exert their anti-obesity ability by activating the phosphorylation of adenosine monophosphate-activated protein kinase (AMPK) in the adipocytes, and upregulate lipolysis and downregulate lipogenesis [98].

5. CONCLUSION

In conclusion, honey alone, or in combination with lime juice could serve as a model pharmacotherapy for treating dyslipidemia and oxidative stress linked to obesity. The hyperlipidemic and oxidatively stressed obese rats in this study were effectively managed by treating them with honey, MIX, and EAFH. Hyperlipidemia and oxidative stress in the obese rat model of this study were ameliorated after treatment. The anti-hyperlipidemic effect was indicative of the reduced serum and tissue LDL, TC, TAG, and VLDL, and an increase in HDL concentration, alongside decreased activity of 3-Hydroxy-3-methylglutaryl (HMG) coenzyme A (CoA) reductase activity (HMGCOARA). The antioxidant enzymes (CAT, GPx, SOD, and GST), and non-enzymatic antioxidants (GSH, vitamin C, and Vitamin E) were elevated while MDA was reduced after the treatment. This was supported by the adipose section from treated rats, which showed a complete absence of adipocytes and scanty adipocytes with an intact architectural organization mostly in small lobules.

Abbreviations

AOI	After obesity induction
ARI	Atherogenic Risk Index
BGC	Blood glucose concentration
CAT	Catalase
CHD-obese rats	Carbohydrate-enriched diet-obese rats
CRI	Coronary Risk Index
EAFH	Ethylacetate Flavonoid-rich fraction of Honey
GPx	Glutathione peroxidase
GSH	Reduced glutathione
GST	Glutathione S- transferase
HMGCR	3-Hydroxy-3-methylglutaryl coenzyme A reductase
HPLC	High-performance liquid chromatography
LP-obese rats	Lipid-enriched diet-obese rats
MDA	Malondialdehyde
MIX	Mixture of 50% FLJ and 50% honey
SOD	Superoxide dismutase
VIT C	Vitamin C

REFERENCES

- [1] Idoko, A., Ezeh, E.M., Philip, O.C., *et al.*, 2023, "Raw and cooked aqueous and methanol extracts of *Vigna unguiculata* (black-eyed bean) enhances renal function in experimental Wister rats", *Nutr. and Food Sc.* Vol. ahead-of-print No. ahead-of-print. <https://doi.org/10.1108/NFS-07-2022-0221>.
- [2] Okafor, J.N.C., Meyer, M., Le Roes-Hill, M., *et al.*, 2022. Flavonoid and Phenolic Acid Profiles of Dehulled and Whole *Vigna subterranea* (L.) Verdc Seeds Commonly Consumed in South Africa. *Mol.* 27: 5265. <https://doi.org/10.3390/molecules27165265>.
- [3] Ying-Yin, C., Sheng-Yi, C., Jer-An, L., *et al.*, 2023. Preventive Effect of Indian Gooseberry (*Phyllanthus emblica* L.) Fruit Extract on Cognitive Decline in High-Fat Diet (HFD)-Fed Rats. *Mol. Nutr. Food Res.* 67:4, 2200791. doi.org/10.1002/mnfr.202200461
- [4] Agunloye, O.M., Oboh, G., Ademiluyi, A.O., *et al.*, 2019. Cardio-protective and antioxidant properties of caffeic acid and chlorogenic acid: Mechanistic role of angiotensin converting enzyme, cholinesterase and arginase activities in cyclosporine induced hypertensive rats. *Biomed.Pharmacol.* 109: 450–458.
- [5] Ayman, M.M., Rene, J.H.B., Mansur, A.S., *et al.*, 2019. Beneficial Effects of Citrus Flavonoids on Cardiovascular and Metabolic Health. *Oxi. Med. Cell.* Long. 2019:1-19.
- [6] Erejuwa, O.O., Nwobodo, N.N., Akpan, J.L., *et al.*, 2016. Nigerian honey ameliorates hyperglycemia and dyslipidemia in alloxan-induced diabetic rats. *Nutr.* 8(95):1-5.
- [7] Shahidi, F., Hossain, A., 2023. Importance of Insoluble-Bound Phenolics to the Antioxidant Potential Is Dictated by Source Material. *Antiox.* 12:203. <https://doi.org/10.3390/antiox12010203>.
- [8] Lotito, S.B., Fraga, C.G., 1997. (+)-Catechin prevents human plasma oxidation. *Free Radic. Biol. Med.* 24:435–441.
- [9] Grzesik, M., Naparło, K., Bartosz, G., *et al.*, 2018. Antioxidant properties of catechins: Comparison with other antioxidants. *Food Chem.* 241: 480–492.
- [10] Alam, M.M., Meerza, D., Naseem, I., 2014. Protective effect of quercetin on hyperglycemia, oxidative stress and DNA damage in alloxan induced type 2 diabetic mice. *Life Sci.* 109: 8–14.
- [11] Mohammed, K.H., Ahmed, A.D., Jihae, H., *et al.*, 2016. Molecular Mechanisms of the Anti-Obesity and Anti-Diabetic Properties of Flavonoids. *Inter. J. Mol. Sc.* 17, 569; 1- 32. [doi:10.3390/ijms17040569](https://doi.org/10.3390/ijms17040569).
- [12] Klaus, S., Pultz, S., Thone-Reineke, C., *et al.*, 2005. Epigallocatechin gallate attenuates diet-induced obesity in mice by decreasing energy absorption and increasing fat oxidation. *Int. J. Obes.* 29:615–623.
- [13] Darwish, A.G., Moniruzzaman, M., Tsoleva, V., *et al.*, 2023. Integrating Metabolomics and Gene Expression Underlying Potential Biomarkers Compounds Associated with Antioxidant Activity in Southern Grape Seeds. *Metabol.* 2023:13, 210. <https://doi.org/10.3390/metabo13020210>
- [14] Zaidun, N.H., Thent, Z.C., Latiff, A.A., 2018. "Combating oxidative stress disorders with citrus flavonoid: naringenin." *Life Sc.* 208:111–122.
- [15] Hernandez-Aquino, E., Muriel, P. 2018. "Beneficial effects of naringenin in liver diseases: molecular mechanisms." *World J. Gastro.* 24(16):1679–1707.

- [16] Nur, Z.R., Kok-Yong, C., Khairul, A.Z., 2018. A Review on the Protective Effects of Honey against Metabolic Syndrome. *Nutr.* 10 (1009): 1-21.
- [17] Mariarosaria, B., Stefania, D., 2020. Anti-Obesity Effects of Polyphenol Intake: Current Status and Future Possibilities. *Inter. J. Mol. Sc.* 20(5642):1-24.
- [18] Krishnasree, V., Mary, U.P., 2017. In vitro antidiabetic activity and glycemic index of bee honeys. *Ind. J. Trad. Knowl.* 16(1): 134–140.
- [19] Rochlani, Y., Pothineni, N.V., Kovelamudi, S., 2017. Metabolic syndrome: Pathophysiology, management, and modulation by natural compounds. *Ther. Adv. Cardio. Dis.* 11: 215–225.
- [20] Nordestgaard, B.G., 2016. Triglyceride-rich lipoproteins and atherosclerotic cardiovascular disease. *Circ. Res.* 118(4):547–563.
- [21] Idoko, A., Ikpe, V.P.O., Nelson, N.O., et al., 2017. Effects of Lime Juice and Honey on Lipid Profile of Cholesterol Enriched Diet Fed Rat Model. *Ann. Res. Rev. Bio.* 20(3):1-10.
- [22] Suhana, S., Francis, K.E., Fuzina, N.H., et al., 2017. Four-Week Consumption of Malaysian Honey Reduces Excess Weight Gain and Improves Obesity-Related Parameters in High Fat Diet Induced Obese Rats. *Evi. Comp. Altern. Med.* 2017: 1-9.
- [23] Facey, A., Dilworth, L., Irving, R., 2017. A Review of the Leptin Hormone and the Association with Obesity and Diabetes Mellitus. *J. Diabet. Metab.* 8(727):1-3.
- [24] Gilberto, J.P., Alexei, V., Henrique, L.S., et al., 2009. Decrease in leptin production by the adipose tissue in obesity associated with severe metabolic syndrome. *Arq Bras Endocrinol Metab.* 53(9): 1088-1095.
- [25] Item, J.A., Chidimma, E.I., Godwin, E.E., et al., 2020. Effect of long-term feeding of the Obudu natural honey and table sugar-sweetened diets on obesity and pro-inflammatory biomarkers in rats. *BMC Nutr.* 6(3): 1-11.
- [26] Soria, A. C, Martínez-Castro, I. and Sanz, J. (2003). Analysis of volatile composition of honey by solid phase micro extraction and gas chromatography-mass spectrometry. *Journal of Separation Science*, 26: 793-801.
- [27] Fuad A, Fadi A, Wael AA, Hammad KA, Saleh A, Ghassab MA, Haya JAS (2018) HPLC Analysis of Chemical Composition of Selected Jordanian Medicinal Plants and their Bioactive Properties. *Orien J Chem* 34(5): 2397-2403.
- [28] National Institute of Health (NIH) (1937). Guidelines for the Care and Use of Laboratory Animals. *Nat. Acad. Press.* 85:23.
- [29] Zimmerman, M., 1995. Ethical Guidelines for Investigations of Experimental Pain in Conscious Animals. *Pain.* 16(2):109-111.
- [30] Nakagawa, T., Ukai, K., Ohyama, T., et al., 2000. Effects of chronic administration of sibutramine on body weight, food intake and motor activity in neonatally monosodium glutamate-treated obese female rats: relationship of antiobesity effect with monoamines. *Expe. Animals.* 49:239–249.
- [31] Rotimi, O.A., Olayiwola, I.O., Ademuyiwa, O., et al., 2012. Effects of fibre-enriched diets on tissue lipid profiles of MSG obese rats. *Food Chem. Tox.* 50 4062–4067.
- [32] Kamal, M.S.A., Ghazali, A.R., Yahya, N.A., et al., 2012. Acute toxicity study of standardized *Mitragyna speciosa* korth aqueous extract in Sprague dawley rats. *J. Plant Stud.* 1(2):404–409.

- [33] Daniel, E.U., Item, J.A., Eyong, U.E., et al., 2020. African walnuts attenuate ectopic fat accumulation and associated peroxidation and oxidative stress in monosodium glutamate-obese Wistar rats. *Biomed. Pharmacol.* 124(109879): 1-10.
- [34] Idoko, A., 2019. Exploitative Beneficial Effects of Citrus Fruits. In: *Citrus - Health Benefits and Production Technology*. Muhammad Sajid, Amanullah (Eds). *IntechOpen*, p. 32-55.
- [35] Shen, W., Xu, Y., Lu, Y.H., 2012. Inhibitory effects of Citrus flavonoids on starch digestion and antihyperglycemic effects in HepG2 cells. *J. Agric. Food Chem.* 60(38): 9609-9619.
- [36] Burke, A.C., Sutherland, B.G., Telford, D.E. 2018. "Intervention with citrus flavonoids reverses obesity and improves metabolic syndrome and atherosclerosis in obese Ldlr^{-/-} mice," *J. Lip. Res.* 59(9):1714– 1728.
- [37] Waleed, F.A., 2019. Nutritional Benefits of Citrus Fruits. *Am. J. Biomed. Sc. Res.* 3(4): 1-4.
- [38] Pan, M.H., Wu, J.C., Ho, C.T., et al., 2018. Antiobesity molecular mechanisms of action: Resveratrol and pterostilbene. *BioFact.* 44:50–60.
- [39] Tan, Y., Chang, S.K.C., 2017. Digestive enzyme inhibition activity of the phenolic substances in selected fruits, vegetables and tea as compared to black legumes. *J. Funct. Foods.* 38:644–655.
- [40] Mohammed, K.A., Khaled, A.A., Abdullah, H.A., 2021. Effect of natural honey on lowering lipid profile. *Saudi Med. J.* 42(5): 473-480.
- [41] Panche, A.N., Diwan, A.D., Chandra, S.R., 2016. "Flavonoids: an overview," *J. Nutr. Sc.* 5(e47).
- [42] Assini, J.M., Mulvihill, E.E., Huff, M.W., 2013. "Citrus flavonoids and lipid metabolism," *Curr. Opin. Lipido.* 24(1):34–40.
- [43] Mahmoud, A.M., Abd El-Twab, S.M., Abdel-Reheim, E.S., 2017. Consumption of polyphenol-rich *Morus alba* leaves extract attenuates early diabetic retinopathy: the underlying mechanism. *Eur. J. Nutr.* 56(4):1671–1684.
- [44] Kamel, E.M., Mahmoud, A.M., Ahmed, S.A., et al., 2016. A phytochemical and computational study on flavonoids isolated from *Trifolium resupinatum* L. and their novel hepatoprotective activity. *Food and Funct.* 7(4): 2094–2106.
- [45] Patti, A.M., Al-Rasadi, K., Giglio, R.V., et al., 2018. Natural approaches in metabolic syndrome management. *Arch. Med. Sc.* 14:422-441.
- [46] Kumaraswamy, A., Rangaraju, S., Gnanasekaran, J., et al., 2020. Evaluation of anti-obesity potential of aqueous extract of *Achyranthes aspera* Linn. in high fat diet induced obese rats. *Clin. Phytosc.* 6(69):1-13.
- [47] Terzo, S., Calvi, P., Nuzzo, D., et al., 2022. Preventive Impact of Long-Term Ingestion of Chestnut Honey on Glucose Disorders and Neurodegeneration in Obese Mice. *Nutr.* 14(4): 756.
- [48] Lee, T.H., Cheng, K.K., Hoo, R.L., et al., 2019. The Novel Perspectives of Adipokines on Brain Health. *Inter. J. Mol. Sc.* 20(5638):1-7.
- [49] Manuha, M.I., Paranagama, P.A., Nageeb, B.M., 2019. Quantitative Analysis of Vitamin C in Lime and Lemon in Vitro: Verification of Vitamin C on the Impairment of Obesity. *International J. Adv. Sc Res Eng.* 5(10): 157-161.
- [50] Radic, R., Nikolic, V., Karner, I., et al., 2003. Circadian rhythm of blood leptin level in obese and non-obese people. *Coll Antrop.* 27(2):555-61.

- [51] Neveen, H.A., Nabila, A.E., Eman, R.Y., et al., 2016. Natural honey lowers plasma glucose, insulin and C-peptide in streptozotocin-induced diabetic rats: Comparison with metformin. *Sch. Res. Lib. Der Pharm. Lett.* 8(9):141-145.
- [52] Ajibola, A., Chamunorwa, J.P., Erlwanger, K.H., 2012. Nutraceutical values of natural honey and its contribution to human health and wealth. *Nutr. Metab.* 9(61):1–12.
- [53] Herin, M., Khotimah, M.Z., Mukhammad, R., 2018. Ameliorative effect of *Citrus aurantifolia* and *Cinnamomum burmanni* extracts on diabetic complications in a hyperglycemic rat model. *Trop. J. Pharma. Res.* 17(5):823-829.
- [54] Nemseck, T.M., Carmody, E., Furchner-Evansona, G., 2011. Honey promotes lower weight gain, adiposity and triglyceride than sucrose in rats. *Nutr. Res.* 31:55-60.
- [55] Eidenberger, T., Selg, M., Krennhuber, K., 2013. Inhibition of dipeptidyl peptidase activity by flavonol glycosides of guava (*Psidium guajava* L.): a key to the beneficial effects of guava in type II diabetes mellitus. *Food Sc. Tech. Camp.* 40(1): 33-41.
- [56] Dongiovanni, P., Lanti, C., Riso, P., et al., 2016. Nutritional therapy for nonalcoholic fatty liver disease. *The J. Nutr. Biochem.* 29, 1-11.
- [57] Idoko, A., Emmanuel, U., Yakubu, O., et al., 2019. Hepatocurative and Glucostabilizing Potentials of Ethanol Extract of Stem bark of *Flacourtia indica* in Aluminium Chloride induced Toxicity in Albino Wistar rats. *Curr. Trends Biomed. Eng. Biosc.* 17(5): 1-7.
- [58] Olukanni, O.D., Alagbe, Y.O., Akande, O.T., et al., 2020. Natural honey reduced atherogenic and coronary risk indices in Wistar rats. *Uni. Medi.* 39(1):3-11.
- [59] Zaidatul, A.O., Wan, S.W.G., Liza, N., et al., 2020. Phenolic Compounds and the Anti-Atherogenic Effect of Bee Bread in High-Fat Diet Induced Obese Rats. *Antio.* 9(33): 1-12.
- [60] Zeka, K., Ruparelia, K., Arroo, R.R.J., et al., 2017. Flavonoids and their metabolites: prevention in cardiovascular diseases and diabetes. *Dis.* 2017(5):16-19.
- [61] Istvan, E.S., Deisenhofer, J., 2000. The structure of the catalytic portion of human HMG-CoA reductase. *Biochim. Biophys. Acta*, 1529: 9-18.
- [62] Kleemann, R., Kooistra, T., 2005. HMG-CoA reductase inhibitors: effects on chronic subacute inflammation and onset of atherosclerosis induced by dietary cholesterol. *Curr. Drug Targ. Cardio. Haemat. Disor.* 5: 441-453.
- [63] Yuko, M., Shoko, Y., Shoichiro, H., 2020. Early life high-fat diet exposure evokes normal weight obesity. *Nutr. Metab.* 17(48): 1-8.
- [64] Kexin, H., Wenzhong, H., Mengyang, H., et al., 2019. Optimization of Ultrasonic-Assisted Extraction of Total Phenolics from *Citrus aurantium* L. Blossoms and Evaluation of Free Radical Scavenging, Anti-HMG-CoA Reductase Activities. *Mol.* 24(2368): 1-16.
- [65] Marco, G., Fulvio, P., Manfredi, M.G., et al., 2022. Bioactive effects of citrus flavonoids and role in the prevention of atherosclerosis and cancer. *J. Bio. Res.* 95(10313):1-11.
- [66] Kiortsis, D.N., Filippatos, T.D., Mikhailidis, D.P., et al., 2007. Statin associated adverse effects beyond muscle and liver toxicity. *Atheroscl.* 195:7–16.
- [67] Suleiman, J. B., Mohamed, M., Abubakar, A.B., et al., 2022. Therapeutic Effects of Bee Bread on Obesity- Induced Testicular-Derived Oxidative Stress, Inflammation, and Apoptosis in High-Fat Diet Obese Rat Model. *Antio.* 11(255): 1-18.

- [68] Sani, N.F.A., Levin, K.B., Chong, P.S., et al., 2014. Effect of the Combination of Gelam Honey and Ginger on Oxidative Stress and Metabolic Profile in Streptozotocin-Induced Diabetic Sprague-Dawley Rats. *BioMed. Res. Inter.* 2014(160695):1-9.
- [69] Machado, D.A.A., Almeida-Muradian, L.B.D., Sancho, M.T., et al., 2018. Composition and properties of *Apis mellifera* honey: A review. *J. Apicul. Res.* 57:35–37.
- [70] Sunitha, D., 2016. A review on antioxidant methods. *Asian J. Pharma. Clin. Res.* 9(2):14-32.
- [71] Seo, H., Lee, N. H., Ryu, S., 2014. Antioxidant and antiapoptotic effects of pine needle powder ingestion and endurance training in high cholesterol-fed rats. *J. exer. nutr. biochem.* 18 (3):301–309.
- [72] Emami, S.R., Mahvash, J., Rouhollah, H., 2016. Impact of eight weeks endurance training on biochemical parameters and obesity-induced oxidative stress in high fat diet-fed rats. *J. exer. nutr. biochem.* 20(1):029–035.
- [73] Kamaruzzaman, M.A., Thanu, A., Yusof, M.R., et al., 2019. Kelulut honey ameliorates glucocorticoid induced osteoporosis via its antioxidant activity in rats. *Asian Pac. J. Trop. Biomed.* 9(12): 493-500.
- [74] Chinedum, E., Joseph, B.S., Zaidatul, A.O., et al., 2020. Bee bread attenuates high fat diet induced renal pathology in obese rats via modulation of oxidative stress, downregulation of NF-kB mediated inflammation and Baxsignalling, *Arch. Physio. Biochem.* 1-18.
- [75] Cui, R., Gao, M., Qu, S., 2014. Overexpression of Superoxide Dismutase 3 Gene Blocks High Fat Diet-Induced Obesity, Fatt Liver and Insulin Resistance. *Gene Ther.* 2014(21):840–848.
- [76] Oihane, G., Fabiola, B., Marilidia, P., et al., 2022. Enterocyte superoxide dismutase 2 deletion drives obesity. *Sci* 25(103707):1-19.
- [77] Domazetovic, V., 2017. Oxidative stress in bone remodeling: Role of antioxidants. *Clin. Cases Min. Bone Metabo.* 14(2): 209-216.
- [78] Christophe, G., Pedro, B.C., 2017. Catalase, a remarkable enzyme: targeting the oldest antioxidant enzyme to find a new cancer treatment approach. *Biol. Chem.* 398(10): 1095–1108.
- [79] Abdulsamie, H.A., Mahmoud, H.H., Lamia, A.A., 2015. The balance between superoxide dismutase and catalase activities in sera of obese iraqi men. *Euromedi. Biomed. J. young doc.* 10(17):198-202.
- [80] Oluwatobi, T.S., Oluseyi, A.A., Michael, O.A., et al., 2015. Quercetin, a natural phytochemical and antioxidant protects against sodium azide-induced hepatic and splenic oxidative stress in rats. *J. Invest. Biochem.* 4(3):69-74.
- [81] Gusti, A.M.T., Qusti, S.Y., Alshammari, E.M., et al., 2021. Antioxidants-Related Superoxide Dismutase (SOD), Catalase (CAT), Glutathione Peroxidase (GPX), Glutathione-S-Transferase (GST), and Nitric Oxide Synthase (NOS) Gene Variants Analysis in an Obese Population: A Preliminary Case-Control Study. *Ant.* 10(595):1-16.
- [82] Lewandowski, Ł., Kepinska, M., Milnerowicz, H., 2019. The Copper-Zinc Superoxide Dismutase Activity in Selected Diseases. *Eur. J. Clin. Invest.* 49(e13036):1-5.
- [83] Choe, S.S., Huh, J.Y., Hwang, I.J., et al., 2016. Adipose Tissue Remodeling: Its Role in Energy Metabolism and Metabolic Disorders. *Front. Endocr.* 7(30): 1-16.

- [84] Michele, L., Federica, Z., Jamal, N., et al., 2019. Adipose Tissue Dysfunction as Determinant of Obesity-Associated Metabolic Complications. *Inter. J. Mol. Sc.* 20(2358): 1-23.
- [85] Yang, S.A., 2017. Lack of Association Between Glutathione s-Transferase Mu 1 (GSTM1) Gene Polymorphisms and Obesity. *J. Exer. Rehab.* 13:608–612.
- [86] Cairra, S., Iannelli, A., Sciarrillo, R., et al., 2017. Differential representation of liver proteins in obese human subjects suggests novel biomarkers and promising targets for drug development in obesity. *J. Enz. Inhib. Med. Chem.* 32:672–682.
- [87] Can, Y., Hakan, B., Serpil, O., et al., 2020. The activities of GST isozymes in stomach tissues of female obese patients. *Turk. J. Biochem.* 45(6):1-8.
- [88] Simona, T., Flavia, M., Antonella, A., 2020. Honey and obesity-related dysfunctions: a summary on health benefits. *J. Nutr. Biochem.* 82:(2020) 108401.
- [89] Dżugan, M., Tomczyk, M., Sowa, P., et al., 2018. Antioxidant activity as biomarker of honey variety. *Mol.* 2018:23 pii: E2069.
- [90] Block, G., Jensen, C.D., Dalvi, T.B., et al., 2009. Vitamin C treatment reduces elevated C-reactive protein. *Free Rad. Bio. Med.* 46 (1):70-77.
- [91] Cepeda-Lopez, A.C., Melse-Boonstra, A., Zimmermann, M.B., et al., 2015. In overweight and obese women, dietary iron absorption is reduced and the enhancement of iron absorption by ascorbic acid is one-half that in normal-weight women. *Am. J. Clin. Nutr.* 102(6):1389-97.
- [92] Büşra, T., Hatice, B., Makkule, G.K., 2019. “Vitamin C Physiology: The Known and the Unknown in Obesity.” *J. Food Nutr. Res.* 7(8):613-618.
- [93] Gariballa, S., Afandi, B., Abuhaltam, M., et al., 2013. Oxidative damage and inflammation in obese diabetic emirati subjects supplemented with antioxidants and B-vitamins: a randomized placebo-controlled trail. *Nutr. Metab. (Lond)*, 10: 21.
- [94] Zeng, G., Zhong, F., Li, J., et al., 2013. Resveratrol-mediated reduction of collagen by inhibiting proliferation and producing apoptosis in human hypertrophic scar fibroblasts. *Biosc. Biotech. Biochem.* 77: 2389– 2296.
- [95] Martín, A., Isabel, S., Julio, S., et al., 2015. Vitamin E reduces adipose tissue fibrosis, inflammation, and oxidative stress and improves metabolic profile in obesity. *Obesity.* 23(8):1598-1606.
- [96] Nemani, H., Uday, K., Boindala, S., et al., 2011. Obesity associated pathophysiological & histological changes in WNIN obese mutant rats. *Ind. J. Med. Res.* 134(3): 330–340.
- [97] Magdalena, J., Leslie, P.K., 2016. Obesity and related consequences to ageing. *AGE.* 38 (23): 1-18.
- [98] Choi, C., Hyun-Doo, S., Yeonho, S., et al., 2020. Epigallocatechin-3-Gallate Reduces Visceral Adiposity Partly through the Regulation of Beclin1-Dependent Autophagy in White Adipose Tissues. *Nutr.* 12(10): 3072.

UNDER PEER REVIEW