

Review Article

Breast Carcinoma: Classification, Risk Factors, Current Diagnostic Procedures and Therapeutics

Abstract

The aetiology of breast cancer is complicated. There are several types of Cancer, and one of them is breast cancer. In population health, breast cancer significantly impacts the most typical invasive malignancy and the second most typical death source for women. Several drugs are approved by FDA (Food and Drug Administration). Some are approved to prevent breast cancer; some are used to treat breast cancer and some drug combinations used in breast cancer. Recently, breast cancer mortality decreased in association with smaller breast volume and meeting the exercise recommendations. On the other hand, dietary fat has been proposed as one of the etiologic factors of breast cancer. Obesity, overweight and reduced physical activity, causes breast cancer. At an early stage, cancer detection could increase breast cancer survival rates significantly in the long term. The most crucial point for the best prognosis is identifying early-stage cancer cells. The conventional diagnostics test for breast cancer includes a physical examination, biopsy (Fine-needle aspiration biopsy, core needle biopsy, Surgical biopsy) and several imaging techniques like mammography (digital mammography, computer-aided detection and breast tomosynthesis), MRI (Magnetic Resonance Imaging).

Keywords: Breast cancer Diagnosis, Classification, Imaging, Risk factor, Tumour morphology

Introduction

Breast cancer

Breast cancer is remarkably ubiquitous cancer and the following most root of death due to cancer in female. The term "breast cancer" refers to a particular cancer prototype that arises from the tissue and typically lines the interior of ducts that supply the milk to the ducts¹[Be consistent. Do you mean \[1\], as you wrote in the text...](#). (Figure 1A)

Extensively breast cancer covers 10.4% of all types of cancer occurrences among female. This makes it the second most frequent type of non-skin cancer and the fifth most general cause of

death [1]. In 2004 worldwide breast cancer cause death around 519,000. [Need more recent reference???](#) Usually, it is common in women than men, though due to delay in diagnosis, the outcome is more unsatisfactory¹ [Be consistent. Do you mean \[1\], as you wrote in the text...](#). Cancer cells are much more similar to cells of the organism, and their RNA and DNA are identical to the organism from which they have originated [2]. This is the leading cause of these cancer cells not detected by the immune system, significantly if the immune system is weakened. Cancer cells are constructed from normal cells due to RNA and DNA mutation or genetic modification and RNA modification [2]. These alterations or mutations can occur spontaneously ill Law of Thermodynamics- raise of entropy. These may be induced by some other influences such as electromagnetic radiation (Gamma-rays, X-rays, Ultraviolet-rays, microwaves etc.), nuclear radiation fungi and bacteria, viruses (due to irritation, tissue inflammation, chemicals in the air, heat, mechanical cell-level injury, food and water, free radicals, ageing and evolution of DNA and RNA. All of the previously mentioned causes and conditions can result in a mutation that may lead to Cancer² [Be consistent. Do you mean \[2\], as you wrote in the text...](#).

The best therapy method depends greatly on the type of breast cancer. Receptor-positive breast cancer fabricates 75% of all cases of cancer, making it the most prevalent form. This form of cancer was found to respond to progesterone and [eestrogenestrogen](#)-restricting and hormone-progression therapies [3]. It developed in response to these hormones. The other one is HER2-positive; it is characterized by cells that make a lot of the HER2/neu protein. It contains 20–30% of breast cancers that are receptor-positive [3] Read as HER2-negative HER2/neu-overproducing cancer³ [Be consistent. Do you mean \[3\], as you wrote in the text...](#). (Figure 1B)

Molecular Classification of Breast Tumors (Cancerous)

In 2000, Dr Perou published an article on tumour stratification based on their molecular-genetic profile⁴ [Be consistent. Do you mean \[4\], as you wrote in the text...](#). The profile counts the etiopathogenetic factors of tumours and their response to treatment. There are two types of epithelial cells: luminal and basal⁴ [Be consistent. Do you mean \[4\], as you wrote in the text...](#). Apart from these well discriminate basal and luminal epithelial cells in glandular breast tissue, undifferentiated progenitor cells, and stem cells exist. Breast tumour classification is done after analyzing several genes regulating cell division and stromal and glandular breast cells' growth⁴ [Be consistent. Do you mean \[4\], as you wrote in the text...](#). (Figure 2)

Basal-Like Tumors: Basal-like tumours are from cells that resemble basal cells of the epithelial lining in ductal-lobular units (terminal portion) [5]. They exhibit negative expression for estrogen, progesterone and HER2 receptors and project positive expression for Cytokeratins 5,6 during immunohistochemistry. They indicate ed that tumours with worst prognosis⁵[Be consistent. Do you mean \[5\], as you wrote in the text....](#).

Luminal Tumors: The cells are present with in the terminal ductal-lobular units, i.e., luminal epithelial cells are akin to the luminal tumours. They are segregated into two subgroups based on estrogen receptors' expression and are exemplify by their gene expression and protein expression with positive immunohistochemistry staining in contrast to special cytokeratins 8, 18⁵[Be consistent. Do you mean \[5\], as you wrote in the text....](#). While the A subgroup has more substantial estrogen receptors, B subgroup has minor expression than A⁵[Be consistent. Do you mean \[5\], as you wrote in the text....](#).

Oestrogen receptor (ER) positive (HER-2 negative), 50-60% of all tumours illustrate germline mutation in BRCA2⁵[Be consistent. Do you mean \[5\], as you wrote in the text....](#).

Salient Features

- HER2-negative and ER-positive tumors are slow-growing and respond well to hormonal therapy.
- Further, they are sub-divided into low proliferation which is more common types and high proliferation which is fewer common types⁶[Be consistent. Do you mean \[6\], as you wrote in the text....](#).
- The low proliferation generally upset older men and women and is normally observed on routine mammographic screening. In this group, histological types are Adequate or steadily differentiated lobular, tubular, or mucinous carcinomas⁶[Be consistent. Do you mean \[6\], as you wrote in the text....](#).
- High proliferation groups can discriminate in lobular carcinomas and are mostly combined with BRCA mutations⁵.

Estrogen Receptor Negative Tumors or Her2 Positive Tumors: HER2 tumours due to their rare molecular-genetic profile shape a diverse group of tumours [5]⁵. They show positive staining for epithelial growth receptor 2 and negative staining for estrogen receptors [6]⁶. They usually

have a feeble prognosis in resemblance to luminal tumours. Among those 10-20% of tumours are HER2 positive tumours. It is relevant with amplification of HER2 gene on chromosome 17 [5]⁵. (Figure 3A)

Salient Features:

- Young women who are TP53 mutation carriers are mainly affected by these types.
- Few of them may apocrine type [6]⁶.
- Less than ten years are the survival rate [6]⁶.
- ER-positive cancers react to 15% to chemotherapy. Triple positive tumours are the higher level of the tumour [5]⁵. (Figure 3B)

Er-Negative or Her-2 Negative Tumors

Salient Features

- Young women who are TP53 carriers get affected [6]⁶.
- Poor diagnosis; poorly differentiated though high grade and triple-negative tumours.
- Histological variations consist of adenoid cystic, metaplastic, medullary, and secretory [6]⁶.

Histological Classification of Breast Tumors

It is segregated into two groups; non-invasive and invasive [7]⁷.

Invasive: Invasive breast tumours invaded the specific basement membrane and mainly are lesions. These are:

- Inflammatory carcinoma
- Tubular carcinoma
- Metaplastic carcinoma
- Medullary carcinoma
- Mucinous carcinoma

- Invasive lobular carcinoma

Non-Invasive: lesions restrained to lobules and ducts and have not to go through the limiting basement membrane [7]⁷.

- Lobular carcinoma
- Ductal carcinoma

Classification (TNM) of Breast Carcinoma

Union for International Cancer Control rules is executed using the TNM classification concerning nodal status (N), Primary tumour size (T), and the absence/ presence of distant metastases (M) (staging) [8]⁸.

For each disease, there are two different TNM classifications:

1. Clinical /cTNM based on imaging and clinical examination.
2. Pathological (pTNM) and it is based upon postoperative histological examination. (Table 1)

Risk Factors for Carcinoma Breast

Age: It is unusual before 25 years, but exceptional in familial cases. At the age of 70-80 years, it has the highest peak but after that declines in incidence occur. At the age of less than 11 years, menarche increases risk by 20% compared to menarche at age greater than 14 years [9]⁹.

Geography: It is seen from a survey study that there is an appreciable variation in the volume of breast tissue (bra cup size) of women according to birth country. Women born in Asia and Africa have smaller breast size than women born in the USA. In developed countries, six times higher incidence, but the incidence is rising in developing countries [9]⁹.

Genetic Factors:

- Mutations in familial ovarian and Cancer (BRCA2), familial breast and ovarian cancer (BRCA1), culpable for 1% of all breast cancer (CHEK2), p53, i.e., Li-Fraumeni syndrome [10]¹⁰.

- Family pedigree of breast cancer – it affects first-degree relatives who do not transfer a settled breast cancer gene mutation [9]⁹.
- Over interpretation of HER2/ proto-oncogene.
- Amplification of MYC and RAS genes [9]⁹.

Breastfeeding: It is observed that longer the span of breastfeeding, breast carcinoma is less [9]⁹.

Hormonal Influence: Excess level of estrogens (nulliparity, long period of reproductive life, increasing age, first child at a late age and exogenous estrogens) [9]⁹.

Environmental Factors: Radiation exposure, alcohol intake, phytoestrogens, tobacco, the light at night, metals such as arsenic, beryllium, cadmium, chromium, nickel etc., Endocrine disrupting chemicals (bisphenol A, Paraben, Phthalates, polybrominated diphenyl ethers, Perfluoroalkyl substances) and organochlorine pesticides (which has estrogen-like effects) [11]⁺.

Proliferative Carcinoma of the Contralateral Breast or Endometrium: have several similar dangerous factors [11]⁺.

Breast Density: High breast thickness on mammography has a 4-5 times greater risk of ER-positive and ER-Negative cancers [11]⁺.

Obesity: Women with obesity and less than 40 years have an ovulatory cycles and lower progesterone levels reduce the risk of carcinoma breast. At the same time, postmenopausal obesity raises the risk associated with ~~oestrogen~~estrogen synthesis in fat depots [11]⁺⁺. Obesity is measured by BMI or body mass index. This is known to be linked to an earlier age at menarche, an increased chance of postmenopausal breast cancer, and a decreased likelihood of premenopausal breast cancer. BMI may be more crucial, but it may not be the exact measure of body fatness [11]⁺⁺.

The odd relationship between obesity in pre- and postmenopausal women may result from the two age groups' varying prevalence's of progesterin receptor positive (ER+/PR+) / oestrogen receptor-positive tumours [9]⁹.

Medicine used for Breast Cancer Treatment

For the therapy of breast cancer, there are numerous medications on the market. Medicines that have been endorsed here by FDA. (Figure 4, 5)

Dietary Natural Products

The primary bioactive ingredients in dietary raw product perform a decisive part in the treatment and prevention of breast cancer. (Table 2) [Need reference?](#)

Physical Examination:

Breast self-examination, or consistent examining, is still believed an essential way towards early detection of breast cancer early, which leads to successful treatment. Breast self-cross-examination is a pragmatic screening tool, correctly when used in consolidation with legitimate check-ups: mammography, and ultrasound or MRI in some cases⁴⁶[Where are references no. 12 to 45???](#). It recommends that all women routinely perform breast self-exams as part of their general breast cancer screening strategy⁴⁶ [Where are references 12 to 45???](#).

Imaging Techniques

The use of imaging methods like mammography and MRI, frequently in conjunction with manual breast examinations, aids in the interpretation of breast cancer⁴⁷. [For the rest of the text references, check number of references???](#) [And write them consistently and in sequence???](#) However, the only method to be certain is to collect some tissue from the questionable area and perform further testing look at it with a lens⁴⁷.

Mammography is renowned for its expertise in capturing replica of the breast's interior. A small-dose X-Ray is used. A mammogram is a specific examination that primarily discovery and scrutiny of diseases in females⁴⁷. A segment of the body exposed to a tiny quantity of radiation during an X-Ray procedure produces images of the interior of the body⁴⁷.

Full-Field Digital Mammography (FFDM) are used to spawn mammographic images of the breast⁴⁸.

The Computer-Aided Detection (CAD) system is an instrument for finding cancer signs by scanning mammographic images for regions with abnormalities in density, mass, or calcification. These areas on the pictures are highlighted by the system, which informs the radiologists to closely examine these regions⁴⁹.

The imaging method known as **Magnetic Resonance Imaging** uses radio waves to construct precise pictures of inner body⁵⁰. Radiation is not necessary for MRI because it does not use X-rays. Breast MRI is used for breast cancer in a variety of ways, including:

- screening high-risk females (due to a gene anomaly or a background of the family)
- helps to collect thorough information about a suspicious region discovered on a mammogram or ultrasound.
- monitor the recurrence after treatment⁵⁰.

Ultrasound of Breast

Sound waves are used in ultrasound portray of the organ to design images of the intramural breast tissues. It is intact, non-invasive and has no purpose of radiation. It is used to help diagnose breast lumps or other abnormalities, that doctor may have found during a physical exam, mammogram or breast MRI⁵¹.

Biopsy

A small sample of breast tissue is abolished during a biopsy process to be tested in the lab. To examine a suspicious area in your breast and decide whether it is breast cancer, you can have a breast biopsy. Breast biopsy procedures come in a variety of varieties⁵².

Breast biopsies aid medical professionals in recognizing and diagnosing anomalies in the cells that make up breast lumps, other unusual breast changes, and suspicious or alarming discoveries on mammograms or ultrasounds. The breast biopsy's lab results help determine whether a patient requires additional surgery or other medical care⁵².

Other Aspects of Breast Cancer Diagnosis

In the last few years, CAD practice have been enlightened. A diagnosis made by a radiologist using the results of computerized analysis of medical images is known as CAD⁵³. When identifying lesions and making diagnostic choices, pictures can serve as a "second opinion." There are two types of CAD systems based on mammographic technologies: one is based on the conventional screen-film⁵⁶.

This instrument seems to be a useful diagnostic tool where breast cancer is suspected, since the technique can easily be applied to the skin over the tumour, or the ipsilateral areola, in the case of a deep-seated neoplasm⁴⁶. Computer-aided detection or analysis (CAD) structures, which use laptop technology to uncover abnormalities in mammograms which incorporates calcifications, masses, and architectural distortion, and therefore the usage of those outcomes by means of radiologists for diagnosis⁵⁴, can play a key role within the early detection of carcinoma and assist to minimize the death charge among ladies with breast most cancers. It's also intended to draw the attention of more research scientists to the research discipline of CAD for carcinoma, and advance studies on the detection and diagnosis of carcinoma and related techniques, along with picture processing, pc technology, and radiological imaging⁵⁵.

Therefore, a study was conducted to correlate the survival of antagonist patients chosen from International Breast Cancer Study Troop trial participants with that of women who turn pregnant following medication for early-stage breast cancer CAD⁵³. According to the research, subsequent pregnancies do not negatively impact the prognosis of early-stage breast cancer. The higher survival observed in this may merely reflect a healthy patient selection bias, but is also consistent with an antitumor effect of the pregnancy⁵⁷. Utilizing diffuse reflectance spectroscopy and natural fluorescence spectroscopy, a calculation has been built up which enables effective grouping of typical breast tissue, fibrocystic change, fibro-adenoma, and invading ductal carcinoma as far as genuinely significant boundaries⁵³.

The combined yields of diffuse reflectance spectroscopy and intrinsic fluorescence spectroscopy reflects promising results for differentiating of breast cancer from benign breast lesions and permits a prospective clinical study⁵³. (Figure 6)

Emerging Therapeutics for Breast Cancer

RNA-Based Therapeutics

In the past few decades, paradigm-shifting research, particularly that involving non-coding RNAs (ncRNAs), has profoundly altered scientific views on the complexity of cellular signaling pathways². There are numerous after effects akin with the use of many chemotherapeutic drugs in the medication of breast cancer. An appealing answer to these issues might be the practice of non-coding RNAs in breast cancer². Studies have shown that specific miRNAs and lncRNAs urge

the hormone, chemo-, and radio-sensitivity of cancer cells, and it appears that there may be some chance for management of cancer patients who exhibit therapy resistance has improved. Thus, the future of ncRNAs being established as potential therapeutics seems very promising in the field of cancers including breast cancers⁵⁸. The miRNA-based therapeutic strategies can open a path for combined therapies- such as chemotherapy, endocrine therapy, or targeted therapy, combined with miRNA based therapeutic, with the aim of enhancing or synergising anti-cancer effects with reduced toxicity, and the improved overall survival rate of breast cancer patients⁵⁹. Different strategies have been undertaken to extend the fate of siRNA systemically and deliver siRNA to the sites of action⁶⁰. MicroRNAs are involved with in many ways, hence it can be capitalized for designing therapeutics Since they can influence the cell response by simultaneously controlling multiple pathways whose proximity is the foundation of the refusal to chemotherapeutics, miRNAs are potentially effective targets in this approach². Since difficulties in targeting miRNAs, especially in vivo, among the possible approaches here presented, the use of PNA represents a feasible strategy to be tested in the near future⁶¹.

Nanotechnology Based Therapeutics

Zinc oxide nanoparticles (ZnONPs) has been widely used as an efficient drug delivery system in many biomedical applications. By using Rheum rhabdomyosarcoma Waste (RRW) as a new bioplatfrom, ZnONPs were created, and their anticancer effects on MCF7 cells were correlate to those of normal HFF cells⁶². Commensurate to the research, ZnONPs may one day be used to treat breast cancer as an effective biocompatible medication. The findings showed that the novel ZnONPs made from Rheum rhabdomyosarcoma waste had a specific anticancer activity⁶². Nevertheless, there are many challenges which needed to be explained for applying them as an efficient cancer therapy strategy- including the need to find more details on their special molecular mechanism and also evaluating their impacts on different cells and tissues⁶².

In order to improve a variety of factors, including time of blood circulation, biodistribution, and tumour cell-specific uptake, a therapeutic nanodrug formulation approach has been developed that readjust cell surface receptor-specific tying association and also maintains the essential synergy with blood and tumour tissue (called "DART" nanoparticles)⁶³. Results offer new insights into approaches for effective development of therapeutic nanoparticles as well as support the continued development of the DART platform for primary and metastatic tumors⁶³. It is

important for the researchers to note all the following considerations in relation to the TPDT of breast cancer utilising organic NPs; (1) it is of great significance to engineer biocompatible and biodegradable organic NPs towards blood cells and blood coagulation (2) dose-dependent and long-term toxicity of organic NPs should be valued in clinical trials, (3) absorption, biodistribution and excretion of organic NPs should be also taken under consideration through severe clinical tests⁶⁴.

Combined Therapeutics

One of the biggest barriers in treating Cancer with chemotherapeutic drugs is the acquisition of drug resistance⁶⁵. P-glycoprotein (Pgp) is a major mediator of the multidrug resistance to many lipophilic natural substances, including taxanes, doxorubicin, and vinblastine⁶⁵. The substantial endeavor that has been made thus distant to combat this and other drug resistances have not been genuinely effective. reported that various orthotopic human breast cancer xenografts selected for high levels of Pgp and multidrug resistance responded well and in a durable manner to different continuous low-dosage chemotherapeutics, when used in amalgamation with an antivascular endothelial cell growth factor (anti-VEGF) receptor-2 (flk-1)-neutralising antibody (DC101)⁶⁵. Taxol, adriamycin, and vinblastine were all found to be efficient when used in combination therapy, but chemotherapy protocols as monotherapies had little to no impact. Similar outcomes were attained when cisplatinum, a non-Pgp substrate drug, was applied to tumours that were immune to it. Finally, it was concluded that vascular-targeting protocols associated with frequent administration of very low doses of certain chemotherapeutic drugs can provide a stable and safe way to circumvent multidrug resistance in established orthotopically growing tumors, as long as these are used in combination with a second antiangiogenic drug, in this case, anti-VEGFR-2 blocking antibodies⁶⁵.

These results SU11248 treatment combined with docetaxel study revealed that SU11248 is quite effective in preclinical breast cancer models and also suggest that it can be useful in the clinical treatment of breast cancer⁶⁶.

According to research, the administration of BI-2536 along with the chemotherapy drugs doxorubicin and cyclophosphamide led to a complete and quicker response than chemotherapy alone and also prevented relapse, which is regarded as the most serious side effect the main danger posed by TNBC⁶⁷. The observations, altogether suggested that in association with

conventional chemotherapy, PLK1 inhibition is an attractive therapeutic approach, for the treatment of patients with TNBC⁶⁷. This approach potentially reduces drug resistance, while simultaneously providing therapeutic anti-cancer benefits, such as reducing tumor growth and metastatic potential, arresting mitotically active cells, reducing cancer stem cell populations, and inducing apoptosis⁶⁸.

Immune checkpoint inhibitors are becoming highly popular and successful for the therapy of cancer, but they have not yet drawn much interest in the treatment of breast cancer⁶⁹. On treatment of BRCA1-mutant breast cancers with cisplatin to increase their mutational load and then drugs in combination were targeted to two different immune checkpoint inhibitors, which gave promising results and suggested that a similar approach can work for patients⁶⁹.

Contrarily, a consolidation of curative drugs or the inclusion of chemotherapy to salutary compounds has shown a significant increase in outcomes and been demonstrated to be a successful approach for the treatment of TNBC⁷⁰. This review sheds light on effective combinational drug strategies and current clinical trial status of various combinatorial drugs for the treatment of TNBC⁷⁰.

Recent attempts to characterize TNBCs at the molecular level have identified a number of novel therapeutic targets, including immune checkpoints, androgen receptor, receptor and non-receptor tyrosine kinases, PARP1, and epigenetic proteins⁷¹. Key findings include that of the PARP inhibitor, olaparib, which extended progression-free survival in a trial of BRCA-mutated breast cancer and for which clinical approval (in this setting) appears forthcoming⁷¹.

Another, findings suggest to conclude that SHP2 establishes a shared signaling node allowing MBC cells to engage a diversity of growth and survival pathways at the same time, including those derived from the ECM⁷². The triple combination of trastuzumab, tucatinib and capecitabine lowered the risk of disease progression or death by 52% in patients with HER2- positive BCB⁷³.

On the basis of altered apoptosis mechanisms, combined chemo-magnetic field-photothermal treatment applying Lf-Doxo-PMNSs demonstrated the apical anticancer action⁷⁴. Therefore, depending on the observations, these can be used as a promising therapeutic platform with potential targeted drug delivery and high loading Furthermore, combining tranilast with Doxil nanomedicine, significantly improved immunostimulatory M1 macrophage content in the

tumorigenic tissue and improved the efficacy of the immune checkpoint blocking antibodies anti-PD-1/anti-CTLA-4 [74]. Capacity features as well as reducing cancer drug resistance⁷⁵. On applying contact-free, thermography-controlled water-filtered infrared-A superficial hyperthermia, immediately followed by hypo-fractionated reirradiation, consisting of 4 Gy once per week up to a total dose of 20 Gy, resulted in very high overall response rates even in large-sized tumors⁷⁶.

It concentrated on improving combinations of chemotherapy, immunotherapy, gene therapy, and radiotherapy with other traditional therapeutic modalities, and prospective directions are also discussed⁷⁷. This review aimed to highlight the importance of light in cancer therapy and further discussed the combinatorial strategies that promised to address the challenges of phototherapy⁷⁷.

References

1. Hiatt AR, Brody GJ. Annual Review of Public Health 2018; 39: 113–33.
2. Kumari K, Groza P, Aguilo F. Regulatory roles of RNA modifications in breast cancer. NAR Cancer 2021; 3(3): zcab036.
3. Lumachi F, Santeufemia D A, Basso SM. Current medical treatment of estrogen receptor-positive breast cancer. World J Biol Chem 2015; 6(3): 231-9.
4. Puztai L, Hess KR, Anderson K, Symmans WF. Pharmacogenomic predictor of sensitivity to preoperative chemotherapy with paclitaxel and fluorouracil, doxorubicin, and cyclophosphamide in breast cancer. J Clin Oncol 2006; 24(26): 4236-44.
5. Eliyatkin N, Yalçın E, Zengel B, Aktaş S, Vardar E. Molecular Classification of Breast Carcinoma: From Traditional, Old-Fashioned Way to A New Age, and A New Way. J Breast Health 2015;11(2): 59-66.
6. Brenton DJ, Carey AL, Ahmed AA, Caldas C. (2005). Journal of Clinical Oncology 2005; 23(29): 7350-7360.
7. Bombardieri E, Gianni L. Breast Cancer-Nuclear Medicine in Diagnosis and Therapeutic Options. Eur J Nucl Med Mol Imaging 2008; 31 Suppl 1: S1-2.
8. Benson RJ. The TNM staging system and breast cancer. The Lancet Oncology 2003; 4 (1): 56-60.

9. Sun J, Liu RH. Cranberry phytochemical extracts induce cell cycle arrest and apoptosis in human MCF-7 breast cancer cells. *Cancer Lett* 2006; 241:124–134.
10. Ikhuoria BE, Bach C. Introduction to Breast Carcinogenesis – Symptoms, Risks factors, Treatment and Management. *European Journal of Engineering Research and Science* 2018;3(7): 745.
11. Lee K, Kruper L, Dieli-Conwright MC, Mortimer EJ. The Impact of Obesity on Breast Cancer Diagnosis and Treatment. *Current Oncology Reports* 2019; 21: 41.
12. Park JH, Darvin P, Lim EJ, Joung YH, Hong DY, Park EU, Park SH, Choi SK, Moon ES, Cho BW. Hwanggeumchal sorghum Induces Cell Cycle Arrest, and Suppresses Tumor Growth and Metastasis through Jak2/STAT Pathways in Breast Cancer Xenografts. *PLoS ONE* 2012; 7: e40531.
13. Suganyadevi P, Saravanakumar KM, Mohandas S. The antiproliferative activity of 3-deoxyanthocyanins extracted from red sorghum (*Sorghum bicolor*) bran through P53-dependent and Bcl-2 gene expression in breast cancer cell line. *Life Sci* 2013; 92: 379–382.
14. Kubatka P, Kello M, Kajo K, Kruzliak P, Vybohova D, Smejkal K, Marsik P, Zulli A, Gonciová G, Mojzís J. Young Barley Indicates Antitumor Effects in Experimental Breast Cancer In Vivo and In Vitro. *Nutr. Cancer* 2016; 68(4):611-21.
15. Cho K, Lee CW, Ohm JB. In-Vitro Study on Effect of Germinated Wheat on Human Breast Cancer Cells. *Cereal Chem* 2016; 93(6): 647–649.
16. Rocha A, Wang L, Penichet M, Martins-Green M. Pomegranate juice and specific components inhibit cell and molecular processes critical for metastasis of breast cancer. *Breast Cancer Res. Treat* 2012; 136(3): 647–658.
17. Kritsanawong S, Innajak S, Imoto M, Watanapokasin R. Antiproliferative and apoptosis induction of α -mangostin in T47D breast cancer cells. *Int. J. Oncol* 2016; 48(5): 2155–2165.

18. Lee CJ, Wilson L, Jordan MA, Nguyen V, Tang J, Smiyun G. Hesperidin suppressed proliferations of both Human breast cancer and androgen-dependent prostate cancer cells. *Phytother. Res* 2010; 24(S1): S15–S19.
19. Li HZ, Yang B, Huang J, Xiang TX, Yin XD, Wan JY, Luo F, Zhang L, Li HY, Ren GS. Naringin inhibits growth potential of human triple-negative breast cancer cells by targeting β -catenin signaling pathway. *Toxicol. Lett* 2013; 220(3): 219–228.
20. Delphi L, Sepehri H. Apple pectin: A natural source for cancer suppression in 4T1 breast cancer cells in vitro and express p53 in mouse bearing 4T1 cancer tumors, in vivo. *Biomed. Pharmacother* 2016; 84: 637–644.
21. Burton LJ, Smith BA, Smith BN, Loyd Q, Nagappan P, McKeithen D, Wilder CL, Platt MO, Hudson T, Odero-Marah VA. Muscadine grape skin extract can antagonize Snail-cathepsin L-mediated invasion, migration and osteoclastogenesis in prostate and breast cancer cells *Carcinogenesis* 2015; 36(9): 1019–1027.
22. Plastina P, Bonofiglio D, Vizza D, Fazio A, Rovito D, Giordano C, Barone I, Catalano S, Gabriele BJ. Identification of bioactive constituents of *Ziziphus jujube* fruit extracts exerting antiproliferative and apoptotic effects in human breast cancer cells. *Ethnopharmacol* 2012;140(2): 325–332.
23. Kim JA, Kim MR, Kim O, Phuong N, Yoon J, Oh WK, Bae K, Kang KW. Amurensin G inhibits angiogenesis and tumor growth of tamoxifen-resistant breast cancer via Pin1 inhibition. *Food Chem Toxicol* 2012; 50(10): 3625–3634.
24. Nemeč MJ, Kim H, Marciante AB, Barnes RC, Talcott ST, Mertens-Talcott SU. Pyrogallol, an absorbable microbial gallotannins-metabolite and mango polyphenols (*Mangifera Indica* L.) suppress breast cancer ductal carcinoma in situ proliferation in vitro. *Food Funct* 2016; 7: 3825–3833.
25. Joo J, Hong S, Cho Y, Seo D. 10-Gingerol inhibits proliferation and invasion of MDA-MB-231 breast cancer cells through suppression of Akt and p38MAPK activity. *Oncol. Rep* 2016; 35: 779–784.
26. Lee HS, Seo EY, Kang NE, Kim WK. [6]-Gingerol inhibits metastasis of MDA-MB-231 human breast cancer cells. *J. Nutr. Biochem* 2008;19(5): 313–319.

27. Ling H, Yang H, Tan SH, Chui WK, Chew EH. (2010). 6-Shogaol, an active constituent of ginger, inhibits breast cancer cell invasion by reducing matrix metalloproteinase-9 expression via blockade of nuclear factor- κ B activation. *British journal of pharmacology* 2010; 161(8): 1763–1777.
28. Hsu YL, Chen CY, Hou MF, Tsai EM, Jong YJ, Hung CH, Kuo P.L. (2010). 6-Dehydrogingerdiol, an active constituent of dietary ginger, induces cell cycle arrest and apoptosis through reactive oxygen species/c-Jun N-terminal kinase pathways in human breast cancer cells. *Mol. Nutr. Food Res* 2010; 54(9): 1307–1317.
29. Lee CG, Lee HW, Kim BO, Rhee DK, Pyo S. Allicin inhibits invasion and migration of breast cancer cells through the suppression of VCAM-1: Regulation of association between p65 and ER- α . *J. Funct. Foods* 2015;15: 172–185.
30. Zhang H, Wang KM, Li, GM, Zhao ZX. Antitumor mechanisms of S-allyl mercaptocysteine for breast cancer therapy. *BMC Complement. Altern. Med. Med* 2014; 14(1): 270.
31. Na HK, Kim EH, Choi MA, Park JM, Kim DH, Surh YJ. Diallyl trisulfide induces apoptosis in human breast cancer cells through ROS-mediated activation of JNK and AP-1. *Biochem. Pharmacol* 2012;84(10):1241-50
32. Chou, C., Wu, Y., Wang, Y., Chou, M., Kuo, S., & Chen, D. Capsaicin-induced apoptosis in human breast cancer MCF-7 cells through caspase-independent pathway. *Oncology Reports* 2009; 21: 665-671.
33. Chang HC, Chen ST, Chien SY, Kuo SJ, Tsai HT, Chen DR. Capsaicin may induce breast cancer cell death through apoptosis-inducing factor involving mitochondrial dysfunction. *Hum. Exp. Toxicol* 2011; 30(10):1657-1665.
34. Thoennissen NH, O'Kelly J, Lu D, Iwanski GB, La DT, Abbassi S, Leiter A, Karlan B, Mehta R. Capsaicin causes cell-cycle arrest and apoptosis in ER-positive and -negative breast cancer cells by modulating the EGFR/HER-2 pathway. *Oncogene* 2010; 29: 285–296.
35. Rajput S, Kumar B, Dey KK, Pal I, Parekh A, Mandal M. Molecular targeting of Akt by thymoquinone promotes G1 arrest through translation inhibition of cyclin D1 and induces apoptosis in breast cancer cells. *Life Sci* 2013; 93(21): 783–790.

36. Wu D, Jia H, Zhang Z, Li S. Capsaicin suppresses breast cancer cell viability by regulating the CDK8/PI3K/Akt/Wnt/ β -catenin signaling pathway. *Mol Med Rep* 2020; 22(6): 4868-4876.
37. Woo CC, Hsu A, Kumar AP, Sethi G, Tan K. Thymoquinone Inhibits Tumor Growth and Induces Apoptosis in a Breast Cancer Xenograft Mouse Model: The Role of p38 MAPK and ROS. *PLoS ONE* 2013; 8(10): e75356
38. Rajput S, Kumar B, Dey KK, Pal I, Parekh A, Mandal M. Molecular targeting of Akt by thymoquinone promotes G1 arrest through translation inhibition of cyclin D1 and induces apoptosis in breast cancer cells. *Life Sci* 2013;93(21): 783–790.
39. Khan MA, Chen HC, Tania M, Zhang DZ. (2011). Anticancer activities of *Nigella sativa* (black cumin). *African journal of traditional, complementary, and alternative medicines* 2011; 8(5 Suppl): 226–232.
40. Gutheil WG, Reed G, Ray A, Anant S, Dhar A. (2012). Crocetin: an agent derived from saffron for prevention and therapy for cancer. *Current pharmaceutical biotechnology* 2012; 13(1): 173–179.
41. Greenshields AL, Doucette CD, Sutton KM, Madera L, Annan H, Yaffe PB, Knickle AF, Dong ZM, Hoskin DW. Piperine inhibits the growth and motility of triple-negative breast cancer cells. *Cancer Lett* 2015; 357(1): 129–140.
42. Do MT, Kim HG, Choi JH, Khanal T, Park BH, Tran TP, Jeong TC, Jeong HG. Antitumor efficacy of piperine in the treatment of human HER2-overexpressing breast cancer cells. *Food Chem* 2013;141(3): 2591–2599.
43. Lai L-h., Fu Q-h., Liu Y, Jiang K, Guo Q-m, Chen Q-y, Yan B, Wang Q-q, Shen J-g. Piperine suppresses tumor growth and metastasis in vitro and in vivo in a 4T1 murine breast cancer model. *Acta Pharmacol Sin* 2012; 33(4): 523–530.
44. Gonzalez-Vallinas M, Molina S, Vicente G, Sanchez-Martinez R, Vargas T, Garcia-Risco MR, Fornari T, Reglero G, de Molina AR. Modulation of estrogen and epidermal growth factor receptors by rosemary extract in breast cancer cells. *Electrophoresis* 2014; 35(11): 1719–1727.
45. Al-Sharif I, Remmal A, Aboussekhra A. Eugenol triggers apoptosis in breast cancer cells through E2F1/survivin down-regulation. *BMC Cancer* 2013; 600.

46. Sarker R, Islam MS, Moonajilin MS, Rahman M, Gesesew HA, Ward PR. Knowledge of breast cancer and breast self-examination practices and its barriers among university female students in Bangladesh: Findings from a cross-sectional study. *PLoS ONE* 2022; 17(6): e0270417
47. Radhakrishna S, Agarwal S, Parikh PM, Kaur K, Panwar S, Sharma S, Dey A, Saxena KK, Chandra M, Sud S. Role of magnetic resonance imaging in breast cancer management. *South Asian J Cancer* 2018; 7(2): 69-71.
48. Yang WT, Lai CJ, Whitman GJ, Murphy WA Jr., Dryden MJ, Kushwaha AC, Sahin AA, Johnston D, Dempsey PJ, Shaw CC. Comparison of full-field digital mammography and screen-film mammography for detection and characterization of simulated small masses. *AJR Am J Roentgenol* 2006; 187(6): W576-81.
49. Masud R, Al-Rei M, Lokker C. Computer-Aided Detection for Breast Cancer Screening in Clinical Settings: Scoping Review. *JMIR Med Inform* 2019;7(3): e12660.
50. Menezes GL, Knuttel FM, Stehouwer BL, Pijnappel RM, van den Bosch MA. Magnetic resonance imaging in breast cancer: A literature review and future perspectives. *World journal of clinical oncology* 2014; 5(2): 61–70.
51. Iranmakani S, Mortezaazadeh T, Sajadian F, Ghaziani MF, Ghafari A, Khezerloo D, Musa AE. A review of various modalities in breast imaging: technical aspects and clinical outcomes. *Egypt J Radiol Nucl Med* 2020;51: 57
52. Loughran CF, Keeling CR. Seeding of tumour cells following breast biopsy: a literature review. *Br J Radiol* 2011;84(1006): 869-74.
53. Tomar D, Yadav AS, Kumar D, Bhadauriya G, Kundu GC. Non-coding RNAs as potential therapeutic targets in breast cancer. *Biochimica et Biophysica Acta (BBA)-Gene Regulatory Mechanisms* 2020;1863(4): 194378.
54. Tay TKY, Tan PH. Liquid Biopsy in Breast Cancer: A Focused Review. *Arch Pathol Lab Med* 2021;145(6):678-686.
55. Gelber S, Coates AS, Goldhirsch A, Castiglione-Gertsch M, Marini G, Lindtner J, Edelman DZ, Gudgeon A, Harvey V, Gelber RD. International Breast Cancer Study

- Group. Effect of pregnancy on overall survival after the diagnosis of early-stage breast cancer. *Obstetrical & Gynecological Survey* 2001; 56(9): 531-2.
56. Tang J, Rangayyan RM, Xu J, Naqa. IE., Yang Y. Computer-aided detection and diagnosis of breast cancer with mammography: recent advances. *IEEE transactions on information technology in biomedicine* 2009;13(2): 236-51.
57. Volynskaya ZI, Haka AS, Bechtel KL, Fitzmaurice M, Shenk R, Wang N, Nazemi J, Dasari R., Feld MS. Diagnosing breast cancer using diffuse reflectance spectroscopy and intrinsic fluorescence spectroscopy. *Journal of biomedical optics* 2008;13(2): 024012.
58. Wong JS, Cheah YK. Potential miRNAs for miRNA-Based Therapeutics in Breast Cancer, *Non-coding RNA* 2020; 6(3): 29.
59. Gomasca M, Maroni P, Banfi G, Lombardi G. microRNAs in the Antitumor Immune Response and in Bone Metastasis of Breast Cancer: From Biological Mechanisms to Therapeutics. *International Journal of Molecular Sciences* 2020; 21(8): 2805.
60. Salari S, Neamati A, Tabrizi MH, Seyedi SM. Green-synthesised Zinc oxide nanoparticle, an efficient safe anticancer compound for human breast MCF7 cancer cells. *Applied Organometallic Chemistry* 2020;34(3): e5417.
61. Dancy JG, Wadajkar AS, Connolly NP, Galisteo R, Ames HM, Peng S, Tran NL, Goloubev, OG, Woodworth GF, Winkles JA, Kim AJ. Decreased nonspecific adhesivity, receptor-targeted therapeutic nanoparticles for primary and metastatic breast cancer. *Science advances* 2020; 6(3):eaax3931.
62. Thorat ND, Bauer J. Nanomedicine: next generation modality of breast cancer therapeutics. *Nanomedicines for Breast Cancer Theranostics*, Elsevier 2020; ISBN: 9780128200179.
63. Montaseri H, Kruger CA, Abrahamse H. Organic nanoparticle based active targeting for photodynamic therapy treatment of breast cancer cells. *Oncotarget* 2020; 11(22): 2120-36.
64. Klement G, Huang P, Mayer B, Green SK, Man S, Bohlen P, Hicklin D, Kerbel RS. Differences in therapeutic indexes of combination metronomic chemotherapy and an anti-

VEGFR-2 antibody in multidrug-resistant human breast cancer xenografts. *Clinical cancer research* 2002; 8(1): 221-232.

65. Abrams TJ, Murray LJ, Pesenti E, Holway VW, Colombo T, Lee LB, Cherrington JM, Pryer NK. Preclinical evaluation of the tyrosine kinase inhibitor SU11248 as a single agent and in combination with “standard of care” therapeutic agents for the treatment of breast cancer. *Molecular cancer therapeutics* 2003; 2(10): 1011-21.
66. Maire V, Némati F, Richardson M, Vincent-Salomon A, Tesson B, Rigai G, Gravier E, Marty-Prouvost B, Koning LD, Lang G, Gentien D, Dumont A, Barillot E, Marangoni E, Decaudin D, Roman-Roman S, Pierré A, Cruzalegui F, Depil S, Tucker GC, Dubois T (2013). Polo-like kinase 1: a potential therapeutic option in combination with conventional chemotherapy for the management of patients with triple-negative breast cancer. *Cancer research* 2013; 73 (2): 813–823.
67. Satelli A, Brownlee Z, Mitra A, Meng QH, Li S. Circulating Tumor Cell Enumeration with a Combination of Epithelial Cell Adhesion Molecule–and Cell-Surface Vimentin–Based Methods for Monitoring Breast Cancer Therapeutic Response. *Clinical chemistry* 2015; 61(1): 259-66.
68. Nolan E, Savas P, Policheni AN, Darcy PK, Vaillant F, Mintoff CP, Dushyanthen S, Mansour M, Pang JM, Fox SB, Perou CM. Combined immune checkpoint blockade as a therapeutic strategy for BRCA1-mutated breast cancer. *Science translational medicine* 2017; 9(393): eaal4922
69. Chalakur-Ramireddy NK, Pakala SB. Combined drug therapeutic strategies for the effective treatment of Triple Negative Breast Cancer. *Bioscience reports* 2018; 38(1): BSR20171357
70. Lee A, Djamgoz MB. Triple negative breast cancer: emerging therapeutic modalities and novel combination therapies. *Cancer treatment reviews* 2018; 62:110-22.
71. Chen H, Libring S, Ruddaraju KV, Miao J, Solorio L, Zhang ZY, Wendt MK. SHP2 is a multifunctional therapeutic target in drug resistant metastatic breast cancer. *Oncogene* 2020; 39:7166–7180.

72. Fares J, Kanojia D, Rashidi A, Ulasov I, Lesniak MS. Landscape of combination therapy trials in breast cancer brain metastasis. *International Journal of Cancer* 2020;147(7):1939-1952
73. Sharifi M, Hasa, A, Nanakali NM, Salihi A, Qadir FA, Muhammad HA, Shekha MS, Aziz FM, Amen KM, Najafi F, Yousefi-Manesh H. (2020). Combined chemo-magnetic field-photothermal breast cancer therapy based on porous magnetite nanospheres. *Scientific Reports* 2020;10(1): 1-5.
74. Notter M, Thomsen AR, Nitsche M, Hermann RM, Wolff HA, Habl G, Münch K, Grosu AL, Vaupel P. Combined wIRA-hyperthermia and hypofractionated re-irradiation in the treatment of locally recurrent breast cancer: evaluation of therapeutic outcome based on a novel size classification. *Cancers* 2020;12(3): 606.
75. Panagi M, Voutouri C, Mpekris F, Papageorgis P, Martin MR, Martin JD, Demetriou P, Pierides C, Polydorou C, Stylianou A, Louca M. TGF- β inhibition combined with cytotoxic nanomedicine normalises triple negative breast cancer microenvironment towards anti-tumor immunity. *Theranostics* 2020;10(4): 1910.
76. Xie Z, Fan T, An J, Choi W, Duo Y, Ge Y, Zhang B, Nie G, Xie N, Zheng T, Chen Y. Emerging combination strategies with phototherapy in cancer nanomedicine. *Chem. Soc. Rev* 2020;49: 8065-8087
77. Bhattacharyya GS, Doval DC, Desai CJ, Chaturvedi H, Sharma S, Somashekhar SP. Overview of Breast Cancer and Implications of Overtreatment of Early-Stage Breast Cancer: An Indian Perspective. *JCO Global Oncology* 2020; 6:789-98.

Formatted: Left

Table 1: TNM classification

| T | It is the elementary tumour | |
|--------------|---|--|
| TX | Reckoning the main tumour is impossible | |
| T0 | There is no indication of the original tumour. | |
| Tis | Carcinoma in situ: intralobular or intraductal carcinoma | |
| T1 | Tumours are mainly less than 2cm in the finest extent. | |
| T1mic | 0.1 cm of micro-invasion or fewer | |
| T1a | Less than 0.5 cm but in excess of 0.1 centimetre | |
| T1b | Less than 1 centimetre but ≥ 0.5 centimetre in | |
| T1c | ≥ 2 centimetre but ≤ 1 centimetre | |
| T2 | Less than 5 centimetres, but at their largest, tumours are more than 2 cm. | |
| T3 | The largest extent of tumours is greater than 5 centimetres. | |
| T4 | Tumors can be of any size and only extend directly through the epidermis or chest wall. | |
| T4a | Expansion to the chest wall | |
| T4b | Breast swelling | |
| T4c | Both the 4a and the 4b | |
| T4d | This includes provocative carcinoma. | |
| N | Regional Lymph nodes | |
| NX | There is no way to determine regional lymph nodes. | |
| N1 | In motile ipsilateral lymph nodes, metastasis occurs. | |
| N2 | Without clinically obvious axillary lymph node cancer | |
| N2a | Metastasis is fixed in axillary lymph nodes to other structures or with one another. | |
| N2b | Metastasis can occur only in clinically visible internal mammary lymph nodes. | |
| N3 | The unilateral infraclavicular lymph node developing metastases | |
| N3a | A lymph node in the infraclavicular | |
| N3b | Internal mammary duct metastases. | |

| | | |
|---|---|--|
| N3c | Lastly, metastasis in the lymph node above the clavicle. | |
| M | Distant Metastasis | |
| MX | Distant metastasis cannot be determined. | |
| M0 | There are no lone metastases. | |
| MO (i+) | Absence of any symptoms or clinical indications of metastases in addition to the presence of tumour cells that can be seen under a microscope or by a molecular test in the blood, non-regional lymph nodes > 2mm. No, radiological or clinical confirmation of metastases. | |
| M1 | Distant metastasis histologically verifies or clinically evident via classical or imaging examination methods, greater than 0.2 mm. | |
| Postoperative TNM classification | | |
| pT | primary tumour | |
| pN | regional lymph nodes | |

[Table 1: TNM classification](#)

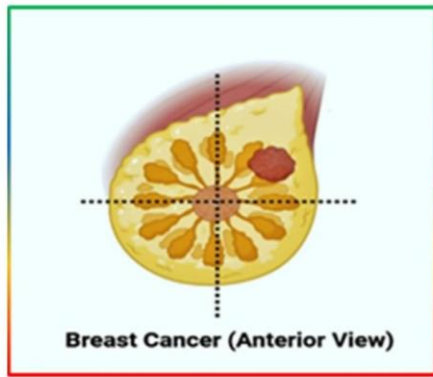
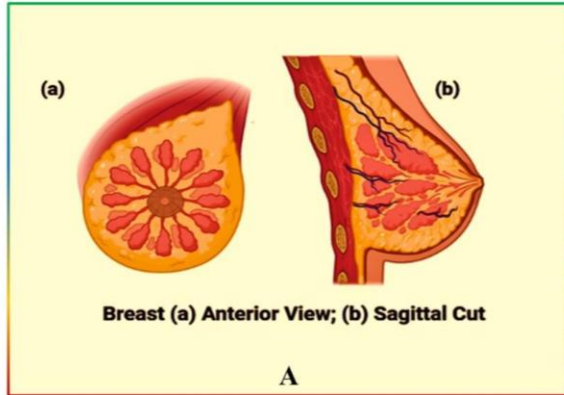
UNDER PEER REVIEW

Table 2: Natural foods and their primary anti-breast cancer potent ingredients

| Cereals | | | | |
|-----------------|--------------------------------------|----------------------|--|------|
| Natural Product | Constituents | Study Type | Main Effect and Possible Mechanism | REF |
| Sorghum | Extracts | in vivo | promoting cell cycle arrest, suppressing tumour growth and metastasis | [12] |
| | 3-deoxyanthocyanin | in vitro | promoting apoptosis by downregulating the Bcl-2 gene and up regulating the p53 gene | [13] |
| Barley | Extracts | in vivo and in vitro | exerting pro-apoptotic activities and anti-proliferative | [14] |
| Wheat | germinated wheat flour | in vitro | promoting growth and induce apoptosis | [15] |
| Fruits | | | | |
| Natural Product | Constituents | Study Type | Main Effect and Possible Mechanism | REF |
| Pomegranate | luteolin, punicic acid, ellagic acid | in vitro | increases adhesion and decreases migration of breast cancer cells and inhibits growth | [16] |
| Mangosteen | α -mangostin | in vitro | Prohibits apoptosis and lower the expression of pS2 and ER alpha | [17] |
| Mangosteen | α -mangostin | in vitro | induces apoptosis via modulating MAPK and HER2/PI3K/Akt signalling pathways | [18] |
| Citrus fruit | Hesperidin | in vitro | anti-proliferative effect is seen | [19] |
| Citrus fruit | Naringin | in vitro | suppress growth potential by heading β -catenin pathway | [19] |
| | | in vivo | prohibiting cell proliferation and promoting G1 cycle arrest and cell apoptosis through inflect β -catenin pathway | [19] |
| Apple | pectic acid | in vitro | induces apoptosis and suppress cell growth | [20] |
| | | in vivo | hinders tumor metastasis in mice through over-expression of P53 | [20] |
| Grape | Anthocyanin | in vitro | Through inhibiting the expression of Snail it decreases invasion, migration and bone turnover and phosphorylated STAT3 | [21] |
| Jujube | triterpenic acids | in vitro | Prohibits apoptotic cell death | [22] |
| Grape | amurensin G | | Suppresses VEGF production | [23] |
| Mango | pyrogallol | In vitro | Suppressing proliferation through arbitrating the AKT/mTOR signaling pathway | [24] |
| Cranberry | NA | In vitro | Inducing apoptosis & G1 phase arrest | [9] |

Table 2: Natural foods and their primary anti-breast cancer potent ingredients

UNDER PEER REVIEW



B

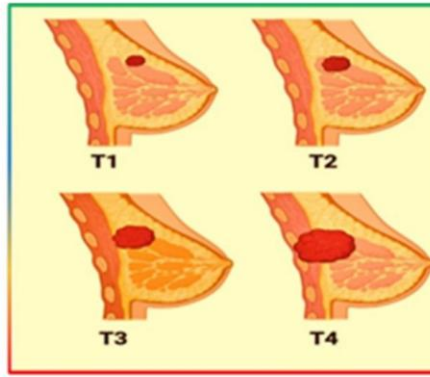


Figure 1: [A]Anterior view and Sagittal cut of breast a. Anterior view and b; [B] Breast cancer anterior view.

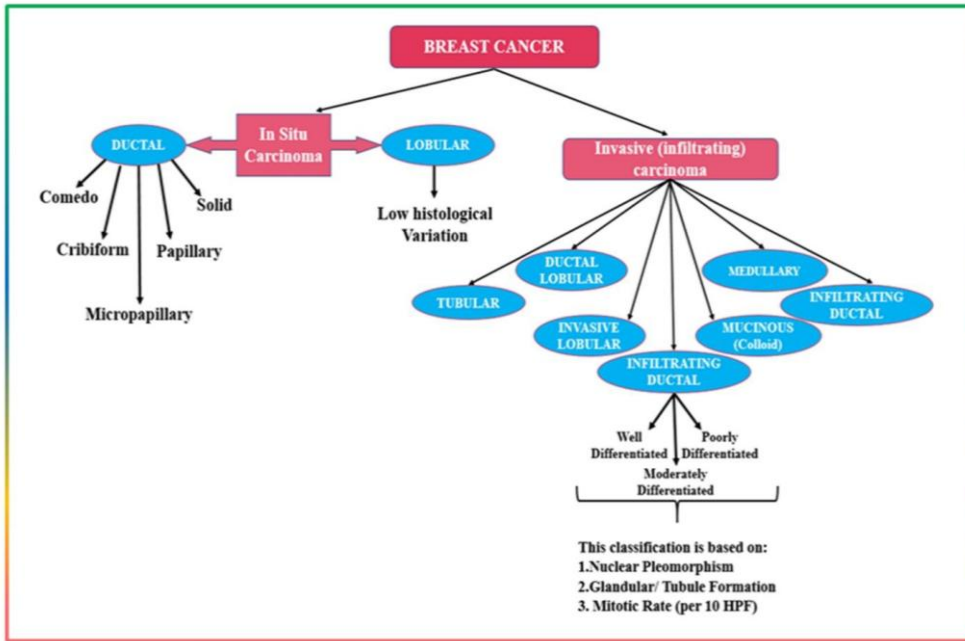


Figure 2: Stages of tumor progression

UNDER REVIEW

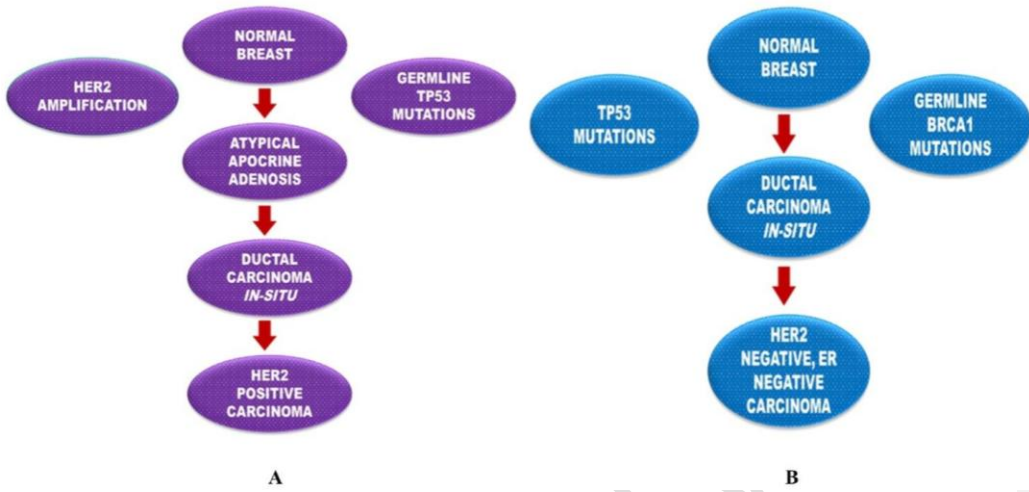


Figure 3: [A] HER2 Positive carcinoma developmental pathway; [B] HER2 negative and ER-negative carcinoma developmental pathway

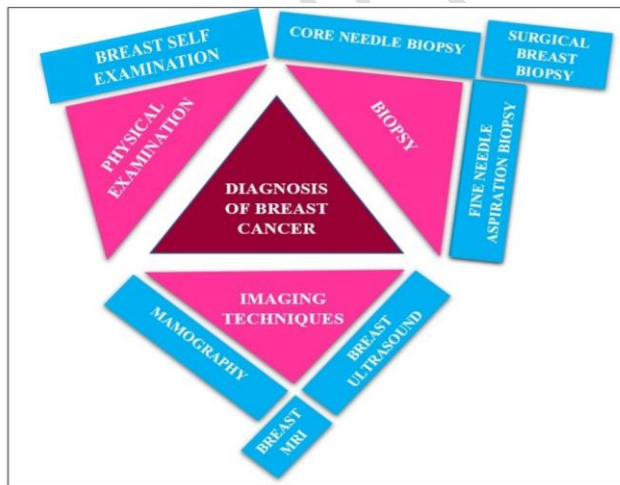


Figure 4: Diagnostics for breast cancer

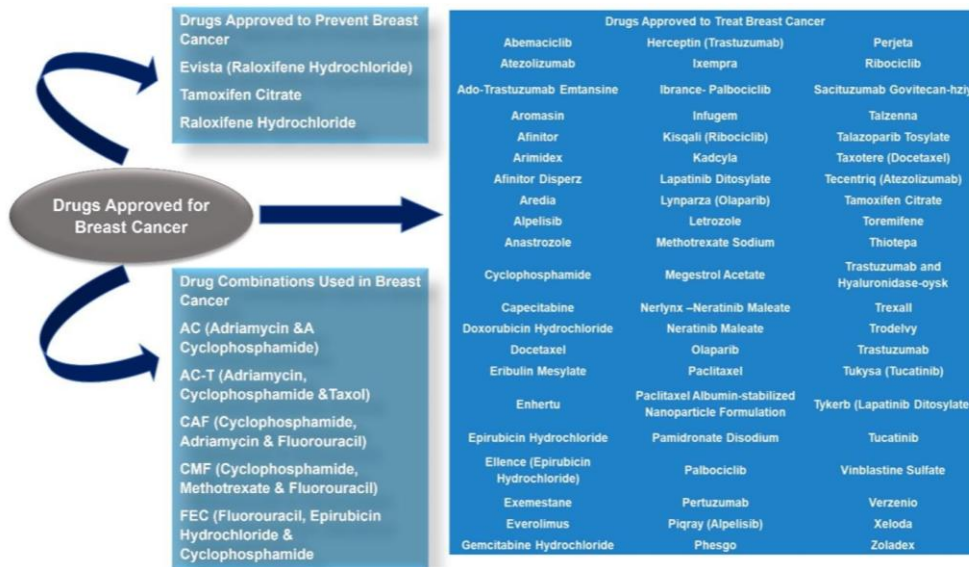


Figure 5: Drugs approved by FDA against Breast cancer

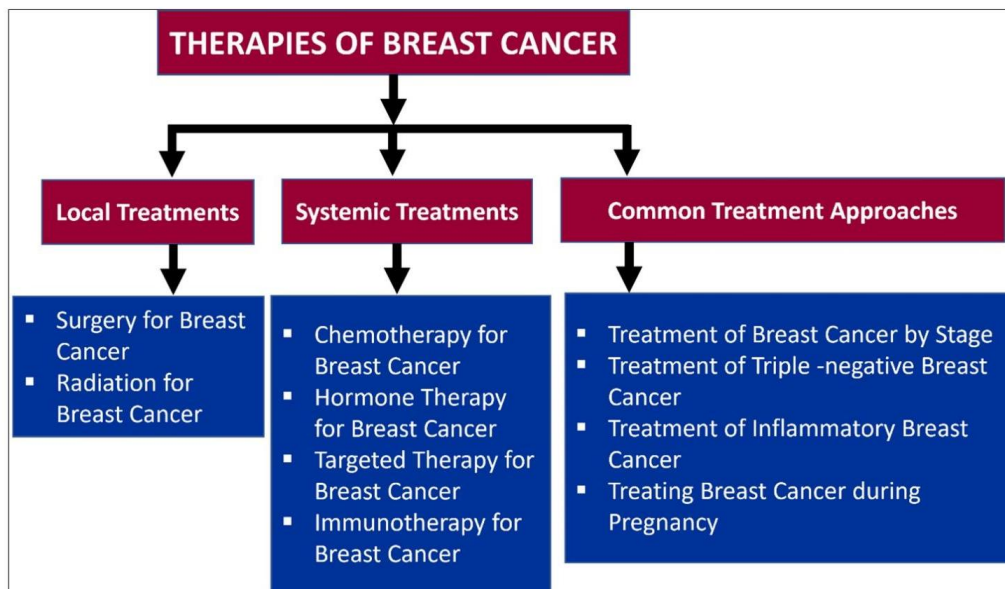


Figure 6: Therapeutics for Breast cancer