

Original Research Article

Long Term Results of Core Decompression as an Alternative to Total Hip Arthroplasty in Avascular Necrosis of Femoral Head

ABSTRACT

Aims: To assess the long-term outcomes of Core decompression, progression in the stage of avascular necrosis and requirement of Total Hip Replacement following core decompression of Femoral head.

Study design: Bidirectional observational study.

Place and Duration of Study: Department of Orthopaedics, Medical College Hospital, Thiruvananthapuram between January 2016 to December 2019.

Methodology: We included 89 hips in 51 patients (33 men, 18 women) who underwent Core decompression for Avascular Necrosis of Femoral Head. Pre operative evaluation using hospital records and post operative evaluation using Harris Hip score was done. The disease was classified according to Ficat staging system.

Results: Out of 89 hips, 24 showed radiological progression at 09-month followup and 42 hips showed progression at 03 years. 17 hips had to undergo Total Hip replacement at 03 years. There were no major complications. 12 Hips had excellent score, 53 Hips had good score, 5 hips had Fair score and 19 hips showed poor score at the end of follow up.

Conclusion: The procedure is highly recommended in stage 1 disease as the statistical analysis shows significant improvement in hip scores. Clinical results of core decompression surgery are very encouraging in stage 1 and stage 2 of the disease; but not so favorable if done in stage 3.

Keywords: Avascular Necrosis, Core decompression, Total Hip Replacement, Harris Hip score

1. INTRODUCTION

Avascular necrosis is the death of tissues due to lack of blood supply. It is also called osteonecrosis when pertaining to bones [1]. Head of femur is one of the common sites for

avascular necrosis. Avascular necrosis of head of femur can occur following trauma or without any history of trauma [2]. Avascular necrosis of head of femur, especially non traumatic etiology, has insidious onset often leading to delay in diagnosis and treatment. Patients often complain of non-specific pain or discomfort during movements of hip which slowly progresses to severe disabling pain and total inability to ambulate as the disease reaches advanced stages [3].

Even though the causative factor for avascular necrosis of femoral head is not clear, it is postulated that any mechanical, physical, pharmaceutical or hereditary insult to the already precarious blood flow to certain predisposed bones (femoral head) can lead to a cascade of events which results in osteonecrosis [4]. Avascular necrosis of hip is more common among young individuals affecting the daily activities of the productive fraction of the community [5]. Avascular necrosis is usually diagnosed clinically along with radiological evidence in X-rays, MRI etc. Harris hip score helps in finding functional improvements following surgery.

The treatment modalities aim at reducing the disease morbidity by halting the disease progression and has been studied extensively and there are options available comprising of nonsurgical treatment and surgical treatment. There is minimal data on nonsurgical treatment when the condition is identified in the early stages. Activity modification with restricted weight bearing is often used for symptom relief but does not halt disease progression [5]. Pharmacologic and biophysical treatments like bisphosphonates, anticoagulants, vasodilators, statins, and biophysical modalities are still quite experimental in nature [6].

The most common surgical treatment is Core decompression for early-stage disease or total hip arthroplasty (THA) [1,4,9]. The ideal goal of early-stage treatment is to postpone or stop the progression of the disease before femoral head collapse. For patients with advanced stage, THA is a better choice with excellent outcomes in terms of pain relief and survivorship [4,8]. Despite the excellent survivorship of THA, young patients are most likely to experience loosening and revision in their lifetime [10].

Paul Ficat and Jaques Arlett investigated the disease in early 1960 and came up with the concept of functional exploration of the bone [7,10]. Core decompression was part of this process and it resulted in decrease in pain and halting of the radiological progression [12]. Core decompression is found to be more successful when done before the stage of structural failure before the mechanical failure of the subchondral bone and collapse femoral head. It is usually used in two instances- in the early stages of the disease to prevent progression of the disease and in advanced cases where risk for major procedures is high [13]. Core decompression of femoral head with or without cancellous bone grafting aims at removing the dead bone from the femoral head, fill the defect and allow new blood vessels to grow into the femoral head thereby halting the progression of disease entity and delay total hip replacement [14].

Blockage of the osseous microcirculation with intramedullary stasis appears to be present in the disease irrespective of the cause and starting point of the affliction. Osseous micro circulation blockage with intramedullary stasis can lead to increased pressure leading to metabolic disturbances causing anoxia and finally necrosis [15]. Core decompression breaks the vicious cycle by reducing the medullary hypertension. Pain is often released immediately with the breach of the outer cortex. Venous drainage is improved, thereby relieving the congestions within the tissue. Revascularisation of the femoral head is initiated through various complex pathways [16].

Core decompression results in hypervascularity of the entire joint, with vasodilatation and decalcification. The cortical foramina and the intramedullary sinusoids are decompressed, and the arterial spasm is relieved. The micro circulation is improved, and metabolic process is normalised [17]. Thus, core decompression may act at several levels to bring about a halt in the avascular necrosis of femoral head.

However, the eventual outcome and progression to THR remains controversial. It is also not clear whether core decompression alone is sufficient and efficient enough in all stages of AVN to prevent progression and delay the need for a THR [18]. There is also a dearth of literature about the long-term efficacy of the procedure especially in the Indian population. This study was made to assess the long-term outcomes of core decompression, progression in stage of avascular necrosis and requirement of THR following core decompression of the femoral head.

2. MATERIAL AND METHODS

This was a bidirectional observational study of the functional outcome and safety of core decompression surgery in avascular necrosis of head of femur, done from Dec 2022 to Aug 2023. All patients of AVN hip who underwent Core decompression at Department of Orthopaedics, Medical College Hospital, Thiruvananthapuram between January 2016 to Dec 2019 were contacted and requested to participate in the study. Individuals who were diagnosed with AVN of femoral head (unilateral and bilateral) and underwent core decompression with a minimum of three years since core decompression who consented to be a part of this study (including permission to use previous records and present for clinico-radiological exam) were included as study population. Patients unwilling to consent to the study or unable to present for current status examination or had core decompression less than two years ago were excluded.

Out of 83 patients who underwent core decompression, 51 patients (38 patients with bilateral hip surgery and 13 patients with unilateral hip surgery) agreed to be a part of study. A total of 89 hips were included in the study but, preoperative and post operative data was obtained from hospital records and present clinico-radiological data was obtained by the authors physically.

The data obtained from hospital records consisted of pre op evaluation and Harris hip score. Post op the patients were followed up monthly for the first three months and then every three months. At every quarterly review, patients were interviewed regarding the pain relief, clinical evaluation done, and the Harris hip score was assessed. AP and frog leg lateral view radiograph of hip were taken, and the radiographic stage was assessed. All patients included had minimum of 3 years post core decompression surgery. In bilateral patients, the time period from hip which was operated later was considered.

The result of treatment was assessed by noting the preoperative, post operative and current pain relief status, Harris hip score, stage of the disease from the radiographs. Timing from core decompression and further surgery due to the progression of the disease time and procedure were also noted. In the entire study, the disease was classified according to Ficat staging system (1985).

Peri Operative Evaluation and Procedural Details

All patients were clinically examined, Harris hip score was assessed . AP and frog leg lateral view radiograph of hip were taken and the radiographic stage was assessed as per Ficats system. After pre anaesthetic evaluation, patients were listed for surgery as a elective procedure and performed by one of two surgeons.

The procedure was performed with the patient positioned on a fracture table. Through a short lateral midline incision, the fascia lata was sectioned and the vastus lateralis muscle was bluntly divided along the direction of its fibers in order to achieve sub periosteal exposure of the lateral aspect of the proximal femur. Small drill hole was made in the mid lateral cortex where the bone begins to flare laterally. Under image intensifier, an entry hole was drilled, and a guide wire is passed into the depth of the subchondral bone in the centre of the lesion near the superolateral corner of the femoral head, taking care not to perforate the joint. A cannulated drill was advanced over the guide wire taking care not to penetrate the joint.

A reamer of 12 mm diameter was introduced over the guide wire under guide of image intensification and a core track was reamed up to about 5 mm of the articular cartilage and core of the necrotic bone was removed using curved long scoop. Into the core decompression tract, cancellous bone harvested from iliac bone was packed in and impacted inside. All wounds were closed in layers. Post operatively weight bearing was not allowed for three months. Patients were given a crutch and in bilateral cases, swing through gait was advised.

Statistical Evaluation

All evaluation was done using SPSS.

A paired T test was done to assess the statistical significance of the difference in the scores stage wise. Method used by Anton Y P et al [8] was used to grade the results. The result was regarded as excellent if the hip score was from 91 -100; good between 81-90; fair between 71-80 and poor if less than 70.

Analysis was done by grouping the results according to the stage and comparing the improvement or worsening within the same stage. The radiographic progression to next stage and further surgery required within the follow up period was also noted. The clinical progression was compared and correlated.

3. RESULTS

Demographic Profile

The mean age of the patients in this study is 37 years (+/- 11.6). The oldest patient in this study is 63 years old and the youngest patient is 22 years old. Significant majority of patients were found to be in the third and fourth decade. 33 of the 51 patients (64.7%) were male. Majority of patients with bilateral disease were also male. No significant difference was found inside of affected limb.

Among the risk factors which were identified on interviewing the patient, a majority of the patients did not elicit any significant history and were classified as idiopathic AVN. (Table 1)

Table1: Percentage distribution of the sample according to risk factors

Risk factors	Count	Percent
Idiopathic	29	32.6
Alcohol	20	22.5
Renal disease	9	10.1
SLE	9	10.1
Trauma	7	7.9
Alcohol, Steroid	6	6.7
Asthma, Steroid	4	4.5
SLE, Steroid	3	3.4
Steroid, SLE, APLA	2	2.2
Total	89	100

Pre op retrieved data regarding staging of AVN revealed 10 hips in stage 1, 61 hips in stage 2, 18 hips in stage 3. (Table 2)

Table 2 : Percentage distribution of the sample according to stage

Stage	Count	Percent
FICAT 1	10	11.4
FICAT 2	61	68.2
FICAT 3	18	20.5

Harris hip score was used to evaluate functional status of the patient. A score of > 90 was termed excellent, 81-90 score was termed good, score 71-80 was fair and score <70 was termed poor. Based on the retrieved documents in the preoperative Harris hip score, 3-month score and 9-month score were recorded. The current score was evaluated when patient presented during the study period by one of the authors. The recorded score as presented below as table. The one-sided t-test was used to calculate the significance (p value) in the change in proportion of scores from the pre op scores.

The final followup hip score from retrieved data (taken between 9-12 months of followup for all patients) revealed 12 hips with excellent scores, 53 hips with good, 5 hips with fair and 19 hips with poor scores. The current evaluation of patients (after a minimum of 2 years after surgery) Harris Hip Score showed 6 patients with excellent, 31 patients with good, 29 with fair and 23 patients with poor scores. (Table 3)

Table 3: Distribution of HIP score

HIP score	Pre-Op		> 3m Post Op			> 9m Post op			> 3y Post Op		
	No	%	No	%	p value	No	%	p value	No	%	p value
Poor	23	25.8	18	20.3	0.36	19	21.3	0.38	23	25.8	0.50
Fair	48	53.9	14	15.7	0.01	6	6.7	0.00	29	32.6	0.02
Good	18	20.3	49	55.1	0.05	53	59.6	0.05	31	34.9	0.04
Excellent	0	0.0	8	8.9	0.00	11	12.4	0.00	6	6.7	0.00

The comparison of mean Harris Hip scores and comparative significance with the paired t test is given in table. (Table 4)

Table 4 : Evaluation of HIP score

HIP Score	Mean	SD	N	Mean Difference	Paired t	p
-----------	------	----	---	-----------------	----------	---

Pre OP > 3m Post OP	74.44 80.30	6.78 9.19	89 89	5.86	4.84	<0.0001
Pre OP > 9m Post OP	74.44 81.29	6.78 9.58	89 89	6.85	5.51	<0.0001
Pre OP > 3y Post OP	74.44 77.25	6.78 9.14	89 89	2.81	2.33	<0.0210
> 3m Post OP > 9m Post OP	80.30 81.29	9.19 9.58	89 89	0.99	0.70	<0.4838
> 9m Post OP > 3y Post OP	81.29 77.25	9.58 9.14	89 89	-4.04	-2.89	<0.0045

** : - Significant at 0.05 level

Out of the total 89 hips under study, 24 hips showed radiological progression of hip disease at evaluation after 9 months and 42 hips at evaluation after 3 years. Stage wise proportionate analysis is as table 5.

Table 5: Percentage distribution of the sample according to stage

Stage			> 3m Post Op			> 9m Post op			> 3y Post Op		
	No	%	No	%	p-value	No	%	p-value	No	%	p-value
FICAT 1	10	11.2	10	11.2	0.5	10	11.2	0.5	09	10.1	0.48
FICAT 2	61	68.6	59	66.3	0.39	47	52.8	0.04	32	40.0	0.002
FICAT 3	18	20.2	20	22.5	0.41	24	27.0	0.26	33	37.1	0.19
FICAT 4	00	0.0	00	0.0	-	08 [#]	9.0	0.03	15 [*]	16.8	0.05

[#] 05 hips underwent THA within 9 months. * 17 hips underwent THA within 3 years.

17 out of the 89 hips (19.10%) and 15 out of 51 patients (29.41%) had to undergo THA by the end of 3 years from core decompression. A significant proportion in hip requiring THA(**p=0.043**) and patients proportion requiring THA(**p=0.046**) compared to total. Figure 1. This constituted 8 patients with unilateral disease, 5 patients with bilateral AVN with one hip requiring THA and 2 patient requiring bilateral THA. Out of these 10 patients were initially in FICAT Stage 3 and one patient was in FICAT Stage 2 at pre op evaluation.

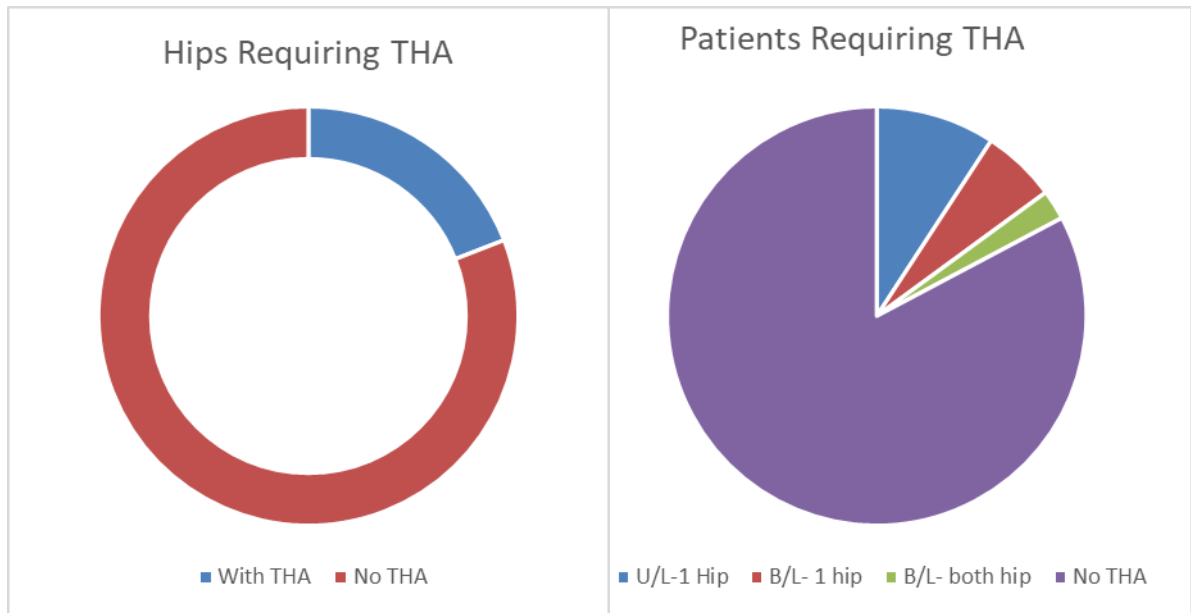


Figure 1 ;Hips and Patients requiring THA

Majority of patients did not show any complications after undergoing this procedure. 4 patients had complaints of deep vein thrombosis and 1 patient, who was a known case of renal disease, required further hemodialysis due to worsening renal parameters. (Table 6)

Table 6 : Percentage distribution of the sample according to complications

Complications	Count	Percent
No	84	94.4
Deep vein thrombosis	4	4.5
Hemodialysis	1	1.1

4. DISCUSSION

Avascular necrosis of the head of femur is a relentlessly progressing condition with an unclear etiology and multiple risk factors affecting young age group patients. In our study, the mean age was 37 years; youngest patient being 22 years old and the eldest being 63 years old. There were no significant differences with severity of disease related to age, however, more than half the patients in the study were under the age of 40 years. As 38 patients out of the 51 patients were in the age group of 20-40 years; primary joint replacement surgery would not be a satisfactory option in restoring them to normal activities as well as the complications of wear and tear and further revision surgery looms. Therefore, surgery in form of core decompression was a good option being relatively simple, reliable and cost-effective procedure.

Significantly higher percentage (64.7%) of patient in the study group were Male. All the patients with bilateral hip disease were also found to be male. One reason for this may be the consumption of alcohol which was found to be a major risk factor. All 7 patients with post traumatic AVN were also male. This leads us to conclude that males are more susceptible to AVN of femoral head especially if they consume alcohol. Other patients were under follow up for the risk factors like pancreatitis, SLE, renal diseases, malignancy etc with the respective specialities and hence, presented to our department relatively early in the disease process. No significant conclusion could be drawn for etiological causes of AVN.

As providing symptomatic relief and improvement of functionality are among the main objectives of this study the Harris Hip score was used to assess the patient. The first method of comparison used division of patients into groups based on the score the higher being the better score. A score of > 90 was termed excellent, 81-90 score was termed good, score 71-80 was fair and score <70 was termed poor. There was a significant increase in hips with Good (81-90) and Excellent (>90) scores at 3 months, 9 months and 3-year evaluation. Conversely, there was a significant decrease in number of hips with Fair score (71-90) in the 3 months, 9 months and at 3 years evaluation. However, it was observed that no significant change was observed in number of hips with poor score (<70) at 3 months, 9 months and even at 3 years compared to pre op figures. It can be inferred that though core decompression improved functionality in patients with atleast a fair score (70 and above) patients with poor functional pre op score (<70) do not benefit from core decompression and can be used as contraindication to this surgery.

Another method used was the comparison of mean Harris Hip score at pre op and follow up at 3 months, 9 months and one year. Comparison was made between each follow up mean score with mean pre op score and also with preceding score like 3 months vs 9 months or 9 months vs 3 years. The hips under this study have shown an overall improvement in the Harris hip score as the mean of the scores increased from 74.4 preoperative hip to 80.3 at 3 months and 81.3 at 9 months in the post operative Harris hip score. There was a decrease in mean Harris hip score to 77.3 in the final followup at 3 years, however, it was still significantly higher than the pre op score. There was no significant difference between 3 and 9 months but there was a significant decrease in score after 9 months. It is inferred that core decompression provides an improvement in the Mean Harris hip score which increase progressively for the first 9-12 months post which there is steady decline in mean functional score. This decrease however does not lower to the pre op mean score at 3 years. Using linear approximation, it can be predicted that the mean score will fall below pre op mean at approximately around 5-7 years on an average.

In our study, we used the radiological classification by Ficat & Arlett to stage the hips, as it was feasible in socioeconomic group of patients. There was no significant change in the number of hips classified as FICAT stage 1 over the entire study period. Similarly, there was no significant change in the number of hips in FICAT 3. However, there was a significant decrease in number of hips in FICAT stage 2 and significant increase in number of hips in FICAT 4. It can be interpreted that there was no progression of disease in the FICAT 1 stage, there was a progressive worsening of FICAT stage 2 and 3 hips with time causing the simultaneous increase in FICAT 4 and maintain the number in FICAT stage 3.

Our study had a 29.41% hips patient had conversion to THA which corresponds to 38% reported by a large metanalysis by Andronic and Weiss Et Al in 2021[18]. In the long term follow up result published by Fairbank and Bhatia [19] of core decompression alone, showed that the 5 year, 10 and 15 years survival rates for the hip in three stages were between 90-100% in stage 1, 65-85% in stage 2 and 23-58% in stage 3. Despite the generally satisfactory clinical results, 56% of the hips had progressed radiologically by at least by one Ficat stage in that stage. Our study follow up averages only 43.7 months, with maximum follow up for 4.5 year and minimum of 3 years. The fact that all the stage 1, 46 hips of stage 2 and 8 hips of the stage 3 disease showed clinical improvement suggests that core decompression and cancellous graft does give symptomatic improvement, slows the radiological progression and delays the need for joint replacement surgery.

5. CONCLUSION

Avascular necrosis of femoral head is common in young adults of both sexes and is a relentlessly progressive condition, if not detected and treated early, usually progresses to arthritis requiring total hip replacement. Therefore, the objectives of treatment are to detect the disease as early as possible, especially in those patients with risk factors for avascular necrosis exists, to retard or reverse the disease process to delay joint replacement surgery and to provide symptomatic relief to the patient. Arthroplasty has the disadvantage of not been compatible with the active lifestyle of the young patients. Therefore, the head preserving surgery is given priority to delay the total hip replacement surgery [20]. Among the head preserving procedures, core decompression assumes an even more important role in Indian setting as it is a simple cost-effective procedure if the pathology is detected early. Core decompression requires only a small incision, short surgical time and brief hospitalization. It does not interfere with further surgery, like hip replacement.

In our study, all the patients in any stage of the disease had symptomatic relief following the procedure. The procedure is highly recommended in stage 1 disease as the statistical analysis shows significant improvement in hip scores and minimal of the stage 1 patients undergoing core decompression had disease progression during the follow up period. Clinical results of core decompression surgery are very encouraging in stage 1 and stage 2 of the disease; but not so favorable if done in stage 3. We recommend the procedure in stage 1 and stage 2 disease as it affords symptom relief, slows the progression of the disease and delays total hip replacement. Stage 3 hip diseases progresses in spite of the surgery. However, more number of cases in stage 3 is needed before it can be confirmed statistically.

CONSENT (WHEREEVER APPLICABLE)

"All authors declare that 'written informed consent was obtained from the patients for publication of this case report and accompanying images. A copy of the written consent is available for review by the Editorial office/Chief Editor/Editorial Board members of this journal."

ETHICAL APPROVAL

Ethical Committee Approval taken from Trivandrum Medical College Ethical Committee.

REFERENCES

1. Mont MA, Cherian JJ, Sierra RJ, Jones LC, Lieberman JR. Nontraumatic Osteonecrosis of the Femoral Head: Where Do We Stand Today? A Ten-Year Update. *J Bone Joint Surg Am.* 2015;97:1604–1627.
2. Aaron RK , Lennox D, Bunce GE, Ebert T ; The conservative treatment of osteonecrosis of the femoral head. A comparison of core decompression and pulsing electromagnetic fields. *Clin Orthop* 249:209-218, 1989
3. Anita N. Scribner, Paolo V, Troia-Cancio, Bruce A. Cox, David Marcantonio, Osteonecrosis in HIV: A Case-Control Study *JAIDS Journal of Acquired Immune Deficiency Syndromes* 25:19-25 2000 Lippincott Williams And Wilkins, Inc, Philadelphia
4. Banerjee S, Issa K, Pivec R, Kapadia BH, Khanuja HS, Mont MA. Osteonecrosis of the hip: treatment options and outcomes. *Orthop Clin North Am.* 2013;44:463–476.
5. Mont MA, Carbone JJ, Fairbank AC. Core decompression versus nonoperative management for osteonecrosis of the hip. *Clin Orthop Relat Res.* 1996;324:169–178.
6. Mont MA, Zywił MG, Marker DR, McGrath MS, Delanois RE. The natural history of untreated asymptomatic osteonecrosis of the femoral head: a systematic literature review. *J Bone Joint Surg Am.* 2010;92:2165–2170.
7. Arlot ME, Bonican M, Charasioux PA, et al: Bone histology in adults with aseptic necrosis. *J Bone joint Surgery* 65A:1314, 1983
8. Anton YP, Shin Yoon Kim: Vascularised compared with non vascularised fibular grafting for treatment of osteonecrosis of femoral head: *J bone joint Surg*, Vol 85A, Number 4, April 2003
9. Zhao DW, Hu YC. Chinese experts' consensus on the diagnosis and treatment of osteonecrosis of the femoral head in adults. *Orthop Surg.* 2012;4:125–130.
10. Chandler HP, Reineck FT, Wixson RL, McCarthy JC: Total hip replacement in patients younger than thirty years old. A five year follow up study. *J Bone Joint Surgery* 63A 1980.

11. Bakshi DP: Treatment of post traumatic avascular necrosis of femoral head by multiple drilling and muscle pedicle bone grafting. A preliminary report. -J Bone Joint Surgery 65B, 1983
12. Boettcher WG, Bonfiglio M, Smith K: Non traumatic necrosis of the femoral head. Part 2. Experiences in treatment. J Bone Joint Surgery 52A:322-329, 1970
13. Bonfiglio M, Voke EM: Aseptic necrosis of femoral head and non union of femoral neck. Effect of treatment by drilling and bone grafting (Phemister technique) J Bone Joint Surgery 50A, 1968
14. Pierce TP, Jauregui JJ, Elmallah RK, Lavernia CJ, Mont MA, Nace J. A current review of core decompression in the treatment of osteonecrosis of the femoral head. *Curr Rev Musculoskelet Med.* 2015;8:228–232.
15. Buckley PD, Gearen PF, Petty RW: Structural bone grafting for early atraumatic avascular necrosis of the femoral head. J Bone Joint Surgery 73A:1357-1364, 1991.
16. Camp JF, Colwell CW : Core decompression of the femoral head for osteonecrosis. J Bone Joint Surgery 68A:1313, 1986.
17. Dorr LD, Takei GK, Conaty JP: Total hip arthroplasty in patients less than forty five years old. J Bone Joint Surgery 65A:474-479, 1983.
18. Andronic, O., Weiss, O., Shoman, H. *et al.* What are the outcomes of core decompression without augmentation in patients with nontraumatic osteonecrosis of the femoral head?. *International Orthopaedics (SICOT)* 45, 605–613 (2021).
19. Fairbank AC, Bhatia D, Jinnah RH, Hungerford DS,: Long term results of core decompression for ischemic necrosis of the femoral head. J Bone Joint Surgery 77B:42-49. 1995.
20. Ficat RP, Arlett J: Functional investigation of bone under normal conditions. In Hungerford DS (ed). Ischemia and necrosis of bone. Baltimore, Williams and Wilkins 29-52, 1980.