

A prepubertal giant juvenile fibroadenoma: casereport and brief literature review

ABSTRACT

INTRODUCTION: Giant juvenile fibroadenomas represent 0.5% of all fibroadenomas, constituting a rare condition in the adolescent age group. In prepuberty, the presence of this condition is extremely rare.

CASE PRESENTATION: We describe a rare case of a 12-year-old girl who presented to our hospital with a rapidly enlarging palpable mass in her left breast that she first noticed 2 months ago. She has not attained menarche yet. Physical examination shows a giant mass of approximately 12 cm in the left breast. The patient was further evaluated via ultrasonography showing a sole large lesion of 12 × 8 cm in the left breast. A surgical excision under general anaesthesia was performed. Histopathological findings post-surgery were suggestive of a giant juvenile fibroadenoma. Patient is on regular follow-up with no signs of recurrence.

CONCLUSION: Giant juvenile fibroadenomas should be included as a differential diagnosis in prepubertal girls with a breast mass. Even though they are very rare in prepuberty, they tend to have a great psychological impact. The treatment should aim at early complete surgical excision and good cosmesis.

Keywords: *Juvenile Fibroadenoma, Giant Fibroadenoma, Prepubertal Fibroadenoma*

Abbreviations: *cm - centimeters, gm - grams*

1. INTRODUCTION

Breast masses in adolescence are uncommon. Although most of the breast masses in paediatric patients are benign, the presence of any breast mass frequently raises parental concerns of a potential cancer. Fibroadenoma is the most common benign tumour in adolescent girls and young women, followed by fibrocystic disease⁽¹⁾. Juvenile fibroadenoma is a rare variant of fibroadenoma occurring at ages between 10 and 18 years. Although reports have been found in children as young as 9 years old and as old as 25 years old. In fact, a juvenile fibroadenoma has been reported in an infant as young as 3 weeks old⁽²⁾. The presentation can be very dramatic and mimic malignancy as it is usually rapidly enlarging and can also cause disfiguring of the breast. Giant juvenile fibroadenoma is one of the rarer clinical findings in adolescent females which represents 0.5% of all fibroadenomas. A juvenile fibroadenoma is further called 'giant' when it is greater than 5 cm, more than 500 g or replaces more than 80% of the breast⁽³⁾. We report a case of giant juvenile fibroadenoma in a 12-year-old prepubertal girl.

2. CASE PRESENTATION

A 12-year-old girl presented with history of rapidly enlarging left breast over the past 2 months with no history of pain, trauma, fever, nipple discharge, oestrogen supplementation or irradiation exposure. She has not attained menarche yet and there is no significant medical or family history contributing to the same. She had normal physical, mental, and sexual development with no findings suggestive of hormonal or sexual abnormality. On examination, left breast was enlarged with a single palpable mass of size 12 x 8 cm, well defined, firm, non-tender, mobile, not fixed to overlying skin and chest wall. Contralateral breast appeared normal. No axillary lymphadenopathy was noted, and rest of the systemic examination was normal. She was in Tanner stage II of sexual

development. The patient was further evaluated with breast ultrasonography which showed a large lobulated hypoechoic lesion in the left breast parenchyma measuring about 12 x 8 x 5 cm. Core needle biopsy of the breast mass was performed which was suggestive of a benign fibro-epithelial tumour with no evidence of malignancy. After counselling the patient and parents, complete surgical excision of the left breast mass which was almost replacing the entire breast was done with an inframammary crease incision preserving the nipple areolar complex. The mass weighed 750 grams. On gross examination, there was single well circumscribed mass measuring 14 x 11 x 8 cm. On histopathological examination, the cut surface of the lump was tan coloured, firm with myxoid areas, and no areas of haemorrhages or necrosis. Histopathology showed uniform stromal cellularity with focal epithelial hyperplasia, without nuclear atypia or necrosis. All features were suggestive of a Giant Juvenile fibroadenoma. A breast conserving surgery was done on the girl with nicely hidden scar on the inframammary crease and is on regular follow-up with no signs of recurrence.

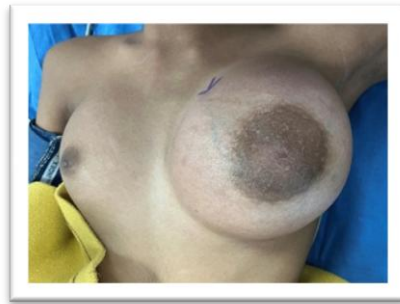

Figure 1 – Preoperative image of the breast

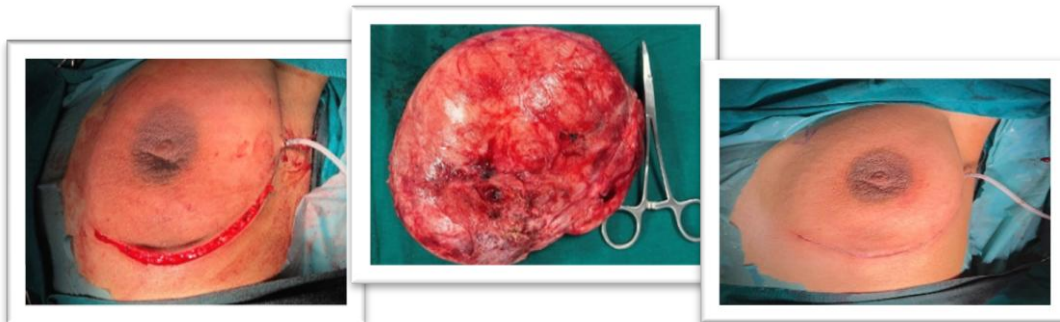


Figure 2

– Intraoperative images of the mass and postoperative images of the breast (Excision of mass with inframammary crease incision preserving the nipple areolar complex)

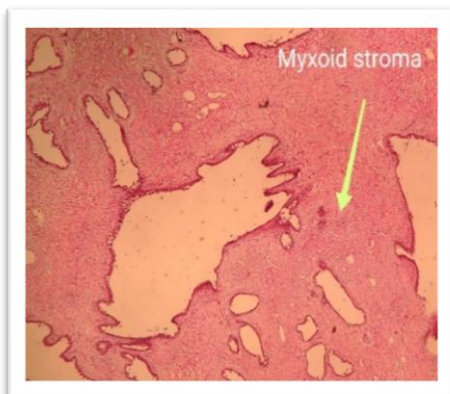


Figure 3a (10x)

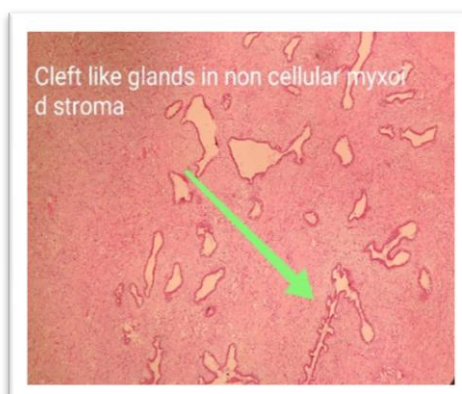

Figure 3b

Figure 3a (magnification 10x),3b (magnification 4x)– Histopathological images after haematoxylin-eosin stain; Juvenile fibroadenoma is characterized by stromal cellularity, epithelial hyperplasia and more often by pericanalicular architecture.

3.DISCUSSION

“Fibroadenomas are among the most common breast tumours with its peak incidence in women in their second and third decades of life. It is a benign condition with a prevalence of 2.2% in this age group”⁽⁴⁾. “Fibroadenomas are usually unilateral, and they frequently occur in the upper outer quadrant and vary in size from less than 1 cm to 20 cm. Fibroadenomas are divided into simple fibroadenoma, juvenile fibroadenoma and multicentric fibroadenomas”⁽⁵⁾. “The Juvenile type is limited to ages between 10 to 18 years. They are characterized by more cellular histology and rapid growth. These lesions are not known to carry any higher of a risk of malignancy. Giant juvenile fibroadenoma is a rare, encapsulated variant which is defined as size more than 5 cm, weighs more than 500 gm, or displaces at least four fifth area of the breast. The overall incidence of giant fibroadenoma is approximately 0.5%-2% of fibroadenomas and is found to be more common in African American adolescents”⁽⁶⁾. “It is the most common cause of unilateral macromastia in younger age groups”⁽⁷⁾. “Our patient had large breast mass of size approximately 14 cm, weighing 750gm and displaced almost entire breast. The exact aetiology of giant juvenile fibroadenomas is unknown, but it is assumed to be an abnormal response to oestrogen, as evidenced by their increased frequency during puberty or responsiveness to pregnancy, oral contraceptives, or cyclic hormones”⁽⁸⁾. “The main differentials for giant juvenile fibroadenoma include cysto-phyllodes tumours, lipomas, and virginal hypertrophy. Other rare differentials are hamartoma, pseudo angiomatous stromal hyperplasia, adenocarcinoma. Giant lesions have the potential to disfigure the breast and hence may raise fears in the patient or her family of malignancy. These tumours may also cause concerns about breast development and body image. Appropriate investigation, communication and counselling are important to address such concerns as most of these lesions are benign. The risk of malignancy is thought to be less than 3%. The size of giant fibroadenoma varies from 5cm to 23cm, with a mean lesion size of 11.2cm”⁽⁹⁾.

“In adolescents, breast ultrasound is considered the most effective diagnostic tool due to breast tissue density. The most common sonographic feature of juvenile fibroadenoma is a well-circumscribed round to oval solid mass, with weak internal echoes in a uniform distribution and intermediate acoustic attenuation and hypervascularity in colour dopplersonography”⁽¹⁰⁾. “The use of mammograms in young females has widely been documented to be of limited value due to increased breast density, and utility is limited due to poor image quality in younger patients as well as the extremely low risk of malignancy”⁽¹¹⁾. Magnetic resonance imaging (MRI), even though it is not the first tool in the diagnosis of such cases, may be used in selected cases. From the traditional Ultrasonography and mammography to the sophisticated contrast enhanced MRI's have not been shown to differentiate between a fibroadenoma and a cysto-phyllodes tumour. Hence Tissue diagnosis using a Core Needle Biopsy (CNB) is a reliable, simple, reproducible, and **lesser expensive** technique to obtain a pre-operative diagnosis and plan the surgical approach and its prognostic implications⁽¹²⁻¹³⁾.

“The goal of treatment is complete excision with good cosmetic results and preservation of as much as breast tissue as possible. This can be completed by simple excision and is aided by the encapsulation of the fibroadenoma. However, the surgical approach could be tricky as their massive size and architectural distortion can make for a difficult cosmetic outcome. A simple excision using an inframammary or peri-areolar approach without reconstructive plasty has shown good to excellent cosmetic results” as detailed by Hille-Betz et al⁽¹⁴⁾.

Approaches could vary from peri areolar, inframammary (Gaillard-Thomas), and inverted “T” incisions⁽¹⁵⁻¹⁷⁾. Surgeons must carefully plan the position of their incision to allow for complete tumour removal without unnecessary scarring. An axillary incision is taken by some, while some prefer acircum-areolar incision. A circum-areolar incision is proven to have the least visible scar but **invariably** leads to loss of sensation of the nipple. The inframammary approach is preferred in ptotic breast, but care should be taken as it violates the inferior pedicle. The inverted “T” incision is also preferred by some as

it provides excellent exposure for removal of any breast mass while allowing for reduction or mastopexy if necessary.

Patient and parents/ guardians must be **counselled** adequately about the post-operative outcomes and with time skin elasticity is regained with adequate coverage of normal breast tissue as they are still undergoing puberty and development. "Mastectomy is reserved for unusual cases or recurrent giant fibroadenomas"⁽⁹⁾. Reconstruction should follow mastectomy, especially in young patients, to minimize the psychological trauma.

4. CONCLUSION

A giant juvenile fibroadenoma is a rare but known pathology found in adolescents and due to its large size prompt early counselling and intervention is required. Ultrasonography is the diagnostic tool used for lesion assessment, and they should be differentiated from phyllodes tumour pre-operatively by a confirmatory tissue biopsy. Surgery should be planned with an aim to attain complete tumour excision and good cosmesis. Adequate **counselling** owing to the age of the patient is of utmost importance and long term follow up is necessary as there are reports of recurrence of this tumour.

Ethical Approval:

As per international standard or university standards written ethical approval has been collected and preserved by the author(s).

Consent

As per international standards, parental written consent has been collected and preserved by the author(s).

8. REFERENCES

1. Valdes EK, Boolbol SK, Cohen JM, et al. Malignant transformation of a breast fibroadenoma to cystosarcomaphyllodes: case report and review of the literature. **Am Surg**. 2005;71:348–53.
2. West KW, Rescorla FJ, Scherer LR, 3rd, et al. Diagnosis and treatment of symptomatic breast masses in the pediatric population. **J Pediatr Surg**. 1995;30:182-6.
3. Jayasinghe Y, Simmons PS. Fibroadenomas in adolescence. **Curr Opin Obstet Gynecol**. 2009;21(5):402-406.
4. Santen R, Mansel R. Benign breast disorders. *N Engl J Med* 2005; 353:275– 285.
5. Williamson ME, Lyons K, Hughes LE. Multiple fibroadenomas of the breast: a problem of uncertain incidence and management. **Ann R Coll Surg Engl**. 1993; 75(3): 161- 163.
6. Marchant DJ. Benign breast disease. *Obstet Gynecol Clin North Am* 2002;29:19–34
7. Lee M, Soltanian HT. Breast fibroadenomas in adolescents: current perspectives. **Adolesc Health Med Ther**. 2015; 6: 159- 163.
8. Agaoglu G, Ozgur F, Erk Y. Unilateral virginal breast hypertrophy. *Ann Plast Surg* 2000;45:451–53.
9. Sosin M., Pulcrano M., Feldman ED, et al. Giant juvenile fibroadenoma: a systematic review with diagnostic and treatment recommendations. **Gland Surg**. 2015 Aug;4(4):312–321.
10. Kim SJ, Park YM, Jung SJ, et al. Sonographic appearances of juvenile fibroadenoma of the breast. **J Ultrasound Med**. 2014;33:1879–84.
11. Simmons PS. Diagnostic considerations in breast disorders of children and adolescents. **Obstet Gynecol Clin North Am**. 1992;19(1):91-102.
12. Baral S, Gyawali M, Thapa N, et al. Giant juvenile fibroadenoma in an adolescent female: A case report. *Clin Case Rep*. 2020;8:3488–3492.

13. Samantaray Sagarika, Panda Niharika, Besra Kusumabati, et al. Utility of tru-cut biopsy of breast lesions – an experience in a regional cancer center of a developing country. *J. Clin. Diagn. Res.* 2017;**11**(March (3)):EC36–EC39.
14. Hille-Betz U, Klapdor R, Henseler H, et al. Treatment of giant fibroadenoma in young women: results after tumor excision without reconstructive surgery. *Geburtshilfe Frauenheilkd.* 2015;**75**(9):929-934.
15. Nambiar R, Kutty MK. Giant fibroadenoma in adolescent females—a clinicopathological study. *Br J Surg* 1974;**61**:113–17
16. Yamamoto Y, Sugihara T. Application of reduction mammoplasty in treatment of giant breast tumour. *Br J Plast Surg* 1998;**51**:109–12.
17. Ng WK, Mrad MA, Brown MH. Juvenile fibroadenoma of the breast: treatment and literature review. *Can J Plast Surg* 2011;**19**:105–7.

UNDER PEER REVIEW