

ANTIMALARIAL EFFECTS OF ETHANOL LEAF EXTRACTS OF *A.indica* AND *O.gratissimum*, AND THEIR HISTOLOGIC EFFECTS ON SOME ORGANS (LIVER, KIDNEY, AND HEART) OF *P.berghei* INFECTED ALBINO MICE

Abstract

Azadirachta indica (Neem) and *Ocimum gratissimum* (clove Basil) have long been employed locally for the management of malaria. The present study compared antimalarial activities of the ethanol leaf extracts of the individual plants, and also assessed their combined effects in malaria-infected mice. The leaves of the different plants were extracted with absolute ethanol (BDL 95%). Swiss albino mice were experimentally infected intraperitoneally with chloroquine-sensitive *Plasmodium berghei* NK65 strain. Parasitaemia level was determined before parasite inoculation and at 24 hours post treatment period. Histopathological study on the liver, kidney, and heart was carried out using the Paraffin Sections method. Extracts of the leaves were administered orally, while chloroquine administration was intramuscular. The efficacy of the leaf extracts was tested on the *P. berghei* infected albino mice using the 4-day curative test. Significant activity against the parasite was produced by infected mice treated with extracts of *A. indica* and *O. gratissimum*, and their combinations throughout the treatment period ($P < 0.05$). Highest reduction of parasitaemia levels was observed on day 4. Maximum parasitaemia reduction (78.65%) was attained with 30mg/kg of combined extracts on the day 7. Mild pathological lesions were observed in mice treated with *A. indica* leaf extract. These observations indicate better anti-malarial activity of the combination therapy as compared with the individual extracts of *A. indica* and *O. gratissimum* and indicate good antimalarial and protective roles of the plant extracts on the parasitized mice at large, as it slows down development of resistance.

Key Words: Malaria Treatment, Phytotherapy, Synergism of phytochemicals, Histology, Organs.

INTRODUCTION

Malaria is a disease caused by *Plasmodium* species and vectored by the female *Anopheles* mosquito (Sitaliet al., 2019; Sato, 2021). Of over forty species recognized of the *Plasmodium* parasites, five species namely:

Plasmodium vivax, *P. ovale*, *P. malariae*, *P. falciparum*, and *P. knowlesi* have been reported to infect humans (Woldearegaiet al., 2019; Kotepuiet al., 2020). A few other species such as *P. berghei*, *P. yoelii*, *P. chabaudi*, and *P. vinckei*, have also been reported to be infective in other mammals like rodents, and monkeys (Larson et al., 2019).

According to the World Health Organization (WHO), approximately 219 million cases and 440 thousand deaths were reported due to malaria in 2018 (WHO, 2018). Nigeria accounts for more cases and deaths than any other country in the world and there is an estimated 100 million malaria cases with over 300,000 deaths per year in Nigeria (Adeyemoet al., 2014). *Plasmodium falciparum*, the most virulent of the malaria parasites, is responsible for most of the mortality and morbidity associated with malaria infections in Nigeria. Pregnant women and children less than five years are most vulnerable to malaria attack (WHO, 2019; Iwuchukwu and Vincent, 2021).

The widespread resistance of malaria parasites against many antimalarial drugs is a factor in the economic constraints of malaria control. There is evidence of resistance against most antimalarial drugs, which is worsened by the emergence of chloroquine-resistant strains of *P. falciparum*, the malaria parasite responsible for most of the death cases every year. This led to the use of artemisinin combination therapy (ACT) and further search for new Phyto therapeutic agents (Osonwaet al., 2017; Afolabiet al., 2021).

If not promptly treated with effective medicines, malaria can cause severe illness that is often fatal (WHO, 2019). Hence, treatment of malaria with combination drug regimens has become the practice of choice because of their increased therapeutic efficacy over monotherapy and the other benefits including decreased cytotoxicity, delay, or prevention of the development of drug resistance (Nwankwo *et al.*, 2022).

Affordability and accessibility has limited the use of artemisinin combination therapy, and these has led to poor treatment practices, production of substandard forms of the drug, inadequate patient adherence to prescribed antimalarial regimen, eventually resulting to treatment failures. Following the problems associated with the implementation of ACT, majority of the population depend on traditional medicinal remedies (Omagha *et al.*, 2021), mainly from plants, which are often more available, affordable, and sometimes perceived as being more effective than conventional antimalarial drugs including artemisinin combination therapy (ACT) (Nigussie and Wale, 2022).

Traditional herbs have been used to treat malaria for thousands of years. Most of these plants are used in the form of monotherapies and only a few plants are taken in combined therapies (Million *et al.*, 2022). Antimalarial plants used in combination may promote the effectiveness of each plant, with efficacy being achieved by the use of a lower dose of each plant extract. This would proffer pharmacological benefits, as one plant extract clears infection from one body system the other clears it from a different site of the same body

(Williamson, 2001). Also, synergism with antimalarial agents could be utilized to prevent or delay the emergence *in vivo* of resistant populations of the parasite (Erhirhie *et al.*, 2021).

Azadirachta indica (Neem) from the Meliaceae family are extensively used as traditional medicinal remedies against malaria in the tropics (Achiet *al.*, 2018; Mbugiet *al.*, 2021; Yarmohammadi *et al.*, 2021). Several studies demonstrated that *A. indica* leaf, seed and stem bark extract possess *in vivo* inhibitory activity on *P. falciparum* asexual stages (Achiet *al.*, 2018; Annette *et al.*, 2019; Afolabiet *al.*, 2021). Antimalarial activity of *Ocimum gratissimum* (African basil/clove basil) has also been demonstrated (Nwankwo *et al.*, 2022). Although these plants are used in the traditional treatment of malaria, there is the need to scientifically assess the efficacy of the individual plant extract and their combinations in the treatment of malaria.

The main aim of the present study was to compare the antimalarial effects of *Azadirachta indica* and *Ocimum gratissimum* extracts with chloroquine in *Plasmodium berghei*-infected mice. The specific objectives were to assess the effects of the ethanol leaf extracts of *A. indica*, *O. gratissimum*, and their combined extracts in reducing parasitaemia in mice, pathological effects of the extracts on the liver, heart, and kidneys of the treated mice; and synergistic effects of the combined extracts in treating rodent malaria.

MATERIALS AND METHODS

Study Area

This study was undertaken in Owerri at the Federal Medical Centre Laboratory. Owerri is the capital city of Imo State of Nigeria, located

between latitudes $5^{\circ} 31'$ and $6^{\circ} 27'$ N and Longitudes $7^{\circ} 00'$ and $7^{\circ} 05'$, and approximately 100 square kilometers (40sq miles) in area, and consists of three Local Government Areas including Owerri Municipal, Owerri North, and Owerri West (Figure 1). Owerri has an estimated population of 1,401,873 according to the 2006 census. It is bordered by the Otamiri River to the East and the Nworie River to the South (Alex *et al.*, 2008).

Owerri has an annual temperature of 20°C - 30°C , relative humidity of 71%, rainfall distribution of 113.5m. Tropical rainforest is the predominant vegetation in Owerri although its density has drastically reduced due to anthropogenic activities such as urbanization, deforestation, and agricultural activities.

Nigeria. The caring and experimental use of mice was in accordance with the National Institute of Health Guidelines for care of Laboratory Animals.

Study Design

The work was an experimental study aimed at investigating the *in vivo* antimalarial effects of ethanol leaf extracts of *A. indica* and *O. gratissimum* in *Plasmodium berghei*-infected Swiss albino mice (*Mus musculus* L: Muridae), using chloroquine as the standard drug. The parasites and the mice were sourced from the National Institute of Medical Research (NIMR), Yaba, Lagos, Nigeria. The plant materials (*A. indica* and *O. gratissimum*) were collected from the Botanical Garden of the Ministry of Agriculture and Natural Resources, Owerri, Imo State, Nigeria. Assessment of parasitaemia, antimalarial effects of the plant extracts, and histopathological changes were done using standard laboratory analytical procedures at the Federal Medical Centre, Owerri.

Preparation of Plant Materials

Two kilogrammes (2kg) of each plant material were harvested, washed twice in clean water, and allowed to drip dry. The plants leaves were air-dried separately in the laboratory at room temperature for three weeks to a constant

weight before pulverizing. A 100g each, of the pulverized leaves of the plants was weighed and soaked in 500ml of absolute ethanol (BDL 95%) for 24 hours. The mixture was then filtered using Watman 2.0 filter paper. The filtrate was evaporated to dryness in a Rotary evaporator at a temperature of 40°C. The extracts were kept in a tightly closed bottle in a refrigerator until needed for antimalarial testing.

The stock solution of each plant filtrate was prepared by dissolving 10g of the extract in 100ml of distilled water to give a stock concentration of 0.10g/ml (Ejebe et al., 2011).

Maintenance of Study Animals.

Sixty-five(65) mature Swiss albino mice (25-30g) of either sex free from infection, were used. The animals were housed in cages lined with wood chip beddings and were acclimatized for ten days in the laboratory before being used for the experiment. The mice were maintained on a standard rat diet (Pfizer) and water *ad libitum*. They were kept at ambient room temperature while maintaining 12-hour light and dark exposure cycles.

Maintenance of Parasites

Plasmodium berghei(NK65 strain) was used as the rodent malaria parasite in the study. The chloroquine sensitive cryopreserved parasites stored

at -80°C were revived, stabilized and maintained by serial passage of blood from infected mice to clean mice that served as donor mice in the study.

Inoculum preparation and parasite inoculation

The blood of a donor mouse was collected in heparinized syringe and diluted in phosphate buffered saline to 10^8 parasitized erythrocytes/ml. The infection of mice was initiated by needle passage of the *P. berghei* parasite preparation from the donor mouse to healthy test mice via an intraperitoneal route (Peter and Anatoli, 1998; Dewit *et al.*, 2006).

The drug chloroquine was administered intramuscularly while the plant extracts and distilled water were administered orally with the aid of an intravenous medicut/mediflon cannula used as an improvised oral cannula (Ejebe *et al.*, 2009)

Experimental Set up and Treatments

Fifty-four (54) mice were divided into six (6) groups (A,B,C,D,E and F) of nine (9) mice each. The nine (9) mice in each group were sub-grouped into three (1,2,3) of three (3) mice in each subgroup to represent the experimental mice and control mice (positive and negative controls). The mice were infected by the methods described by Peter and Anatoli (1998), and David *et al.*, (2004), with 0.2ml of diluted (10^8 parasitized erythrocytes/ml) infected blood each intraperitoneally (i.p), except those in group F that was the control group. Treatment of mice in experimental groups A to E commenced on day

four when parasitaemia was well observed in the infected mice and percentage parasitaemia was assessed 24h post treatment. Fifty milligram per kilogram body weight of *A. indica* leaf extract, 50mg/kg body weight of *O. gratissimum* leaf extract, 10ml/kg body weight of chloroquine, and 30mg/kg body weight each of *O. gratissimum* leaf extract and *A. indica* leaf extract were used for the treatment, and treatment was repeated daily with the same dose for 72 hours. Percentage parasitaemia was assessed 24 hours post treatment and was repeated on daily basis throughout the treatment period.

- Group A - Control (Infected with no treatment).
- Group B - Infected and treated with chloroquine (CHQ) (10ml/kg)
- Group C - Infected and treated with *A. indica* leaf extract (50mg/kg).
- Group D - Infected and treated with *O. gratissimum* leaf extract (50mg/kg).
- Group E - Infected and treated with combined extract each of *A. indica* and *O. gratissimum* leaf extracts (30mg/kg).
- Group F - Not infected (Normal Control).

Twenty four hours after the last treatment (96 hours post-infection) blood smears from all the mice were prepared and stained with Giemsa stain for assessment of parasitaemia levels

Assessment of Parasitaemia

Before parasite inoculation and at 24 hours post treatment period, the experimental mice were bled from their tails, thin blood smears were made by fixing for 5 minutes using methanol stained with 10% Giemsa stain in phosphate buffer, P^H? 7.2, and examined microscopically under oil immersion at x100. Parasitaemia level was determined by counting the parasites observed in 10 fields of approximately 100 erythrocytes per field. The difference

between the mean values of the experimental group was calculated and expressed as percentage parasitaemia inhibition using the following equation:

% Inhibition =

$$\frac{\text{ParasitizedRBCinNegativeControl} - \text{ParasitizedRBCinstudygroup} \times 100}{\text{ParasitizedRBCinNegativeControl}}$$

Assessment of Histopathological Changes.

The animals were sacrificed by cervical dislocation 24 hours (one day) after the last dose of the treatments, and the organs were harvested.

Pathological changes were observed in three main organs – heart, kidney, and liver of the different groups of experimental mice. For light microscopic examination, tissues from each group were fixed with 10% buffered formalin, embedded with paraffin, and processed. After routine processing, paraffin sections of each tissue were cut into 5µm thickness and stained with hematoxylin and eosin. The photomicrographs of the relevant stained sections were taken with the aid of a light microscope.

The following scores were used to grade the degree of histopathological changes or lesions observed in the organs: not present (“), very mild (+), mild(++), moderate (+++), and severe (++++). The degree of damages caused in the organs were scored or assigned as follows: not present (“), 1 to 4 foci/section examined (+), 5 to 8 foci/section examined (++), 9 to 12 foci/section examined (+++), >13 foci/section examined (++++). Tubular nephrosis was graded (++) when scattered cells were detected with pyknotic, karyorrhexis, karyolytic nuclei, or loss of polarity, (+++) when these changes

were present in larger sections of a tubule, and (++++)) when multiple tubules in an area were affected.

Data Analysis

Data was analyzed using the statistical package for social sciences (SPSS) version 2.0. Tabulations, percentages and graphs were used to present results. Statistically significant differences were analyzed using Analysis of variance (ANOVA). Graphs were plotted using Microsoft excel, version 2007.

RESULTS

Intensity of Parasitaemia

Table 1 shows that few minutes prior to infection, there were no significant differences in parasite intensity in both the control groups A,B,and F, and treatment groups C, D, and E, ($P<0.05$; $P=0.00$). No

parasite was observed in the peripheral blood of all the experimental mice.

Twenty-four hours after infection, parasite intensity was between 136853 ± 1022.01 and 138633 ± 852.31 in all the infected mice. Parasite intensity was not significantly different in treatment groups B, C, D, and E ($P > 0.05$; $P = 0.995, 0.599, 0.9902, \text{ and } 1.00$), that were infected with the parasites.

Twenty-four hours after last treatment with 30mg/kg and 50mg/kg body weight of the mice, parasite intensity in groups A (infected but not treated) rose significantly from 138083 ± 1.00 to 181358.00 ± 1.00 ($P < 0.05$; $P = 0.00$). The parasite intensity in groups B (infected and treated with chloroquine) significantly decreased to 3.00 ± 0.58 ($P < 0.05$; $P = 0.00$). There were non-significant reductions in parasite intensity among those treated with plant extracts of *Aindica* and *O. gratissimum* and their combined regimens ($P > 0.05$; $P = 1.00$).

Table 1: Changes in Parasite Intensity before Infection, after Infection, and after Administration of Ethanol Leaf Extracts of *A. indica*, and *O. gratissimum* in *P. berghei*-infected Mice (Therapeutic Effects of *A. indica* and *O. gratissimum*).

Experimental groups	Parasite intensity				
	Before infection(x10 ³)		After infection (x10 ³)		After treatment (x10 ³)
A – Infected, No Treatment	0.000 ± 0.00		138083.00 ± 1.000		181358.00 ± 1.00
B – 10ml/kg of Chloroquine	0.000 ± 0.00		138633.00 ± 852.31		3.00 ± 0.58
C – 50mg/kg <i>A. indica</i>	0.000 ± 0.00		136853.00 ± 1022.01		1957.00 ± 694.54
D – 50mg/kg of <i>O. gratissimum</i>	0.000 ± 0.00		137971.00 ± 903.51		3083.00 ± 93.54
E - 30mg/kg each of <i>A.i</i> & <i>O.g</i>	0.000 ± 0.00		137634.00 ± 2301.11		1235.00 ± 111.53
F – Not Infected, Normal Control	0.000 ± 0.00		0.00± 0.00		0.00 ± 0.00

Key: (*A.i*)=*Azadirachta indica*, (*O.g*)=*Ocimum gratissimum*.

Antimalarial Effects of the Plant Leaf Extracts

The therapeutic effect of the leaf extracts of the plants on the infected animals (Figure 2) showed that the animals responded to the extracts within the first seven days of treatment with 69.89% reduction of parasitaemia for *O. gratissimum* treated group, 71.11% for *A. indica* treated group, and 82.70% for combined extracts of *A. indica* and *O. gratissimum* treated groups before the parasitized red blood cells started to increase which later led to the deterioration of the health condition of the animals. The antimalarial action of the combined leaf extracts of *A. indica* and *O. gratissimum* (82.70%) was close to that of chloroquine (97.98%).

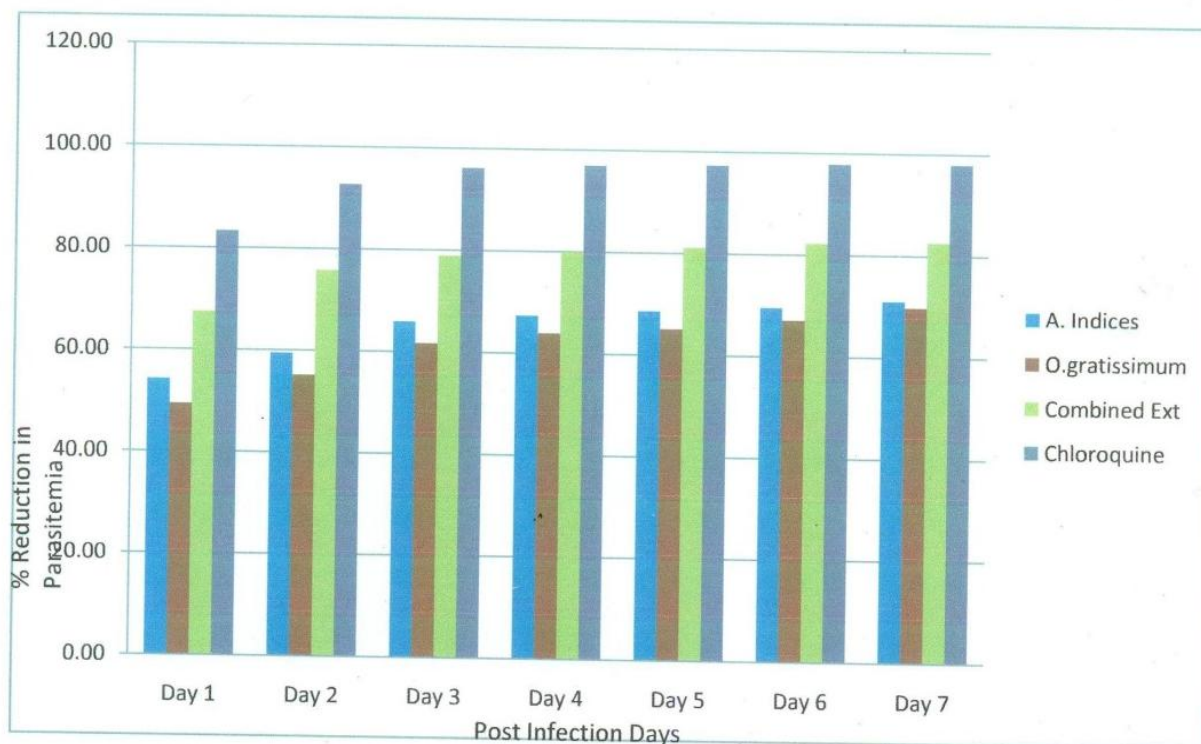


Figure 2: Therapeutic Effect of Ethanol Extracts of the Plants Leaves on albino Mice Infected with *P. berghei*

Malaria-induced Pathological Lesions and Effects of Plant Leaf Extracts.

Physical examination of some internal organs (liver, kidney and heart) of the experimental animals did not show any macroscopic changes. Histological studies revealed some damages caused by the malaria parasites on the liver(Plates 2-6, table 2), on the kidney (plates 7-12, table 3),and on the heart (plates 13-18,table 4), and the extent of reduction of these damages by the administered drugs. The accumulation of iron in the liver (hemosiderosis), death of cells of the liver (hepatic necrosis), and marked damages of the nephron in the kidney (tubular nephrosis), was severe in group A (Infected and not treated mice).Reduction of the lesions and other damages were observed in the groups treated with *A. indica* extract, *O. gratissimum* extract, and the combined extracts of *A. indica* and *O. gratissimum*. The absence of any pathological damage in the untreated infected group (tables 2, 3, and 4) is an indication that it was not caused by the malaria parasite.

Table 2: Pathological Effects of the Plants Leaf Extracts on the Liver of Infected Mice

	<i>A. indica</i> Leaf Extract	<i>O. gratissimum</i> Leaf Extract	Combined Extract each of <i>A. indica</i> and <i>O. gratissimum</i>	Chloroquine	Control (INT)
	50mg/kg	50mg/kg	30mg/kg	10ml/kg	
Kupffer cell Hyperplasia	+++	+	+	-	++++
Haemosiderosis	++	++	++	-	++++
Hepatic Necrosis	+++	+	+	++	++++
Periportal Mononuclear cells infiltration	+++	++	+	+	-

The following scores indicate the degree of lesions/histopathological changes observed in the organ: (-) not present, (+) very mild, (++) mild, (+++) moderate, (+++++) severe. (INT)-infected but not treated, (*A.i*)=*Azadirachta indica*, (*O.g*)=*Ocimum gratissimum*.

Table 3: Pathological Effect of Plant Extracts on the Kidney of Infected Mice

	<i>A. indica</i> Leaf Extract	<i>O. gratissimum</i> Leaf Extract	Combined Extract each of <i>A. indica</i> and <i>O. gratissimum</i>	Chloroquine	Control (INT)
	50mg/kg	50mg/kg	30mg/kg	10ml/kg	
Tubular Nephrosis	++	-	+	++	++++
Perivascular interstitial mononuclear cell infiltration	+	-	-	-	++++

The following scores indicate the degree of lesions/histopathological changes observed in the organ: (-) not present, (+) very mild, (++) mild, (+++) moderate, (+++++) severe. (INT) – infected but not treated, (*A.i*)=*Azadirachta indica*, (*O.g*)=*Ocimum gratissimum*.

Table 4: Pathological Effect of Plant Extracts on the Heart of the Infected Mice.

	<i>A. indica</i> Leaf Extract	<i>O. gratissimum</i> Leaf Extract	Combined Extract each of <i>A. indica</i> and <i>O. gratissimum</i>	Chloroquine	Control (INT)
	50mg/kg	50mg/kg	30mg/kg	10ml/kg	
Myofibers degeneration and necrosis	++	+	-	-	-

The following scores indicate the degree of lesions/histopathological changes observed in the organ: (-) not present, (+) very mild, (++) mild, (+++) moderate, (+++++) severe, (INT)-infected but not treated, (*A.i*)=*Azadirachta indica*, (*O.g*)=*Ocimum gratissimum*.

3.4.1 Malaria-induced Pathological Lesions and Effects of Plant Leaf Extracts on the Liver

Plate 1 shows the micrograph of liver of normal mice with absence of lesions. The leaf extract of *O. gratissimum* and combined extracts of *O. gratissimum* and *A. indica* reduced pathological damages caused by the parasite (Plates 4 and 5) better than the *A. indica* leaf extract (Plate 3). The reduction of the pathological damages in this organ by *O. gratissimum* leaf extract, and the combined extracts of *A. indica* and *O. gratissimum* is similar to that of chloroquine (Plates 4, 5, and 6). This is evident in their very mild/mild reduction of Kupffer cells, hemosiderosis, and reduction of hepatic necrosis irrespective of the dosage. The lesions were more persistent in the group treated with *A. indica* extracts (plate 3), while those treated with *O. gratissimum* extracts recovered quickly (Plate 4).

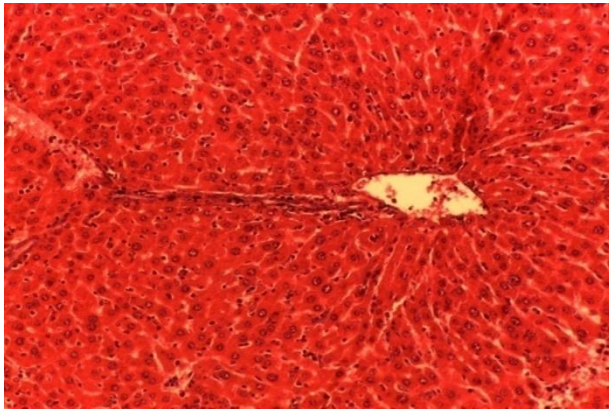


Plate 1: Histologic section of Liver of normal control Mice without infection under high magnification (40x) showing the absence of lesions in the liver of the mice.

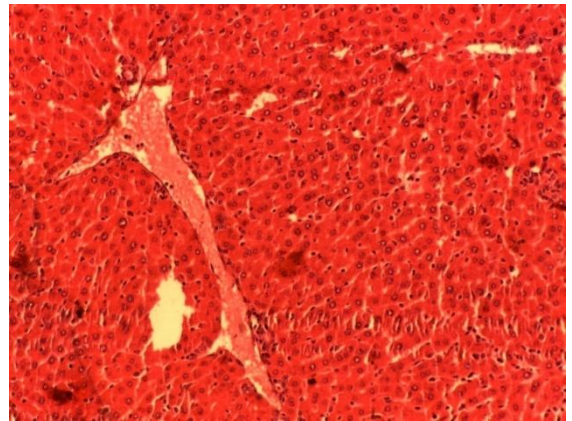


Plate 2: Histologic section of infected and not treated liver (INT) under high magnification (40x) showing severe histopathological lesions in the mice

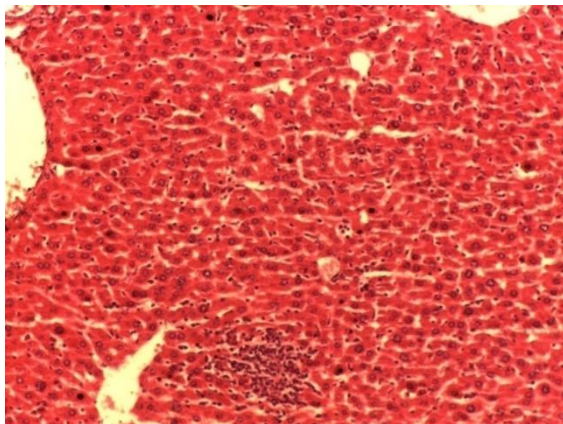


Plate 3: Histologic section of Liver of infected Mice treated with *A.indica* leaf Extract under high magnification (40x) showing moderate histopathological lesions observed in the mice.

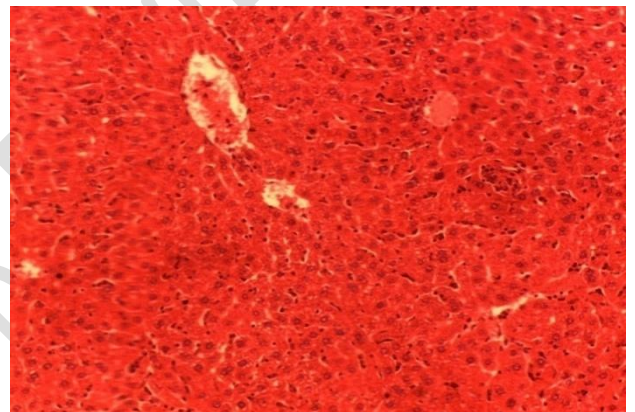


Plate 4: Histologic section of Liver of infected Mice treated with *O.gratissimum* leaf Extract under high magnification (40x) showing mild histopathological lesions observed in the liver of the mice.

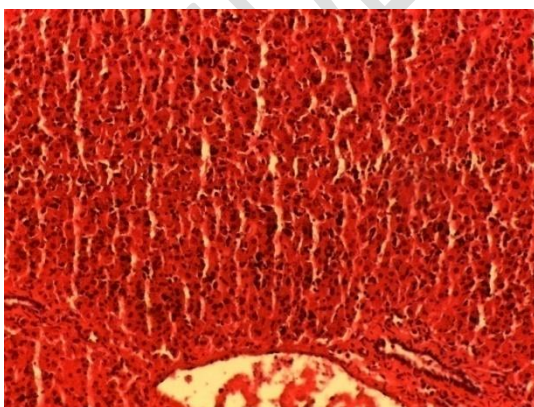


Plate 5: Histologic section of Liver of infected Mice treated with combined leaf extracts each of *A.indica* and *O.gratissimum* under high magnification (40x) showing very mild lesions observed in the liver of the mice.

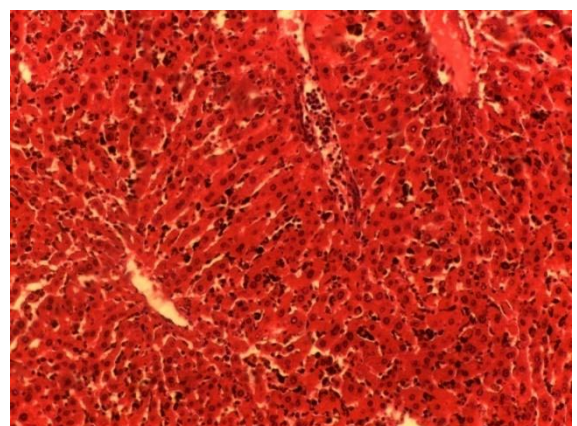


Plate 6: Histologic section of Liver of infected Mice treated with Chloroquine under high magnification (40x) showing very mild lesions observed in the liver of the

3.4.2 Malaria-induced Pathological Lesions and Effects of Plant leaf Extracts on the Kidney

Plate 7 shows the micrograph of the kidney of normal mice with absence of lesions. The leaf extract of *O. gratissimum* reduced pathological damages (Plate 10) better than *A. indica* leaf extract (Plate 9), and chloroquine (Plate 12). This is indicated in its total reduction of tubular nephrosis, and perivascular interstitial mononuclear cell infiltration. The combined extracts, each of *O. gratissimum* and *A. indica* (Plate 11) had the same effect with that of *O. gratissimum*. The reduction by *A. indica* was mild as well as that of chloroquine.

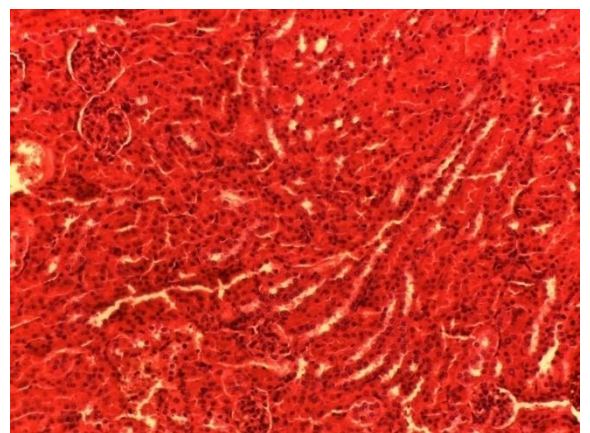
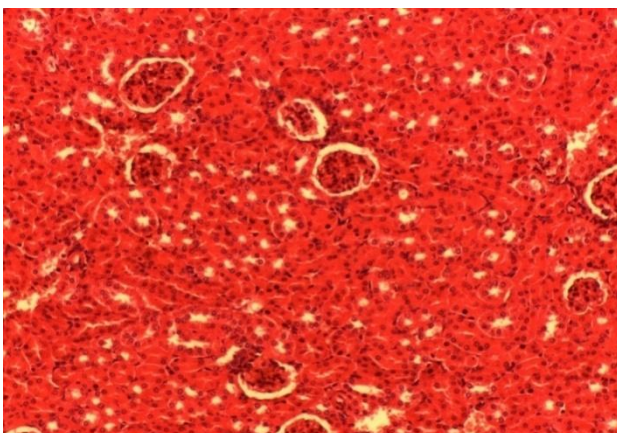


Plate 7: Histologic section of Kidney of normal control Mice without infection under high magnification (40x) showing absence of lesions in the kidneys of the mice.

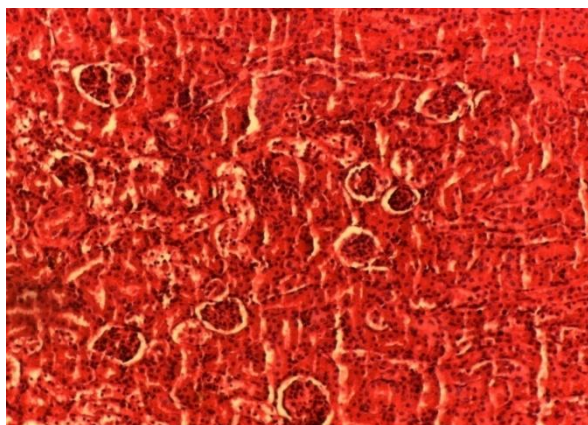

Plate 8: Histologic section of Kidney of infected and not treated (INT) Mice under high magnification (40x) showing moderate lesions observed in the kidneys of the mice

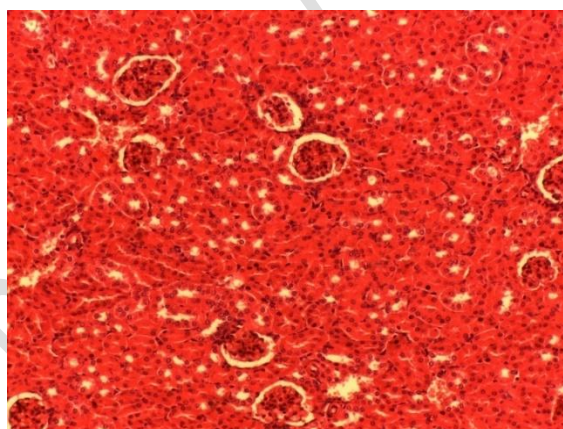


Plate 9: Histologic section of Kidney of infected Mice treated with *A.indica* leaf Extract under high magnification (40x) showing very mild lesions observed in the kidneys of the mice.

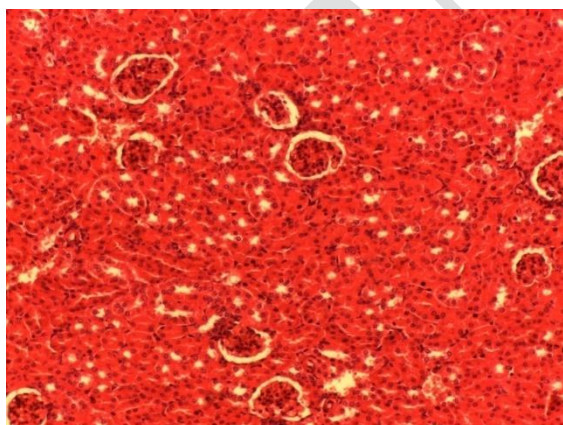


Plate 10: Histologic section of Kidney of infected Mice treated with *o.gratissimum* leaf Extract under high magnification (40x) showing absence of lesions observed in the kidneys of the mice.

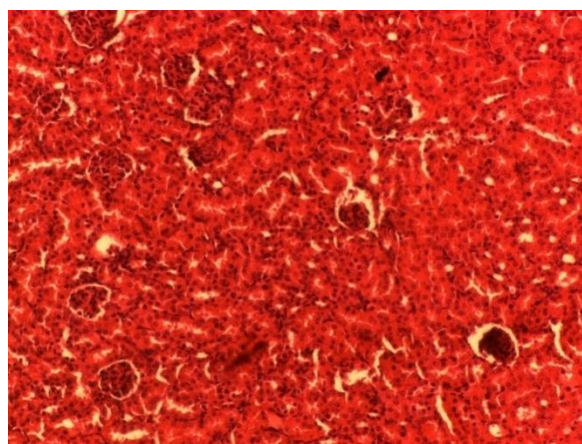


Plate 11: Histologic section of Kidney of infected Mice treated with combined leaf extracts each of *A.indica* and *O.gratissimum* under high magnification (40x) showing absence of lesions in the kidneys of the mice.

Plate 12: Histologic section of Kidney of infected Mice treated with Chloroquin under high magnification (40x) showing mild lesions observed in the kidneys of the mice.

3.4.3 Malaria-induced Pathological Lesions and Effects of Plant Leaf Extracts on the Heart

Plate 13 shows the micrograph of the heart of normal mice with absence of lesions. The combined extract of *A. indica* and *O. gratissimum*, and the leaf extract of *O. gratissimum* had almost similar effects as no lesion was recorded (Plates 17 and 16, respectively), though it was very mild with the *O. gratissimum* leaf extract. Also the control groups (group infected without treatment and the group infected and treated with chloroquine) did not record any pathological damage (Plates 14, and 18), respectively. The *A. indica* leaf extract recorded very mild pathological damage (Plate 15).

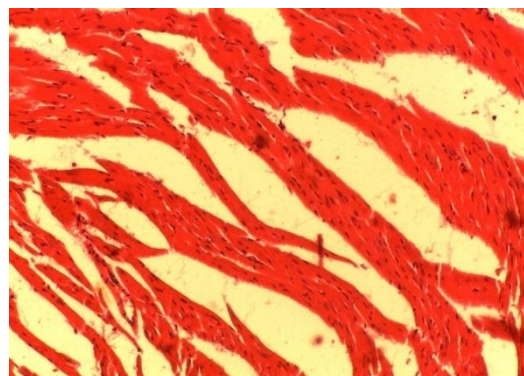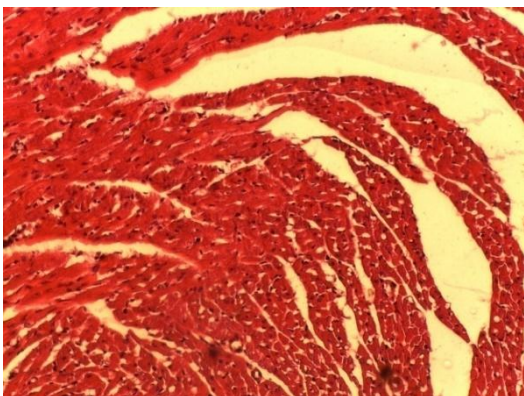


Plate 13: Histologic section of Heart of normal control Mice without infection under high magnification (40x) showing absence of lesions in the heart of the mice.

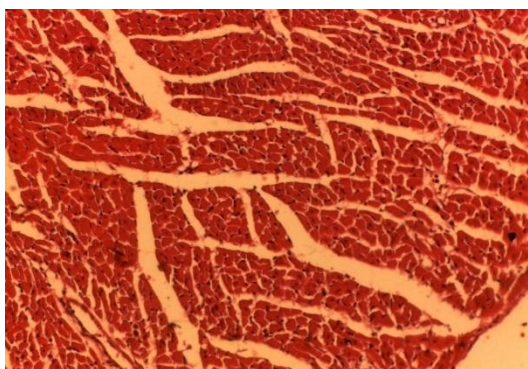


Plate 14: Histologic section of Heart of infected and not treated (INT) Mice under high magnification (40x) showing absence of lesions in the heart of the

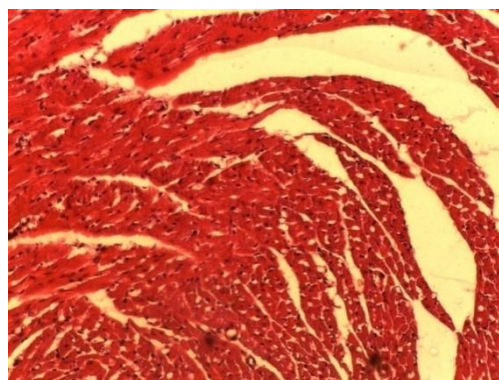


Plate 15: Histologic section of Heart of infected Mice treated with *A.indica* leaf Extract under high magnification (40x) showing very mild lesions observed in the

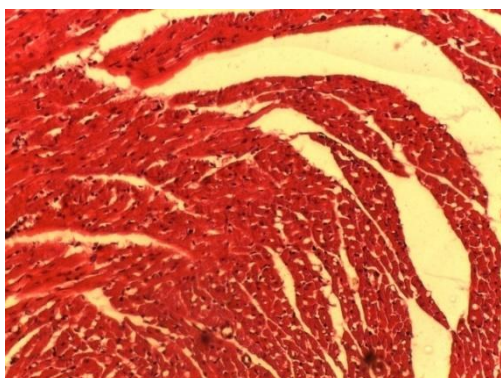


Plate 16: Histologic section of Heart of infected Mice treated with *O. gratissimum* leaf Extract under high magnification (40x) showing very mild/absence of lesions in the heart of the mice.

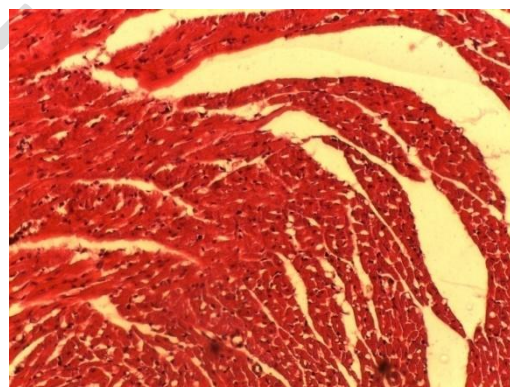


Plate 17: Histologic section of Heart of infected Mice treated with combined leaf extracts each of *A.indica* and *O.gratissimum* under high magnification (40x) showing absence of lesions in the heart of the mice.

Plate 18: Histologic section of Heart of infected Mice treated with Chloroquine under high magnification (40x) showing absence of lesions in the heart of the mice.

DISCUSSION

The *in vivo* antimalarial activities of *A. indica* and *O. gratissimum* leaf extracts were studied in *P. berghei*-infected mice to determine the treatment outcomes of combined therapy.

Before parasite inoculation and at 24 hours post treatment period, parasitemia was monitored by microscopic examination of Giemsa-stained thin blood smears in all the experimental mice. The significant increase in the level of parasitaemia in the infected untreated group recorded from day 1 to day 7, as symptomized by the enlargement of the red blood cells, anaemia, loss of appetite, and loss of weight as major clinical signs observed during the course of treatment is in tune with the view that parasitaemia in mice increases progressively after infection until the point of death if no suitable treatment is administered (Osonwa *et al.*, 2017).

The reduction in parasitaemia levels was highest in the group administered with the combined extracts of *A. indica* and *O. gratissimum* (Figure 2, [82.70%]) than those administered with single plant extracts. This may be attributed to the synergistic antiplasmodial effect of the compounds or their metabolites. These findings agree with the reports of Awe and Makinde (1998), Tona *et al.*, (2001), Iwalokun (2008), Adebajo *et al.*, (2014), Somsaket *et al.*, (2015), Ekpo and Ekanemesang, (2016), Cissy *et al.*, (2016), and Igbokwe *et al.*, (2021) who reported that phytochemicals are responsible for the antimalarial activities of many plants. Also, these metabolites may be acting individually or in synergy with one another to produce antimalarial activity.

Pathologically, the severe damages observed in the liver of the animals in group A (infected but not treated) may be as a result of the parasite life cycle during erythrocytic stages in the blood stream. Responding to the damage caused, macrophages (Kupffer cells) in the liver proliferated actively (Kupffer cell hyperplasia), breaking down ruptured red blood cells by phagocytic action thereby splitting up the hemoglobin molecules. This results to pathological effects such as accumulation of iron in the liver (haemosiderosis). Extensive and rapid death of parenchyma cells of the liver (Hepatic Necrosis) also occurred. These findings agree with the reports of Soniranet *al.*, (2012) and Idowuet *al.*, (2014).

In the liver, it was observed that the combined extract of *A. indica* and *O. gratissimum* reduced pathological damages better than the single extracts of *A. indica*, or *O. gratissimum* (Plate 5). Proliferation of Kupffer cells and accumulation of hemosiderin was mild while destruction of liver cells was not observed in this group. All these damages were severe in the untreated infected group. Reduction in the Kupffer cells which are phagocytic in nature may be due to few parasitized red blood cells in the liver as a result of the antiplasmodial effect of the extracts. Observation of liver cells necrosis in the infected and untreated group (Group A) showed the efficiency of the combined extract of *A. indica*, and *O. gratissimum* at reducing this pathological damage. This may be as a result of synergistic effect of phytochemicals present in the combined extracts but not present in the single/individual extracts, which prevented the exo-erythrocytic schizogony of the malaria parasites in the liver (Idowuet *al.*, 2014).

Observations of the kidneys indicated that there was no significant pathological damage on administration of the leaf extracts. This is evident in the groups treated with *O. gratissimum* extract, and that treated with the combined extracts of *A. indica*, and *O. gratissimum* without any trace of pathological lesion in the kidney (Plates 10 and 11). Destruction of the nephron (tubular nephrosis) was moderate at 50mg/kg dose of the *A. indica* leaf extract-treated group, while infiltration of mononuclear cells was not present in the combined extract, and *O. gratissimum* group, but very mild in the *A. indica* treatment group at 50mg/kg dose, thus, indicating the absence of foreign substances that could activate the infiltration of the mononuclear cells as observed in the infected and untreated group. This indicates the renal protective role of the combined extract each of *A. indica* and *O. gratissimum*, and *O. gratissimum* individual extract on inoculated mice. This finding agrees with the reports of Elsheikha and Sheasha (2007), Bussayo *et al.*, (2011), Elias *et al.*, (2012), Koulet *et al.*, (2014), and Somsaket *et al.*, (2015).

Administration of *O. gratissimum* leaf extract, and the combined extract each of *O. gratissimum* and *A. indica* did not cause any lesions at all, in addition to the control treatment (Plates 16 and 17), and untreated control. The *A. indica* leaf extract recorded mild lesions. The absence of the pathological damage in the untreated infected group is an indication that it was not caused by the malaria parasite. Therefore, certain chemical substances present in the *A. indica* leaf extract had led to the degradation and necrosis of myofibers in the heart. The activity of the combined leaf extracts of *A. indica* and *O. gratissimum* was also observed to be better than the individual/separate extracts of *A.*

indica and *O. gratissimum*, which corroborates the results observed in their antiplasmodial activity (Idowuet *et al.*, 2014; Osonwaet *et al.*, 2017; and Anigboroet *et al.*, 2018).

4.2 Conclusion

From the study, individual leaf extracts of *A. indica* and *O. gratissimum* have been shown to be effective in the treatment of malaria parasite in mice by reducing the parasite intensity. The leaf extracts also proved good at reducing pathological damages caused by *P. berghei*, as evident in the restoration of hepato-, renal-, and cardiac integrity upon administration of the extracts. All these therapeutic observations were more pronounced in the combined extracts treatments indicating synergistic action of the extracts. It is therefore recommended that the coadministration of these locally used plants investigated in this study be taken for the treatment and management of malaria as their action is very close to that of the antimalarial drug, chloroquine which was the standard drug used in this study.

References

17. Achi, N.K., Onyeabo C., Nnate, D.A., Ekeleme-Egedigwe, C.A., Kalu, I.K., Chibundu, I.C. and Wokoma, G.C. (2018). Therapeutic effects of *Azadirachta indica* A. juss. leaves in malaria-induced male wister rats. *Journal of Pharmacy and Pharmacognosy Research*, **6**(3): 191-204.
30. Adebajo, A.C., Odediran, S.A., Aliyu, A.F., Nwafo, P.A., Nwoko, T.N. and Umana, S.U. (2014). *In Vivo* Antiplasmodium Potentials of the Combinations of four Nigerian Antimalarial Plants. *Journal of Molecules*, **19**(9):13136-13146.
6. Adeyemo-Salami, O.A., Farambi, E.O. and Ademowo, O.G. (2014). An investigation into the antimalarial effect of methanol extract of *Paullinaipinnata* leaves in *P. berghei* infected

- mice and course of infection. *African Journal of Medicine and Medical Sciences* **43**(1): 93-94.
10. Afolabi, O.J., Simon-oke, I.A. and Oladokun, O.I. (2021). Antiplasmodial Activity of Ethanol Extract of Neem Leaf (*Azadirachta indica*) in Albino Mice Infected with *Plasmodium berghei*. *International Archives of Clinical Pharmacology*, **7**:2572-2578.
 21. Alex, D.W.A. and Okorie, P.U. (2008). "Water quality studies of Nworie Rivers in Owerri, Nigeria." *Journal of Mississippi Academy of Sciences*, **20**(1): 55-60.
- Alkadi, H.O. (2007). A review. *Journal of Chemotherapy*, **53**: 385-391.
- Alven, S. and Aderibigbe, B. (2019) Combination therapy strategies for the treatment of malaria. *Molecules*, **24**(19):3601-3609.
- Amaratunga, C., Sreng, S., Mao, S., Tullo, G.S., Anderson, J.M., Chuor, C.M. and Fairhurst, R.M. (2014). Chloroquine remains effective for treating *Plasmodium vivax* malaria in Pursat province, Western Cambodia. *Journal of Antimicrobial Agents and Chemotherapy*, **58**:6270-6272.
41. Anigboro, A. A., Onakurhefe, P., Tonukari, N.J., Avwioroko, O.J. and Egbeme, E. (2018). Quantitative determination of some phytochemicals (phenol, flavonoid, saponin and alkaloid) in twenty-two Nigeria medicinal plants. *Nigerian Journal of Science and Environment*, **13**(1): 86-93.
 20. Annette, H., Barbara, P., Sofia, T., Judith, N. and Fabrizio, B. (2019). Effects of *Azadirachta indica* seed kernel extracts on early erythrocytic schizogony of *Plasmodium berghei* and proinflammatory response in inbred mice. *Malaria Journal*, **18**:35-43.
 27. Awe, S.O. and Makinde, J.M. (1998). Effect of petroleum ether fractions of *Morinda lucida* on *Plasmodium berghei* in mice. *Journal of Pharmaceutical Biology*, **36**(4): 301-304.
 38. Bussayo, A.O., Laura, Z., Olubusola, D.O., Oluwafunmike, A.S., Luciana, D. and Ademola, C.E. (2011). "Ameliorative effects of ethanol leaf extracts of *Azadirachta indica* on renal histologic alterations in streptozotocin-induced diabetic rats". *The American Journal of Chinese Medicine*, **39**(5): 903-916.
- Chesbrough, M. (2006). District laboratory practice in tropical countries. Cambridge University Press.
33. Cizzy, N., Engeu, O.P., Berna, O., Norbert, A. and Esther, M. (2016). *Artemisia annua* L. and *Venonia amygdalina* Del: A potential Herbal Artemisinin Combination Treatment against malaria. *British Journal of Pharmaceutic Resources*, **14**(3):1-7.
 26. David, A.F., Lip, J. R., Simon, L.C., Rato, B. and Solomon N. (2004). Antimalarial drug discovery: efficacy models for compound screening. *Nature review* **16**: 522-528.

24. Dawit D., Eyassu, M., Asfaw, D., Dawit,A., Kelbessa, U., Wallelign, M., Daniel, M., Ashenafi, A. and yared, M. (2006). *In vivo* antimalaria activity of hydrocoholic extracts from *Asparagus africanus* Lam. In mice infected with *Plasmodium berghei*. *Ethiopian Journal of Health Development* **20**(2): 112-118.
22. Ejebe, D.E., Emudianohwo, J.O., Ozoko, T., Simialayi, I.M., Esume, C.O. and Maduodi, U.V. (2011). An Investigation into the antiplasmodial effect of the ethanol extract of the leaves of *Helliantusannus* in Swiss Albino mice. *Global Journal of Pharmacology*, **5**(2): 92-96.
25. Ejebe, D.E., Siminialayi, I.M., Emudainowho, J.O.T., omakporaye, S.L., Ojeih, A.E., Akonoghrere, R., Odekuma, I.E. and Ahatty, G.C. (2009).An improved technique for the oral administration of solutions of test substances to experimental rats using mediflon.medicut intravenous cannula.*American Journal of Biotechnology*, **8**(6): 60-96.
32. Ekpo,D.E. and Ekanemesang, M.U. (2016). Antiplasmodial/antimarlarial effect of ethanol extracts of leaves of *Vernoniaamygdalina* and *Gongronemalatifolium* on the activity of catalase in *Plasmodium berghei*-parasitized mice. *International Journal of BCRR*, **10**(4): 1-9.
39. Elias, R.M., Correa-Costa, M. and Barreto, C.R. (2012). “Oxidative stress and modification of renal vascular permeability are associated with acute kidney injury during *P. berghei*ANKA infection”. *PLoS ONE*, **7**(8):440-444.
37. Elsheikha, H.M. and Sheashaa, H.A. (2007). “Epidemiology, pathophysiology, management and outcome of renal dysfunction associated with *Plasmodium* infection”. *Journal of Parasitology Research*, **101**(5): 1183-1190.
16. Erhirhie, E.O., Ikegbune, C. and Okonkwo, O.B. (2021). Antimalarial herbal drugs: a review of their interactions with conventional antimalarial drugs. *International Journal of Phytomedicine and Physiotherapy*, **7**:4-10.
- Granham, P.C. (1966). *Malaria parasite and other haemosporidia*. Blackwell Scientific Publications, Washington DC, USA.
36. Idowu, O.A., Soniran, O.T., Ajayi, O.I. and Olubi, I.C. (2014). Effect of *Morindamorindiodeson* organs of mice infected with *Plasmodium berghei*. *Nigerian Journal of parasitology*, **35**(1-2): 31-40.
34. Igbokwe,V.U,Eze, D.E.,Adams, D.M., Kabiu, K.M., Ezekiel, I., Ejeka,P.O.andOkpara P.O. (2021).Antimalarial Effects of Five Traditional Nigerian Medicinal Plant Extracts on *Plasmodiumberghei*-Infected Rats. *FUDMAJournal of Sciences*, **5**(2), DOI: <https://doi.org/10.33003/fjs-2021-0502-461>.

29. Iwalokun, B.A. (2008). Enhanced antimalarial effects of chloroquine by aqueous *Vernonia amygdalina* leaf extract in mice infected with chloroquine resistant and sensitive *Plasmodium berghei* strains. *Journal of African Health Sciences*, **8(1)**: 25-35.
8. Iwuchukwu, I.C., and Vincent C.N (2021). Studies on prevalence of malaria and its adverse foetal outcomes in FMC, Owerri, Imo State, Nigeria. *Archives of Community Medicine and Public Health*, **7(2)**: 151-163.
- Kellick-Kendrick, R. (1978). Taxonomy, Zoography and Evaluation. In: Rodent Malaria, kellick-kendrick, R. and W. Peters (Eds). Academic Press, London, pp:1-52.
4. Kotepui, M., Kotepui, K.U Millanez, G.D. and Masangkau, F.R. (2020). Severity and mortality of severe *Plasmodium ovale* infection: a systematic review and meta-analysis. *PLoS ONE*, **15**: e0235014.
40. Koul, A., Mohan, V. and Bharati, S. (2014). "Azadirachtaindica mitigates DMBA-induced hepatotoxicity: a biochemical and radiometric study". *Indian Journal of Biochemistry and biophysics*, **51(1)**:37-45.
5. Larson, B., Barthelemy, N., Stephan, N., Nancy-Diamela, M., Francois, R., Virginie, R. and Frank, P. (2019). Rodent Malaria in Garbon: Diversity and Host range. *International Journal of Parasitology*, **10**:117-124.
- Lathia, T.B. and Joshi, R. (2004). Can haematological parameters discriminate malaria from non-malarious acute febrile illness in the tropics? *Indian Journal of Medical Sciences*, **58(6)**: 239-243.
18. Mbugi, E.V., Sife, A.S., Mboni, R., Grace, E. P.M., Bestina, D. and Edda, T.L. (2021). Effectiveness of *Azadirachtaindica* (neem tree) on prevention and treatment of clinical human malaria: A systematic review. *Journal of East Africa Science*, **3**:1-4.
14. Million, E., Mulugeta, T. and Umeta, B. (2022). Traditional Medicine Practice and its Role in the Management of Malaria in Jimma Town, Oromia, Ethiopia. *Journal of Infection and Drug Resistance*, **15**:2187-2198.
13. Nigussie, G. and Wale, M. (2022). Medicinal plants used in traditional treatment of malaria in Ethiopia: a review of ethnomedicine, anti-malarial and toxicity studies. *Malaria Journal*, **21**: 262-266.
11. Nwankwo, E.N., Ezekwesili, O.O. and Chude, C.M. (2022). In vitro antiplasmodial and in vivo toxicity potentials of *Menthapiperita* and *Ocimum gratissimum* essential oils and their synergistic effect with conventional antimalarial drugs against *Plasmodium falciparum*. *International Journal of Mosquito Research*, **9(1)**: 114-122.
- Ofem, O.E., Ani, E.J. and Eno, A.E. (2012). Effect of aqueous leaf extract of *Ocimum gratissimum* on haematological parameters in rats. *International Journal of Applied and Basic Medical Research*, **2(1)**:38-42.

12. Omagha, R., Idowu, E.T. and Adeneye, A.K. (2021). Survey of ethnobotanical cocktails commonly used in the treatment of malaria in southwestern Nigeria. *Future Journal of Pharmaceutical Sciences*, **7**:152-158.
9. Osonwa, E.U., Mbonu, D.O., Eluu, C.S. and Oli, A.N. (2017). Antiplasmodial and biochemical effects of combination of ethanol leave-extract of *Azadirachta indica* and *Ocimum gratissimum* on *Plasmodium berghei*-infected mice. *African Journal of Pharmaceutical Sciences and Pharmacy*, **5**:1-6.
23. Peter, I.T. and Anatoli, V.K. (1998). The current global malarial situation. Malaria parasite biology, pathogenesis, and protection. *American Society for Microbiology, Washington DC*, pp.11-22.
2. Sato, S. (2021). *Plasmodium* – a brief introduction to the parasites causing human malaria and their basic biology. *Journal of Physiology/Anthropology*, **40**:1-5.
1. Sitali, L., Miller, J.M., Mwenda, M.C., Bridges, D.J., Hawela, M.B. and Hamainza, B. (2019). Distribution of *Plasmodium* species and assessment of performance of diagnostic tools used during a malaria survey in southern and western provinces of Zambia. *Malaria Journal*, **18**:130-133.
31. Somsak, V., Chachiyo, S., Kittitorn, J., Audomkasok, S. and Sriwiphat, S. (2015). Antimalarial and Antihypoglycemic Properties of Siamese Neem Tree (*Azadirachta indica*) in *Plasmodium berghei*-infected Mice. *Malaria Contraction Elimination*, **4**:134-137.
35. Soniran, O.T., Idowu, O.A., Ajayi, O.L. and Olubi, I.C. (2012). Comparative study on the effects of Chloroquine and Artesunate on histopathological damage caused by *Plasmodium berghei* in four vital organs of infected albino mice. *Journal of Malaria Research and Treatment*, **10**:11-55.
28. Tona, L., Mesia, K., Ngimbi, N.P., Chrimwami, B., Okond, A., Cimanga, K., Bruyne, T.D., Apers, S., Hermans, N., Totte, J. and Pieters, L. (2001). In-vivo antimalarial activity of *Cassia occidentalis*, *Morinda morindoides* and *Phyllanthus niruri*. *Annals of Tropical Medicine and Parasitology*, **95**(1): 47-57.
- Trampuz, A., Jereb, M., Muzlovic, I. and Prabhu, R.M. (2003). Clinical review: severe malaria. *Journal of Critical Care*, **7**(4): 315-319.
- WHO (2018). World malaria report. *World Health Organization*. <https://www.who.int/publications/report>.
- Willcox, M.L. and Bodeker, G. (2004). Traditional Herbal Medicines for Malaria. *British Medical Journals*, **329**: 1156-1159.
3. Woldearegai, T.G., Lalremruata, A., Nguyen, I.T., Gmeiner, M., Veletzky, L. and Tazenda-kuitsouc, G.B. (2019). Characterisation of *Plasmodium* infections among inhabitants of rural areas in Gabon. *Journal of Scientific Reports*, **9**(1): 41597-41599.

World Health organization.(2017). Malaria.Fact Sheet, No-94.

7. World Health Organization/RBM.(2019). Documentation of the socio-economic impact of malaria epidemics in Africa.Final report.[www.rollbackmalaria.org/seim2019/\(WHO/HTM/MAL/2019.1102\)](http://www.rollbackmalaria.org/seim2019/(WHO/HTM/MAL/2019.1102)).
19. Yarmohammadi, F., Mehri, S., Najan, N., Salar, A.S. and Hosseinzadeh, H. (2021). The Protective Effect of *Azadirachta indica* (Neem) against Metabolic Syndrome: A Review. *Iran Journal of Basic Medical Sciences*, **24** (3): 280-292.

UNDER PEER REVIEW