

Short Research Article

Preservation of Demodex Folliculorum in the Eyelash Follicles of Cadavers

ABSTRACT

Purpose: This study aims to investigate the presence of Demodex mites, particularly Demodex folliculorum, in the eyelash follicles of cadavers preserved through different embalming methods. The purpose is to determine the viability and persistence of these mites in post-mortem conditions, challenging previous assumptions about their survival limits.

Methods: Four human cadavers were examined in collaboration with the Department of Ophthalmology, and eyelash samples were epilated for microscopic analysis. A modified Coston method with an olive oil solution was employed to enhance the visibility of the mites. The demographic data and preservation methods of the cadavers were recorded.

Results: Microscopic examination revealed the presence of Demodex folliculorum in all cadaver samples, but no live mites were found. Skeletons of these mites were particularly evident in areas with concentrated oil residues. The mites exhibited signs of death, including the cessation of leg and mouth movements, as well as decreased autofluorescence.

Conclusions: Demodex folliculorum demonstrated resilience by persisting in the eyelash follicles of cadavers preserved through different methods, even after embalming. The findings challenge existing assumptions about the survival limits of these mites and underscore the need for further research in post-mortem conditions. Additionally, the study highlights the potential risks of parasitic infections for healthcare personnel working with cadavers and emphasizes the importance of awareness and preventive measures in such settings.

Keywords: Cadaver; Demodex folliculorum; Parasite.

Comment [B1]: Was the sample size of 4 large enough to make such conclusions, not seeing where the sample size was calculated

Introduction

The Demodex mite – of the phylum Arthropoda originates from the Greek words "Demos" meaning fat and "Dex" meaning worm[1]. Although there are about 65 species, two species known as *Demodex folliculorum* (DF) and *Demodex brevis* (DB) are the most common ectoparasites living in humans. These two species differ from each other in terms of their structural features and localization. DF is larger, typically measuring around 0.3 to 0.4 millimeters in length, and has a more elongated, worm-like shape with a tapered front end. On the other hand, DB is smaller, with an average length of about 0.2 to 0.3 millimeters, and has a shorter, stubbier appearance, and a more cylindrical body. DF is located at the root of the cilia with their heads attached to the lash root but DB is more common in the body, unlike DF, it is found alone deep in the glands[2].

Belonging to the arthropod family, Demodex has an exoskeleton covering its body, they have eight short articulated legs and tiny claws on its legs, which help them anchor themselves to the walls of hair follicles and move through the sebaceous glands. Apart from that, they reproduce internally, with males and females coming together within the hair follicle or gland. Demodex mites have specialized mouthparts called buccal appendages, which they use to feed on skin cells, sebum, and other debris in the hair follicles and sebaceous glands[3]. These mites do not have lungs. they obtain oxygen through diffusion across their body surface. They have an undeveloped digestive system and are even believed to have no anus and due to this anatomic difference they vomit the epithelial cells and lipid which they have eaten [4]. While they cause mechanical damage to the eyelash edge with their small claws, they inflict chemical damage with lipases and cytokines like IL-17, and MMP9 in their vomit and cause inflammation [5].

The prevalence of Demodex mites in humans is relatively high, with studies suggesting that a large portion of the population especially older age group carry these mites. They are considered as obligate ectoparasites, and they generally do not cause harm when their numbers remain in balance. However, their population can increase under certain conditions, leading to infestations and associated skin and eye conditions, especially depending on factors such as age, geographical

location, and overall health[4]. When these mites multiply out of control it is called "demodicosis"[6].In the literature Demodicosis has been associated with blepharitis, loss and misalignment of eyelashes, conjunctivitis, keratitis, and basal cell carcinoma of the lid [6,7]. A Demodex infestation can be diagnosed by examining the eyelashes and skin for the presence of cylindrical dandruff and using techniques such as lash sampling and microscopic examination.[8]. Treating a definitively diagnosed Demodex infestation presents a significant challenge as it requires complex and often long-term treatment. Systemic treatment of demodicosis is based on the administration of antibiotics such as Tetracycline, Doxycycline, Metronidazole, and Ivermectin. On the other hand, Metronidazole, Permethrin, Benzoyl Benzoate, Crotonol, Lindane, and Sulfur are among the most commonly used topical treatments for demodicosis. The overall goal of treatment is to prevent parasite growth, eradicate mites, and prevent reinfestation [9]. Treatment options for Demodex also include the use of botanical essential oils such as tea tree oil, camphor oil, sage oil, peppermint oil, neem oil, and clove oil, which have shown high efficacy and low side effects[10].

Although there are many studies that aim to investigate Demodex in patients with various skin diseases, research of Demodex in forensic autopsy cases is quite limited. Ozdemir et al. investigated the incidence and viability of demodex in forensic autopsies with a high risk of contamination and they detected live parasites in 10% of the cases[11]. According to current literature, there is no evidence of this parasite in the corpses whose forensic autopsy process has been completed and preserved with embalming fluids.

Material and Methods

This study was conducted in accordance with the tenets of the Declaration of Helsinki. In this study, we aimed to investigate DF and DB in the eyelash roots of fresh frozen cadavers preserved by different embalming methods. For this purpose, four human cadavers were examined in cooperation with the Department of Ophthalmology in the laboratory of the Department of Anatomy. Eyelash samples were epilated from the human cadavers and examined with a light microscope by an experienced ophthalmologist.

The microscopic examination protocol began with the collection of samples. By modifying the classical Coston method according to Gao's suggestion, we performed eyelash epilation, extracting a total of 8 eyelashes (4 from the lower eyelid and 4 from the upper eyelid) from every cadaver's eyes using special fine forceps. Then, for sample preparation, the samples were placed on a glass slide and mixed with an olive oil solution. This solution helps to clear the sample, make the mites more visible under the high-resolution digital microscope (Bresser-Biolux Touch LCD, Bresser GmbH), and is a non-toxic medium for the viability of the demodex. It is shown in Figures 1A and 1B.

Demographic information of all sample cadavers is shown in Table 1. For the cadavers of samples A and B, the cause of death was reported as pending. Also the cause of death was reported as natural death for the cadaver of sample C and congestive heart failure due to atherosclerotic heart disease for the cadaver of sample D.

Gastrointestinal, urinary, and endocrine system or neurological, periodontal, dermatological, and infectious diseases were not reported in any of the cadavers. The cadaver of sample A had a history of hypertension, was connected to a heart monitor, and had undergone cataract surgery. The cadaver of sample B had suffered a stroke 5 years ago and was bedridden. Cirrhosis was reported in the cadaver of sample C, and pulmonary embolism and deep vein thrombosis were reported in the cadaver of sample D.

The cadavers of samples A and B were freshly frozen. These cadavers, which did not undergo any embalming process, were kept in the morgue at -20 degrees for 20 months. After the death of the cadaver belonging to the C sample, it was preserved for 20 months in the morgue at -20 degrees without any embalming process. Then it was embalmed and placed in a cadaver pool consisting of embalming fluid. This embalming fluid in the cadaver pool contained phenol, formal, glycerine, thymol, ethanol, and water. After being in the cadaver pool for 7 days, samples were taken for microscopic examination. The cadaver of sample D was embalmed as soon as it died and was preserved for 24 months in the morgue at -20°C.

Results

As a result of microscopic examination, DF was detected in all cadaver samples. Some of the DF mites preserved in the eyelashes of cadavers are shown in Figure 2. The skeletons of these DF mites were evident at the base of the eyelashes, especially in areas where oil residues were concentrated. The sign of death for DF has been defined as cessation of movements of the legs or mouth and decreased autofluorescence [12]. The mites detected in this study had the defined death signs.

Comment [B2]: It would be interesting to also note how much of DF was detected in the cadavers

Discussion

DF is a mite that lives on human hosts. Human body temperature between 36.5 and 37.5 °C (97.7 to 99.5 °F) provides suitable temperature range conditions for DF, which can survive between 5°C and 37°C. Maldonado et al. reported that the maximum survival time of DF under in vitro maintenance conditions using RPMI-1640 supplemented with human serum was 15.20 ± 1.03 days at 20 °C [13]. The mites can survive better at low temperatures than at high temperatures. However extreme temperatures below 0°C or above 37°C are harmful to their survival [14]. The most suitable maintenance temperature for DF is 5°C, while the optimal temperature for their development in vitro is 16-22°C. In our study, it was an expected finding that DF did not exhibit vitality due to the temperature maintained in the morgue and the pool. The longest reported survival time of DF under in vitro conditions was 15.20 ± 1.03 days at 20°C. The lethal temperature for DF is 54°C, and the effective temperature for mite death is 58°C [15].

Demodex folliculorum is generally considered to be photosensitive. These mites are typically more active during the night, which suggests they prefer darkness. This behavior is thought to be related to their avoidance of light and potential heat generated by sunlight which has an oxidation effect. Activated by the host's melatonin, they come out of the eyelash follicles and they mate by going to the edge of the eyelashes [16].

Transmission of Demodex between hosts is a complex subject. While the exact mechanism of invasion remains unclear, it is believed to occur through direct contact between individuals [4]. Today, ectoparasites and various microorganisms pose significant risks to healthcare personnel due to accidents and careless procedures. Healthcare workers, especially those in autopsy rooms or handling cadavers for educational purposes, face an increased risk of infection. This risk is further elevated in cases involving individuals with compromised skin integrity. Given these factors, it is crucial for students and educators who work with cadavers in Anatomy laboratories to be aware of potential parasitic infections.

conclusion

In conclusion, this study delved into an unexplored realm, investigating the presence of Demodex mites in the eyelash follicles of cadavers preserved under different embalming methods. Surprisingly, the study revealed the persistence of Demodex folliculorum in all cadaver samples, even in those that had undergone embalming. These findings shed light on the resilience of these mites under various conditions and temperatures, challenging prior assumptions about their survival limits.

Furthermore, the study emphasized the potential risks of parasitic infections for healthcare personnel, particularly those working with cadavers in autopsy rooms or educational settings. It underscores the importance of awareness and precautions to prevent infections among individuals, especially when dealing with cadavers in anatomy laboratories.

References

- 1- Coston, T.O., 1967. Demodex folliculorum blepharitis. Transactions of the American Ophthalmological Society. 65, p. 361.

Comment [B3]: How do we then reach this conclusion that Health workers are at risk when the study is indicating there were no live Demodex in the cadavers

- 2- Liu, J., Sheha, H., & Tseng, S. C. G., 2010. Pathogenic role of Demodex mites in blepharitis. *Current Opinion in Allergy and Clinical Immunology*. 10(5), 505. <https://doi.org/10.1097/ACI.0B013E32833DF9F4>
- 3- Wolf, R., Ophir, J., Avigad, J., Lengy, J., Krakowski, A., 1988. The hair follicle mites (*Demodex* spp.). Could they be vectors of pathogenic microorganisms? *Acta Dermatovenereologica*. 68(6).
- 4- Bitton, E., Aumond, S., 2021. Demodex and eye disease: a review. *Clinical and Experimental Optometry*. pp. 285–294. <https://doi.org/10.1111/cxo.13123>.
- 5- Kim, J. T., Lee, S. H., Chun, Y. S., Kim, J. C., 2011. Tear cytokines and chemokines in patients with Demodex blepharitis. *Cytokine*, 53(1). <https://doi.org/10.1016/j.cyto.2010.08.009>
- 6- Luo, X., Li, J., Chen, C., Tseng, S., Liang, L., 2017. Ocular demodicosis as a potential cause of ocular surface inflammation. *Cornea*. 36(Suppl 1), S9. <https://doi.org/10.1097/ICO.0000000000001361>.
- 7- Cheng, A.M.S., Sheha, H., Tseng, S.C.G., 2015. Recent advances on ocular Demodex infestation, *Current Opinion in Ophthalmology*. 26(4), pp. 295–300. <https://doi.org/10.1097/ICU.0000000000000168>.
- 8- Huang, C. X., Li, H. G., Luo, H. Q., Fu, Q. M., He, B. S., Bao, M. H., 2021. Essential oils for the treatment of demodex. *E3S Web of Conferences*. 271. <https://doi.org/10.1051/e3sconf/202127104034>
- 9- Jacob, S., VanDaele, M. A., Brown, J. N., 2019. Treatment of Demodex-associated inflammatory skin conditions: A systematic review. *Dermatologic Therapy*. Vol. 32. <https://doi.org/10.1111/dth.13103>
- 10- Jacobi, C., Doan, S., Pavel, V., Chiambaretta, F., Kärcher, T., 2022. Different approach to manage demodex blepharitis—initial and maintenance treatment. *Current Eye Research*. 47(3). <https://doi.org/10.1080/02713683.2021.1978099>

- 11- Özdemir, M. H., Aksoy, U., Akisu, Ç., Sönmez, E., & Çakmak, M. A., 2003. Investigating demodex in forensic autopsy cases. *Forensic Science International*. 135(3), 226–231. [https://doi.org/10.1016/S0379-0738\(03\)00216-0](https://doi.org/10.1016/S0379-0738(03)00216-0)
- 12- Gatault, S., Foley, R., Steinhoff, M., Powell, F., 2016. 352 Autofluorescence of Demodex mites is related to motility. *Journal of Investigative Dermatology*, 136(9). <https://doi.org/10.1016/j.jid.2016.06.372>.
- 13- Maldonado, H., Mendoza, D., Garavito, G., Lizarazo, M., Escaf, L., Egea, E., 2021. Enhancing survival of *Demodex folliculorum* (Acari: Demodicidae) under in vitro condition: Effect of temperature and culture media. *Persian Journal of Acarology*. 10(4). <https://doi.org/10.22073/pja.v10i4.69561>
- 14- Zhao, Y. E., Guo, N., Wu, L. P., 2011. Influence of temperature and medium on viability of *Demodex folliculorum* and *Demodex brevis* (Acari: Demodicidae). *Experimental and Applied Acarology*, 54(4). <https://doi.org/10.1007/s10493-011-9445-5>
- 15- Zhao, Y. E., Guo, N., Wu, L. P., 2009. The effect of temperature on the viability of *Demodex folliculorum* and *Demodex brevis*. *Parasitology Research*. 105(6). <https://doi.org/10.1007/s00436-009-1603-x>
- 16- Smith, G., Manzano-Marin, A., Reyes-Prieto, M., Antunes, C. S. R., Ashworth, V., Goselle, O. N., ... Braig, H. R., 2022. Human follicular mites: ectoparasites becoming symbionts. *Molecular Biology and Evolution*. 39(6). <https://doi.org/10.1093/molbev/msac125>

Table 1: Demographic information of sampled cadavers.

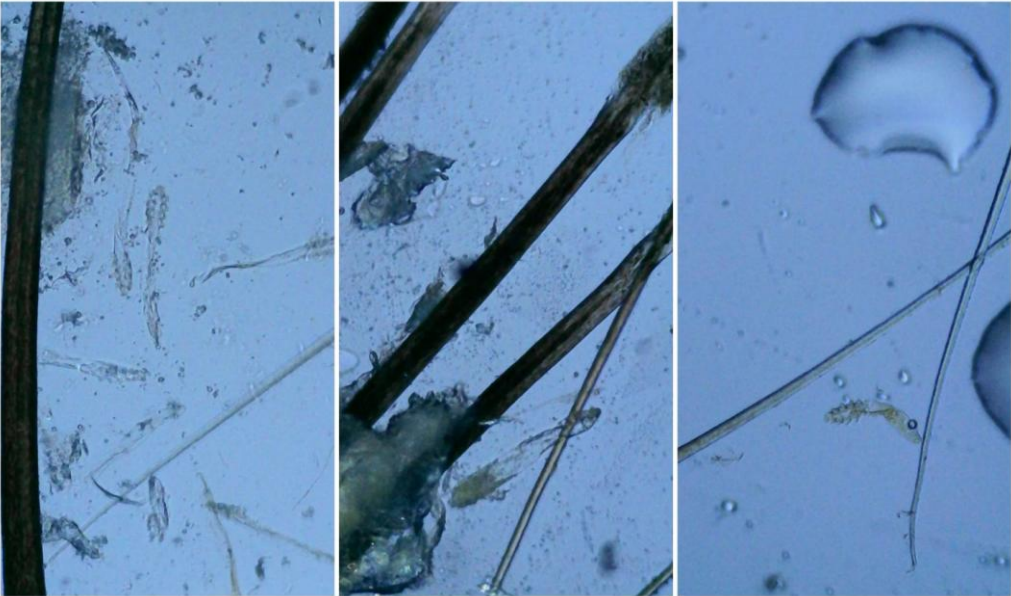
Sample	Gender	Age	Weight (<i>pound</i>)	Height (<i>inch</i>)	BMI
A	Female	79	260	63	46.1
B	Female	71	150	65	25.0
C	Female	77	200	62	36.6
D	Male	67	151	73	20.5

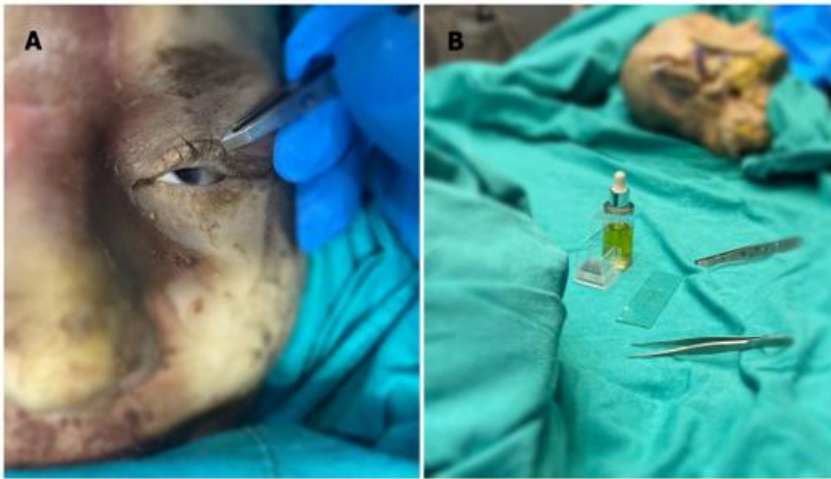

Figure 1: Microscopic examination protocol of samples.

A: taking the eyelash sample from the upper eyelid, B: placing the sample on

Figure 2: Microscopic image of *Demodex folliculorum*.



UNDER PEER REVIEW