

Harlequin Ichthyosis: A Rare skin disorder

Abstract

Harlequin ichthyosis, an exceptionally rare and severe genetic skin disorder, presents a unique intersection of genetics, skin biology, and clinical manifestation. This congenital condition, a severe form of ichthyosis, has captivated the medical community due to its striking clinical features. It arises from genetic mutations in the ABCA12 gene, disrupting skin barrier formation. The clinical presentation is characterized by diamond-shaped scales, facial distortions, and medical challenges, particularly in neonates. Historical accounts have contributed to our evolving understanding, culminating in recent genetic advancements. While no cure exists, treatment involves a combination of medical interventions and supportive care. The psychosocial impact on affected individuals and families is profound. Despite challenges, the future is promising, driven by genomics, precision medicine, novel therapies, and collaborative research. Harlequin ichthyosis represents a remarkable example of progress at the intersection of science and compassion.

Keywords:- Harlequin ichthyosis, genetic mutation, congenital disorder.

Introduction: -

Harlequin ichthyosis, an exceptionally rare and severe genetic skin disorder, stands as a poignant example of the intricate relationship between genetics, skin biology, and clinical manifestation. This congenital condition belongs to the broader spectrum of ichthyoses, a group of hereditary skin disorders characterized by aberrant scaling and thickening of the skin. Harlequin ichthyosis, in particular, represents one of the most severe and visually distinctive forms within this spectrum, captivating the attention of researchers, clinicians, and the medical community as a whole. With an estimated incidence of just one in several hundred thousand births, Harlequin ichthyosis remains a medically and genetically intriguing anomaly. This disorder's origin lies in a genetic mutation affecting the ABCA12 gene, crucial for the formation of the skin barrier. Mutations in this gene lead to a deficient production of the lipid transporter ABCA12, which is pivotal in the complex process of skin development and maintenance. (1,2)

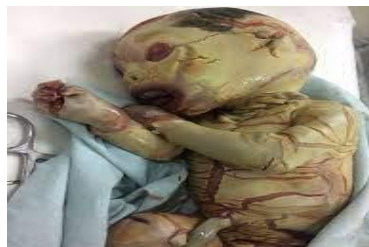

Figure 1- Appearance of Harlequin ichthyosis

Clinical manifestations: -

Clinical Presentation of Harlequin Ichthyosis:

- Instantly recognizable and evokes fascination and empathy.
- Newborns display a unique appearance resembling fish scales and armor.
- Skin texture is deeply cracked, forming a diamond-shaped pattern.
- Resembles a harlequin's costume due to thickened and scaled skin.
- Facial distortions and functional limitations are evident.
- Skin Abnormalities and Facial Distortions:
 - 1) Affects eyelids, nose, mouth, and ears.
 - 2) Limits movement of arms and legs.
 - 3) Restricts chest movement, leading to breathing difficulties.
 - 4) Feeding problems are common.
- Medical Challenges:
 - 1) Skin disruptions hinder protective barrier function.
 - 2) Difficulty in regulating water loss and body temperature.
 - 3) Susceptibility to infections due to compromised barrier.
 - 4) Excessive dehydration and life-threatening infections.
 - 5) Survival was rare in the past.
- Post-Newborn Period:
 - 1) Skin plates shed, revealing widespread scales and redness.
 - 2) Improved survival due to medical support and treatment.
 - 3) Infants have a better chance of living into childhood and adulthood. (1,2)

History: -

The history of Harlequin ichthyosis is marked by a series of historical accounts that have contributed to our evolving comprehension of this rare genetic disorder. While the term "harlequin" originally referred to a character in Italian theatre known for its distinctive diamond-patterned costume, the condition itself remained largely enigmatic until recent advancements in genetics and medical understanding provided greater clarity. This historical data offers insights into the progressive development of our knowledge about Harlequin ichthyosis:

Early Historical Depictions:

Historical records from the past include intriguing descriptions of infants born with scales forming diamond shapes akin to a harlequin's attire. These early references, often steeped in mysticism and lacking scientific understanding, documented the visual characteristics that we now identify with Harlequin ichthyosis.

18th and 19th Centuries:

During the 18th and 19th centuries, sporadic reports emerged of individuals exhibiting severe skin irregularities resembling the distinctive harlequin pattern. These historical accounts, while not medically accurate, contributed to recognizing the unique clinical presentation associated with Harlequin ichthyosis.

Stephan Bibrowski ("Lionel the Lion-faced Man"):

A significant moment in the history of Harlequin ichthyosis involves Stephan Bibrowski, who gained attention as "Lionel the Lion-faced Man" during the late 19th and early 20th centuries. Although not definitively confirmed, Bibrowski's exceptional appearance and skin condition are believed to align with the characteristics of Harlequin ichthyosis. This case stands as one of the initial instances of public awareness of the disorder.

Advancements in Medical Understanding:

The true breakthrough in comprehending Harlequin ichthyosis arrived with advancements in genetics and dermatology. The identification of mutations within the ABCA12 gene and their role in the formation of the skin barrier marked a pivotal juncture in understanding the disorder's underlying molecular mechanisms.

Recent Cases and Contemporary Progress:

In more contemporary times, cases like the one reported in Odisha, India, on 22 April 2021. The baby girl was born to a 30-year-old woman at a hospital in Berhampur in the state's Ganjam district, who has multiple congenital anomalies, Santosh Kumar Mishra, superintendent of the medical college and hospital, said. The facial features of the baby, including the mouth, eyes and ears were deformed, restricting breathing and eating. The baby was kept in the intensive care unit. The condition of the mother was good, Indira Palo, assistant professor at the college and hospital's gynaecology department, said the disease affected one in three million births and is caused due to a mutated gene inherited from the parents.

Harlequin baby dies two days after birth in Nagpur-

After fighting for her life for two days, a baby girl in Nagpur who was born with a rare congenital condition with almost no exterior skin passed away on Monday. The 1.8 kilogram girl had thick slabs of broken, hardened skin covering her body, revealing her internal organs. She was diagnosed with Harlequin Ichthyosis, a disease that affects one in 300,000 births. She passed away at the privately run Lata Mangeshkar Medical College and Hospital on Monday morning after being put on oxygen. She was born on Saturday to a 23-year-old Amravati, Maharashtra's Vidarbha region resident. Her grandma and the infant's impoverished Amravati farmer father were taken aback upon seeing her. They have acknowledged the circumstances, though," Dr. Kajal Mitra remarked. The baby was placed on a ventilator because of respiratory issues that started in the morning. According to the experts, the illness wasn't identified sooner since the mother wasn't a frequent patient at the hospital. "Conventional ultrasonography is not able to detect skin disorders, particularly Harlequin Ichthyosis," noted Dr. Mitra.

Aetiology:-

The aetiology of Harlequin ichthyosis lies in genetic mutations that disrupt the normal development of the skin's barrier function and epidermal differentiation. This rare and severe disorder is primarily attributed to mutations in the ABCA12 gene, which encodes a transmembrane protein responsible for lipid transport and plays a critical role in maintaining the integrity of the skin barrier. (3)

1. Harlequin ichthyosis is primarily inherited in an autosomal recessive manner, meaning that an affected individual inherits two copies of the mutated ABCA12 gene, one from each parent. The ABCA12 gene mutations lead to the dysfunction of the ABCA12 protein, resulting in impaired lipid transport in the epidermis.(4)

2.The ABCA12 protein is integral to the transport of lipids, particularly lipids that contribute to the formation of the skin's protective lipid barrier. This lipid barrier is crucial for retaining moisture, preventing dehydration, and protecting against environmental factors. Mutations in the ABCA12 gene disrupt lipid transport, leading to the characteristic skin abnormalities seen in Harlequin ichthyosis.(5)

3. Proper epidermal differentiation is essential for the formation of a functional skin barrier. The disruption of lipid transport due to ABCA12 mutations results in abnormal keratinocyte differentiation, leading to the accumulation of thickened, hard scales. The skin's inability to shed these scales effectively and maintain appropriate moisture levels contributes to the severe dryness and cracking seen in Harlequin ichthyosis.(6)

4.The combination of impaired lipid transport and disrupted epidermal differentiation causes the skin to form large, diamond-shaped plates separated by deep fissures. This distinctive pattern gives rise to the harlequin-like appearance that characterizes the disorder.

5. The compromised skin barrier in Harlequin ichthyosis has broader physiological consequences beyond cosmetic appearance. It can impair temperature regulation, hinder fluid balance, and increase susceptibility to infections. The skin's rigidity and fissures can also limit movement and lead to complications in breathing and feeding, particularly in neonates.

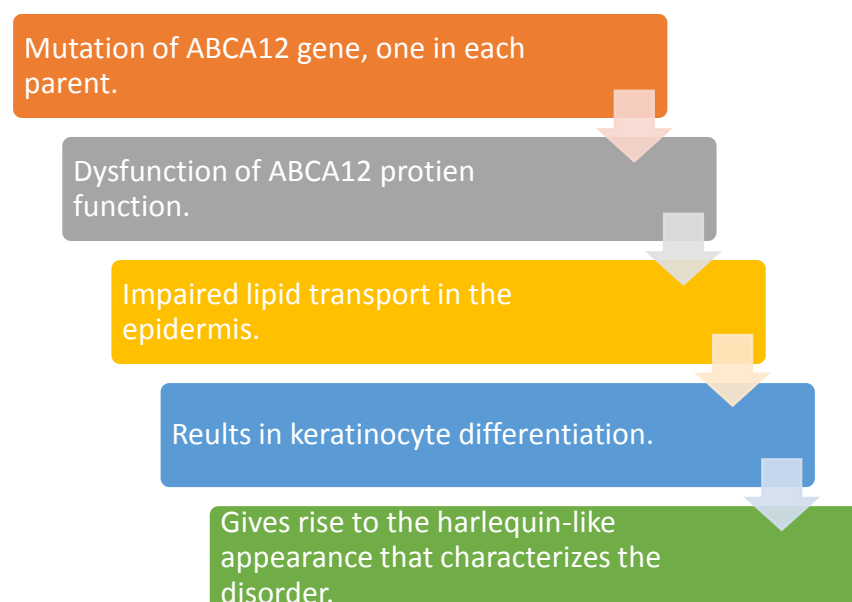


Figure 2 Pathophysiology of Harlequin ichthyosis

Signs and symptoms:-

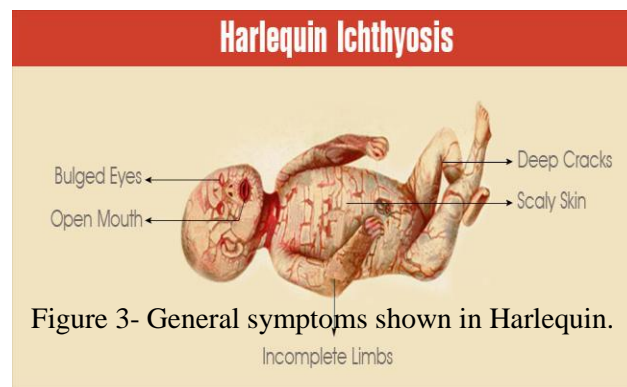
In New Borns:

Babies with Harlequin ichthyosis are usually born prematurely. That means they may have a higher risk of other complications as well.

The sign people usually first notice is hard, thick scales all over the body, including the face. The skin is pulled tightly, causing the scales to crack and split open.

This hardened skin can cause a number of serious issues, including:

- Eyes not closing.
- Lips pulled tight, leaving the mouth open and making nursing difficult.
- Ears fused to the head.
- Small, swollen hands and feet.
- Limited mobility in arms and legs.
- Nursing difficulties.
- Breathing problems due to tight chest skin.



In Older Children & Adult:

Children with Harlequin ichthyosis may experience a delay in physical development. But their mental development is usually on track with other children their age.

A child born with Harlequin ichthyosis will likely have red, scaly skin throughout their life.

They may also have:

- Sparse or thin hair as a result of scales on the scalp.
- Unusual facial features due to stretched skin.
- Reduced hearing from a build-up of scales in the ears.
- Problems with finger movement due to tight skin.
- Thick fingernails.
- Recurring skin infections.
- Overheating due to scales that interfere with sweating. (7, 8)

Diagnosis:-

Although no cure exists for Harlequin ichthyosis, advancements in medical care have significantly improved patient outcomes [9]. The diagnosis of Harlequin ichthyosis involves a comprehensive approach that includes clinical evaluation, genetic testing, and dermatological assessments. Due to the rarity and severity of the disorder, accurate diagnosis

is essential for appropriate medical management and genetic counselling. The key diagnostic steps are as follows:

1. Clinical Examination:

- A thorough clinical examination is conducted to assess the characteristic signs and symptoms of Harlequin ichthyosis, including the presence of diamond-shaped skin plates, deep fissures, and other skin abnormalities.
- The unique appearance of the skin is often sufficient for preliminary diagnosis.

2. Dermatological Evaluation:

- Dermatologists play a critical role in evaluating the skin's condition and assessing the severity of scaling, cracking, and constrictions.
- Skin biopsies may be performed to examine the histological features of the affected skin.

3. Genetic Testing:

- Genetic testing is a pivotal diagnostic tool for confirming Harlequin ichthyosis. It involves identifying mutations in the ABCA12 gene.
- Molecular genetic testing, including DNA sequencing, can reveal specific mutations associated with the disorder [10].

4. Prenatal Diagnosis:

- For families with a history of Harlequin ichthyosis or known carriers of ABCA12 mutations, prenatal diagnosis can be pursued.
- Prenatal testing involves genetic analysis of fetal DNA obtained through chorionic villus sampling (CVS) or amniocentesis [11].

Treatment:-

Due to the severity of the condition, treatment strategies often involve a combination of medical interventions and supportive care. The following are key components of the treatment approach:

1. Skin Care and Hydration:

- Regular application of emollients and moisturizers helps alleviate skin dryness and scaling.
- Bathing routines should include lukewarm water and mild cleansers to prevent further drying of the skin [12].

2. Topical Treatments:

- Topical retinoids and keratolytics may be prescribed to help reduce the thickness of the scales and promote shedding.
- These treatments require careful monitoring due to the potential for skin irritation [13].

3. Systemic Retinoids:

- In severe cases, systemic retinoids like isotretinoin may be considered to manage scaling and improve skin condition.
- Systemic retinoids require close medical supervision due to potential side effects [14].

4. Supportive Care:

- Addressing complications like infections and limiting skin constriction is essential.

- Protecting the eyes, maintaining fluid balance, and ensuring proper nutrition are crucial aspects of supportive care [15].

With improved neonatal facilities, infants born today have a better chance of living longer, healthier lives but early, intensive treatment is vital. A new-born with Harlequin ichthyosis requires neonatal intensive care, which may include spending time in a heated incubator with high humidity. Tube feeding can help prevent malnutrition and dehydration. Special lubrication and protection can help keep eyes healthy.

Other initial treatments might include:

- Applying retinoid to help shed hard, scaly skin.
- Applying topical antibiotics to prevent infection.
- Covering the skin in bandages to prevent infection.
- Placing a tube in the airway to help with breathing.
- Using lubricating eye drops or protective devices on the eyes [8, 16].

Psychosocial Impact on Patients with Harlequin Ichthyosis:

Harlequin ichthyosis is not only a physically demanding condition but also has profound psychosocial implications on affected individuals and their families. The visible and severe nature of the disorder can lead to a range of emotional, psychological, and social challenges:

- Body Image and Self-Esteem
- Social Isolation and Stigma
- Mental Health Challenges like stress, anxiety, depression, etc.
- Educational and Vocational Challenges
- Family Dynamics
- Quality of Life
- Coping Strategies and Support

Future prospectus:-

The future outlook for Harlequin ichthyosis is characterized by optimism and potential, driven by remarkable strides in genetics, molecular biology, and innovative therapies. Genomic advancements have illuminated the genetic mutations at the heart of the disorder, while precision medicine holds promise in tailoring treatments to individual genetic profiles, including groundbreaking approaches like gene therapy. Ongoing research targets the core defects in skin barrier function, exploring strategies to normalize lipid transport and promote healthy skin development. Stem cell and regenerative therapies offer hope for repairing damaged skin tissue. Equally important are advancements in psychosocial support, addressing the emotional impact on individuals and families. Collaboration among researchers, clinicians, and advocacy groups fosters collective progress. Amidst the challenges, the convergence of scientific breakthroughs, technology, and compassionate care instills hope for a brighter future, where those with Harlequin ichthyosis can experience improved outcomes and enhanced well-being.

Conclusion:

Harlequin ichthyosis, an enigmatic genetic skin disorder, has traversed a complex historical journey from myth and mysticism to modern scientific understanding. This rare condition, characterized by its distinctive clinical presentation, has posed significant medical challenges, particularly in neonates. Genetic insights into ABCA12 mutations have paved the way for improved diagnosis and the potential for precision therapies. While there is no cure, advancements in treatment and supportive care offer hope for enhanced quality of life. The psychosocial impact cannot be underestimated, emphasizing the importance of holistic care. Looking to the future, collaborative research, innovative therapies, and compassionate support herald a brighter outlook for those affected by Harlequin ichthyosis. As science and empathy converge, we navigate a path toward improved outcomes and well-being for individuals and families facing this rare and complex genetic disorder.

Reference:-

1. Valerio E, Barlotta A, Lorenzon E, Antonazzo L, Cutrone M. Harlequin Color Change: Neonatal Case Series and Brief Literature Review. *AJP Rep.* 2015 Apr;5(1):e73-6.
2. Tsuboi K, Tsuboi N, Nosaka N, Nishimura N, Nakagawa S. Neonatal Harlequin color change associated with Prostaglandin E1 administration. *Pediatr Int.* 2021 May;63(5):610-611.
3. Grall A, Guaguère E, Planchais S, et al. PNPLA1 mutations cause autosomal recessive congenital ichthyosis in golden retriever dogs and humans. *Nat Genet.* 2012;44(2):140-147.
4. Akiyama M. Harlequin ichthyosis and other autosomal recessive congenital ichthyoses: the underlying genetic defects and pathomechanisms. *J Dermatol Sci.* 2006;42(2):83-89.
5. Elias PM, Williams ML, Holleran WM, et al. Pathogenesis of permeability barrier abnormalities in the ichthyoses: inherited disorders of lipid metabolism. *J Lipid Res.* 2008;49(4):697-714.
6. Elias PM, Williams ML, Holleran WM, et al. Pathogenesis of permeability barrier abnormalities in the ichthyoses: inherited disorders of lipid metabolism. *J Lipid Res.* 2008;49(4):697-714.
7. Cheshire WP, Low PA. Harlequin syndrome: still only half understood. *J Neuroophthalmol.* 2008 Sep;28(3):169-70.
8. Carroll CB, Zajicek JP. The 'harlequin' sign in association with multiple sclerosis. *J Neurol.* 2004 Sep;251(9):1145-6.
9. Oji V, Tadini G, Akiyama M, et al. Revised nomenclature and classification of inherited ichthyoses: results of the First Ichthyosis Consensus Conference in Sorèze 2009. *J Am Acad Dermatol.* 2010;63(4):607-641.
10. Fischer, J. (2009). Autosomal Recessive Congenital Ichthyosis. *Journal of Investigative Dermatology*, 129(6), 1319–1321. doi:10.1038/jid.2009.72

11. Hackett, C. B., & Lee, H. J. (2017). Prenatal Diagnosis of Harlequin Ichthyosis Using a Targeted Next- Generation Sequencing Panel. *Pediatric Dermatology*, 34(3), e172–e174. doi:10.1111/pde.13123
12. Vahlquist, A., Bygum, A., Gånemo, A., Virtanen, M., Hellström-Pigg, M., Strauss, G., & Brandrup, F. (2018). Genotypic and Clinical Spectrum of Self-Improving Collodion Ichthyosis: ALOX12B, ALOXE3, and TGM1 Mutations in Scandinavian Patients. *Journal of Investigative Dermatology*, 138(2), 421–429. doi:10.1016/j.jid.2017.09.013
13. Rajpopat, S., Moss, C., Mellerio, J., Vahlquist, A., Gånemo, A., Hellström-Pigg, M., ... McGrath, J. (2011). Harlequin Ichthyosis: A Review of Clinical and Molecular Findings in 45 Cases. *Archives of Dermatology*, 147(6), 681–686. doi:10.1001/archdermatol.2011.40
14. Vahidnezhad, H., Youssefian, L., Saeidian, A. H., Zeinali, S., Sotoudeh, S., & Uitto, J. (2017). Harlequin Ichthyosis, a Systematic Review of Therapeutic Outcome Reports and an Analysis of Patient-Derived Data. *Journal of Dermatological Treatment*, 29(5), 470–475. doi:10.1080/09546634.2017.1318344
15. Judge, M. R., McLean, W. H., & Munro, C. S. (2005). Disorders of Keratinization. In *Rook's Textbook of Dermatology* (8th ed., pp. 19.1-19.73). John Wiley & Sons.
16. Wilson J, Fisher R, Caetano F, Soliman-AboumarieH, Patel B, LedotS, Price S, VandenbrieleC. Managing Harlequin Syndrome in VA-ECMO -do not forget the right ventricle. *Perfusion*. 2022 Jul;37(5):526-529.