

## Ultrasonography as a tool in assessment of breast pain among women

### ABSTRACT

**Background:** Breast pain or mastalgia is a common breast symptom in women after breast lump. The increase in awareness of breast cancer and the possibility that a breast pain may be associated with underlying breast disease prompt women to seek medical attention. Ultrasound is a valuable imaging modality in evaluation of breast pain and breast diseases in general.

**Objectives:** To determine the role of ultrasound and the outcome of breast ultrasound among women with breast pain.

**Methods:** This cross-sectional descriptive study was conducted on 87 women who were referred for ultrasound scan on account of breast pain from July 2015 - December 2016 at radiology department of UATH. A high frequency linear transducer 7.5 MHz of EMP G70 ultrasound machine manufactured by Shenzhen Emperor Electronic Technology®, China 2011 was used in scanning the breast.

**Result:** The mean age of study population was  $32 \pm 15$  years with age range of 16 and 69 years. Majority of the patients were in the age group 30-39 years representing 54.0%. 32(36.8%) of women with breast pain had abnormal ultrasound findings. Sonographic findings included mass 13 (14.9%), cyst 10 (11.5%), ductal dilation 4(4.6%), calcification 3(3.5%), architectural distortion 2(2.3%). BIRADS 1 (normal/negative) was the commonest category seen in 55(63.2%) of patients, 21(24.1%) were benign (BIRADS 2), 6(6.4%) were probably benign (BIRADS 3), 3(3.4%) were suspicious BIRADS 4 and 2(2.3%) were highly suggestive of malignancy BIRADS 5. There was positive correlation between ultrasound findings with age This was however not statistically significant ( $P=0.67$ ). There was positive correlation between abnormal ultrasound findings with type of pain ( $P=0.08$ ), location of pain ( $P=0.63$ ), contraception ( $P=0.39$ ), and family history of breast cancer ( $P=0.11$ ). However, this was not statistically significant

**Conclusion:** Evaluation of breast pain in a woman is very essentially not only to alleviate her fears but also to detect any abnormalities which may require treatment medically or surgically. Ultrasound is an important imaging tool in evaluating women with breast pain.

**Key words:** Breast cancer, ultrasound, breast pain, women, Nigeria

### Introduction

Breast pain, breast lump and nipple discharge are common breast presentation which require evaluation. Breast pain is common in female and the second most frequent breast symptom after breast lump for which women seek for medical help<sup>1,2</sup>. The reasons most women with breast pain seek for medical attention may not be farfetched from the increase awareness of breast cancer and the concerned that breast pain may be related to underlying breast diseases causing anxiety in them.<sup>2,3</sup> About 70-80% of women in their life time at some point have presented for a breast imaging as a result of pain in the breast<sup>1</sup>.

The aetiology of breast pain is not known, however multiple factors have been postulated to be responsible for breast pain among which include hormonal disturbance, use of hormonal medications (hormonal replacement therapy, oral contraceptives) and psychological factors<sup>1,3</sup>. Breast pain is of two types according to clinical classification: cyclical and non-cyclical with each having a possible different underlying physiology<sup>1,4</sup>.

Breast pain is not a common symptom associated with breast cancer but some studies have suggested that cyclical pain especially in postmenopausal women may be an independent and useful clinical marker for increased risk of breast cancer<sup>5,6</sup>. A prevalence of 0-3.2% for breast cancer has been reported among women presenting with breast pain.<sup>3,7,8</sup> The value of breast imaging in breast pain may not be clearly stated in the literature however; breast imaging in evaluating breast pain may not only be to exclude breast cancer but may also be helpful in detecting any underlying pathology which may be treatable<sup>1</sup>. Combination of mammography and ultrasound plays a significant role in evaluation of the breast especially after the age of 40 years while ultrasound scan usually the first imaging modality to rule out breast mass in young women and in women with mammographically dense breast<sup>9</sup>. The aim of this study is to determine the role of ultrasound and the outcome of breast ultrasound among women with breast pain.

## **Methodology**

**STUDY DESIGN:** This was a descriptive cross-sectional study which spanned from July 2015 - December 2016.

**STUDY AREA:** This study was carried out at the radiology department of University of Abuja teaching hospital, Gwagwalada, (F.C.T). The Hospital is located in Gwagwalada whose geographical coordinates are 8° 56' 29" North and 7° 5' 31" East.

**STUDY POPULATION:** This comprising of 87 women who met the inclusion criteria. Data obtained include social demography variables, characteristic of breast pain, ultrasound findings and Breast

Imaging, Reporting and Data System descriptor (BIRADS) classification of abnormalities detected on ultrasound.

### **INCLUSION CRITERIA**

- i. Women who were referred from the general outpatient's department on account of breast pain.
- ii. Women within the ages of 16-70 years.
- iii. Women that consented to participate in the study.

### **EXCLUSION CRITERIA**

- i. Women with palpable mass
- ii. Previous surgery

### **Breast ultrasound**

Ultrasound of the breast was done using a high frequency linear transducer 7.5 MHz of EMP G70 ultrasound machine manufactured by Shenzhen Emperor Electronic Technology®, China 2011. Patients were told to lie supine slightly in oblique position on the couch with hand raised and placed under the neck for examination of each breast. Each breast was examined physically by the radiologist and patients were told to use their index finger to localise the pain in the breast. Coupling gel was applied over the skin of the breast, right breast then left. The breast was scanned radially in both transverse and longitudinal planes. Ultrasound findings were noted and categorise using Breast Imaging, Reporting and Data System descriptor. All scans were done by consultant radiologist.

### **Data analysis**

Data was analysed using SPSS 19.0 software 2010 by IBM<sup>R</sup> USA. The chi square-test was used to establish any statistical difference. Probability values of <0.05 was considered as statistically significant.

## **RESULT**

There were eight –seven patients who presented with breast pain without palpable mass and were referred for breast ultrasound scan. The mean age of study population was 35±15years with age range of 16 and 68 years. Majority of the patients were in the age group 30-39 years and 20-29 years representing 54.0% and 28.7% respectively. Table 1.

**Table 1: Age distribution among women with breast pain in Abuja.**

Age group (years)	Freq	%
≤20	3	3.4
21-29	25	28.7
31-39	47	54.0
41-49	7	8.0
51-59	3	3.4
61-69	2	2.3
	87	100

Among the women studied, 45(51.7%) of the patients were married. 49(56.3%) of patient had between 1-4 children and 17(19.5%) were nulliparous. Only 31(35.6%) of the patients recruited use contraceptive. 6(6.9%) of the patient were on hormonal replacement therapy. Majority of the patients were premenopausal representing 68(78.2%) and 19 (21.8%) were postmenopausal. 15(17.2%) had family history of breast cancer and 72(82.8%) without family history of cancer. Table 2.

**Table 2: Social demographic variables of women with breast pain in Abuja**

Variables	Freq	%
-----------	------	---

---

**Marital status**

Married	45	51.7
Single	27	31.0
Divorce	15	17.3

**Parity**

0	17	19.5
1-4	49	56.3
>5	21	24.1

**Contraceptive usage**

No	56	64.4
Yes	31	35.6

**Family history of breast cancer**

Yes	15	17.2
No	72	82.8

**Hormonal therapy**

Yes	6	6.9
No	81	93.1

Premenopausal	68	78.2
Postmenopausal	19	21.8

The characteristic of breast pain among study group was cyclical in 37.9%, acyclical in 62.1%. In 28.7%, pain was focal and 71.3% it was diffuse. Pain was unilateral in 64.4% and bilateral in 35.6%.  
Table 3.

**Table 3: Characteristic of breast pain among women in Abuja**

Characteristic of pain	Freq	%
<b>Type of pain</b>		
Cyclical	33	37.9
Acyclical	54	62.1
<b>Localization of pain</b>		
Diffuse	62	71.3
Focal	25	28.3
<b>Site of pain</b>		
Unilateral	56	64.4
Bilateral	31	35.6

In 55(63.2%) of patients, ultrasound findings were normal and abnormal in 32(36.8%). Abnormal ultrasound findings include: mass 13 (14.9%), cyst 10 (11.5%), ductal dilation 4(4.6%), calcification 3(3.5%), architectural distortion 2(2.3%). There was positive correlation between ultrasound findings with age This was however not statistically significant ( $P=0.67$ ) Table 4.

**Table 4: Ultrasound findings with age among patients with breast pain**

Ultrasound findings	<20	20-29	30-39	40-49	50-59	60-69	<i>P</i> -value	
Normal	55(63.2)	3(100.0)	19(76.0)	32(68.1)	1(14.3)	0(0.0)	0(0.0)	0.67
Mass	13(11.9)	0(0.0)	3(12.0)	5(10.6)	4(57.1)	1(33.3)	0(0.0)	
cyst	10(11.5)	0(0.0)	2(8.0)	6(12.8)	0(0.0)	2(66.7)	0(0.0)	
ductal dilation	4(4.6)	0(0.0)	1(4.0)	3(6.4)	0(0.0)	0(0.0)	0(0.0)	
calcification	3(3.5)	0(0.0)	0(0.0)	0(0.0)	2(28.6)	0(0.0)	1(50.1)	
architextural D	2(2.3)	0(0.0)	0(0.0)	1(2.1)	0(0.0)	0(0.0)	I(50.1)	
	87(100.0)	3(100.0)	25(100.0)	47(100)	7(100.0)	3(100.0)	2(100.0)	
architectural distortion =Architextural distortion								

Using the BIRADS classification of breast lesion, 55(63.2%) were BIRADS 1 (normal/negative), 21(24.1%) were BIRADS 2 (benign), 6(6.9%) were BIRADS 3(probably benign), 3(3.4%) were BIRADS 4 (suspicious) and 2(2.3%) were BIRADS 5 (malignant.) Figure 1.

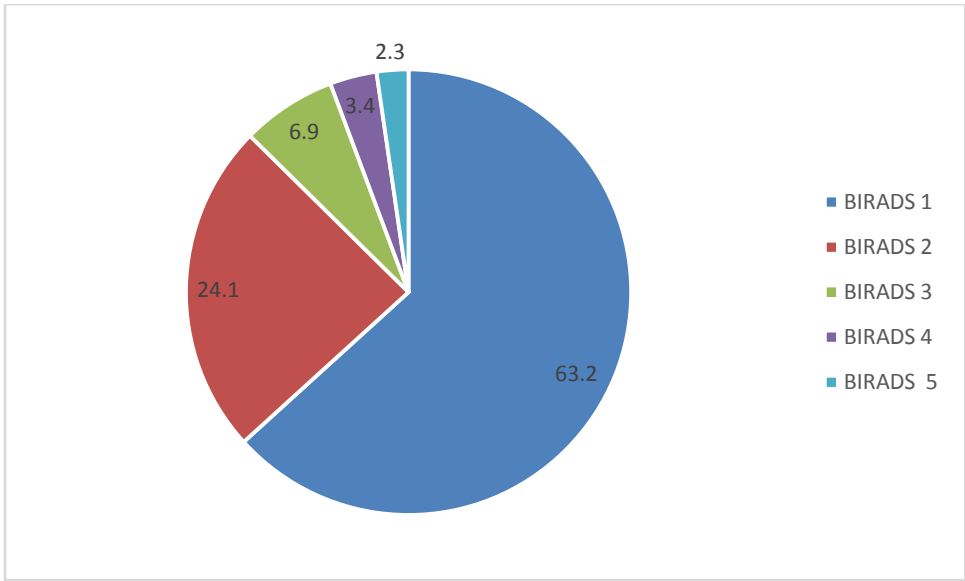


Figure 1: BIRADS classification of ultrasound findings among women with breast pain

UNDER PEER REVIEW

There was positive correlation between abnormal ultrasound findings with type of pain ( $P=0.08$ ), location of pain ( $P=0.63$ ), contraception ( $P=0.39$ ), and family history of breast cancer ( $P=0.11$ ). However, this was not statistically significant. Table 5.

**Table 5**

**Correlation of abnormal ultrasound findings with type of pain, location of pain, contraceptive and family history of breast cancer**

variables	abnormal uss findings n=32				
	N(32)	%	Pearson	correlation(r)	P-value
<b>Type of pain</b>					
cyclical	10	31.3		0.52	0.08
acyclical	22	68.6			
<b>Parity</b>					
0	6	18.8			
1-4	14	43.8	0.18		0.17
>5	12	37.5			
<b>location of pain</b>					
diffuse	13	40.6	0.23		0.63
focal	19	53.4			
<b>contraception</b>					
Yes	12	37.5	0.39		0.39
No	21	65.6			
<b>Family history of breast cancer</b>					
Yes	7	21.8	0.11		0.11
No	25	78.1			

## Discussion

Majority of the patients who presented with breast pain in this study were in the age group 30-39 and 20-29 representing 54.0% and 28.7% respectively. It has been shown that breast pain is more common in premenopausal women suggesting a hormonal aetiology and is usually associated with menstrual cycle<sup>3</sup>. Premenstrual water retention in the breasts has also been proposed as a cause of mastalgia, however Preece et al, in their study found no correlation between total body water and breast pain in 39 women with breast pain and 17 control subjects.<sup>11</sup> The predominance of premenopausal women in this study presenting with breast pain may suggest its hormonal aetiology.

Studies have shown that in majority of women with breast pain presenting for breast scan especially without a palpable mass, no abnormalities were seen<sup>3,9,7</sup>. Our study is in agreement with this as 63.2% of patient in this study had normal breast scan. Breast pain itself may not be specific for a particular breast disease, however varying breast pathologies have been detected by breast imaging for pain which may warrant surgical treatment. This study was predominantly on women who presented with breast pain alone and sonographic abnormalities detected on ultrasound included: mass 13 (14.9%), cystic 10 (11.4%), ductal dilation 4(4.6%), calcification 3 (3.4%), architectural distortion 2(2.3%). Zeena et al<sup>9</sup> in their study among women with breast pains, breast mass was seen in 13% of patients on ultrasound, in a study by Akreyi et al<sup>12</sup> 32.8% was breast mass and 34% was breast mass in a study by Al-Sarairah et al<sup>13</sup>. The varying prevalence of breast mass among women with breast pain may be due to the type of patients recruited for the study. Zeena et al<sup>9</sup> Akreyi et al<sup>13</sup> and Al-Sarairah et al<sup>14</sup> also recruited patients with palpable mass while patients with palpable mass was excluded in this study thereby resulting in low prevalence of breast mass in this study. Majority of breast mass in this study had benign features and as such were categorise as BIRADS 2. In young women of reproductive age breast masses are usually benign however few do have breast cancer<sup>3,10,14</sup>. Breast cyst and fibroadenoma were common abnormal ultrasound findings noted in a study by Nasreen et al<sup>3</sup> which is similar to the findings obtained in this study

Most studies also showed that cyst was another common benign lesion on breast scan of women with breast pain<sup>3,9</sup>. The cyst may vary in size from small to very large. Larger cysts are common cause of local tenderness which has been well documented<sup>15</sup> and sometimes may be relieve by cyst puncture and aspiration. However, in a non-palpable cyst of few millimetres in size, it will be difficult to associated breast pain to the cyst as many of these cysts may undergo spontaneous regression<sup>16</sup>. The cyst found in this study was of varying sizes with benign features and none underwent cyst puncture and aspiration.

The prevalence of 0-3.2% for breast cancer has been reported among women presenting with breast pain. In this study 2(2.3%) of women with breast pain had cancer which was categorised as BIRADS 5. This was histologically proven to be invasive carcinoma. These two women had no family history of breast cancer. This study also conforms to low prevalence of breast cancer among women with breast pain. Other studies have also collaborated low incidence of breast cancer among women with breast pain<sup>3,7</sup>. In a study by Tumyan et al, higher prevalence of breast cancer 4.6% was detected among patient with focal breast pain without a palpable mass using combination of mammography and ultrasound<sup>17</sup>. The lower prevalence in this study however may likely be due to the use of only ultrasound in evaluation of breast pain.

Despite the low prevalence of malignancy in patient with breast pain, breast imaging in women with breast pain may go a long way in reassuring the patients and allay any fear of cancer as no abnormalities are frequently detected. Main reason for imaging patients with breast pain is reassurance as most may not seek further medical help after reassuring them that their pain is not due to cancer<sup>1,6,7</sup>. However breast abnormalities with benign features are generally common although most may not necessarily have any clinical consequences, detection of these abnormalities may warrant necessary follow ups and intervention especially if pain is severe enough to interfere with one's daily activities.

Ultrasound is a valuable imaging in evaluating breast pain because it is readily available and accessible and does not use ionizing radiation. It is an important imaging modality for evaluating breast pain not associated with palpable mass. However, when use in combination with other imaging modalities like mammography the detection rate of cancer may be high especially in postmenopausal women<sup>1</sup>.

## **Conclusion**

Ultrasound is an indispensable tool in evaluating breast pain because it is readily available, accessible, user friendly, real time and inexpensive when compare to other imaging modalities like mammographic especially in a poor resource country. Ultrasound is most likely the first line imaging modality in evaluating breast pain among young women. Combination of mammography and ultrasound should be used in older women greater than 40 years.

## **Consent**

As per international standard or university standard, Participants' written consent has been collected and preserved by the author(s).

## REFERENCES

1. Breast Pain: Expert Panel on Breast Imaging: Peter M. Jokich, Lisa Bailey, Carl D'Orsi, Edward D. Green, Anna I. Holbrook, Su-Ju Lee et al *Journal of the American College of Radiology* 2017;14:525-53
2. Marrow M. The evaluation of common breast problems. *Am Fam Physician* 2000;61:2371–2378.
3. Nasreen Naz, Saba Sohail, Mukhtiar Ahmed Memon. Utility of Breast Imaging in Mastalgia. *JLUMHS* 2010; 09: 12-16
4. Smith RL, Pruthi S, Fitzpatrick LA. Evaluation and management of breast pain. *Mayo Clin Proc.*2004;79:353–72.
5. Plu-Bureau G, Le MG, Sitruk-Ware R, Thalabard JC. Cyclical mastalgia and breast cancer risk: results of a French cohort study. *Cancer Epidemiol Biomarkers Prev* 2006;15:1229-31.
6. Smallwood JA, Kye DA, Taylor I. Mastalgia; is this commonly associated with operable breast cancer? *Ann R Coll Surg Engl* 1986;68:262-3. Duijm LE, Guit GL, Hendriks JH, Zaat JO, Mali
7. Lucien E M Duijm, Gerard L Guit, Jan H C L Hendriks, Joost O M Zaat, Willem P T M Mali, Value of breast imaging in women with painful breasts: observational follow up study. *BMJ*. 1998; 317: 1492–1495.
8. Leung JW, Kornguth PJ, Gotway MB. Utility of targeted sonography in evaluation of focal breast pain. *J Ultrasound Med* 2002;21:521-6.
9. Zena. M. Al hindawi, Hussain. J. Alsalami , Alaa. S. Alattabi. Role of breast ultrasound in assessment of women with breast pain. *Iraq Med J* |2018; 2: 83–85.
10. H Hasni,, F A Meah,, A Norlia, , N A Sharifah, , A Zulfiqar,. Ultrasound in the Assessment of the Palpable Breast Mass. *Med J Malaysia* 2004; 59:486-494.
11. Preece PE, Richards AR, Owen GM, Hughes LE. Mastalgia and total body water. *Br Med J*. 1975;4:498–500
12. Akreyi HA. The role of breast ultrasound in assessing patients with mastalgia in Erbil, Iraq. *Zanco J Med Sci*. 2013;17:331-335.

13. Al-Sarairah JS, Al-Hiari RN. Breast pain assessment using breast ultrasound at King Hussein Medical Center in Jordan Indian J Med Res Pharmaceut sci. 2016:31-5.
14. Malik G, Waqar F, Buledi GQ. Sonomammography for evaluation of solid breast masses in young Patients: J Ayub Med Coll Abbottabad 2006;18 (2):34-7
15. Tabar I, Pentek Z, Dean PB. The diagnostic and therapeutic value of breast cyst puncture and pneumocystography. Radiology. 1981;141:659–663.
16. Brenner RJ, Bein ME, Sarti DA, Vinstein AL. Spontaneous regression of interval benign cysts of the breast. Radiology. 1994;193:365–368.
17. Tumyan L, Hoyt AC, Bassett LW. Negative predictive value of sonography and mammography in patients with focal breast pain. Breast J 2005;11:333-7.

UNDER PEER REVIEW