

## **Toxicity Evaluation of dual fungicide SAAF (Carbendazim 12% and Mancozeb 63%) through physiological markers in *Oreochromismossambicus***

### **Abstract**

The study was designed to evaluate the acute toxicity induced by SAAF in freshwater fish, *Oreochromismossambicus*. Fungicides are widely used for pest management and increase crop output. When used in excessive doses, they are also exceedingly dangerous to non-target organisms. The present investigation is about changes in biochemical parameters in *Oreochromismossambicus* due to toxicity induced by the application of fungicides in paddy-cum-fish ecosystem in India. The SAAF fungicide, a mixture of carbendazim (12%) and mancozeb (63%) is used to combat fungal diseases such as sheath blight, sheath rot, blast, and leaf spot diseases of rice plants. The present research aimed to determine the toxicity and evaluate the effect of sublethal concentrations of SAAF on some biochemical, haematological, and histological parameters of *Oreochromismossambicus* after 10, 20 and 30 days. *Oreochromismossambicus* were exposed to different concentrations of SAAF (10.5 mg/lit, 11.5mg/lit and 12.5 mg/lit) respectively and LC50 was determined. LC50 for SAAF was detected to be 13.5mg/lit using SPSS Vs.21. After 30 days of exposure, the individuals exposed to toxicity were sacrificed and the parameters were checked in the treated fish. Among biochemical parameters, total glucose, cholesterol, stress-related enzymes AST and ALT showed a significant increase while total protein showed a substantial decrease, whereas among haematological parameters, Haemoglobin, RBC, and PCV had risen and WBC and MCV showed a marked decrease. The tissue necrosis was quite prominent in the gill, heart, liver, kidney, and muscle after 30 days of exposure to the fungicide.

**Keywords:** *Oreochromismossambicus*; SAAF, Biochemical parameters, Haematological parameters, Histological parameters

### **INTRODUCTION**

In India, more than 50% of the population depends on agriculture and related industries for their livelihood. However, the potential for horizontal development in agriculture is severely constrained by the rapid urbanization and industrialization of the world. Moreover, the extensive use of chemical fertilizers and pesticides to increase productivity has had a negative impact on the environment in a number of ways, including soil and water pollution,

a decline in soil fertility, and a decline in the population of beneficial insects (Swaminathan, 2006; Jewitt and Baker, 2007; Liu *et al.*, 2015).

Similar to this, aquaculture in India faces some serious challenges. Intensive aquaculture has had a detrimental and long-lasting influence on ecology, causing changes to the local biodiversity and environment (Yuan *et al.*, 2019) and changes to the local biodiversity and ecosystem brought about by the introduction of foreign species (De Silva *et al.*, 2009). Additionally, extensive aquaculture is prone to disease outbreaks and parasite transmission (Blaylock and Bullard, 2014).

Consequently, one of the most practical methods for producing food sustainably is to grow paddy and fish on the same plot of land at the same time while utilizing water resources (Ahmed and Turchini, 2021). In farming systems that rely primarily on rice, rice-fish culture is a small-scale aquaculture. Numerous South and Southeast Asian nations have practiced rice-fish culture for thousands of years (Ghosh *et al.*, 1985). In India, raising fish alongside paddy is a long-standing custom (Alikunhi 1955). It has primarily been practiced in Kerala and West Bengal, two coastal states in India, in a traditional manner. A wide variety of fish species have been cultured in rice-cum-fish ecosystem including common carp (*Cyprinus carpio*), Indian Major Carp- rohu (*Labeo rohita*), mrigal (*Cirrhinus mrigala*) and catla (*Catla catla*), Chinese carp - silver carp (*Hypophthalmichthys molitrix*) and occasionally grass carp (*Ctenopharyngodon idella*), tilapia (*Oreochromis mossambicus*) and silver barb (*Puntius javanicus*) (Gupta *et al.*, 1998).

According to Vromant and Chau (2001), rice-fish culture is a type of concurrent culture, or agricultural cropping system that incorporates fish culture alongside rice culture. The main goal of applying pesticides as one of the management tactics in a rice field is to protect the crop from pests, such as insects, rodents, fungi, and undesired plants (weeds), as well as to encourage rice development. Indiscriminate pesticide use, however, could have a severe impact on the ecosystem's health and harm any naturally occurring or intentionally introduced aquatic life, including fish. A healthy ecosystem's delicate species balance is destroyed by pesticides and other substances related to them (Khan and Francis, 2005). Pesticides applied to agricultural fields for pest control programs appear to cause a variety of physiological and biochemical alterations in freshwater organisms by affecting the actions of various enzymes. Fish in particular often experience behavioral and physiological changes

as a result of changes in the chemical composition of the natural aquatic environment (O'Brien 1967).

Since tilapia (*Oreochromis spp.*), a teleost fish, is found all over the world, it is a useful model for studies on toxicology and the evaluation of aquatic ecosystems. Yet, the presence of pesticides in heavily populated areas where irrigation and rains flush these chemicals into rivers and streams and contaminate aquatic life may have a considerable impact on this fish's immune system. The present investigation is about change in biochemical, histological and haematological parameters in *Oreochromismossambicus* due to toxicity induced by application of fungicides in paddy-cum-fish ecosystem in India.

## **MATERIALS AND METHODS**

### **Fish Species: *Oreochromismossambicus***

A number of healthy and equal size ( $5.2 \pm 2$  cm) and weight ( $4.5 \pm 3$ g) of *Oreochromismossambicus* were collected from CIFA (Central Institute of Freshwater Aquaculture), Bhubaneswar, Odisha, in the month of March prior to the experimentation. Healthy fishes were selected for the experiment with no fungal or algal infection. The samples were acclimatized for 15 days to laboratory conditions and kept in aquariums containing 35 litre of water and were regularly fed. They were kept in a glass aquarium with continuously flowing dechlorinated water that had a pH of 6.4 and a temperature between 25-27°C to help them adjust to the lab setting. Feeding was stopped 24 hours before the experiment began to prevent the tank from being overrun with organic debris.

### **Fungicide**

The substance utilized in this experiment is a SAAF-branded fungicide. This fungicide contains mancozeb (63%) and carbendazim (12%) in combination. In the rice plant, SAAF is used to combat fungal diseases such as sheath blight, sheath rot, blast, leaf spot, and others. The UPL firm supplied this fungicide.

Chemical composition: Carbendazim technical (98% pure): 12.25% w/w, Mancozeb technical (85% pure)

### **Experimental Design**

- 10 samples of *Oreochromismossambicus* were randomly selected from the stock and were exposed to ten different concentrations of SAAF (Carbendazim & mancozeb) for 96 hr to determine the mean lethal concentration (LC50).

- SAAF application was restricted to 3 doses. LC50 was found 13.5mg/lit using SPSS Vs. 21.
- In the case of *Oreochromismossambicus*, Dose 1: 10.5mg/lit, Dose 2: 11.5 mg/lit, and Dose 3: 12.5mg/lit were selected for the chronic sub-lethal study.
- A control group was maintained side by side.

### **Biochemical Parameters**

The toxicated fish samples were sacrificed after the end of each 10, 20 and 30 days and processed. First, blood was drawn from the caudal vein of a toxicated fish without the use of an anticoagulant, and the blood was spun at 2000 rpm for 5 minutes at 4°C. Supernatant (serum) was collected after centrifugation and kept at -20°C until analysis and biochemical parameters are analyzed.

The biochemical parameters included for investigation were glucose, cholesterol, total protein, AST, ALT. Serum glucose and cholesterol concentration was estimated spectrophotometric method according to procedure described by Mendel *et al.*, (1954) and Tietz (1986) respectively. Total protein concentration in serum was analyzed by Biuret method according to Dumas (1975). The concentration of Aspartate aminotransferase (AST) and alanine aminotransferase (ALT) in serum were measures through a spectrophotometer (Elico company, Model No.- SL342) by 2,4 dinitrophenylhydrazine (2,4-DNHP) method (Reitman and Frankel, 1957).

### **Haematological Assessment**

Blood was collected by severing the caudal vein by using a sterile plastic syringe (2.5 ml) and immediately transferred into assay tubes, containing EDTA (5mg/ml) followed by the study of Haematological parameters.

Blood parameters like Haemoglobin concentration (Hb), RBC (Red blood cells), WBC (white blood cells), PCV (Packed Cell Volume), MCV (Mean corpuscular volume) were estimated. The haemoglobin content in erythrocyte was determined by using Sahil'shemocytometer. The blood samples were diluted with appropriate diluting fluids for RBC and WBC count and were determined using improved Neubauer haemocytometer and calculated (Hesser 1960; Blaxhall and Daisley, 1973). Packed Cell volume (PCV) was determined by using microhematocrit capillary tube (Wintrobe, 1967). Absolute values like MCV was calculated using standard formula (Dacie and Lewis 1975).

### **Data Analysis**

Student's t-test was performed between control and exposed values. The mean values were found to be significantly different at a 5% level of significance.

### **Histological parameters**

Different vital organs (gill, liver, kidney) were carefully removed at chronic toxication (after 30 days) and fixed in 10% formalin solution followed by dehydration in ascending grades of alcohol and washed in xylene. The fixed tissues were embedded in paraffin wax followed by thin sectioning (5  $\mu$ m) with the help of a microtome (Euromex Holland microtome, Arnhem, The Netherlands). Staining was done according to the Harris hematoxylin and eosin (H&E) method and photographed using a microscope camera (Bernet *et al.*, 1999).

## **RESULT**

### **Biochemical parameters**

The biochemical components of tilapia fish (*Oreochromis mossambicus*) subjected to sub-lethal doses of SAAF (carbendazim and mancozeb) fungicide at various exposure times (10, 20, and 30 days), were investigated in the current study. In accordance with the sub-lethal dose (10.5 mg/L, 11.5 mg/L, and 12.5 mg/L), variations in biochemical markers including glucose, cholesterol, total protein, AST, and ALT were shown in Tables 1, 2, and 3.

Fish used in the investigation had considerably higher glucose levels than the control group ( $p < 0.05$ ). Cholesterol is an essential component of a healthy organism, required to build cell membranes, produce bile acid, and create steroid hormones. The information shown in (Tables 1, 2, and 3) reveals a substantial rise in cholesterol levels in the studied tissues from the fish Tilapia. Generally, the increase in cholesterol contents in all tissues was found to be increased with the hours of exposure. Proteins are essential organic compounds needed by living things for the synthesis of new tissue as well as for the efficient use of energy. The findings of this investigation demonstrated a considerable reduction in the protein content of the experimental fish. Tables 1, 2, and 3 show changes in plasma enzyme activity such as AST and ALT. When compared to the control group, AST activity in fish exposed to all three 10.5, 11.5 and 12.5 mg/L SAAF concentrations was considerably higher ( $p < 0.05$ ) and with the hours of exposure, ALT activity greatly increased.

### **Haematological parameters**

The haematological parameters of tilapia fish (*Oreochromis mossambicus*) subjected to sub-lethal doses of mancozeb and carbendazim at various exposure times were investigated in the current study. In accordance with the sublethal dose (10.5 mg/L, 11.5 mg/L, 12.5 mg/L)

and exposure time (10, 20, and 30 days), variations in RBC, WBC, PCV, MCV were shown in Tables 4, 5, and 6. Fish used in the investigation had considerably higher RBC levels than the control group ( $p < 0.05$ ). The information shown in (Tables 4, 5, and 6) reveals a substantial decrease in Haemoglobin, RBC, and PCV & substantial rise in WBC and MCV. In case of percentage change over control, in tables 4, 5, and 6, the values of Haemoglobin, RBC, and PCV are positive. It indicates a gradual decrease in the amount of Hb, RBC, and PCV. However, the value of WBC and MCV comes in negative, it defines the gradual increase in WBC and MCV due to stress.

### **Histological parameters**

After exposure to sub-lethal doses, (10.5 mg/L, 11.5 mg/L, 12.5 mg/L) of dual fungicide SAAF (mancozeb 63% and carbendazim 12%) the fish *Oreochromis mossambicus* were sacrificed after 10 days, 20 days, 30 days. The organs studied for toxication induced by the fungicide were gill, liver and kidney. The slides for the concerned organs were compared for the intoxicated fish and the control fish. Figures 4 A, 4B, 5A, 5B, 6A, 6B represents the Gill, Liver, and Kidney of Control and Intoxicated fish respectively.

#### **Gill**

The changes including due to toxicity were: Epithelial hyperplasia with lamellar fusion, epithelial hypertrophy, edema, general necrosis, telangiectasia, increased mucous production, and degeneration of primary and secondary gill lamellae. Damages at lethal dose were much more extensive with severely degenerated primary and secondary gill lamellae, lamellar fusion, and lamellar disorganization compared to sub-lethal concentration in both fish species.

#### **Liver**

The histological changes observed in the liver were the formation of a large number of vacuoles, enlargement of nuclei of some cells, nuclear hypertrophy, enlarged sinusoids, and atrophic areas as compared to control cells of the liver. The damage to liver cells at sub-lethal concentration was highly intense. The changes observed were liver obscured, vacuolated, and atrophied. Nuclear and cytoplasmic degeneration and melanomacrophages were also found.

#### **Kidney**

Under sub-lethal exposure, the proximal convoluted tubule and secondary convoluted tubules were degenerated to some extent and cellular contours were not prominent, renal corpuscle with glomerular expansion and absence of Bowman's space, nuclear hypertrophy and

d formations of vacuoles were observed as compared to control group.

## DISCUSSION

Numerous studies have revealed that high pesticide concentrations in various forms of wastewater are hazardous to aquatic life, particularly fish species (Min & Kang 2008; Sturve *et al.*, 2008; Üner *et al.*, 2006). Fish are especially sensitive to water contamination from the environment. Therefore, pollutants like pesticides may seriously harm some physiological and biochemical processes when they get into the fishes' organs (John 2007; Monteiro *et al.*, 2006; Velisek *et al.*, 2006). Similar to other pesticides, SAAF can seriously affect physiology and health. In this regard, alterations in biochemical parameters can serve as an effective diagnostic tool to identify harmful effects in target organs and to assess the physiological status of fish exposed to SAAF. According to the results of the current study, SAAF is extremely harmful to tilapia (*Oreochromis mossambicus*). With increasing concentration and exposure time, SAAF became more harmful to *Oreochromis mossambicus*.

According to reports, fish typically exhibit elevated blood glucose levels when unfavourable conditions prevail. This condition benefits the fish by giving its essential organs the energy substrates they need to meet the higher energy requirement (Banee *et al.*, 2008; Saha & Kaviraj, 2009; Velisek *et al.*, 2006). Blood glucose elevation was frequently employed as a supplementary indicator of a stress reaction. On the basis of our results it is clear that SAAF acts as a stressor in fish. According to Raja *et al.* (1992), the rise in blood sugar caused by pesticide exposure may signify a disruption in the metabolism of carbohydrates because of an increased breakdown of liver glycogen, which may be mediated by an increase in the hormones adrenocorticotrophic and glucagon and/or decreased insulin action. Both *L. rohita* (Das and Mukherjee, 2000) and *S. schlegeli* (Jee *et al.*, 2005) have been linked to cypermethrin-induced hyperglycemia.

In contrast to the fish exposed to SAAF, where a rise in cholesterol was seen after 10 days, the fish exposed to pesticides showed an elevation at every exposure times (Table 1, 2 & 3). The current findings are consistent with those of Üner *et al.*, (2008) who discovered that cholesterol concentrations in the serum of *O. niloticus* exposed to pesticides generally rose when compared to the control value. They came to the conclusion that liver and kidney failure, which results in the release of cholesterol into the blood, may be to blame for the rise in cholesterol concentrations. Cholesterol is a precursor to all steroid hormones and is a necessary structural component of membranes. In the current study, fish exposed to pesticides show an increase in

blood cholesterol levels, which indicated hypercholesteremia. This increase in serum cholesterol levels may have been caused by stress brought on by toxicants.

According to Yeragiet *et al.*, (2003), Remia *et al.*, (2008), and Pang-Hung *et al.*, (2008), proteins are essential organic compounds needed by organisms for tissue development and play a crucial role in energy metabolism. According to the findings of this study, the protein content of the tissues under investigation significantly decreased. Proteolysis and enhanced metabolism during toxicant stress may be the cause of the protein decrease (Remia *et al.*, 2008).

Several blood serum soluble enzymes have been proposed as useful stress indicators. Therefore, serum AST and ALT activities have been widely used in the diagnosis of fish diseases as well as in the detection of tissue damage brought on by environmental contamination. According to Palaniveluet *et al.*, (2005), an increase in these enzyme activities in the serum or extracellular fluid is a sensitive sign of even mild cellular damage and denotes stress-related tissue deterioration. In general, the results of AST and ALT may indicate liver degenerative alterations and hypofunction because toxicants' effects on hepatocytes typically take the form of tissue damage, which results in the release of cellular enzymes into the blood serum. Thus, increases in these enzyme activities in *Oreochromismossambicus* serum are mostly caused by the enzymes leaking from the liver cytosol into the blood stream as a result of liver damage from pesticides, providing evidence of the hepatotoxic action of toxicants.

Blood serves as a marker for pathological alterations brought on by pollution. Fish blood exhibits striking alterations prior to the commencement of any environmental toxicity in the nearby water. For toxicological studies, haematological factors are crucial. Indicators of environmental stress are also applied to them. According to haematological research, fish physiological activity is changed by acute fungicide exposure. In programmes for environmental biomonitoring, they are therefore often utilised. Due to this, the impact of SAAF on the freshwater fish *Oreochromismossambicus* haematological parameters were reviewed in light of previous research on other fish species. The current investigation showed that exposure to various sub-lethal dosages of the fungicide SAAF resulted in substantial alterations in the fish's haematological parameters.

Erythrocytes are important and trustworthy markers of a variety of stressors (RainzaPaiva *et al.*, 2000). Erythrocytes serve as a long-term indicator of an organism's health (Haley and Weister, 1985). The amount of RBC count often falls in response to high pesticide concentrations or prolonged exposure of fish to their sub-lethal concentration. This results from a slower or

slower rate of RBC synthesis. When exposed to various sub-lethal quantities of the drug SAAF, the experiment conducted for the current study revealed a substantial change showing a decrease in the quantity of RBC. *Oncorhynchus mykiss* subjected to cypermethrin showed a similar state (Muhammed Atamanalp and Telat Yanik, 2002).

*Oreochromis mossambicus* when exposed to sumithion and sevin (Koundinya *et al.*, 1980), *Ctenopharyngodon idella* exposed to fenvalerate (Shakoori *et al.*, 1996), and *Heteropneustes fossilis* exposed to deltamethrin (Kumar *et al.*, 1998) are some other species that have been exposed.

Our result is in accordance with some previous workers. Gill histological damage was also reported due to exposure of different pesticides like, mosquito fish (*G. affinis*) to deltamethrin (Cengiz and Unlu, 2006), and maneb and carbaryl application to rainbow trout (*O. mykiss*) (Boran *et al.*, 2010). Das and Mukherjee (2000) studied the toxic effect of sub-lethal doses of hexachlorocyclohexane (HCH) during 45 days in organs like liver, kidney, gill, skin, muscle, heart and brain of *Labeo rohita*. Our result agrees with the typical macroscopic changes associated with diazinon toxicity as reported (Boran *et al.*, 2012). The liver plays an important role in metabolic processes and detoxification of many xenobiotics, acute exposures of any toxic component may lead to accumulation in the liver, causing pathological alterations (Dar *et al.*, 2022a; Dar *et al.*, 2022b; Saha *et al.*, 2021; Sharma *et al.*, 2021). Other researchers observed similar results by like blood congestion, hyperplasia, curling of secondary lamellae; hemorrhage, epithelial hyperplasia, clubbing, and necrosis were found in the gill (Akter *et al.*, 2020).

Certain other studies also support the toxic effects of pesticides in various tissues and organs of different fish, such as atrazine to *Labeo rohita* (Jayachandran and Pugazhendy, 2009), Cypermethrin to *Torputitora* (Ullah *et al.*, 2014), *Corydoras melanistius* (Santos *et al.*, 2012).

## CONCLUSION

Although a toxicant first exerts its effects at the cellular or even molecular level, it ultimately leads to changes in physiological and biochemical processes. Given that the blood is the first organ to be affected by unfavourable changes in the ambient environment, blood biochemical profiles can reveal vital information about the internal environment of an organism. The findings of the current study unequivocally demonstrate the detrimental effects of the fungicide SAAF on the biochemical, haematological and histological components of the tilapia fish

(*Oreochromis mossambicus*). All the metabolites studied are found to be sensitive changes in the normal indicators, which reflect changes in the normal activities of various functional systems. The changes in biochemical parameters like proteins, glucose, cholesterol, AST, ALT, and haematological parameters like hemoglobin, RBC, WBC, PCV and MCV in the fungicide SAAF treated fishes will naturally affect these animals' nutritional value. Damages of histological

parameters at lethal dose was much more extensive with severe degenerated primary and secondary gill lamellae, lamellar fusion and lamellar disorganization compared to sublethal concentration in both fish species. The damage to liver cells at sublethal concentration was highly intense. Nuclear and cytoplasmic degeneration and melanomacrophages were also found. The proximal convoluted tubule and secondary convoluted tubules were degenerated to some extent and cellular contours were not prominent. Therefore, it is important to pay attention to changes in the biochemical and physiological makeup of aquatic creatures, which are at risk from the use of pesticides.

## REFERENCES

- Ahmed, N. Turchini, G.M. (2021). The evolution of the blue-green revolution of rice-fish cultivation for sustainable food production. *Sus Sci* 16: 1375–1390.
- Akter, R., Pervin, M.A., Jahan, H. (2020). Toxic effects of an organophosphate pesticide, envoy 50 SC on the histopathological, hematological, and brain acetylcholinesterase activities in stinging catfish (*Heteropneustes fossilis*). *JoBAZ* 81, 47.
- Alikunhi, K.H. (1955). Rice Field Fish Culture Outside Indonesia. International Inland Fisheries Training Centre, Bongor, Indonesia (mimeo).
- Atamanalp, M., Yanik, T. (2002). Alteration in haematological parameters of rainbow trout *Oncorhynchus mykiss* exposed to mancozeb, *Turk. J. Vet. Anim. Sci.* 27: 1213- 1217.
- Banaee, M., Mirvagefi, A.R., Rafei, G.R., Majazi Amiri, B. (2008). Effect of sub-lethal diazinon concentrations on blood plasma biochemistry, *Int J Environ Res* 2: 189–198.

Blaxhall, P.C., Daisley, K.W. (1973). Routine hematological methods for use with fish blood. *J Fish Biol* 5: 771-781.

Blaylock, R.B., Bullard, S.A. (2014). Counter-insurgents of the blue revolution? Parasites and diseases affecting aquaculture and science. *J Parasitol* 100, 743–755.

Boran H.

(2012). Assessment of acute toxicity and histopathology of the fungicide captan in rainbow trout. *Exp Toxicol Pathol* 64(3):175-179.

Boran, H., Altinok, I., Capkin, E. (2010). Histopathological changes induced by maneb and carbaryl on some tissues of rainbow trout, *Oncorhynchus mykiss*. *Tissue Cell*, 42(3):158-64

Cengiz, E.I., Unlu, E. (2006). Sub-lethal effects of commercial deltamethrin on the structure of the gill, liver and gut tissues of mosquitofish, *Gambusia affinis*: A microscopic study. *Environ. Toxicol. Pharmacol*, 21:246-253

Dacie, J.V., Lewis, S.M. (1975). *Practical Haematology* 5<sup>th</sup>.ed. Churchill.

Dar, O.I., Aslam, R., Pan, D., Sharma, S., Andotra, M., Kaur, A., Jia, A, Faggio, C., 2022b. Source, bioaccumulation, degradability and toxicity of triclosan in aquatic environments: a review. *Environ. Technol. Innov.* 25, 102122.

Dar, O.I., Aslam, R., Sharma, S., Kaura, A., Jia, A, Faggio, C., 2022a. Biomolecular alterations in the early life stages of four food fishes following acute exposure of Triclosan. *Environ. Toxicol. Pharmacol.* 91, 103820.

Das, B.K., Mukherjee, S.C. (2000). A histopathological study of carp *Labeo rohita* exposed to Hexachlorocyclohexane. *Veterinarski Archiv* 70(4):169-180.

De, Silva, S.S., Nguyen, T.T.T., Turchini, G.M., Amarasinghe, U.S., Abery, N.W. (2009). Alien species in aquaculture and biodiversity: a paradox in food production. *Ambio* 38: 24–28.

Dumas, B.T. (1975). Determination of total protein in serum. *Clin Chem* 21: 1159-1166.

Ghosh, A., Saha, S.K., Banerjee, R.K., Mukherjee, A.B. & Naskar, K.R. Package of practices for increased production in rice-cum-fish farming system. *Aquaculture Extension Manual* 4, Central Inland Fisheries Research Institute, (1985), 1-14.

- Gupta, M.V., Sollows, J.D., Mazid, M.A., Rahman, A., Hussain, G. & Dey, M.M. Integrating aquaculture with rice farming in Bangladesh: feasibility and economic viability, its adoption and impact. ICLARM Newsletter, (1998), 1-3.
- Haley, P.J., Weister, M.G. (1985). Erythrocyte volume distribution in rainbow trout. *Ame J Vet Res* 46(10): 2210-2212.
- Hesser, E.F. Methods for routine on fish haematology. *The prog. Fish Cult*, (1960). 22: 164-171.
- Jayachandran, K., Pugazhendy, K. (2009). Histopathological Changes in the Gill of *Labeorohita*(Hamilton) Fingerlings Exposed to Atrazine. *J Sci Res*4(3):219-221.
- Jee, J-H, Masroor, F., Kang, J.C. (2005). Responses of cypermethrin-induced stress in haematological parameters of Korean rockfish, *Sebastes schlegeli* (Hilgendorf). *Aqua Res* 36:898–905. doi:10.1111/j.1365-2109.2005.01299.x
- Jewitt, S., Baker, K. (2005). The green revolution re-assessed: insider perspectives on agrarian change in Bulandshahr District, Western Uttar Pradesh, India. *Geoforum; J Physic Human RegGeosci* 38: 73–89.
- John, P.J. (2007). Alteration of certain blood parameters of freshwater teleost *Mystus vittatus* after chronic exposure to metasystox and sevin, *Fish PhysiolBiochem* 33, 15–20.
- Khan, M.Z. and C.P.L. Francis (2005). Adverse effects of pesticides and related chemicals on enzyme and hormone systems of fish, amphibians and reptiles. *Proc. Pakistan AcMad. Z Sahceie* 42: 15-323.
- Kumar, S., Lata, S., Gopal, K. (1998). Deltamethrin induced physiological changes in freshwater catfish *Heteropneustes fossilis*, *Bull. Environ. Contam. Toxicol.* 62(3):254-258.
- Liu, Y., Pan, X., Li, J. A. (2015). 1961–2010 record of fertilizer use, pesticide application and cereal yields: a review. *Agro Sus Dev* 35, 83–93.
- Mendel, B., Kemp, A., Myers, D.K. (1954). A colorimetric micro-method for the determination of glucose. *Biochem*56: 639–646.
- Min, E.U., Kang, J.C. (2008). Effect of waterborne benomyl on the hematological and antioxidant parameters of the Nile tilapia, *Oreochromis niloticus*, *Pest BiochemPhysiol* 92: 138–143.

Monteiro, M., Quintaneiro, C., Pastorinho, M., Pereira, M. L., Morgado, F., Guilhermino, L., Soares, A.M.V.M. (2006). Acute effects of 3, 4-dichloroaniline on biomarkers and spleen histology of the common goby *Pomatoschistus microps*, *Chemosphere* 62: 1333–1339.

O'ner, M., Atli, G., Canli, M. (2008). Changes in serum biochemical parameters of freshwater fish *Oreochromis niloticus* following prolonged metal (Ag, Cd, Cr, Cu, Zn) exposures. *Environ Toxicol Chem* 27:360–366. doi:10.1897/07-281R.1

O'Brien, R.D. (1967). *Insecticides action and metabolism* Academic Press, London.

Palanivelu, V., Vijayavel, K., Ezhilarasibalasubramanian, S., Balasubramanian, M.P. (2005). Influence of insecticidal derivative (Cartap Hydrochloride) from the marine polychaete on certain enzyme systems of the freshwater fish *Oreochromis mossambicus*. *J Environ Biol* 26:191–196.

Pang-Hung, Y., S. Jian, R. Amartalingam and J.B. Choon-Fah (2008). Boric Acid Levels in Fresh Noodles and Fish Ball. *Ame J Agril Biol Sci* 3: 476-481.

Rainza -Paiva, M.J.T., Ishikawa, C.M., Das Eiras, A.A. and Felizardo, N.N. (2000). Hematological analysis of “Chara” *Pseudoplatystoma fasciatum* in the new millennium. Nice, France, European Aquaculture Soc. Special pub., 28:590

Raja M, Al-Fatah A, Ali M, Afzal M, Hassan RA, Menon M, Dhama MS. (1992). Modification of liver and serum enzymes by paraquat treatment in rabbits. *Drug Meta. Drug Inter*, 10:279–291.

Ranganatha Koundinya, P., Ramamurthi, R. (1980). Haematological studies in the *Sarotherodon mossambica* (peters) exposed to a lethal concentration of sumithion and seven, *Curr. Sci.* 49 (16):645-646

Reitman, S., Frankel, S. (1957). Glutamic – pyruvate transaminase assay by colorimetric method. *Ame J Clin Path* 28: 56.

Remia, K.M., Logaswamy, S., Logankumar, K., Rajmohan, D. (2008). Effect of an insecticides (Monocrotophos) on some biochemical constituents of the fish *Tilapia Mossambica*. *Poll. Res.*, 27: 523-526.

Saha, S., Chukwuka, A.V., Mukherjee, D., Patnaik, L., Nayak, S., Dhara, K., Saha, N.C., Faggio, C. (2021). Chronic effects of diazinon® exposures using integrated biomarker responses in freshwater walking catfish, *Clarias batrachus*. *Appl. Sci.* 11(22), 10902.

Saha, S., Kaviraj, A. (2009). Effects of cypermethrin on some biochemical parameters and its amelioration through dietary supplementation of ascorbic acid in freshwater catfish *Heteropneustes fossilis*, *Chemosphere*, 74, 1254–1259.

Santos, R.F.B., Dias, H.M., Fujimoto, R.Y. (2012). Acute toxicity and histopathology in ornamental fish amazon bluespotted corydora (*Corydoras melanistius*) exposed to formalin. *Ann. Brazil. Acad. Sci.*, 84(4):1001-1007.

Shakoori, A.R., Mughal, A.L. and Iqbal, M.J. (1996). Effect of sublethal doses of fenvalerate (a synthetic pyrethroid) administered continuously for four weeks on the blood, liver and muscles of fresh water fish, *Ctenopharyngodon idella*. *Bull Environ Contam Toxicol* 3(57):4 87-494.

Sharma, S., Dar, O.I., Andotra, M., Sharma, S., Kaur, A., Faggio, C., 2021a. Environmentally relevant concentrations of triclosan induce cyto-genotoxicity and biochemical alterations in the hatchlings of *Labeo rohita*. *Appl. Sci.* 11, 10478.

Sturve, J., Almroth, B.C., Förlin, L. (2008). Oxidative stress in rainbow trout (*Oncorhynchus mykiss*) exposed to sewage treatment plant effluent, *Ecotoxicol Environ Saf* 70: 446–452.

Swaminathan, M.S. (2006). An evergreen revolution. *Crop Science* 46: 2293–2303.

Tietz, N.W., Pruden, E.L., Siggard, A.O. (1986). *Textbook of clinical chemistry*. Saunders, Philadelphia.

Ullah R, Zuberi A, Tariq M, Ullah S. (2014). Acute Toxic Effects of Cypermethrin on Hematology and Morphology of Liver, Brain and Gills of Mahseer (*Tor putitora*). *Int. J Agri Biol*

Üner, N., Oruç, E.Ö., Sevgiler, Y., Sahin, N., Durmaz, H., Usta, D. (2006). Effects of diazinon on acetylcholinesterase activity and lipid peroxidation in the brain of *Oreochromis niloticus*, *Environ Toxicol Pharmacol* 21: 241–245.

Velisek, J., Dobsikova, R., Svobodova, Z., Modra, H., Luskova, V. (2006). Effect of deltamethrin on the biochemical profile of common carp (*Cyprinus carpio L.*), *Bull Environ Contam Toxicol* 76: 992–998.

Vromant, N., Chau, N. T. H., Ollevier, F. (2021). The effect of rice seeding rate and fish stocking on the floodwater ecology of the rice field in direct-seeded, concurrent rice-fish systems. *Hydrobiologia* 445: 151–164.

Wintrobe, W.M. A hematological odyssey. Johns Hopkins Med. (1967). 120:287s. 1926- 66.

Yeragi, S.G., Ranaand A.M., Koli. V.A. (2003). Effect of pesticide on protein metabolism of mudskipper, *Boleophthalmusdussumieri*, J Ecotoxicol Environ Monit 13: 211-214.

**Table 1: Effects of sub-lethal levels of SAAF (dose- 10.5 mg/L) on biochemical parameters were determined in *O. mossambicus* after 10, 20 and 30 days exposure.** Values expressed in Mean±S.D. of 10 replicates. Student's t-test was performed between control and exposed values. The mean values were found to be significantly different at 5% level of significance. Percentage increase or decrease over control were expressed within brackets.

Parameters	No. of Fish	Control	Toxicated		
			10 Days	20 Days	30 Days
Glucose	10	24.00±0.12	26.33±0.23 (-9.70%)	29.14±0.36 (-21.41%)	31.45±0.41 (-31.04%)
Cholesterol	10	42.36±1.61	46.10±1.42 (-8.82%)	50.23±1.02 (-18.57%)	52.46±1.21 (-23.84%)
Total Protein	10	3.46±0.47	3.18±0.96 (8.09%)	2.87±0.65 (17.05%)	2.79±0.95 (19.36%)
AST	10	57.86±1.11	59.43±1.02 (-2.71%)	61.21±1.32 (-5.78%)	61.98±1.31 (-7.12%)
ALT	10	23.29±1.51	24.16±1.24 (-3.73%)	29.41±1.56 (-26.27%)	30.12±1.44 (-29.32%)

**Table 2: Effects of sub-lethal levels of SAAF (dose- 11.5 mg/L) on biochemical parameters were determined in *O. mossambicus* after 10, 20 and 30 days exposure.**

Parameters	No. of Fish	Control	Toxicated		
			10 Days	20 Days	30 Days
Glucose	10	24.00±0.12	27.46±0.14 (-14.41%)	30.29±0.44 (-26.20%)	33.28±0.64 (-38.66%)
Cholesterol	10	42.36±1.61	48.62±1.16 (-14.77%)	52.20±1.34 (-23.22%)	54.64±1.26 (-28.98%)
Total	10	3.46±0.47	3.11±0.81	2.68±0.77	2.15±0.74

Protein			(10.11%)	(22.54%)	(37.86%)
AST	10	57.86±1.11	61.00±1.19 (-5.42%)	63.11±1.07 (-9.07%)	66.18±1.67 (-14.37%)
ALT	10	23.29±1.51	25.71±1.31 (-10.39%)	31.23±1.48 (-34.09%)	34.26±1.42 (-47.10%)

**Table 3: Effects of sub-lethal levels of SAAF (dose- 12.5 mg/L) on biochemical parameters were determined in *O. mossambicus* after 10, 20 and 30 days exposure.**

Parameters	No. of Fish	Control	Toxicated		
			10 Days	20 Days	30 Days
Glucose	10	24.00±0.12	30.19±1.21 (-25.79%)	36.21±1.28 (-50.87%)	39.48±1.41 (-64.5%)
Cholesterol	10	42.36±1.61	51.67±1.65 (-21.97%)	54.26±1.47 (-28.09%)	58.68±1.31 (-38.52%)
Total Protein	10	3.46±0.47	3.08±0.14 (10.98%)	2.38±1.06 (31.21%)	1.15±1.33 (66.76%)
AST	10	57.86±1.11	62.46±1.25 (-7.95%)	66.21±1.18 (-14.43%)	69.22±1.07 (-19.63%)
ALT	10	23.29±1.51	27.81±1.26 (-19.40%)	32.48±1.54 (-39.45%)	36.44±1.42 (-56.46%)

**Table 4: Effects of sub-lethal of SAAF (dose – 10.5 mg/L) on haematological parametrrs were determined in *O. mossambicus* after 10, 20 & 30 days exposure.**

Parameters	No. of fishes	Control	Toxicated		
			10 days	20 days	30 days
Haemoglobin	10	12.08±0.15	11.8±0.23 (2.31)	10.98 ± 0.36 (9.10)	10.12± 0.15 (16.22)
RBC	10	2.56± 1.61	2.36±1.42 (7.81)	2.17± 1.02 (7.81)	2.09 ± 1.21 (18.35)
WBC	10	7.46±0.47	7.51± 0.96 (-0.67)	8.03± 0.65 (-7.64)	8.24± 0.95 (-10.45)
PCV	10	41.21±1.11	40.2± 1.02 (2.45)	39.04±1.32 (5.26)	38± 1.31 (7.78)
MCV	10	83.29±1.51	89.26±1.24 (-7.16)	91± 1.56 (-9.25)	97.07± 1.29 (-16.54)

**Table 5: Effects of sub-lethal of SAAF (dose – 11.5 mg/L) on haematological parametrrs were determined in *O. mossambicus* after 10, 20 & 30 days exposure.**

Parameters	No. of fishes	Control	Toxicated		
			10 Days	20 days	30 days
Haemoglobin	10	12.08±0.15	10.96 ± 0.15 (9.27)	9.77± 0.24 (19.12)	9.46 ± 0.43 (24.17)
RBC	10	2.56± 1.61	2.26 ± 1.16 (46.87)	2.11 ± 1.34 (17.57)	1.66 ± 1.26 (35.15)
WBC	10	7.46± 0.47	8.56 ± 0.81 (-14.74)	8.69± 0.37 (-16.48)	9.03± 0.24 (-21.04)
PCV	10	41.21±1.11	39.21± 1.19 (4.85)	37.33± 1.07 (9.41)	36.42± 1.63 (11.62)
MCV	10	83.29±1.51	90.59± 1.31 (-8.76)	93.23± 1.48 (-11.93)	97.26± 1.02 (-16.77)

**Table 6: Effects of sub-lethal of SAAF (dose – 12.5 mg/L) on haematological parametrrs were determined in *O. mossambicus* after 10, 20 & 30 days exposure.**

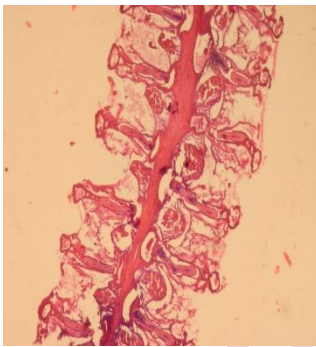
Parameter	No of fishes	Control	Toxicated		
			10 days	20 days	30 days
Haemoglobin	10	12.08±0.15	10.29±1.21 (16.47)	9.82± 1.28 (18.70)	9.31± 1.41 (22.93)
RBC	10	2.56± 1.19	2.19± 1.15 (14.45)	2.02± 1.46 (21.09)	1.21± 1.31 (52.73)
WBC	10	7.46± 0.37	8.63± 0.24 (-15.68)	9.11± 1.06 (-23.19)	10.02± 1.39 (-34.31)
PCV	10	41.12±1.11	38± 1.25 (7.58)	37.16± 1.28(9.63)	35.48± 1.27(13.71)
MCV	10	83.29±1.31	91.81± 1.16 (-10.22)	94.56± 1.34 (-13.53)	98.13± 1.22 (-17.81)



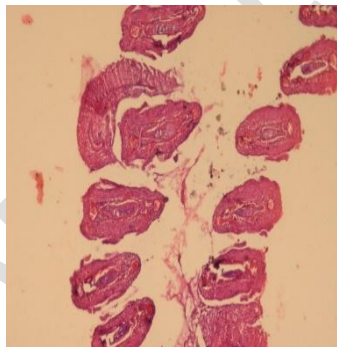
Figure 1: Fish species: *Oreochromis mossambicus*



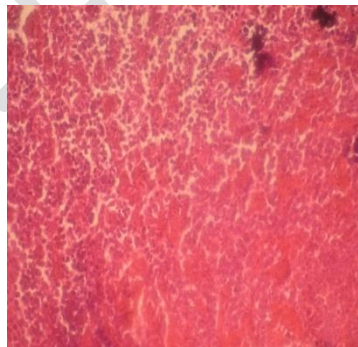
Figure 3: Acclimatization of *Oreochromis mossambicus*



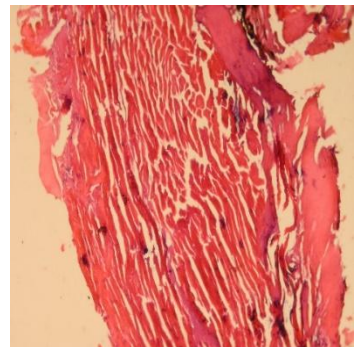
**Figure 4(A): Gill of Control Fish**



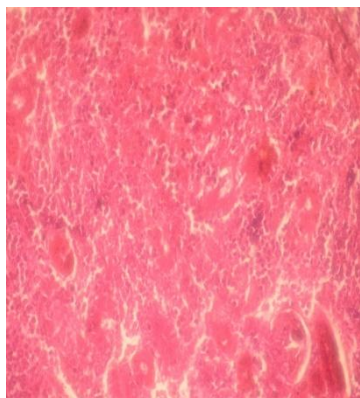
**Figure 4(B): Gill of Toxicated Fish**



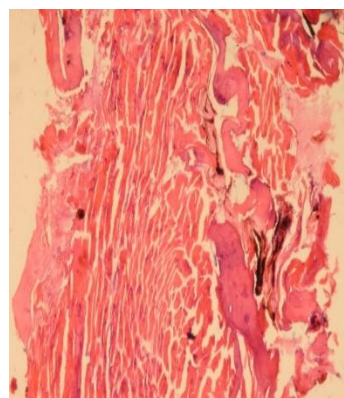
**Figure 5(A): Liver of Control Fish**



**Figure 5(B): Liver of Toxicated Fish**



**Figure 6(A): Kidney of Control Fish**



**Figure 6(B): Kidney of Toxicated Fish**

**Fig 4-6 (A-B): Slides of Organs of Control and Toxicated *Oreochromismossambicus*; Sacrificed after 30 days of exposure to SAAF**

UNDER PEER REVIEW