

PILOMATRIXOMA OF THE CHEST WALL: A CASE REPORT

ABSTRACT:

Pilomatrixoma is typically an isolated benign tumor of the hair follicle matrix with very low incidence, recurrence, and initial diagnostic accuracy. This report presents a case of a on the chest that was initially ignored due to the lack of awareness. The paper helps to emphasize the importance of its vast differential diagnosis.

INTRODUCTION:

Pilomatrixoma, **pilomatricoma** or calcifying epithelioma of Malherbe, is a rare benign tumor characterized by differentiation toward the hair matrix and cells originating in the cortex[1]. About one percent of all benign skin lesions are **pilomatrixoma**, [2], hence it is a relatively uncommon tumor.

From an epidemiological perspective, patients younger than 20 years old, more frequently women, present **pilomatrixoma** in the existing literature. The majority of tumors were located in the upper body (including head and neck) and the limbs. **Pilomatrixoma** typically presents as a solitary lesion, although some patients may present multiple lesions [3].

Pilomatrixoma typically manifests as a firm, **moveable**, and slowly expanding mass. Although discomfort or discharge from the lesions is uncommon, it has been reported [4,5]. **Pilomatrixoma** is a mass that appears under the skin and originates in the deep dermis or subcutaneous tissue. As the top layer of skin thins, sometimes clearly defined arteries or skin ulcerations become visible [6,7]. Due to its diverse clinical presentation, **pilomatrixoma** is frequently **misdiagnosed** as epidermal cysts or dermoid cysts prior to surgical removal [7,8], resulting in an extremely low rate of proper preoperative diagnosis. **Furthermore, there is a dearth (or paucity) of information about pilomatrixoma occurring in other parts of the body.** Thus, we show a case of chest wall **pilomatrixoma**.

CASE PRESENTATION:

A 43-year-old male came to general surgery OPD of a tertiary care hospital with the **main complaint** of “Swelling over chest in the midline since 2 years”. The “swelling” was initially of size of a pea which has progressed to the present size of a lemon **and was** not associated with pain, discharge or fever.

Clinical Findings

Clinically, a 5x3 cm nodosity was observed located in the upper midline of the chest (Figure?). Firm consistency, moveable, painless and with no increase in local temperature. The axillary lymph nodes were not palpable bilaterally, there were no engorged veins and no ripples in the skin of the chest wall.

Diagnostic Assessment

A Fine Needle Aspiration Cytology (FNAC) was done which suggested a round cell neoplasm.

Intervention

An excisional biopsy of the nodosity was performed under general anesthesia. A mass of 5x4x2cm was removed after separating from surrounding structures and sent for histopathology (Figure 1).

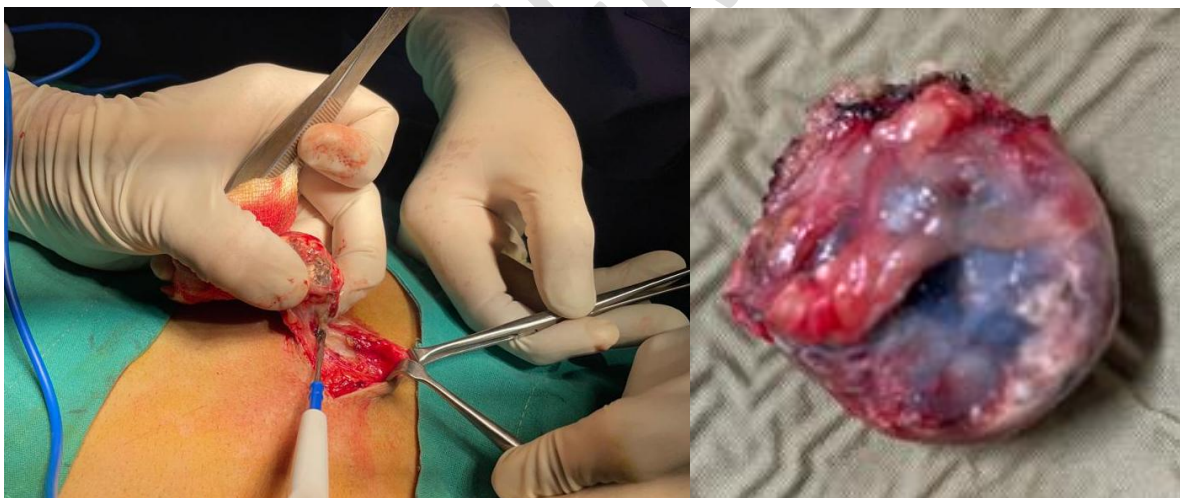


Figure 1 - Intraoperative excisional biopsy along with the excised mass

Histopathological Findings

Histopathologically, the hematoxylin and eosin (HE) stained sections showed a tumor composed of an epithelial component exhibiting the typical population of basaloid and ghost cells and a mesenchymal component showing fibroblastic proliferation. The basaloid cells were characterized by round to oval, hyperchromatic nuclei and scanty cytoplasm. The ghost cells were eosinophilic with a central unstained shadow in the site of the lost nucleus suggestive of calcified and ossified adnexal tumour favouring pilomatrixoma (Figure 2).

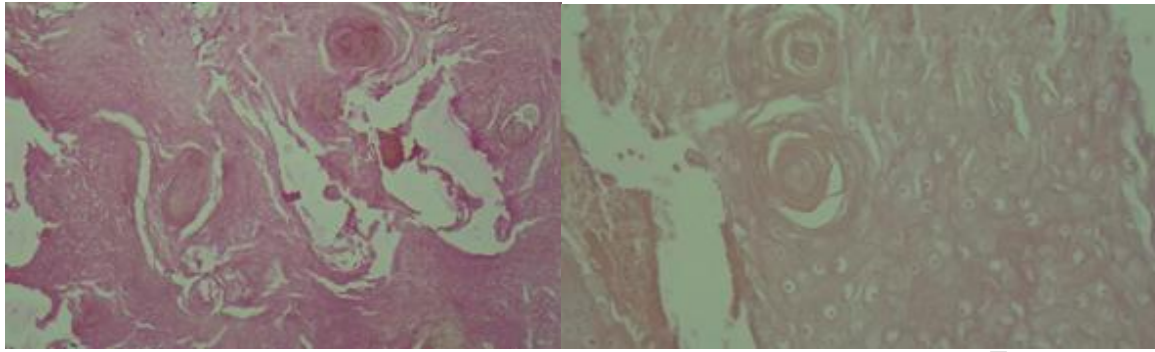


Figure 2 - H/E stain showing ghost cells

Follow-up and Outcomes

The patient tolerated the wide excision well and continued to keep regular follow-up appointments with surgery staff.

DISCUSSION:

Pilomatrixoma, also known as calcifying epithelioma of Malherbe, develops from the matrix cells of hair follicles. This lesion, formerly assumed to originate in the sebaceous glands, was first reported by Malherbe and Chenantais in 1880 and given the name calcifying epithelioma. To more clearly communicate the histological origin, Forbis and Helwig (1961) coined the term **pilomatrixoma** in their paper. [1,2]

About 90 occurrences of a rare malignant variant called pilomatrix carcinoma have been recorded in the medical literature. It can recur and has an aggressive local pattern. It has shown evidence of metastasis in numerous instances. **While we did find some similarities between our case and the malignant counterparts**, we did not find any of the hallmarks of malignancy, such as a high mitotic rate with atypical mitoses, central necrosis, infiltration of skin and soft tissue, or invasion of blood and lymphatic vessels.[1-4]

In most cases, the skin directly over a tumor will seem and feel normal, but the examiner may notice a **tent sign** – a flattening of part or all of the tumor's surface with angulation that resembles the side of a tent – if they stretch the skin. This is because the tumor is fusing with the epidermis above it, which causes blood vessels to develop through the skin and cause a bluish or reddish tint.[9] Myotonic dystrophy, Gardner syndrome, xeroderma pigmentosum, and basal cell nevus syndrome have all been linked to multiple pilomatrixomas, despite the fact that these tumors are typically isolated.[3,6,8]

A **pilomatrixoma** is characterized by distinct tumor borders and a connective tissue capsule on histopathology. It can be found in the dermal or subcutaneous tissue. Cystic transformation is common, and the tumor itself consists of islands of epithelial cells formed of varied numbers of uniform basaloid matrical cells. These basaloid cells centrally degenerate as the tumor advances in stage. The unstained centers of these cells give rise to the **awkward** appearance of ghost or shadow cells. Despite their specificity, however, these

phantom cells are not restricted to **pilomatrixomas**. There could be a moderate to severe inflammatory response. Giant cells not native to the body, keratin fragments, and central calcifications are also present. In between 70% and 85% of instances, calcification was observed.[2,7,10-12]

Due to their often superficial, tiny, and well-circumscribed nature, **pilomatrixomas** are rarely evaluated with diagnostic imaging. In this example, plain radiographs showed nothing unusual, however **pilomatrixomas** often show calcification at certain points. CT scans reveal a well-defined, subcutaneous lesion of dense soft tissue, with or without calcification. On MRI, calcifications could look like a rim-enhancing lesion with some small pockets of signal dropout.[13-15] A well-defined mass is seen on ultrasound, either totally echogenic with prominent posterior or acoustic shadowing in the subcutaneous layer or with inner echogenic foci and a peripheral hypoechoic rim.[16]

Reviewing several case reports and series, Wang et al. found that 45 percent of **pilomatrixoma** patients were misdiagnosed by fine needle aspiration cytology.[17] However, fine needle aspiration has been found to be quite accurate in their study and other more recent studies when two critical components are observed, basaloid cells and ghost cells, since this has been found to be specific for **pilomatrixoma**. [10]

Marginal excision, like in this case, is a common method of treating **pilomatrixomas**. Excision of the skin may be necessary if the tumor has invaded the dermis. The recurrence rate is quite small, falling between 3% and 0%. [1,2,4,7] **Recurrence or rapid growth after surgical excision warrants reapproach to rule out malignancy or misdiagnosis.**

CONCLUSION:

In conclusion, although there have been case reports in the literature describing the clinical features and location addressing the main differential diagnoses and diagnostic pitfalls of **pilomatrixoma**. Given the focality of the changes, lesion in our case was best described as **pilomatrixoma**, in such cases wide excision surgery is recommended.

The main purpose of this article is to raise awareness among clinicians and illustrate the value of careful clinical screening, which can render definitive diagnosis of early, asymptomatic and clinically unsuspected cases of **pilomatrixoma**.

REFERENCES:

1. Birman, M. V., Mc Hugh, J. B., Hayden, R. J., & Jebson, P. J. L. (n.d.). *Pilomatrixoma of the fore Arm: A Case Report*. Nih.gov. Retrieved August 10, 2023, from <https://www.ncbi.nlm.nih.gov/pmc/articles/PMC2723706/pdf/iowa0029-0121.pdf>
2. Moehlenbeck FW. Pilomatrixoma (calcifying epithelioma): a statistical study. *Archives of Dermatology*. 1973 Oct 1;108(4):532-4.
3. Harper PS. Calcifying epithelioma of Malherbe: Association with myotonic muscular dystrophy. *Archives of Dermatology*. 1972 Jul 1;106(1):41-4.
4. Noguchi H, Kayashima K, Nishiyama S, Ono T. Two cases of pilomatrixoma in Turner's syndrome. *Dermatology*. 1999 Dec 24;199(4):338-40.
5. Malherbe A, Chenantais J. Note sur l' pithomecalcifi des glandes sabacees. *Prog Med (Paris)*.

6. Forbis R, Helwig EB. Pilomatrixoma. *Arch Dermatol.* 1961;83:606-618.
7. Lopansri S, Mihm MC., Jr Pilomatrix carcinoma or calcifying epitheliocarcinoma of Malherbe: a case report and review of literature. *Cancer.* 1980 May 1;45(9):2368-73. [PubMed]
8. Kumaran N, Azmy A, Carachi R, Raine PA, Macfarlane JH, Howatson AG. Pilomatrixoma - accuracy of clinical diagnosis. *J Pediatr Surg.* 2006;41:1755-1758.
9. Graham JL, Merwin CF. The tent sign of pilomatrixoma. *Cutis.* 1978;22:577-80.
10. Solanki P, Ramzy I, Durr N, Henkes D. Pilomatrixoma: Cytologic features with differential diagnostic considerations. *Arch Pathol Lab Med.* 1987;I 11:294-297.
11. Pant I, Joshi SC, Kaur G, Kumar G. Pilomatrixoma as a diagnostic pitfall in clinical practice: report of two cases and review of literature. *Indian J Dermatol.* 2010 Oct;55(4):390-2
12. DeRosa DC, Lin-Hurtubise K. Pilomatrixoma: an unusual dermatologic neoplasm. *Hawaii J Med Public Health.* 2012 Oct;71(10):282-6
13. Som PM, Shugar JM, Silvers AR. CT of pilomatrixoma in the cheek. *Am J Neuroradiol.* 1998;19:1219-1220.
14. 11. De Beuckeleer LH, De Schepper AM, Neetens I. Magnetic resonance imaging of pilomatrixoma. *Eur Radiol.* 1996;6:72-75
15. 12. Hoffmann V, Roeren T, Möller P, Heuschen G. MR imaging of a pilomatrixoma. *Pediatr Radiol.* 1998;28:272.
16. Hughes J, Lam A, Rogers M. Use of ultrasonography in the diagnosis of childhood pilomatrixoma. *Pediatr Dermatol.* 1999;16:341-344
17. Wang J, Cobb CJ, Martin SE, Venegas R, Wu N, Greaves TS. Pilomatrixoma: clinicopathologic study of 51 cases with emphasis on cytologic features. *Diagn Cytopathol.* 2002;27:167-172