

Anal abscess revealing rectal cancer: case report

ABSTRACT

An anal abscess or fistula is a rare presentation of cancer. Assuming a benign condition, diagnosis is often delayed, leading to advanced stages of the tumor at first diagnosis. Due to the rarity of these cases, there are no treatment guidelines for cancers of the anorectal region presenting as abscesses or fistulas. For these reasons, we share our experience in the management of adenocarcinoma discovered following persistent inflammation due to chronic anal fistula. We focus on the clinical presentations, assessments and treatments of these individuals.

Keywords: [Rectal cancer ,Anal abscess , Emergency , Tumor]

1. INTRODUCTION

Abscess or **fistula** of the anal region is an uncommon presentation of malignancy. Under the assumption of a benign condition, diagnostics is often delayed, resulting in advanced **tumor**stages at **first** diagnosis. Due to the case rarity, treatment guidelines for cancers of anorectal region masquerading as abscess or **fistula** are missing.[1]

. For these reasons, we offer our experience in managing an adenocarcinoma discovered as a result of persistent inflammation caused by a chronic anal fistula, emphasising and discussing the clinical presentations, assessments, and therapy of those individuals.[2]

2. PRESENTATION OF CASE

Patient aged 52, diabetic on metformin, with a history of recurrent anal abscesses operated on three times. During the last operation, a seton drain was inserted, which remained in place for six months, but which the patient did not tolerate. He consulted the emergency department complaining of anal pain and perianal erythema, which had been present for three months. The patient had interpreted this as a recurrence of his abscess and had hesitated to consult for fear of a new operation.

On admission, the patient was hemodynamically stable. Anal examination revealed a scar with two horseshoe-shaped external orifices, linked to the old fistula, located at 11 o'clock and 2 o'clock (Figure 1).

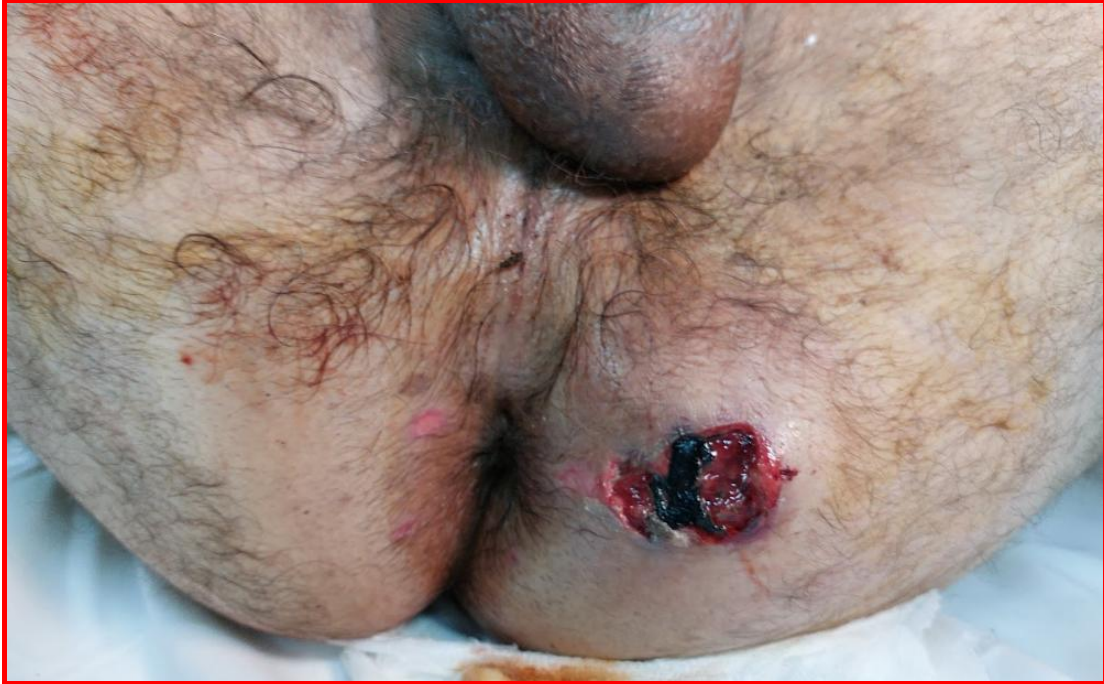

FIGURE 1 : PREOPERATIVE IMAGE SHOWING THE CLINICAL PRESENTATION

Adjacent to this area was a 3cm ulceration with irregular margins and a necrotic fundus leaking pus. On touch, a fixed ulcer-burgeoning process was palpated, located 5 cm from the anal margin.

A total colonoscopy was performed, revealing a tumor in the lower rectum with no other location in the rest of the colon. Biopsies of the tumor were taken. Anatomopathological findings confirmed the presence of a moderately differentiated adenocarcinoma. A TAP (please explain extensively the acronym) extension study was performed, revealing no distant location in the rectum but showing local invasiveness (Figures 2 and 3).

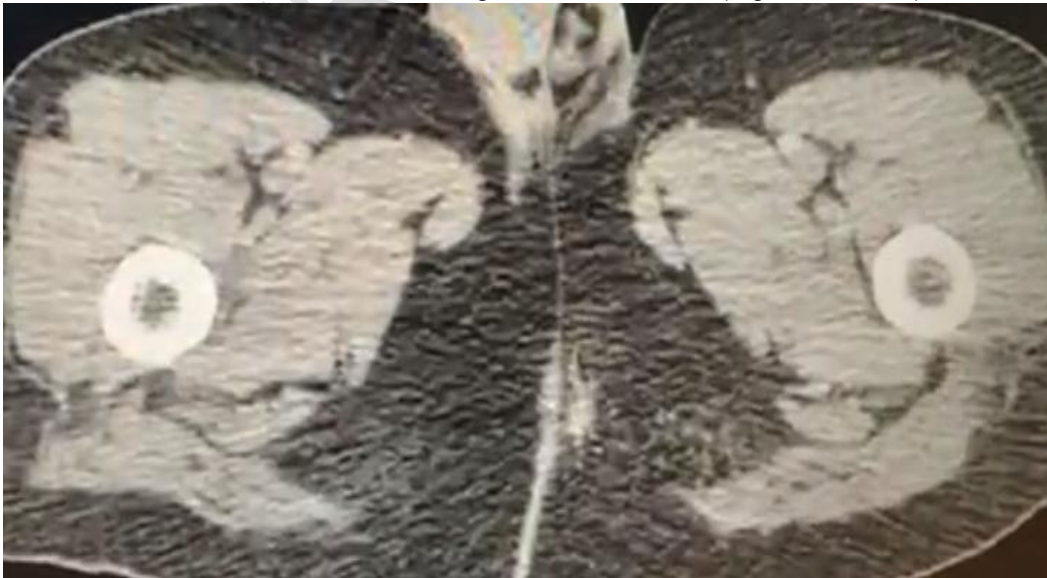

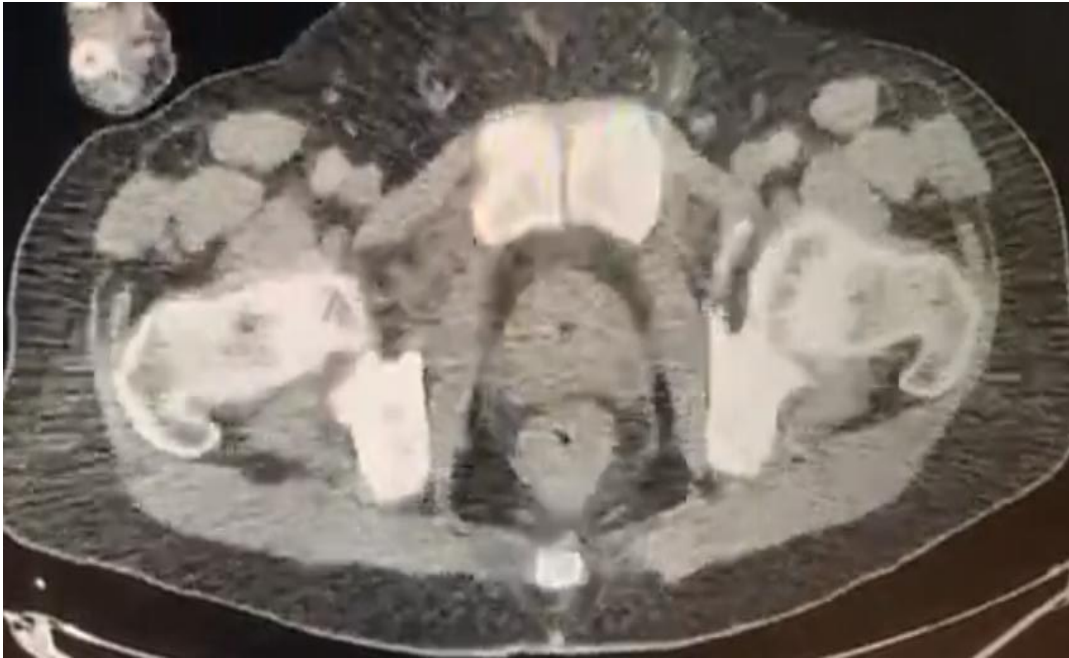


Figure 2 : Axial scan section showing the fistulous path

Figure 3 : axial CT section showing the rectal tumor

The patient underwent neoadjuvant radiochemotherapy, followed by abdominoperineal amputation, with a favourable outcome and no signs of recurrence over 2 years of follow-up.

3. DISCUSSION

To the best of our knowledge, Guiss et al. were the first to report cancer implantation in an anal fistula in 1954) [4] In most cases, the cause of anal fistula is considered to be non-specific cryptoglandular infection, and to a lesser extent, it is associated with inflammatory bowel disease, infections (such as actinomycosis, tuberculosis, lymphogranuloma venereum, human immunodeficiency virus), trauma, surgery, malignancy, and irradiation [3]

Colorectal cancer is the second most common cause of cancer-related death worldwide. It is well-known that metastasis to the liver and lung and local recurrences can occur.

Additionally, colorectal cancer occasionally metastasizes to other sites.[4] and grafting on an anal fistula path is exceptional, as in the case of our patient.

There are two types of cancer of an anal fistula: carcinoma originating in a chronic anal fistula, and the implantation of rectal or colon cancer cells in an anal fistula.[6]

In most patients, early diagnosis of this disease is difficult. Detection is usually late as the symptoms often initially mimic benign inflammatory conditions of the anorectal region and biopsies fail to reveal the infiltrating carcinoma.[5]

A histological diagnosis is definitely necessary to confirm the diagnosis and thence for treatment to be initiated. As some anal adenocarcinomas have mucinous features, superficial biopsies are often inadequate as these mucinous tumors form mucin lakes in the submucosa and muscularis propria layers [2]

Once the diagnosis has been confirmed, a multidisciplinary approach is preferred due to the complexity of the condition. Neo-adjuvant chemoradiotherapy has been reported to be promising in the management of this condition,[2]

Surgical resection is the first choice of curative treatment for perianal mucinous carcinoma [5]. As local excision is inadequate in most cases, APR with wide excision of both ischiorectal fossae and the overlying skin is recommended. On the other hand, radiotherapy alone or combined with chemotherapy can be a curative treatment for squamous cell carcinoma of the anal canal[5] and can also be used as an adjunct to surgery as part of the **neoadjuvant** protocol, as we are doing for our patient.

The prognosis in these advanced cases is not so severe, with many of the reported patients surviving without recurrence. Perioperative adjuvant and neoadjuvant therapy,, may improve the prognosis. [7]

4. CONCLUSION

The occurrence of anal abscess as the first sign of rectal cancer is a rare but important presentation. This observation highlights the need to search for an underlying cause in patients presenting with unusual anorectal symptoms, even in the absence of a significant medical history. **As symptoms could be misleading, in all cases of anal fistula presents an inexplicable trend, an early colonoscopy is probably recommended.**

Advanced anorectal carcinomas might masquerade as abscesses or **fistulas**, causing diagnostic issues and delaying oncologic therapy. Even in these extreme cases, surgical treatment with a curative purpose should be performed.

ETHICAL APPROVALS per international standard or university standard written ethical approval has been collected and preserved by the author(s).

CONSENT As per international standard or university standard, patient(s) written consent has been collected and preserved by the author(s).

REFERENCES

1. Tekbaş A, Mothes H, Settmacher U, Schuele S. Non-mucinous adenocarcinomas and squamous cell carcinomas of the anal region masquerading as abscess or fistula: a retrospective analysis and systematic review of literature. J Cancer Res Clin Oncol. 2022 Jun 1;148[6]:1509–22.
2. Leong FQH, Chan DKH, Tan KK. Anal Adenocarcinoma Can Masquerade as Chronic Anal Fistula in Asians. Ann Coloproctology. 2018 Dec 3;35[1]:47–9.
3. Fukai S, Tsujinaka S, Miyakura Y, Matsuzawa N, Hatsuzawa Y, Maemoto R, et al. Anal fistula metastasis of rectal cancer after neoadjuvant therapy: a case report. Surg Case Rep. 2022 Mar 31;8[1]:57.
4. Kato R, Miyamoto Y, Sawayama H, Ogawa K, Iwatsuki M, Iwagami S, et al. Relapse of Rectal Cancer in an Anal Fistula: A Rare Case. Vivo Athens Greece. 2021;35[5]:2937–40.
5. Ohta R, Sekikawa K, Goto M, Narita K, Takahashi Y, Ikeda H, et al. A Case of Perianal Mucinous Adenocarcinoma Arising from an Anorectal Fistula Successfully Resected after Preoperative Radiotherapy. Case Rep Gastroenterol. 2013;7[2]:219–23.

6. [Ishiyama S, Inoue S, Kobayashi K, Sano Y, Kushida N, Yamazaki Y, et al. Implantation of Rectal Cancer in an Anal Fistula: Report of a Case. Surg Today. 2006 Aug 1;36\(8\):747–9.](#)
7. [Ikeda T, Nanashima A, Ichihara A, Kitamura E, Nagatomo K, Tanaka H. A rare case of rectal cancer with perianal metastasis: a case report. World J Surg Oncol. 2019 Aug 20;17\[1\]:149.](#)

[Mucoïd carcinoma of the anus and perianal fistula: a clinical case and review of the literature]

[Article in Italian]

[R Bronzi, L Puglielli, P Innocenti, G Pizzicannella, L Artese, A Capelli, A M Napolitano](#)

- PMID: 2562044

Abstract

The Authors describe a case of mucoïd anal carcinoma occurring in a perianal fistula. Surgical treatment was an abdomino-perineal resection (Miles' operation). On the basis of their experience and of the results reported in the literature, the Authors discuss the clinical and histological aspects of this association.

Similar articles

- [\[Anal mucinous adenocarcinoma arising in long standing fistula-in-ano\].](#)

Itah R, Werbin N, Skornick Y, Greenberg R. Harefuah. 2008 Feb;147(2):117-9, 183. PMID: 18357666 Hebrew.

- [\[Infiltrating mucinous carcinoma developed on chronic anal fistula; diagnostic and surgical difficulties\].](#)

Mateş IN, Dinu D, Rădulescu G, Iosif C. Chirurgia (Bucur). 2003 Sep-Oct;98(5):459-64. PMID: 14999975 Romanian.

- [Mucinous adenocarcinoma arising from chronic perianal fistula.](#)

Hisham RB, Sabariah AR, Yunus AG. Med J Malaysia. 2006 Mar;61(1):88-90. PMID: 16708740

- [\[Perianal colloid adenocarcinoma. Apropos of a case\].](#)

Cougard P, Dramard JM, Morin F, Ferry C. J Chir (Paris). 1988 Apr;125(4):276-8. PMID: 2839530 Review. French.

- [Perianal mucinous adenocarcinoma: unusual case presentations and review of the literature.](#)

Schaffzin DM, Stahl TJ, Smith LE. Am Surg. 2003 Feb;69(2):166-9. PMID: 12641361 Review.

UNDER PEER REVIEW