

Original Research Article

Aqueous extract of the leaves of *OcimumGratissimum* (*Lamiaceae*)(false basil) as an alternative to the chemical antibiotics used in breeding cobb500 broiler chickens in the department of Azaguie(Côte d'Ivoire).

ABSTRACT

In order to propose a plant extract as an alternative to the use of antibiotics used in broiler breeding, an experimental study was carried out in the department of Azaguie and the choice fell on the aqueous extract leaves of *OcimumGratissimum* L (EAOG). To achieve this objective, fifty (50) broiler chicks of COBB 500 strains were divided into two (02) batches of twenty-five (25) each. Thus, batch I received only the aqueous extract of *Ocimumgratissimum* L., while batch II received the prophylaxis recommended for rearing in this locality. Phytochemical screening revealed the presence of sterols and polyterpenes, polyphenols, flavonoids, alkaloids and catechin tannins in *OcimumGratissimum*L. The acute toxicity study carried out on broilers showed that EAOG is not toxic by the oral route in a single dose at a dose of 2000 mg/kg BW. The EAOG caused a significant increase ($p < 0.05$) in the live weight of the treated chickens compared to the controls. In addition, the results showed a significant reduction in the mortality rate and feed conversion ratio of chickens treated with EAOG compared to controls. Finally, concerning the biochemical and leukocyte parameters, the results showed a significant increase in the levels of urea and AST, lymphocytes, white blood cells, neutrophils and basophils of chickens treated with the extract compared to those treated with the usual antibiotics. The aqueous extract of the leaves of *Ocimumgratissimum* could be recommended to poultry farmers as an alternative to the usual antibiotics.

Keywords: Broilers, *Ocimumgratissimum* L., alternative, antibiotic

1. INTRODUCTION

Poultry farming is an important source of income and contributes to food safety for a large part of the population in countries south of the Sahara. [1] However, **Poultry industry** conduct is dominated by the misuse of antibiotics [2]. Consequently, the European Union (EU) has banned the use of antibiotics for preventive purposes and as feed additives in

livestock production [3]. Indeed, the inappropriate use of these antibiotics has harmful consequences on the health of animals and that of consumers [4]. Studies carried out in several countries including Ghana, Nigeria and Senegal have revealed prevalence rates antibiotic residues of 30.8% for beef, 29.3% for kid meat, 28.6% for pork, 24% for mutton [5]. In Côte d'Ivoire, studies by Dagnogo et al. [6] revealed the presence of tylosin residues in chicken eggs. Added to this is the strong resistance of bacteria of animal origin to antibiotics [7] and their possible transmission from animals to humans [2]. In view of all these disadvantages, it is therefore important to look for alternatives. For this, an increasingly growing interest is focused on the use of natural products such as plant extracts [8] developing future drugs. *Ocimum gratissimum* (Lamiaceae) is one of the most used plants in traditional medicine in the treatment of several pathologies [9]. Indeed, it has healing, antifungal and anthelmintic properties [10]. In view of these multiple uses, could the aqueous extract of the leaves of *Ocimum gratissimum* be used as an alternative to chemical antibiotics in broiler breeding? Thus, the general objective of this study is to contribute to the improvement of the production of broiler chickens and the health of consumers by the use of the aqueous extract of the leaves of *Ocimum gratissimum* as an alternative to the chemical antibiotics used in raising broiler chickens.

2. MATERIALS AND METHODS

2.1. Plant material

The plant material consists of fresh leaves of *Ocimum gratissimum* L. These leaves were harvested in September 2021 at the Felix Houphouët-Boigny University (UFHB) and authenticated at the UFHB National Floristic Center under the number ucj008881.

2.2. Animal material and feed

The study focused on fifty (50) COBB500 strain broilers. A bag of starter pellets and five (05) bags for growth and finishing all of 50 kg purchased from the company IVOGRAIN were used for food.

2.3. Veterinary products

The veterinary products used are antibiotics, vaccines and vitamins (Amin 'total). Panteryl and Vetacox are used respectively as anti-stress and anticoccidial. H120 vaccines are used against Infectious Bronchitis and Ornibur against Gumboro. The combined sota HB1 120 and

AVIVAC-IB+ND+ have been used respectively against Newcastle disease and Infectious Bronchitis.

2.4. Arrival of chicks and start-up

The chicks purchased from the WECIPlus hatchery were transported to the poultry house. On arrival, the number of chicks delivered, the average weight and the health status of the chicks were checked.

2.5. Livestock management

The study took place from October to November 2021. It was carried out in Azaguié, 3 km from the village Abbé-Bégnini in the N'KOH plantation. Before receiving the chicks, the breeding building was subject to a fifteen (15) day crawl space. Litter made of wood shavings was spread over the entire surface of the floor. The radiant fixed to the beams was suspended about 1 m above the ground; which made it possible to heat the starting area.

2.6. Substitution of antibiotics by the aqueous extract

The prophylaxis program of this study is given in Table I.

Table I: Sanitary prophylaxis applied to chickens during the trial

Age (days) ^o	Shares	Products administered
1	Controls: Administration of antibiotic as anti-stress (2g/2l of water)	Pantéryl
	Treated: Administration of EAOG plant extract as an anti-stress (2g/2l of water) EAOG	
2,3,4	Controls: vitamins (2g/2l of water)	Pantéryl
	Treated: Administration of plant extract as vitamins (2g/2l of water) EAOG	
9	Controls and treated: 1st GUMBORO vaccine (2g/2l of water)	Ornibur
10,11,12	Controls and treated: Newcastle vaccine and Infectious bronchitis in drinking water (2g/2l of water)	HB1 120
18,19,20	Controls: Anticoccidials (2g/2l of water)	Vetacox S
	Treated: Administration of plant extract as anticoccidials (2g/2l of water) EAOG	

22,23,24	Controls: Newcastle vaccine booster + vitamins (2g/2l of water)	Lasota combiné + Amintotal
	Treated: Newcastle vaccine booster + vitamins (2g/2l of water)	EAOG
24,27	Controls: Administration of antibiotic Tétracolivit	
	Treated: Administration of plant extract as antibiotic (2g/2l of water)	EAOG
30,31,32	Treated and Controls: Newcastle and Infectious Bronchitis vaccine booster in drinking water (2g/2l of water)	AVIVAC-IB+ND+
40,42	Treated and Controls: Newcastle and Infectious Bronchitis vaccine booster in drinking water (2g/2l of water) Tétracolivit	
	Treated: Administration of plant extract as an antibiotic (2g/2l of water)	EAOG

EAOG :aqueous extract of *Ocimumgratissimum* leaves

2.7. Phytochemical screening

The characterization of the different chemical groups was carried out using the techniques described Békro et al. by [11].

2.8. Acute toxicity of the aqueous extract of *OcimumGratissimum*

Leaves Acute toxicity was carried out according to the guideline of the Organization for Economic Co-operation and Development (OECD) 423 [12]. The study was carried out on nine (09) chickens of which six (06) were used for the test and the three (03) were used for the repetition of the test. From the 1st to the 21st day, the chickens received antibiotics and vaccines in accordance with the prophylaxis recommended in the department of Azaguié. On the 21st day, the chickens were divided into two batches of three (03) chickens each. In accordance with the LD50 greater than 2000 mg/kg bw indicated by the work of Piba et al. [13], the dose of 2000 mg/kg PC was chosen. Thus, batches I and II received respectively the aqueous extract of *Ocimumgratissimum* leaves in a single dose at a dose of 2000 mg/kg bw and distilled water at a dose of 1 ml/100g. The chickens were observed individually every 30 minutes for 24 hours then regularly 14 days. Special attention was given during the first 4 hours and daily for 14 days. Observations included changes in feathers, beak, eyes, tremors, convulsions, diarrhea, sleep and coma.

2.9. Livestock management: Practical phase

After the start-up phase, the chickens were weighed individually, and divided into two batches of twenty-five (25) each depending on the treatment (control batch and treated batch). Thus, each batch was fed with pellets. The quantities of pellets served and refused are weighed.

2.10. Effect of EAOG on zootechnical parameters

The average live weight, the consumption index (IC), as well as the mortality rate (MR) and the relative weight of the organs were calculated according to the following methods.

Average live weight = Sum of the weights of the chickens of the same batch / Number of the batch.

Consumption Index (IC) = quantity of food consumed / ADG

Mortality Rate (TM) (%) = (Number of dead subjects / Number of subjects placed) *100

Relative organ weight

Relative weight (%) = relative organ weight / body weight *100

2.11. Sacrifice of animals

On the 45th day, **five (05)** chickens from each batch were weighed then slaughtered by bleeding and plucking. They were eviscerated then the organs which are the kidneys, the gizzard, the liver, the spleen and the heart were removed and weighed.

2.12. Effect of the aqueous extract on blood parameters

The blood collected in the purple tubes containing the anticoagulant Ethylene Diamine Tetra Acetic (EDTA) made it possible to misuse the rate of white blood cells (WBC), red blood cells (RB), hemoglobin (HGB), hematocrit (HCT). In addition, mean corpuscular volume (MCV), mean corpuscular hemoglobin (MCH), mean corpuscular hemoglobin concentration (MCHC), blood platelets (PLQ), neutrophils, basophils, eosinophils and lymphocytes were measured using an automaton (SYSMEX XN 1000).

2.13. Effect of the aqueous extract of the leaves on the biochemical markers

Using a Rotofix 32 A type centrifuge (Germany), the blood taken from the dry tubes was centrifuged at 3000 rpm for 4 minutes. Thus, urea, uric acid, alanine-aminotransferase (ALAT), aspartate aminotransferase (ASAT) and creatinine were measured using a HITACHI 704 R (Japan) type automaton.

2.14. Statistical Analysis

Statistical analyzes were performed using Graph Pad version 7 software. The values are presented as mean \pm standard error. The level of significance of the differences between the means are estimated by the t test and the Anova One-way test at the 5% level.

3. RESULTS AND DISCUSSION

3.1. Results

3.1.1. Phytochemical screening

Phytochemical screening showed that the aqueous extract of *Ocimum Gratissimum* contains sterols and polyterpenes, flavonoids, alkaloids, saponosides and catechin tannins.

3.1.2. Acute toxicity

The single dose administration of 2000mg/kg/bw of EAOG did not cause any mortality in treated chickens. In addition, observation of the chickens after 30 min, then regularly for 14 days showed no signs of toxicity, namely salivation, drowsiness, morbidity and coma. The chickens therefore showed signs of well-being like the controls. The aqueous extract of the leaves of *Ocimum Gratissimum* would therefore not be toxic in a single dose. Thus, the LD50 of the extract would be greater than 2000 mg/kg bw.

3.1.3. Evaluation of the effect of EAOG on zootechnical parameters

3.1.3.1. Effect of EAOG on the live weight of the chickens

The average weight of the treated chickens and that of the controls are respectively 2600 ± 50.99 g and 2000 ± 50.95 g. Statistical analysis shows that the mean weight of the treated chickens is significantly higher ($p < 0.05$) than that of the controls.

3.1.3.2. Effect of EAOG on feed conversion

The feed conversion of the treated chickens and that of the controls are respectively 2 and 2.5 (**Figure 1**). Statistical analysis shows that the feed conversion index of the treated chickens is significantly lower ($p > 0.05$) than that of the controls.

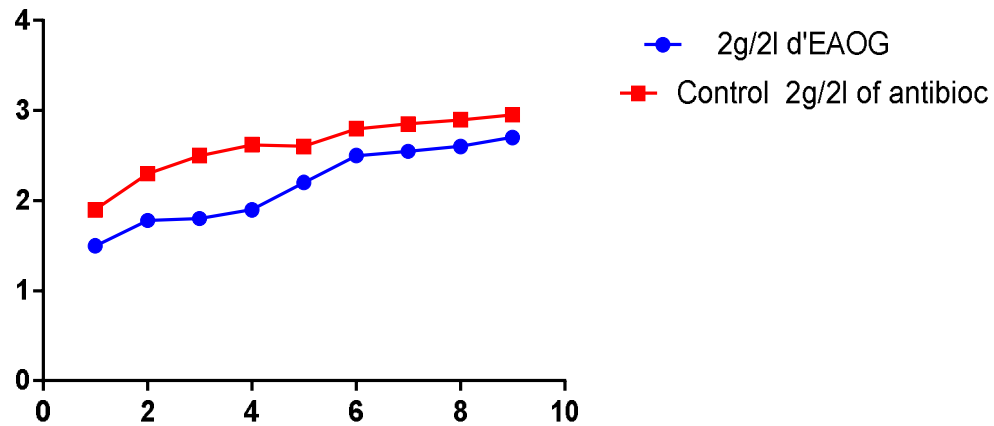
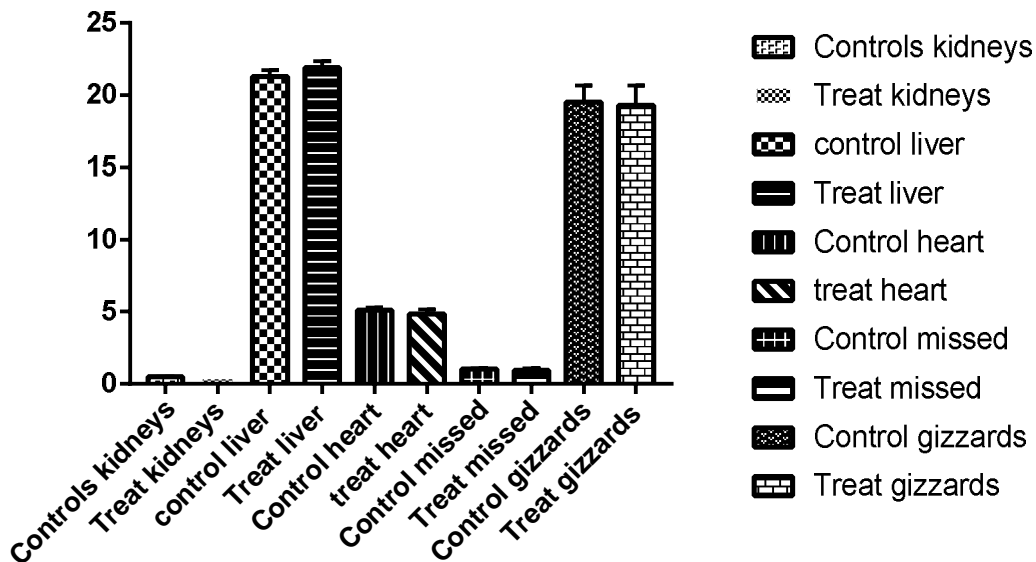


Figure 1: Chicken consumption index

The action of EAOG on the health status and mortality of broiler chickens, presents five cases of mortality including 2 in the treated batch and 3 in the control batch. Statistical analysis showed no significant difference ($p > 0.05$).

3.1.3.3. Effect of the aqueous extract of *Ocimum gratissimum* on the relative weight of the organs

The results relating to the weight of the organs which are the kidney, the liver, the heart, the spleen and the gizzard of chickens treated with the aqueous extract of the leaves of *Ocimum gratissimum* and witnesses, are shown in **Figure 2**. These results revealed that the relative weights of the kidneys, heart, spleen and gizzard of the treated batch are lower than those of the control batch with values of 0.5061 ± 0.002121 for the treated batch and 0.5081 ± 0.005576 for control batch as regards the kidneys. For the heart, these values are 4.519 ± 0.2778 for the treated batch and 5.124 ± 0.3464 for the control batch. The weight of the spleen of the treated batch is 0.8682 ± 0.11 and that of the controls 1.022 ± 0.1557 ; of 18.53 ± 0.8786 for the treated group and 19.5 ± 0.5273 for the control group at the level of the gizzard. Whereas the relative liver weight of the treated group (21.64 ± 0.5003) is greater than that of the control group (21.28 ± 0.6151). Statistical analysis shows no significant difference ($p > 0.05$) between the relative weight of these different organs of treated chickens compared to controls.



Values are mean changes in animal weight, n=25; no significant difference between controls and treated P > 0.05.

Figure 2: Effect of EAOG on relative organ weight after 45 days

3.1.4. Effect of EAOG on biochemical markers

The results showed that the levels of urea, AST, ALT and creatinine of chickens treated with EAOG are lower than those of the control group. The urea levels of the treated batch and the control batch are respectively 0.148 ± 0.00663 and 0.256 ± 0.0276 . At the AST level, the treated group has a value of 111.6 ± 5.391 against 162.2 ± 7.499 for the control group. From the point of view of ALT, the treated chickens have a rate of 79.6 ± 6.129 and the controls a rate of 94 ± 2.2881 ; the creatinine of the treated group is 11.4 ± 3.415 and that of the controls 11.8 ± 2.2881 (**Figure 3**). Statistical analysis showed that only the urea and AST levels of chickens treated with the aqueous extract of *Ocimum gratissimum* are significantly lower ($p < 0.05$) than those of control chickens.

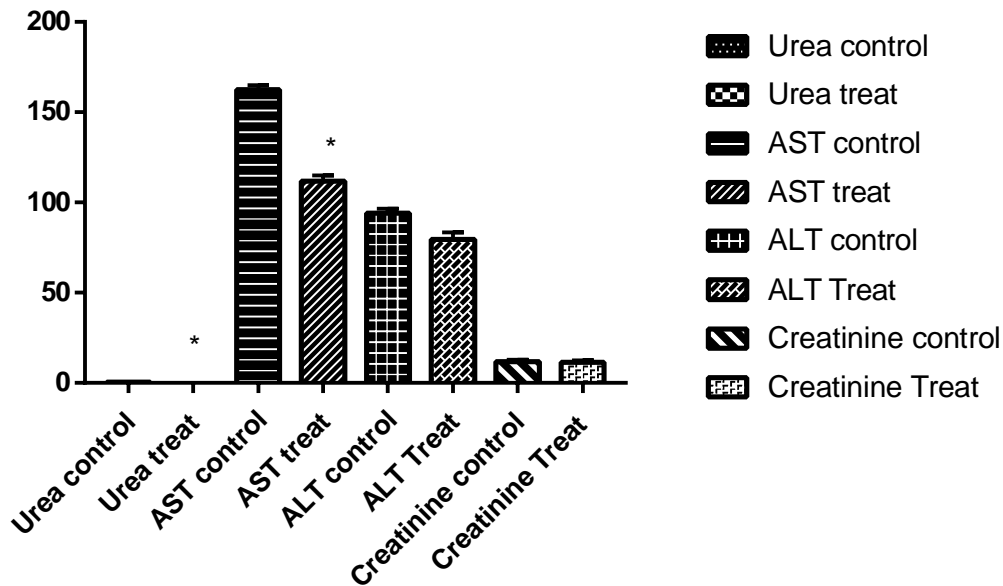


Figure 3: Effect of aqueous extract of *Ocimumgratissimum* on biochemical markers

3.1.5. Effect of EAOG on erythrocyte parameters

Administration of the aqueous extract of the leaves of *Ocimumgratissimum* showed that the levels of red blood cells (RBC), hemoglobin (HGB), mean corpuscular hemoglobin concentration (MCHC) and mean corpuscular volume (MCV) of the treated batch are lower than those of the control batch. At the RBC level, the treated batch has a value of 2.364 ± 0.152 and 2.496 ± 0.467 for the control batch. For HGB, these rates varied from 6.32 ± 0.3484 to 6.86 ± 1.253 from the treated batch to the control batch. The MCHC rate is 26.8 ± 0.2793 for the treated batch and 27.27 ± 0.4857 for the control batch. The MCV is 126.3 ± 2.46 for the treated batch and 129.7 ± 1.537 for the control batch. While at the HCT level, those of the treated batch are higher than those of the control batch. The hematocrits (HCT) of the treated chickens are 29.72 ± 1.524 against 29.26 ± 4.906 for the control group. Statistical analysis showed no significant difference ($p > 0.05$) between the treated group compared to the control in terms of erythrocyte parameters (**Figure 4**).

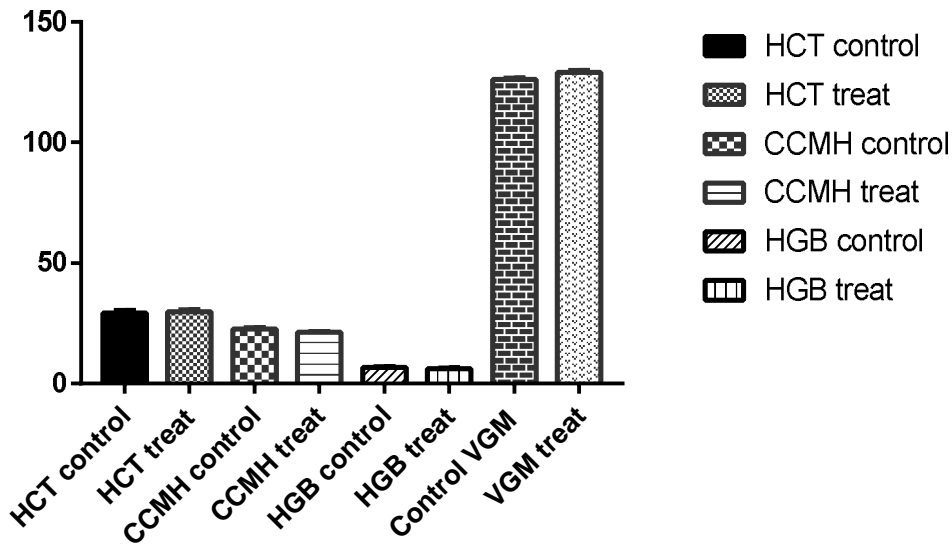


Figure 4: Effect of aqueous extract of *Ocimumgratissimum* on erythrocyte parameters

3.1.6. Effect of EAOG on leukocyte parameters

The results revealed that the levels of lymphocytes, white blood cells, neutrophils and basophils of the treated chickens are higher than those of the control group. With a value of 12.62 ± 1.076 and 6.47 ± 1.962 for the lymphocytes; 27.8 ± 1.664 and 18.18 ± 1.324 for white blood cells; 36.7 ± 1.891 and 23.06 ± 4.832 for neutrophils and 2.98 ± 0.3557 and 1.63 ± 0.1464 for basophils. Statistical analysis of these values shows a significant increase ($p < 0.05$) in treated chickens compared to controls. The rate of blood platelets in the treated batch (10.2 ± 1.158) is higher than the control batch (8.4 ± 1.208). While at the level of eosinophils, those of the treated (0.022 ± 0.0008944) are lower than those of the controls (0.023 ± 0.0007071). However, statistical analysis shows no significant difference ($p > 0.05$) between these two batches in terms of blood platelet and eosinophil cell levels (**Figure 5**).

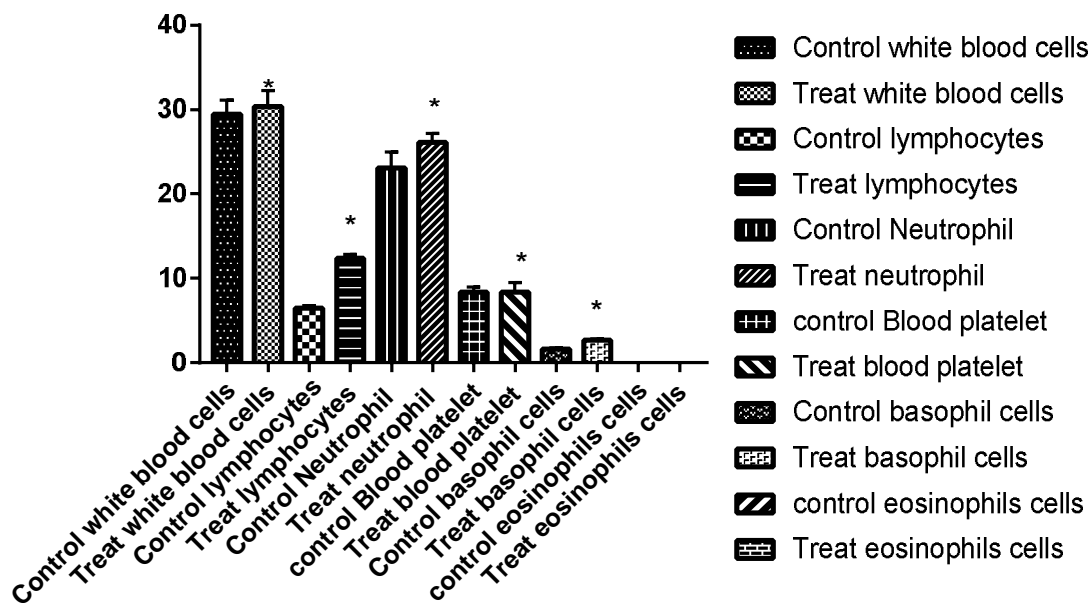


Figure 5:Effect of aqueous extract of *Ocimumgratissimum* on leukocyte parameters

3.2. Discussions

The phytochemical study of the aqueous extract of *Ocimumgratissimum* leaves. revealed the presence of sterols, polyterpenes, polyphenols, flavonoids, alkaloids, saponosides and catechin tannins. These results are consistent with those of Piba et al. [13].Indeed, these authors showed that the aqueous extract of *Ocimumgratissimum* leaves contained the same compounds as polyphenols, tannins, flavonoids and sterols. The results showed that EAOG is not toxic orally in a single dose at the rate of 2000 mg/kg BW. Indeed, no signs of toxicity were observed in chickens. These results corroborate those of Piba et al. [13]According to these authors, administration of the aqueous extract of *Ocimumgratissimum* leaves in a single dose at a dose of 2000 mg/kg BW orally in mice did not show any signs of toxicity. The mean live weights of the treated chickens ($2600 \pm 50.99g$) are significantly higher ($p < 0.05$) than those of the controls ($2000 \pm 50.95g$). These results show that the aqueous extract of *Ocimumgratissimum* leaves would have a beneficial effect on the weight gain of chickens due to its richness in nutrients. Indeed, this extract would be a source of vitamin A (antioxidant), vitamin C (tonic) and minerals (phosphorus, calcium) which are useful for the development of bone tissues [14]. These results are in agreement with those of Atapattu & Belpagodamage [15]. According to these authors, the *Capsicum annum* powder incorporated into chicken feed significantly ($p < 0.05$) increases the weight of treated chickens

(2579±23 g) compared to controls (2375±23 g). The feed conversion index of the treated chickens is lower than that of the controls with values of 2 and 2.5 respectively. This reduction in the feed conversion ratio is very beneficial both for the animal and for the breeder. Because the lower the feed conversion ratio, the more efficient the bird is in converting the food consumed into live weight. These results are consistent with those of Kouakou et al. [16]. According to these authors, the feed consumption index of the layers treated with the aqueous extract of the inflorescences of *Thonningiasanguinea* was lower (2.8) than that of the controls (3.3). During this experiment, two (02) cases of mortalities were observed in treated chickens against three (03) in the control group. Statistical analysis showed no significant difference ($p>0.05$) between these mortality rates. These results are similar to those obtained by Sagna [17]. This author found three (03) mortalities by incorporating the meal of *Azadirachta indica* in the diet of chickens. The results concerning the relative weight of the kidneys, liver, heart, spleen and gizzard revealed no significant difference ($p>0.05$) between these organs in the treated and control groups. These results would show that the aqueous extract of the leaves of *Ocimumgratissimum* would have no lethal action. This extract would, on the other hand, have a lipid and fat retention activity via its polyphenol composition [18]. These results are similar to those of Souahibou [19]. According to this author, the flour of the seeds of *hibiscus sabdariffa L.* does not admit of harmful effects on these same organs in chickens. The results revealed that the urea and AST levels of the batch treated with EAOG at 2g/2l of water are significantly lower ($p<0.05$) than those of the control batch. In fact, the values were respectively 0.148 ± 0.00663 and 111.6 ± 5.391 for the treated batch and 0.256 ± 0.0276 and 162.2 ± 7.499 for the control batch. Urea is an important kidney marker. Its low content in chickens treated with the aqueous extract of the leaves of *Ocimumgratissimum* could mean that this extract would not have a toxic effect on the kidney but rather a reno-protective effect. The results of Gnonlonfoun [20] are different from those of the present study in terms of urea levels. According to this author, there is no significant difference between control (0.053 ± 0.002) and treated (0.073 ± 0.002) batches with ginger powder (*Zingiber officinale* Roscoe) in Ross308 broilers with colibacillosis. This difference could be explained by the breed of chicken chosen [21]. The AST level of chickens treated with EAOG is significantly lower than that of the control batch with the respective values of 111.6 and 162.2 U/I. AST is an important liver marker. Its decrease in chickens treated with the aqueous extract of the leaves of *Ocimumgratissimum* is due to the presence of flavonoids in this extract. Indeed, Lin & Jian-Guo [22] showed that flavonoids have a protective activity on the liver. These results are supported by Dotou [23]. He observed a

significant reduction in the AST level in the treated group with a value of 149.775 ± 0.01 and a value of 152.41 ± 0.34 for the control group after administration of the ethanolic extract of *Tridax procumbens* in the ISA Brown cockerel. With regard to erythrocyte parameters, the results showed no significant difference ($p > 0.05$) between the treated group compared to the control. The nonsignificant variation of the erythrocyte parameters would mean that the aqueous extract of the leaves of *Ocimum gratissimum* would have no harmful effect. These results are consistent with those of Kiki [24]. According to this author, the incorporation of chilli powder in chicken feed did not show any adverse effect on hematological parameters. The levels of white blood cells, lymphocytes, neutrophils and basophils of the treated batch are significantly higher ($p < 0.05$) than those of the control batch. With regard to white blood cells and lymphocytes, their increase could be explained by the presence of immunostimulatory compounds contained in the extract. Indeed, flavonoids and polyphenols strengthen the immune system due to their antioxidant properties [25]. On the other hand, these results could also be explained by the stimulation of the immune system in the presence of a possible infection that occurred in the chickens treated during this study. Indeed, according to Soetan et al. [26], the main functions of white blood cells and their differentials are to fight against infections, to defend the body against the invasion of foreign organisms. These results are contrary to those of Kiki [24]. Indeed, he observed a decrease in the number of white blood cells in chickens treated with pepper powder (*Capsicum frutescens*). This difference would be related to the broiler breed used for this study. At the level of neutrophils, the results showed a significant increase ($p < 0.05$) in chickens treated with EAOG compared to chickens treated with antibiotics. This increase in neutrophil levels in chickens treated with EAOG could indicate that this extract contains antibacterial molecules. Indeed, neutrophils are phagocytic cells that play an important role in antimicrobial control and in acute inflammation. These results are supported by Morabandza et al. [27] who showed a significant increase in neutrophil counts in Wistar strain rats treated with aqueous extract of *Garcinia kola*. Regarding the level of basophils, the results also indicated a significant increase in the treated batch compared to the control. These results show that the aqueous extract of the leaves of *Ocimum gratissimum* would contain molecules which would have activated the basophils which would promote blood flow to the tissues.

4. CONCLUSION

The phytochemical study showed that the aqueous extract of the leaves of *Ocimum gratissimum* L. (EAOG) contains sterols and polyterpenes, polyphenols, flavonoids,

alkaloids, saponosides and catechin tannins. The acute toxicity study of this plant revealed no signs of toxicity. The lethal dose 50 was therefore estimated to be greater than 2,000 mg/kg B.W. Thus, the aqueous extract of *Ocimumgratissimum L.* would be non-toxic orally in a single dose at a dose of. 2000 mg/kg B.W. This extract showed no adverse effects on vital organs during prophylaxis. In addition, it would have immuno-stimulatory and protective effects on the kidney and liver. In view of these results, the aqueous extract of *Ocimumgratissimum L.* could be an alternative to the use of antibiotics in poultry farming. The results obtained are satisfactory and open up many research perspectives.

Disclosure of conflict of interest

All authors have seen and approved the manuscript as submitted. All authors participated in the work in a substantive way and are prepared to take public responsibility for the work. All authors of the manuscript have no conflict of interests to declare. The manuscript submitted to the journal is not copied or plagiarized version of some other published work. All the data taken from other sources is written in authors own language and properly cited. The text, illustrations, and any other materials included in the manuscript do not infringe upon any existing copyright or other rights of anyone.

Statement of ethical approval

The animal material used for this study, were used according to the Organisation for Economic Co-operation and Development (OECD) guideline 423.

REFERENCES

- [1]Barbut, 2002. Poultry product processing. Editions *Chemical Rubber Company PRESS*. USA, 539 p.
- [2] Dosso S., 2014. Analysis of poultry practices and the use of antibiotics in poultry farming modern in the department of Agnibilékrou (Ivory Coast). Veterinary medicine thesis of the Cheikh Anta Diop University of Dakar (Senegal), 152p.
- [3] Coffman J., 1999. The use of drugs in food animals: benefits and risks. CAB International. E. coli." *Journal of Genetics Microbiology*, 130(6): 1325-1330

- [4] El Boujnouni A., 2020. History of bacterial resistance to antibiotics. Thesis dissertation, Mohammed V University of Rabat, Faculty of Medicine and Pharmacy Rabat, Morocco, 142p.
- [5] Corpet D. & Brugere H., 1996. Residues of antibiotics in foods of animal origin: microbiological consequences, assessment of the no-effect dose in humans. *Journal of Veterinary Medicine*, 146, 72-82.
- [6] Dagnogo K., Coulibaly A., Kaba S., Allo V., Dongo A.C., Soro K., Biege G.M., Datte J. & Dembelé A., 2018. Determination of the level of contamination and the intake of tylosin residues (macrolides) from eggs for consumption in the District of Abidjan (Côte d'Ivoire). Félix Houphouët-Boigny University, Abidjan, Ivory Coast. *Journal of Applied Biosciences*, 129: 13067–13074.
- [7] Guessenn N., Konan F., Beudje F, Tiékoura B., Ouattara D., Kouadio J., N, & Dosso M., 2012. Antibiotic susceptibility of *Escherichia coli* strains isolated from stool diarrhea in piglets in Ivory Coast. *BioAfrica Review*, 10.47-57.
- [8] Hernandez F., Madrid J., Garcia V., Orengo J. & Megias M.D., 2004. Influence of two plant ex-tracts on broiler performance, digestibility, and digestive organ size *Poultry Sciences*, 83:169-174
- [9] Chen Y.H., Tsai F.L., Lee H.H. & Liu J.Y., 2014. Dietary supplementation of *Ocimum gratissimum* improves immune response without affecting growth performance and blood characteristics in Taiwan country chicken. *Japan Poultry Science Association*, 51: 313-320.
- [10] Yapo C.V.Y., Konkani D.G., Coulibaly K., Camara D & Zirihi G.N., 2016. Botanical study, evaluation of antifungal activity on in vitro growth of *Candida albicans* and toxicity on HFF cells of *Mallotus oppositifolius* (Geiseler) Müller.Arg (Euphorbiaceae) leaves. *Journal of Animal & Plant Sciences*, 28(1): 4330-4339.
- [11] Békro Y.A., Békro J.A.M., Boua B., Trabi F.H & Ehouan E., 2007. Ethnobotanical study and phytochemical screening of *Caesalpinia benthamiana* (Caesalpinaceae). *Science and Nature*, 4(2): 217-225.

[12] Organization for Economic Co-operation and Development (OECD 423), 2001. OECD Guideline for the Testing of Chemicals: Acute Oral Toxicity. Method by class of acute toxicity. OECD Publishing: 14 p.

[13] Piba S.C., Konan A.K., Koné L.N., Kouamé G., Kouakou R.K. & Tra H.F., 2021. Phytochemistry, antioxidant activity and acute toxicity of medicinal plants used against the sequelae of stroke in Côte d'Ivoire. *Journal of Biological and Chemical Sciences*. 15 (2): 652-663.

[14] Cardenas D.J., 2017. Basil (*Ocimum gratissimum*). www.Doctissimo.fr, consulted on November 23, 2021.

[15] Atapattu N.S. & Belpagodagamage, U.D., 2010. Effect of dietary chili powder on growth performance and serum cholesterol contents of broiler chicken. *Tropical Agricultural Research and Extension*, 13(4):106-109.

[16] Kouakou S.K., Toure A., Ouattara K. & N'guessan J.D., 2010. In vivo anticoccidial activity of the aqueous extract of *Thonningiasanguinea* (Balanophoraceae) inflorescences in laying hens. *Original Paper* 4(4): 864-870.

[17] Sagna R.F., 2010. Test of substituting groundnut cake with neem cake (*azadirachta indica*) on live and carcass performance of broiler chickens. Master's thesis, Cheikh Anta Diop University of Dakar (UCAD), Senegal, 75p.

[18] Chan S.L., Tabellion A., Bagrel D., Perrin-Sarrado C., Capdeville-Atkinson C. & Atkinson J., 2008. Impact of chronic treatment with red wine polyphenols (RWP) on cerebral arterioles in the spontaneous hypertensive rats. *Journal of Cardiovascular Pharmacology*, 51(3): 304-310.

[19] Souahibou S.S., 2014. Zoo technical and economic performance of broiler chickens (Cobb500) fed rations based on flour from the seeds of the green variety of bissap (*hibiscus sabdariffa*, linn). Doctoral thesis, Cheickh Anta Diop University of Dakar, Senegal, 140p.

[20] Gnonlonfoun M.G., 2017. Effects of ginger powder (*Zingiber officinale* Roscoe) on biochemical parameters in Ross 308 broilers with colibacillosis, License dissertation, University of Abomey-Calavi, Benin, 67p.

- [21] Maxwell M.H., 1990. Hematological and histopathological findings in young broilers reared in poorly and well-ventilated environments. *Research in Veterinary Sciences*, 48: 374-376.
- [22] Lin W. & Jian-Guo J., 2018. Protective effects of plant-derived flavonoids on hepatic injury, *Journal of Functional Foods*, 44: 284-291.
- [23] Dotou G., 2016. Healing effect of exethanolic trait of *Tridax procumbens* on the biochemical parameters in the ISA Brown cockerel infected with Gumboro disease, License dissertation, University of Abomey-Calavi, Benin, 69p.
- [24] Kiki S.P., 2013. Effects of chilli powder (*Capsicum frutescens*) on zootechnical, hematological, biochemical and carcass parameters of the Hubbard broiler chicken. Master's thesis, University of abomey-calavi, Benin, 79p.
- [25] Manach C., Regeat F., Texier O., Agullo G., Demigne C., & Remesy C., 1996. Bioavailability, metabolism and physiological impact of 4-Oxo-flavonoids. *Nutrition Research*, 16: 517-544.
- [26] Soetan, K. O., Akinrinde, A. S., & Ajibade, T. O. 2013. Preliminary studies on the haematological parameters of cockerels fed raw and processed guinea corn (*Sorghum bicolor*. Proceedings of 38th Annual Conference of Nigerian Society for Animal Production. Pp. 49 - 52
- [27] Morabandza C.J., Gombe A.H, Agbonon A. & Abena A.A., 2021. Impact of the aqueous extract of the mesocarp of the fruit of *Garcinia kola* Haeckel (Clusiaceae) on immunity and blood antioxidant potential in thermo-Wistar rats. stress. *Journal of animal and plant sciences*, 47(2): 8433-8444.