

Case study

Association of a bennet and trapezius fracture : case report

Abstract :

The association of Bennet fracture and fracture of the trapizius are rare, the authors report a case of 56 years old male after a slip, who were treated by percutaneous pinning according to Iselin technique. Functional outcomes were satisfying after 1year follow-up.

Introduction :

The trapezium fracture is a rare injury and represents 3% of carpal fractures (1); it can be isolated or associated with other injuries, the most common being Bennett's fracture (2). The trapeziometacarpal joint is a complex joint due to its high degree of mobility, and the mechanism is often combined. Careful analysis of the radiograph is fundamental to not miss any trapezium lesions that may lead to rhizarthrosis. Through an observation of a patient presenting with a trapezium fracture associated with a Bennett's fracture and a literature review, we will discuss the diagnostic and therapeutic particularities of this exceptional injury association.

Case Presentation :

A 56-year-old patient presented to the emergency department with a closed trauma to the right wrist following a slip with the reception point being the palm of the right hand in dorsiflexion. Clinical examination revealed pain and total functional impotence with edema of the thenar compartment without downstream vascular or neurological disorders. A wrist X-ray (fig 1) showed an intra-articular vertical fracture of the trapezium associated with a Bennett's fracture with internal displacement of the articular fragment but without dislocation of the first metacarpal bone. A CT scan was requested (fig 2), which did not show any associated dislocation or lesion.

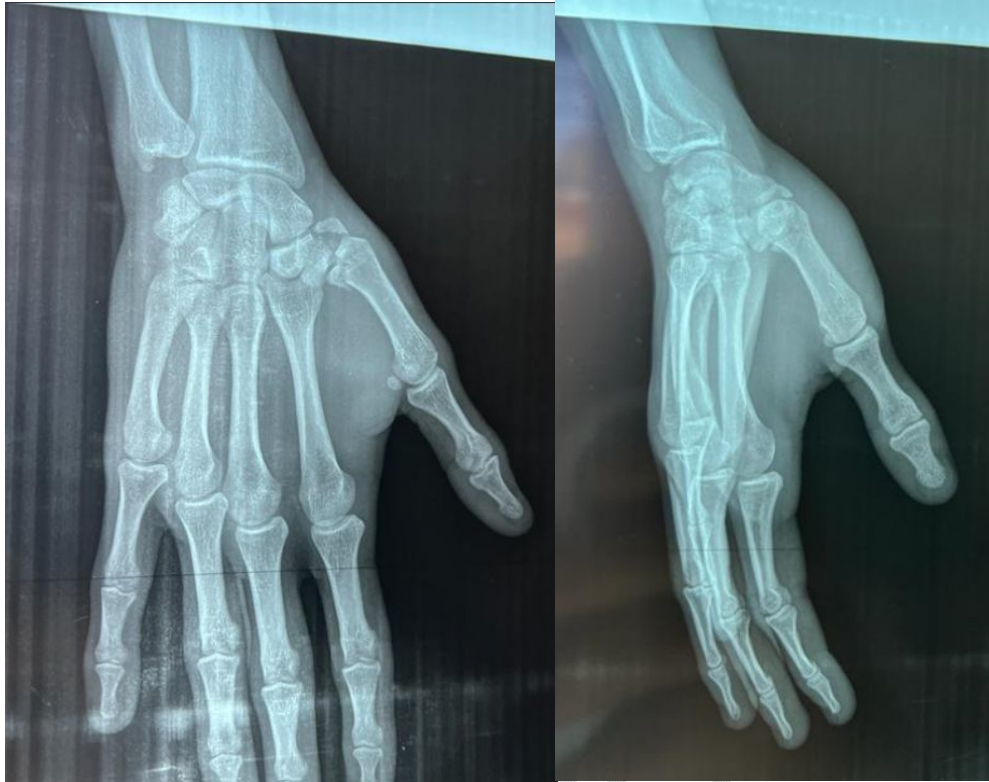

Fig 1: Trapezium fracture associated with a Bennett's fracture

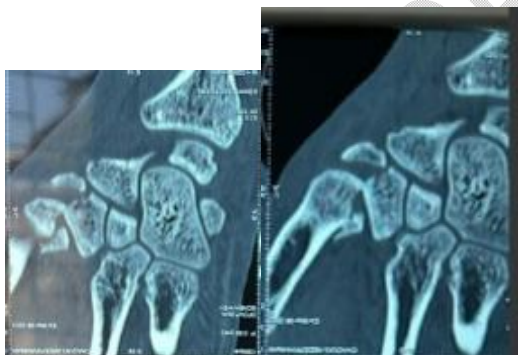


Fig 2: CT scan image showing a trapezium fracture associated with a Bennett's fracture.

The patient underwent surgical treatment under local-regional anesthesia. Reduction was performed by closed external manipulation under fluoroscopic control. Osteosynthesis by pinning according to the Iselin technique was performed, with spontaneous anatomical reduction of the trapezium fracture. Postoperative immobilization with a commissural plaster splint was carried out for six weeks, followed by a wrist and hand rehabilitation protocol.

The patient had a favorable outcome after a one-year follow-up, with consolidation of the fractures and functional recovery.

DISCUSSION

The trapezium fracture is a rare injury, accounting for only 3% of all carpal fractures (3). It is associated with the Bennett fracture in 15% of cases (4).

There are two theories regarding the pathogenesis of trapezium fractures. According to Manon's theory, a fall on the hand in dorsal flexion and radial inclination causes the radial styloid to wedge into the trapezium, combined with tearing by the trapezoid ligament. Monsche's theory talks about a commissural shear that results in trapezium fracture, trapeziometacarpal dislocation, or first metacarpal base fracture depending on the application point (5).

Radiography confirms the diagnosis, but the overlap of the trapezium with the trapezoid does not always allow the fracture to be visualized on frontal and profile incidences. The Robert incidence, performed with the hand in pronation, shows the body of the trapezium. CT scan allows for further evaluation in difficult cases.

Orthopedic treatment with plaster immobilization with thumb in opposition gives good results for isolated and non-displaced trapezium fractures (6). This treatment is not indicated in the case of association with a Bennett fracture.

Reduction of these fractures should be anatomical due to their articular nature, and it can be done by open or closed reduction. For fractures with large fragments, osteosynthesis can be done using thin Kirschner wires or Herbert screws (7). Osteosynthesis with screws should be preferred. Trapezectomy may be considered in comminuted fractures (7), and non-anatomical reduction exposes to complications, including rhizarthrosis.

Bennett fracture requires closed reduction osteosynthesis by percutaneous pinning, and several techniques are proposed. Islin's technique is the most commonly used, and open reduction and internal fixation allow for the reduction of the articular surfaces.

CONCLUSION :

The association of ipsilateral trapezium and Bennett fractures is rare, and the diagnosis may be incorrect, which highlights the importance of specific radiological incidences and complementary CT scan. Adequate treatment can prevent complications, mainly represented by rhizarthrosis.

References :

- 1- Razemon JP. Carpal bone fractures. In: Tubiana R, editor.
- 2- Simultaneous trapezius and Bennett fractures: about a case
- 3 - BENNETT'S FRACTURE COMBINED WITH FRA TRAPEZIUM A report of three cases

4- Sharp, J. (1988). Fracture of the trapezium: Mechanism, pathology and indications for treatment. Fr. J. Orthop Surg., 3, 380-391

5- Simultaneous trapezius and Bennett fractures: about a case and review of the literature

6-McGuigan FX. Simultaneous trapezium and Bennett's fractures. Comment J Hand Surg 1993; 18A: 944

7- Pointu J et al. Trapezius fractures: mechanism, anatomo-pathology and therapeutic indications. Rev. Chir Orthop 1988; 5: 454-65

UNDER PEER REVIEW