

An Incidental Finding of Double Cystic Ducts during Laparoscopic Cholecystectomy: A Case Report

ABSTRACT

Introduction: Abnormal anatomy of the biliary duct are common, and failure to recognize them may lead to complications during operative or endoscopic procedures. The diagnosis is usually established during surgery

Presentation of the Case: we have reported the case of a 46-year-old patient with a history of epilepsy and psychosis under treatment, presenting upper right abdominal pain, admitted at an academic medical center, with the intra operative discovery of a duplicated biliary duct, the accessory cystic duct was anterior the primary cystic duct and drained in the common biliary duct, both cystic ducts were clipped, and no complications occurred during or after the laparoscopic cholecystectomy.

Discussion: Double gall bladders with double cystic ducts are not an uncommon occurrence, however a double cystic duct with a sing gall bladder is a an extremely rare biliary duct abnormality, several authors reported the need to rely on per operative cholangiography to mitigate the risk of biliary injury.

Conclusion: Surgeons must be aware of the different biliary duct abnormalities to minimize the risk for the patients.

Keywords: Cystic duct duplication; laparoscopic cholecystectomy; biliary duct abnormality.

1. INTRODUCTION

Biliary duct abnormalities are not uncommon to come across during laparoscopic cholecystectomy, they, however, predispose patients to higher risk of ductal injury and post operative complications. Cystic duct duplication with a single gall bladder is on the other hand an extremely rare biliary duct abnormality. We describe in this article the case of a patient admitted to an academic public medical center [1].

2. PRESENTATION OF THE CASE

A 46 years old patient, with a history of epilepsy treated by Phenobarbital, and psychosis treated by Haloperidol, and having no prior history of abdominal surgery, reporting a right upper colicky pain evolving for 6 months, without any cholestasis symptoms, no fever or chills, and no

weight loss. The patient has been received in consultation, the physical examination of the patient revealed an anicteric patient, with a soft abdomen. Pre operative ultrasound showed multiple gall stones, with a non dilated intra hepatic and extrahepatic biliary duct systems. Pre operative liver function tests were in the normal range.

After dissection of the calot triangle, an accessory cystic duct was discovered (Figs.1,2), it was anterior to the main cystic duct and the cystic artery, and draining into the common biliary duct. Both cystic ducts were clipped and then sectioned, the artery was then clipped and sectioned and the cholecystectomy performed normally.

The post operative course was uneventful, and the patient was discharged the following day of the surgery.

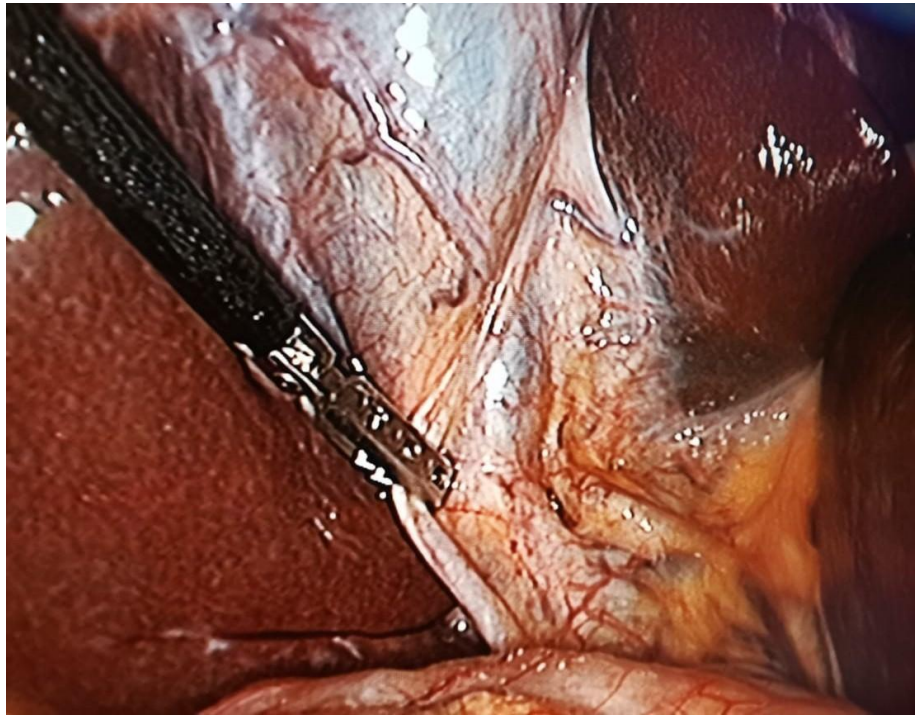


Fig. 1. Laparoscopic image of the duplicated cystic duct

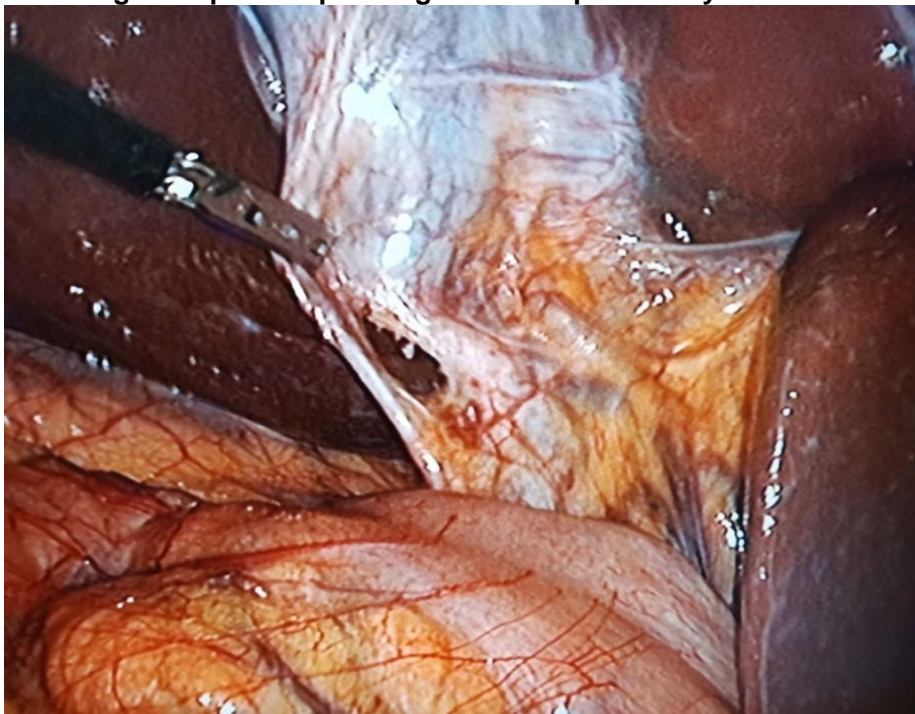


Fig. 2. After dissection between the two cystic ducts

3. DISCUSSION

“Developmental abnormalities during embryogenesis may lead to extra hepatic biliary tract abnormalities, with reported incidences varying between 7.3 and 47%” [2,3]. Double gall bladders with double cystic ducts are not an

uncommon occurrence, however a double cystic duct with a single gall bladder is an extremely rare biliary duct abnormality [4]. Flannery and Caster [5] have categorized this anomaly into three types. A « Y » type where the two cystic ducts join to form a single canal that drains in the common biliary duct, a « H » type where the

accessory cystic duct enters separately either in the right, left, or common hepatic duct, it is the most described variation in literature [6,7].

In our case the patient had the « H » variation with cystic duct draining directly in the common hepatic duct. The third configuration is called the trabecular type, where the accessory cystic duct enters the substance of the liver directly, forming a cholecystohepatic duct.

“Other biliary variations may give the appearance of a double duct draining the gall bladder were described by Blumgart and Hann” [8]: Drainage of the segment VI into the cystic duct, Drainage of the right posterior sector duct into the cystic duct, Drainage of the distal part of the right posterior sector duct into the neck of the gallbladder. Drainage of the proximal part of the right posterior sector duct into the body of the gall bladder.

“However, biliary variations do not appear to have a correlation with stone formation” [9].

4. CONCLUSION

Double cystic duct is a rare anomaly, and with more than 500 000 laparoscopic performed annually in the united states [10], surgeons must be aware of the many possible anatomic variations to minimize the risk of complications.

CONSENT

As per international standard or university standard, patient(s) written consent has been collected and preserved by the author(s).

ETHICAL APPROVAL

As per international standard or university standard written ethical approval has been collected and preserved by the author(s).

COMPETING INTERESTS

Authors have declared that no competing interests exist.

REFERENCES

1. Agha RA, Franchi T, Sohrab C, Mathew G, Kirwan A, Thomas A, et al. The SCARE 2020 guideline: Updating consensus Surgical Case Report (SCARE) guidelines. *International Journal of Surgery*. 2020; 84(1):226-30.
2. H. P. Klotz, R. Schlumpf, F. Largiader, Injury to an accessory bile duct during laparoscopic cholecystectomy, *Surg. Laparosc. Endosc.* 1992;2:317–337.
3. Khayat MF, Al-Amoodi MS, Aldaqal SM, Sibiany A. Abnormal anatomical variations of extra- hepatic biliary tract, and their relation to biliary tract injuries and stones formation, *Gastroenterology Res.* 2014;7: 12–18. Available:<http://dx.doi.org/10.14740/gr596e>
4. Senapati A, Wolfe JHN. Accessory cystic duct - An operative hazard. *Journal of the Royal Society of Medicine.* 1984;77(10): 845–846. Available:<https://doi.org/10.1177/014107688407701009>
5. Flannery MG, Caster MP. Congenital abnormalities of gall bladder: 101 cases, *Int Abstr Surg.* 1956;103:439–457. DOI: 10.12659/AJCR.905963
6. Tsutsumi S, Hosouchi Y, Shimura T. Double cystic duct detected by endoscopic retrograde cholangiopancreatography and confirmed by intraoperative cholangiography in laparoscopic cholecystectomy. *Hepatogastroenterology.* 2000;47:1266–1268.
7. Hirono Y, Takia Y, Nitta N, Hashimoto H. Double cystic duct found by intraoperative cholangiography in laparoscopic cholecystectomy, *Surg Laparosc Endosc.* 1997;7:263–265.
8. Blumgart LH, Hann LE. *Surgical and Radiological anatomy of the liver and the biliary tract*, W B Saunders, London; 2000. Available:<https://doi.org/10.1016/B978-1-4377-1454-8.00107-7>
9. Ong WM, Cheng Y. Intraoperative diagnosis of a duplicated cystic duct. *ANZ Journal of Surgery.* 2019;89:E464-E465. Available:<https://doi.org/10.1111/ans.14763>
10. Huston TL, Dakin GF. Double cystic duct. *Can J Surg.* 2008;51(1):9-10.