

INVASIVE DUCTAL CARCINOMA IN NIPPLE AREOLA COMPLEX PRESENTING AS NIPPLE ULCER: A CASE REPORT

ABSTRACT:

INTRODUCTION:

Invasive breast cancer, deriving from lactiferous duct and lobule which progresses in the nipple is a rare entity but exceptionally seen in Paget's disease and skin carcinoma. Invasive ductal carcinoma (IDC), also known as infiltrating ductal carcinoma, is one of the most common types of Ca Breast. American Cancer Society states that about 75% of all Ca Breast are IDC. The cancer which has spread to the surrounding breast tissues will be termed as invasive. Lactiferous ducts carry milk from lobule to nipple and carcinoma here will be known as ductal carcinoma.

CASE PRESENTATION:

42 year old female present with complaint of ulcer over upper outer quadrant of the left breast and nipple areola complex 6 month back.

DISCUSSION:

Invasive breast cancer, deriving from lactiferous duct and lobule which progresses in the nipple is a rare entity but exceptionally seen in Paget's disease and skin carcinoma.

CONCLUSION:

Invasive ductal carcinoma with skin ulcer without paget's disease is very rare. This can be diagnosed by tissue biopsy, mammography and histopathological examination.

Key words: invasive ductal cancer ;MRM

INTRODUCTION:

Invasive ductal carcinoma (IDC)/infiltrating ductal carcinoma is most common type of breast cancer. Almost 75% of all breast cancers are Invasive Ductal cancers as stated by the American Cancer Society. Carcinoma which spreads into surrounding breast tissue is Invasive. Ductal carcinoma involves the lactiferous ducts. The American Cancer Society estimates about 287,860 new cases of Invasive Ca Breast to be diagnosed in women in 2022, mostly IDC.

Risk factors include (1) Modifiable risk factors: Parity: Nulliparous women or 1st pregnancy after 35 years, Late age at 1st pregnancy, obesity: BMI >30, >10 years use HRT, Radiation exposure (2) Non modifiable risk factors: Ethnicity: White American, African American, Family h/o breast cancer: 1st degree relative (mother, sister, daughter), Genetics: BRCA1 and BRCA2 mutations, Sex: Female, Early menarche which is <12 years, Late menopause which is >55 years, High lipid diet, Breast disorders which are benign (epitheliosis).

Patient c/o swelling of all/part of breast, irritation of skin, skin dimpling, orange peel breast or nipple, nipple retraction, discharge from nipple, scaliness/thickening of the nipple/breast skin, swelling or lump under arm. Paget's disease of the breast is one of the rare form of breast cancer. It starts on the nipple and extends to areola. Paget's disease of the breast is not related to Paget's disease of bone which is a metabolic bone disease. Most often after 50 years of age Paget's disease of breast is seen. Most of the patients also have an underlying ductal breast carcinoma, either in-situ (in its original place) or invasive. Paget's disease of the breast confined only to the nipple is rare. Paget's disease of the breast may mimic some of the non-cancerous conditions like eczema or dermatitis causing tingling/itching/redness in the nipple or areola, flaky/crusty/thickened skin on or around the nipple, flat nipple, bloody or a yellowish nipple discharge are the symptoms of Paget's disease that are similar to eczema and some common skin infections. So Paget's disease is easily misdiagnosed.

PATIENT PRESENTATION:

A 42-year-old Hindu married female presented with a complaint of an ulcer over the left breast and nipple areola complex 6 months back for which the patient took oral antibiotics and the ulcer healed in 4 days. Again after 14 days the patient developed an ulcer at the same site. The patient has taken oral antibiotics but the ulcer has not healed. True-cut biopsy is s/o invasive ductal carcinoma. The patient had taken 8 cycles of chemotherapy: Adriamycin + Cyclophosphamide + Taxel. After which left breast Modified Radical Mastectomy has been done.

CLINICAL FINDINGS:

The patient was vitally stable.

Local examination: Approx 1x1cm² healed scar present over the upper outer quadrant left breast and nipple areola complex.

INVESTIGATIONS:

All routine blood investigations were done and found to be normal.

Investigation done before chemotherapy

Mammography: s/o changes of fibroadenosis in both breasts, marked vascularity seen involving left nipple at the site of ulcer, BIRADS category IV.

Tissue biopsy: s/o invasive ductal carcinoma.

Ct head, neck, thorax, abdomen and pelvis: s/o left nipple areolar skin depression, however no evidence of any definitive enhancing mass lesion seen.

Immunohistochemistry: s/o ER(EP1):negative, PR(EP2):negative, Her2(EP3):Positive(3+).
Investigation done after MRM

Histopath: s/o invasive ductal carcinoma

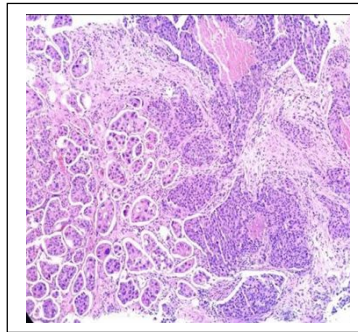
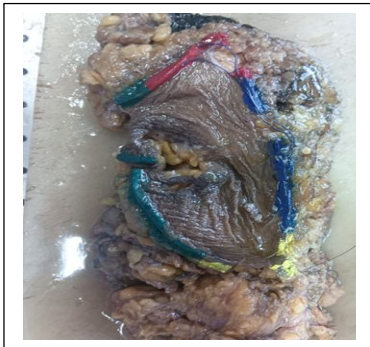


Fig. 1. Investigation done before chemotherapy

Immunohistochemistry: s/o ER(EP1):negative, PR(EP2):negative, Her2(EP3):Positive(3+).

THERAPEUTIC INTERVENTION:

Patient has taken 8 cycles of Neoadjuvant chemotherapy (adriamycin+cyclophosphamide+taxel) after which modified radical mastectomy was done.

DISCUSSION:

Invasive breast carcinoma deriving from lactiferous duct and lobule in the nipple is a rare entity, except in Paget's disease and skin carcinoma. Mostly breast cancers develop from the terminal duct lobular units and rarely in the nipple. Tumor grade, stage, and stage, tumor-nipple distance, HER2 positivity were significant predictors of occult nipple involvement in Ca breast. Tumor location has an influence on the involvement of nipple. Central or retroareolar tumors have higher nipple recurrence compared to other 4 breast quadrants. So, breast conserving surgical procedures shouldn't solely be based on tumor location, also size, stage, IHC and HER2 status of carcinoma should be taken into consideration. As of now there aren't any established criteria that would classify local recurrences within the breast as true or secondary cancers (metachronal ipsilateral breast cancers). As an add-on, increase in the no. of nipple-sparing mastectomies prophylactically in hereditary breast and ovarian cancer syndrome surveillance is conducted routinely. Several nipple sparing surgeries like hollowing out mammary gland in the nipple, have been shown. It's important to educate the patients to visit an available medical organization immediately when they feel a nipple swelling/redness/pigmentation/exudative crust/itchiness. Nipple's Paget's disease starts always in the nipple that might extend to areola, appears as a reddish, scaly rash on the nipple and areola. There's an inflamed and sore skin which can also be itchy or might cause a burning sensation. Sometimes an ulcerated nipple could also be found.

CONCLUSION:

Invasive Carcinoma of the Breast from the lactiferous duct and lobule in the nipple is extremely rare, but could be seen in Paget's disease and carcinoma of the skin. Majority of Ca Breast develops from the lobular units of terminal duct and rarely in the nipple, as it is far from the lobules. Invasive ductal carcinoma with skin ulcer without paget's disease is very rare. This can be diagnosed by tissue biopsy, mammography, histopathology.

CONSENT:

Consent has been taken from the patients.

Ethical Approval:

As per international standard or university standard written ethical approval has been collected and preserved by the author(s).

CONFLICT OF INTEREST:

There are no conflict of interests to be declared.

FUNDING:

None.

AUTHOR'S CONTRIBUTION :

All authors contributed equally in treatment, management and follow-up of the patient and in compilation of the case report.

REFERENCES:

1. Congdon GH, Dockerty MB. Malignant lesions of the nipple exclusive of Paget's disease. Surg Gynecol Obstet. 1956;103(2):185-92.
2. Sanders MA, Brock JE, Harrison BT, Wieczorek TJ, Hong X, Guidi AJ, et al. Nipple-invasive primary carcinomas: clinical, imaging, and pathologic features of breast carcinomas originating in the nipple. Arch Pathol Lab Med. 2018 May;142(5):598-605.
3. Kryvenko ON, Yoon JY, Chitale DA, Lee MW. Prevalence of terminal duct lobular units and frequency of neoplastic involvement of the nipple in mastectomy. Arch Pathol Lab Med. 2013 Jul;137(7):955-60.

- 4 Fisher B, Anderson S, Redmond CK, Wolmark N, Wickerham DL, Cronin WM. Reanalysis and results after 12 years of follow-up in a randomized clinical trial comparing total mastectomy with lumpectomy with or without irradiation in the treatment of breast cancer. *N Engl J Med.* 1995;333(22):1456–61.
- 5 Edge SB. Nipple-sparing mastectomy: how often is the nipple involved?. *J Clin Oncol.* 2009;27(30):4930–2.
- 6 Shahrin Niza AS, Rohaizak M, Naqiyah I, Srijit D, Noraidah M. Isolated ipsilateral nipple recurrence: important lessons to learn. *Malays J Med Sci.* 2011;18(2):82–4.
- 7 Srivastava A, Webster DJ. Isolated nipple recurrence seventeen years after subcutaneous mastectomy for breast cancer – a case report. *Eur J Surg Oncol.* 1987;13(5):459–61.
- 8 Laronga C, Kemp B, Johnston D, Robb GL, Singletary SE. The incidence of occult nipple-areola complex involvement in breast cancer patients receiving a skin-sparing mastectomy. *Ann Surg Oncol.* 1999;6(6):609–13.
- 9 Lambert PA, Kolm P, Perry RR. Parameters that predict nipple involvement in breast cancer. *J Am Coll Surg.* 2000;191(4):354–9.
- 10 Simmons RM, Brennan M, Christos P, King V, Osborne M. Analysis of nipple/areolar involvement with mastectomy: can the areola be preserved?. *Ann Surg Oncol.* 2002;9(2):165–8.
- 11 Yoshida T, Takei H, Kurosumi M, Ninomiya J, Ishikawa Y, Hayashi Y, et al. True recurrences and new primary tumors have different clinical features in invasive breast cancer patients with ipsilateral breast tumor relapse after breast-conserving treatment. *Breast J.* 2009;16(2):127–33.
- 12 Sakai T, Nishimura S, Ogiya A, Tanabe M, Kimura K, Morizono H, et al. Four types of ipsilateral breast tumor recurrence (IBTR) after breast-conserving surgery: classification of IBTR based on precise pathological examination. *Pathol Int.* 2015;65(3):113–8.
- 13 Hartmann LC, Schaid DJ, Woods JE, Crotty TP, Myers JL, Arnold PG, et al. Efficacy of bilateral prophylactic mastectomy in women with a family history of breast cancer. *N Engl J Med.* 1999;340(2):77–84.
- 14 Sacchini V, Pinotti JA, Barros AC, Luini A, Pluchinotta A, Pinotti M, et al. Nipple-sparing mastectomy for breast cancer and risk reduction: oncologic or technical problem? *J Am Coll Surg.* 2006;203(5):704–14.
- 15 Murthy V, Chamberlain RS. Defining a place for nipple sparing mastectomy in modern breast care: an evidence based review. *Breast J.* 2013 Nov;19(6):571–81

