

***Original Research Article***

***SERRATIA MARECESENS meningitis complicated by ventriculitis: about a neonatal case***

**ABSTRACT:**

*Serratia marcescens* (italics) belongs to the Enterobacteriaceae family, commonly found in water, soil, animals, insects, plants. Although *S. marcescens* displays relatively low virulence, it causes nosocomial infections and outbreaks in severely immunocompromised or critically ill patients, especially in settings such as intensive care units, especially neonatal units. This microorganism gives rise to a wide range of clinical manifestations in neonates: from asymptomatic colonization to keratitis, conjunctivitis, urinary tract infections, pneumonia, surgical wound infections, sepsis, bloodstream infection and meningitis. The most common site of infection is the bloodstream, followed by the respiratory tract and the gastrointestinal tract. *Serratia marcescens* strains implicated in epidemic events have often proven to be multiresistant. Indeed, this species displays an intrinsic resistance to several classes of antibiotics. Often, the precise source of infection cannot be identified. However, the contaminated hands of healthcare workers are considered a major vehicle for its transmission. Infection of the central nervous system by this bacterium in the neonatal period leads to serious neurological sequelae with high mortality interest of early and adequate management. Through our work we report the clinical presentation, the positive diagnosis as well as the therapeutic management and the evolution of a newborn having presented a meningitis with *Serratia marcescens* complicated by ventriculitis.

**KEY WORDS:**

Newborn, neonatal intensive care unit, epidemic, meningitis, *Serratia marcescens*, ventriculitis, external bypass, antibiotic therapy.

**INTRODUCTION:**

*Serratia marcescens* is a widespread microorganism in the environment, but is not a common component of human faecal flora. Most infections are exogenously acquired and spread within and between hospitals. [1] Manual transmission seems to be the main mechanism of nosocomial spread. Environmental sources in hospitals were found to include suction taps, colonized disinfectants or soap, and insufficiently sterilized breast pumps and respirators. Illness in humans has been associated with infection of the urinary tract, respiratory tract, local wounds, and central venous catheters. Colonization in neonatal units has been associated with a tenfold increase in the rate of *Serratia marcescens* bacteraemia and meningitis. In neonates, the major risk factors for *Serratia* infection are immaturity of the immune system and low birth weight (<1500 g) in preterm neonates, length of stay, and use of antibiotics, especially if they are general antibiotics and administered empirically.

**OBJECTIVE:**

Report the medical observation of a newborn hospitalized in the neonatal intensive care unit university hospital center MOHAMMED VI MARRAKECH who presented with *serratia marcescens* meningitis complicated by ventriculitis following sepsis during the epidemic occurring in our department in February 2023.

**MEDICAL OBSERVATION:**

Newborn female hospitalized in our training since birth for neonatal respiratory distress on premature 34 weeks of amenorrhea and 2 days according to first trimester ultrasound, from a first-degree related marriage. **Check composition**

The newborn was initially hospitalized for neonatal pulmonary infection complicated by nosocomial infection with *Serratia Marcescens* treated with good evolution, on the thirty-eighth day of her hospitalization the patient presented manifest hypotonia, fever at 40 degrees with a positive infectious balance sheet made blood count objectifying white blood cells To 15200/mm<sup>3</sup>, polymorphonuclear neutrophils To 10890/mm<sup>3</sup>, pads To 154,000/mm<sup>3</sup> and a C-reactive protein To 111.49mg/l. **check composition**

A lumbar puncture made **objectified** a greenish purulent macroscopic appearance with leukocytes at 2080/mm<sup>3</sup>, red blood cells at 160/mm<sup>3</sup>, direct examination **objectified** the presence of a gram-negative bacillus, and culture isolated *Serratia marcescens* multiresistant, **proteinorachia** at 7.093g/l, **glucorachy** at 0.013g/l. **check composition**

Trans-fontanelar ultrasound revealed moderate tetraventricular hydrocephalus with signs of ventriculitis. [FIGURE 1, FIGURE 2].

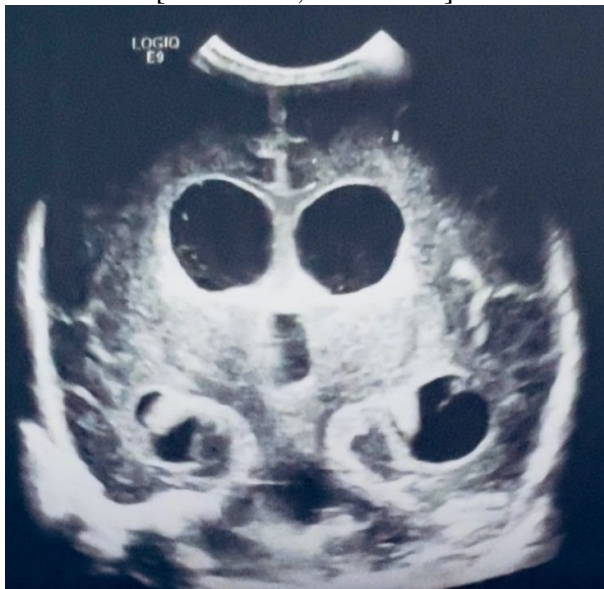

FIGURE 1: **TRANSFONTANELLAR ULTRASOUND CORONAL SECTION**

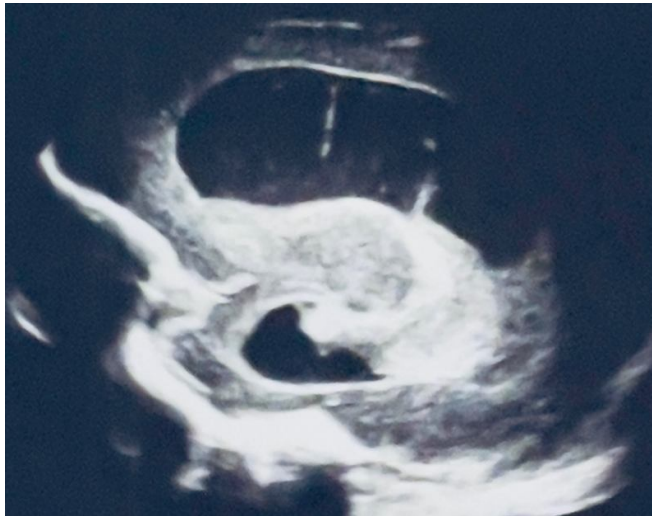

FIGURE 2: TRANSFONTANELLAR ULTRASOUND SAGITAL SECTION

A cerebral computed tomography showed active major tetra-ventricular hydrocephalus associated with ventriculitis. [FIGURE 3].

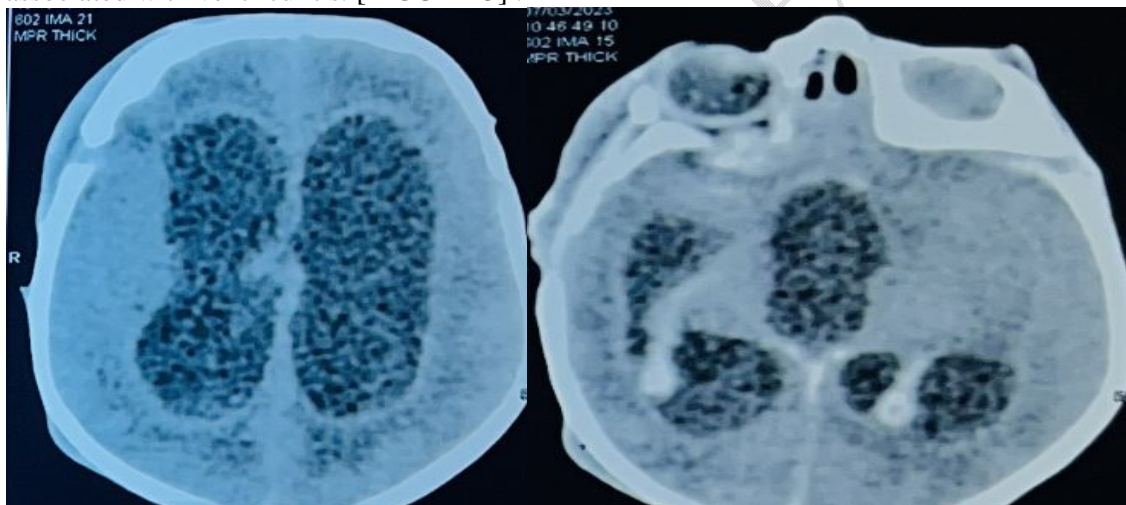


FIGURE 3: BRAIN SCANNER

The patient was put on meropenem and amikacin, then on ciprofloxacin. (dose/duration/frequency and reason for shifting)

Faced with proteinorachia?? at 8.07 g/l, an external bypass was performed in our patient by the neurosurgery team.

After 10 days of ciprofloxacin, a control lumbar puncture was performed showing a macroscopic xanthochromic appearance, leukocytes at 400/mm<sup>3</sup>, red blood cells at 320/mm<sup>3</sup>, direct examination did not object any germ and the culture was sterile, the proteinorachia at 0.76g/l and glucorachia at 0.13g/l

In view of the good clinical and biological improvement, removal of the drain was indicated with the continuation of ciprofloxacin for 8 weeks.

A control trans-fontanelar ultrasound was performed, showing a clear regression of the hydrocephalus.

Our patient presented during her hospitalization with generalized tonic-clonic convulsions under phenobarbital at a dose of 5mg/kg/day.

## **DISCUSSION:**

The hospital environment can play an essential role in the transmission of multidrug-resistant pathogens, [1] including *Serratia marcescens* which is able to survive in most of them.

Until the end of the 20th century, *Serratia marcescens* was considered a non-pathogenic saprophytic organism. Its pathogenicity in humans was noted in 1913; however, the prevalence of *Serratia marcescens* in human disease was underestimated for years, until the first known outbreak of nosocomial *Serratia marcescens* infection in 1951. Since then, infections with this organism have been reported from more and more frequently [2,3].

Although *Serratia marcescens* displays relatively low virulence, it causes nosocomial infections in severely immunocompromised or critically ill patients, especially in settings like intensive care units, especially neonatal units [4,5].

*Serratia marcescens* gives rise to a wide range of clinical manifestations in newborns: from asymptomatic colonization to keratitis, conjunctivitis, urinary tract infections, pneumonia, surgical wound infections, sepsis, *circulation infection blood* and meningitis [6,7]. However, the most common site of infection is the bloodstream, followed by the respiratory system and the gastrointestinal tract [8].

The need for repeat lumbar puncture during treatment in a neonate with confirmed meningitis has been debated. Some experts recommend a 2nd lumbar puncture systematically at 48 hours after the start of treatment, while others suggest that a 2nd lumbar puncture be performed if clinical conditions have not improved after 24 to 72 hours of treatment. A retrospective multicentre study by Greenberg et al. did not show a significant difference in the mortality rate between two groups of newborns with confirmed bacterial meningitis, the first of which benefited from a single lumbar puncture while the second has had two or more lumbar punctures [11]

The choice of antibiotic therapy differs according to the results of the antibiogram, in general meropenem in combination with amikacin started early have proven satisfactory results. Corticosteroids have no indication in neonatal meningitis because they modify neither mortality nor neurological sequelae [12], therefore corticosteroid therapy was not performed in our patient. Phenobarbital has been used in neonatal meningitis with seizures. In the study by Chemsî et al, it was used in 51% of cases with an average duration of 7 days [13]. Nosocomial neonatal meningitis has a formidable prognosis, despite the great progress made in the means of diagnosis and management. Mortality rates are currently estimated at between 6.6 and 13% in industrial countries, compared to 20 to 30% in the 1990s. However, in developing countries, mortality rates are still high ranging from 27 to 58% [14, 15,16]. The high mortality of neonatal meningitis is explained by a certain number of factors which determine the prognosis: the diagnostic delay, the virulence of the germ, the gestational age and the early onset of the meningitis. Other prognostic factors should be considered such as the vulnerability of the neonatal nervous system, immuno-incompetence, hypotrophy and neonatal suffering [17,18].

In our patient in addition to these two antibiotics, ciprofloxacin was started in front of the radiological signs of ventriculitis.

A radiological monitoring was practiced in our patient every 15 days, a screening for deafness was negative.

Early identification of colonized or infected patients and prompt implementation of infection control measures, in particular rigorous hand hygiene and contact precautions, are essential to curb the spread of infection.

The Healthcare Infection Control Practices guidelines emphasize the importance of a collaborative, multidisciplinary approach to controlling infections in the hospital setting. These interventions include staff training, environmental sampling, isolation of colonized patients, implementation of infection control measures, and awareness of the role of cross-contamination.

### **CONCLUSION:**

**Serratia marcescens** is a very harmful nosocomial pathogen, especially in neonatal intensive care units, which tend to cause epidemics that are difficult to control, with fatal infections such as neuro-meningeal infections. It is important to respect various preventive measures, especially washing hands.

The severity of neonatal meningitis is linked firstly to the high mortality it causes and secondly to the frequency of neurosensory and psychomotor complications. Short-term and long-term monitoring can detect sequelae at their onset.

### **REFERENCES**

#### **Check the style of all references**

Hilly M, Adams ML, Nelson SC. A study of digit fusion in the mouse embryo. Clin Exp Allergy. 2002;32(4):489-98.

1. Ottria, G.; Dallera, M.; Aresu, O.; Manniello, MA; Parodi, B.; Spagnolo, AM; Cristina, ML Environmental monitoring program in the cell therapy facility of a research centre: Preliminary investigation. J.Prev. Med. Hyg. 2010, 51, 133–138. [PubMed]

2. Al Jarusha, AM; El Qouqa, A.; El Jadba, AH; Al Afifi, AS An outbreak of *Serratia marcescens* septicaemia in neonatal intensive care unit in Gaza City, Palestine. J.Hosp. Infect. 2008, 70, 119–126. [CrossRef] [PubMed]

3. Su, LH; Or, JT; Leu, HS; Chiang, PC; Chiu, YP; Chia, JH; Kuo, AJ; Chiu, CH; Chu, C.; Wu, TL; et al.

Extended epidemic of nosocomial urinary tract infections caused by *Serratia marcescens*. J. Clin. Microbiol. 2003, 41, 4726–4732. [CrossRef] [PubMed]

4. Uduman, SA; Farrukhy, AS; Nathz, KNR; Zuhair, MY; Ifrah, A.; Khawla, AD; Sunita, P. An outbreak of *Serratia marcescens* infection in a special-care baby unit of a community hospital in United Arab Emirates: The importance of the air conditioner duct as a nosocomial reservoir. J.Hosp. Infect. 2002, 52, 175–180. [CrossRef] [PubMed]

5. Dessì, A.; Puddu, M.; Testa, M.; Marcialis, MA; Pintus, MC; Fanos, V. *Serratia marcescens* infections and outbreaks in neonatal intensive care units. J. Chemother. 2009, 21, 493–499. [CrossRef] [PubMed]

6. Societa' Italiana di Igiene, Medicina Preventiva e Sanita' Pubblica (SItI)—Gruppo Italiano Studio Igiene Ospedaliera (GISIO). Available online: <http://www.sitinazionale.org/bdsdocs/gisio/ricerca/01serratia.pdf> (accessed on 13 December 2018).

7. Mahlen, SD Serratia infections: From military experiments to current practice. Clin. Microbiol. Rev. 2011, 24, 755–791. [CrossRef] [PubMed]
8. Gastmeier, P.; Loui, A.; Stamm-Balderjahn, S.; Hansen, S.; Zuschneid, I.; Sohr, D.; Behnke, M.; Obladen, M.; Venberg, RP; Rüden, H. Outbreaks in neonatal intensive care units-they are not like others. Am. J. Infect. Control 2007, 35, 172–176. [CrossRef]
9. Iguchi, A.; Nagaya, Y.; Pradel, E.; Ooka, T.; Ogura, Y.; Katsura, K.; Kurokawa, K.; Oshima, K.; Hattori, M.; Parkhill, J.; et al. Genome evolution and plasticity of Serratia marcescens, an important multidrug-resistant nosocomial pathogen. Genome Biol. Evol. 2014, 6, 2096–2110. [CrossRef]
10. Casolari, C.; Pecorari, M.; Fabio, G.; Cattani, S.; Venturelli, C.; Piccinini, L.; Tamassia, MG; Gennari, W.; Sabbatini, AM; Leporati, G.; et al. A simultaneous outbreak of Serratia marcescens and Klebsiella pneumoniae in a neonatal intensive care unit. J.Hosp. Infect. 2005, 61, 312–320. [CrossRef]
11. Greenberg RG, Benjamin DK Jr, Cohen-Wolkowicz M, Clark RH, Cotten CM, Laughon M, et al. Repeat lumbar punctures in infants with meningitis in the neonatal intensive care unit. J Perinatol 2011; 31 (6): 425–9
12. Daoud AS, Baticha A, Al-Sheyyab M, et al. Lack of effectiveness of dexamethasone in neonatal bacterial meningitis. Eur J Pediatr 1999 158:230–3.
13. Chemsî M, Lehlîmi M, El-Bouz M, Elatîqi S, Habzi A, Benomar S. Neonatal purulent meningitis: about 31 cases. Rev Mar Mal Child 2017; 40:20-21.
14. Campeotto F, Garnier F, Kalach N, Soulaines P, Dupont C, Raymond J. Nosocomial acquisition of multiresistant bacteria in a neonatology department: prospective study and analysis of risk factors. Arch Pediatr 2014; 11(11):1314-18.
15. O. Kamath S, Mallaya S, Shenoy S. Nosocomial infections in neonatal intensive care units: profile, risk factor assessment and antibiogram. Indian J Pediatr 2015, 77(1):37-9.
16. Bas AY, Demirel N, Zenciroglu A, Göl N, Tanir G. Nosocomial blood stream infection in a neonatal intensive care unit in Ankara, Turkey. Turk J Pediatr 2014; 52(5):464-70.

17. Bentlin MR, Ferreira GL, Rugolo LM, Silva GH, Mondelli AL, Rugolo Junior A. Neonatal meningitis according to the microbiological diagnosis: a decade of experience in a tertiary center. *ArqNeuropsiquiatr* 2010; 68(6):882-887.

18. Maalej SM, Kassis M, Rhimi FM, Bacteriology of meningitis in the region of Sfax, Tunisia (1993-2001). *Med mal infect* 2006; 36:105-10.

UNDER PEER REVIEW