

Case report

Double Gastric Perforation as a complication of Peptic Ulcer Disease, a rare Surgical Entity

Abstract

Aim- Double gastric perforations are a rare surgical entity and the operating surgeon has to be aware of the possibility of multiple perforations

Here in we report a case of a 70year old male with double gastric perforation

Presentation of Case:

A 70 year old male patient presented to casualty with complaints of pain abdomen since 3 days and not passing stool and flatus since 2 days. Initial vitals were heart rate 104beats/min, resp rate 23/min bp 95/65mmhg.

Initial resuscitation was done. Chest x-ray and x-ray erect abdomen and usg abdomen and pelvis revealed Gas under the diaphragm

Usg revealed- peritoneal collection with air echoes and debris (?Hollow viscous perforation)

Discussion:

Patient was taken up for emergency laparotomy and intra op pathology revealed 2 perforations one in the antrum and one in pylorus of stomach.

Biopsy was taken and modified Graham's omental patch repair done

Patient discharged without any issue and UGIE after 6weeks revealed no evidence of malignancy

Conclusion:

The occurrence of multiple perforations is rare and should always be kept in mind when encountering a Hollow Viscous Perforation. In emergency setting a quick and a safe surgery has to be carried out with thorough peritoneal toilet followed by postoperative medical management of H.pylori infection

Keywords - double gastric perforation, Graham's omental patch repair, peptic ulcer disease

Introduction-

Hollow Viscous Perforation is one of the common cause of surgical emergency. Of which perforated peptic ulcer is seen in majority of cases. Patients with perforated peptic ulcer have a hospital mortality risk of 10% to 20%. Most patients with perforated peptic ulcer are adequately treated by peritoneal washout and omental patch, with subsequent elimination of risk factors (1). Biopsy to rule out cancer should be done in patients with perforated gastric ulcer(2). Rarely there can be multiple perforations and one must always be aware during the surgery.

Presentation of Case:

A 70 year old male patient came to the casualty with complaints of Pain Abdomen since 3days and not passing stool and flatus since 2days , Associated with Vomitings since 2days and Abdominal Distension. No history of fever , No history of Hematemesis or Black coloured stools. Pt had a history of consuming Native Medications since 3years ,not a known case of Diabetes/ Hypertension.No History of similar complaints in the past and this was the first episode of having such complaints. He is a non smoker and non alcoholic

On Examination Patient was Conscious and Coherent , Pulse rate 104beats/min Respiratory Rate28/min, BP 95/65mmHg

Abdomen was distended, guarding and rigidity were present ,diffuse tenderness , Bowel Sounds were absent.No Growths/Mass ,No ballooning on Digital Rectal Examination

Chest Xray and Xray Erect Abdomen were inconclusive and Usg Abdomen revealed internal air echos with peritoneal collection and internal debris.PreOP TLC was 11,000cells/mm³,

Hb11gm%, platelet count 1.4lakhs , Sr urea 40mg/dl, Sr Creatinine 0.9mg/dl, Na-137meq ,K-3.3meq

Patient was taken up for an Emergency Laparotomy. IntraOP Findings were around 1000ml of biliopurulent fluid was drained and 2 perforations- One at Antrum of Stomach around 2.0x1cms in size and one at Pylorus of Stomach around 1.5x1cms in size were found. Fig 1

Biopsy was taken and a Modified Grahams Omental patch repair was done for both the perforations and Thorough toileting was done, 2 ADK drains one in Morrison space and one in pelvis were given

Patient recovered completely, postop period was uneventful and pateint was discharged on post op day7. The biopsy showed inflammatory cells and there was no evidence of malignancy.An Upper GI Endoscopy of this patient after 6weeks revealed no evidence of malignancy

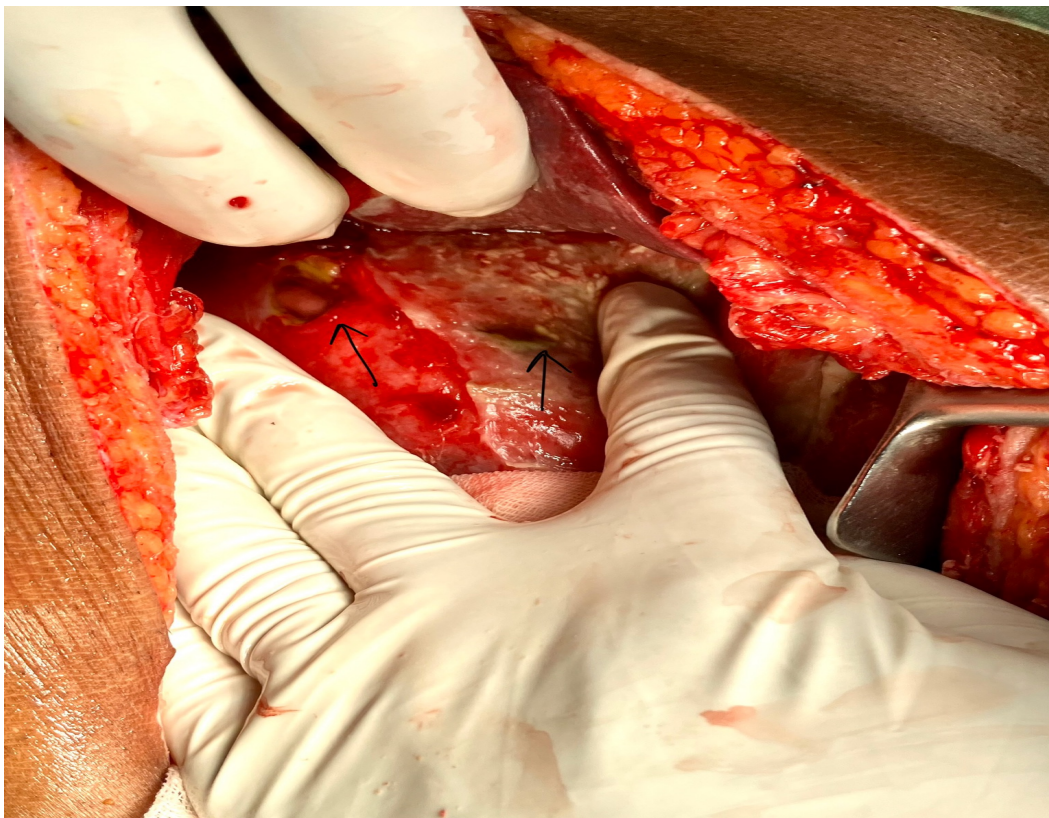


Fig. 1. biliopurulent fluid at Pylorus of Stomach

Discussion:

Perforation is the second most common complication of Peptic ulcer with an annual incidence of 11 operations per 100,000 population. Perforations are associated with the highest rate of mortality(3). The incidence of *H. pylori* in the setting of gastric ulcers is between 80% and 90% and up to 100% in the setting of duodenal ulcers(4).

Peptic perforation is the most prevalent surgical emergency. With high mortality and morbidity, peptic perforation is most commonly present in the first part of the duodenum (35-65%), with 25-45% located in the pylorus, and 5-25% in the stomach. (5). One of the major difference between a Gastric and a duodenal ulcer is that , the gastric ulcers more commonly harbour malignancy and should be biopsied (6). Causes of gastric perforation include *H.pylori* infection, NSAID abuse, Smoking , Stress , Spicy food and Malignancy. The patient had a Boey score of 2 which suggests a Perioperative Morbidity of 75% and Mortality of 33% (7)

Occurance of Multiple perforation is a rare entity of which multiple gastric perforation is further more rare(8). There are a very few cases that reported of multiple perforations in literature. Our case had perforation one along the Greater Curvature and the other at the pylorus. As it was an emergency and taking patients age and delayed presentation into consideration we performed a Modified Grahams Omental Patch Repair of both the perforations with Biopsy of the perforations and post operative medical management for eradication *H.pylori* infection. The biopsy revealed no evidency of malignancy and subsequent UGI Endoscopy after 6weeks showed Antral Gastritis and a healed Ulcer. The patient is doing well and is on regular followup. For peptic perforation, a Graham patch repair, with or without an acid reducing surgery is probably the most appropriate management. It is the easiest, quickest, safest operation, and can be applied to all situations by every surgeon; moreover, it can be complemented later with an effective medical treatment that should include eradication of *H. pylori*.(10)

Conclusion :

The occurance of multile perforations is rare and should always be kept in mind when encountering a Hollow Viscous Perforation. In tropical countries like India *H.pylori* infection is the commonest cause followed by NSAIDs abuse.In emergency setting a quick and a safe surgery has to be carried out with thorough peritoneal toilting followed by postoperative medical management of *H.pylori* infection

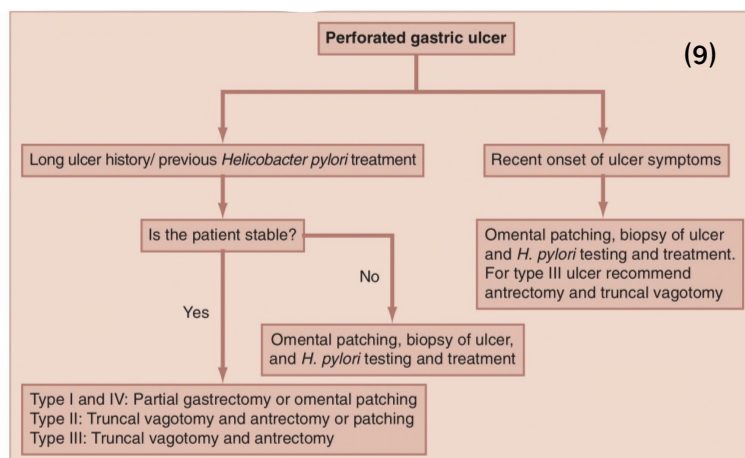


Fig 2. Recommended treatment algorithm for surgical management of perforated gastric ulcers.

References-

(1) &(2)- Michael J. Zinner, Stanley W. Ashley, O. Joe Hines. Maingot's Abdominal Operations, 13th ed. New York: McGraw-Hill Education; 2019. 1295p

(3) Wang YR, Richter JE, Dempsey DT. Trends and outcomes of hospitalizations for peptic ulcer disease in the United States, 1993 to 2006. *Ann Surg*. 2010;251(1):51-58.

(4) Kokoska ER, Kauffman GL Jr. Helicobacter pylori and the gastroduodenal mucosa. *Surgery*. 2001;130(1):13-16.

(5) Bulut OB, Rasmussen C, Fischer A. Acute surgical treatment of complicated peptic ulcers with special reference to the elderly. *World J Surg*. 1996;20:574-577.

(6) Yeo, Charles J, David W. McFadden, Steven R. DeMeester, Jeffrey B. Matthews, James W. Fleshman. Shackelford's surgery of the alimentary tract, 8th ed. Philadelphia, PA : Elsevier, [2019]. 691p

(7) Lohsiriwat V, Prapasrivorakul S, Lohsiriwat D. Perforated peptic ulcer: clinical presentation, surgical outcomes, and the accuracy of the Boey scoring system in predicting postoperative morbidity and mortality. *World J Surg*. 2009 Jan;33(1):80-65.

(8) &(10) Atul K. Sharma, Rakesh K. Sharma, Santosh K. Sharma, Devendra Soni, Tej Pratap Singh. Double peptic perforation: Report of a rare case. *Asian Journal of Surgery* (2015) 38, 239-241

(9) Flowchart- Yeo, Charles J, David W. McFadden, Steven R. DeMeester, Jeffrey B. Matthews, James W. Fleshman. Shackelford's surgery of the alimentary tract, 8th ed. Philadelphia, PA : Elsevier, [2019]. 699p