

**CHRONIC TOXICOLOGICAL ASSESSMENT OF AQUEOUS EXTRACT OF A COMBINATION OF NAUCLEA LATIFOLIA ROOT AND ACALYPHA TORTA LEAF ON THE LIVER, KIDNEY AND HEART OF WISTAR RAT**

**ABSTRACT**

**Background:** *Nauclea latifolia* and *Acalypha torta* are medicinal plants found in Nigeria with scientifically validated anti-diabetic properties. Although these herbal preparations are derived from natural sources, some of them may still possess the potential to cause some adverse reactions on the vital organs of the body. **Aim:** This study was therefore designed to assess the chronic toxicological effects of orally administered aqueous extract of a combination of *N. latifolia* root and *A. torta* leaf on the liver, kidney, and heart of Wistar rats. **Materials and Methods:** Hot aqueous extraction of the mixture of dried, pulverized samples was carried out for 24 hours at the laboratory temperature. After filtrations, the final filtrate was evaporated to dryness using Rotary Evaporator. Effects of the *Nauclea latifolia* *Acalypha torta* extract (NLAT), on the liver, kidney, and heart were assessed following daily oral administration of the extract in alloxan-induced diabetic rats at the dose of 100.0 mg/kg for six months. Changes in body weight and blood glucose levels were monitored. All the indices of liver, kidney, and heart functions were estimated with the aid of Randox Diagnostic Test Kits following the manufacturer's methods and a total of eighty-four rats (120-150g) were used. **Results:** Results showed that the extract, NLAT, had a positive impact on body weight which correlates with the concomitant reduction in the average blood sugar levels. There was no observable significant differences ( $P>0.05$ ) in the activities of alanine aminotransferase (ALT), aspartate aminotransferase (AST), alkaline phosphatase (ALP) and lactate dehydrogenase (LDH) when compared with the controls. Total bilirubin (TB), direct bilirubin (DB), creatinine, and urea levels were within the normal ranges. Histopathological evaluations showed no perturbation of the normal architectures of the liver, kidney and heart. **Conclusion:** The combination at the dose tested was well tolerated by the animals and there was no indication of hepatotoxicity, nephrotoxicity, or cardiotoxicity.

**Keywords:** *Nauclea latifolia*, *Acalypha torta*, Histopathology, Hepatotoxicity, Nephrotoxicity, Cardiotoxicity

## INTRODUCTION

Phytomedicines are reportedly the most commonly adopted form of alternative medicine. According to Fabricant and Farnsworth, 2001 [1] almost 65% of the world's populations have incorporated traditional medicine (mainly herbs) into their primary modality of health care.

Many people in developing countries of Africa, particularly those in rural areas, have more access to traditional than modern medicines and use them more frequently for primary healthcare. About 80% of the population are dependent on herbal remedies [2].

World Health Organization (WHO) Expert Committee recommends and encourages the appropriate use of herbal remedies certified safe by Food and Drug Regulatory bodies. However, in rural areas these tradodrugs are produced by herbalists without adequate standardization and very few of these preparations undergo safety assessment evaluations prior to commercialization.

*Nauclea latifolia* and *Acalypha torta* are among the medicinal plants commonly found in Nigeria. The roots and leaves of *N. latifolia* and *A. torta* respectively have been shown to be richly endowed with antidiabetic and anti-hypertensive properties [3,4,5,6,7]. These plants are effective when taken separately or in combination with other plants [3]. Findings on the three months - sub-chronic toxicity study on the aqueous extract of a combination of both plants suggested that the extract was well tolerated by the experimental animals. Histopathological evaluations at the same time revealed no organ-system perturbation with normal architectures in the liver, kidney, and heart indicating that these aqueous extract of this mixture did not cause any observable deleterious effects on the animals [8].

The present study was therefore designed to investigate the chronic effect(s) of this same extract in Wistar rats following six months of oral administration.

## MATERIALS AND METHODS

**Place and Duration of Study:** The work was carried out at laboratory unit of the Department of Biochemistry, Nnamdi Azikiwe University, Awka, Anambra State, Nigeria, for a period of six months.

**Plant Materials:** Samples of *Nauclea latifolia* root and *Acalypha torta* leaf were collected from Nnamdi Azikiwe University premises and Abagana respectively in Anambra State, Nigeria. They were identified and authenticated in the Department of Botany, Faculty of Biosciences, Nnamdi Azikiwe University, Awka.

**Animals:** Mature Wistar rats weighing between 120-150g purchased from Chris Animal Farm, Mgbakwu, Awka were used for this study as the animal models. The rats were housed in the animal house of the Department of Applied Biochemistry, Nnamdi Azikiwe University, Awka and were allowed to acclimatize for 7days at room temperature with adequate ventilation. The animals were also sustained with standard animal chows (Guinea growers pellets) and had free access to clean water *ad libitum*.

**Chemicals and Reagents:** All the chemicals and reagents used were of analytical grade and these included chloroform, formalsaline from BDH Limited, Poole, England; Radox kits from USA, whereas paraffin, haematoxylin and eosin dyes were made by May and Baker Limited, Dagenham, England. All the assay kits used for the biochemical analyses were manufactured by Radox Laboratories Ltd., Admore Diamond Road, Crumlin Co., Antrim, UK Ot 94QY.

Equipment: Rotary evaporator RE52-2 SEARCHTECH INSTRUMENT and Spectrophotometer – Ultrospec 3100 proAmersham Biosciences, Biochrom Ltd, England.

**Aqueous Extraction:** Eight hundred and fifty grams (850g) of *Nauclea latifolia* root sample and one hundred and seventy grams (170g) of *Acalypha torta* leaf sample were mixed and soaked with 5.0 litres of distilled water and this was allowed to stand for 24 hours with intermittent stirring, after which cheese cloth and Whatman No.1 filter paper were used to filter. The filtrate was then evaporated with a rotary evaporator under reduced pressure and temperature below 40°C to obtain the aqueous extract as a semi-solid paste. The percentage yield was calculated and the extract (NLAT) stored in the freezer until used.

**Induction of Diabetes:** The baseline blood glucose levels of all the rats were estimated after an overnight fast using AccuCheck – Active glucometer and glucostrips. Diabetes mellitus was then induced with intraperitoneal administration of alloxan monohydrate (150.0 mg/kg) solubilized in

normal saline. Two hours (2h) after administration, the alloxan – induced hypoglycemia in the animals was ameliorated using oral infusion of 20 % glucose-D solution. The rat blood glucose levels were measured again after 48 hours and levels  $\geq 200.0$  mg/dl were regarded as established diabetes.

**Chronic Toxicity Study:** Eighty-four (84) male Wistar rats within the weight range of 120g-150g were used after acclimatization with the laboratory environmental conditions for 7days. The animals were weighed and divided into four groups (A – D) of 21 rats each (i.e n = 21). The normal control rats (A) received normal saline (1.0 ml/kg b.wt) only while the positive control animals (B) were the untreated diabetic rats. Diabetic rats in groups C and D were treated with 20.0 mg/70kg.bwt and 100.0 mg/kg.bwt of glibenclamide (reference drug) and aqueous NLAT extract respectively. Saline, glibenclamide and NLAT extract were administered orally via a stomach tube once daily for six (6) months (180 days).

At the end of each month, 2 animals from each group were anaesthetized using chloroform swab and blood was collected by heart puncture into plain specimen containers and allowed to clot. After centrifugation, the serum samples obtained were used for the determination of biochemical parameters. The animals were dissected and organ samples excised carefully and fixed in 10% formalsaline. Organ sections were trimmed, processed and stained with haematoxylin and eosin (HE) stains for histopathological examination.

#### **Biochemical Assays:**

Aspartate aminotransferase (AST), and Alanine aminotransferase (ALT) were determined using Reitman and Frankel method (9). Blood urea content was determined by the method described by Fawcett and Scott [10]. Creatinine was determined following the colorimetric method as described by Bartels and Bohmer [11]. Total bilirubin was analyzed by the colorimetric method [12]. Alkaline phosphatase (ALP) and Lactate dehydrogenase (LDH) activities were both determined by the method of Rec [13].

**Statistical Analysis:** Results of the study were expressed as mean $\pm$  standard deviation. Differences between the mean of the treated groups and their control in this animal studies were

analyzed using the Analysis of Variance (ANOVA) of SPSS 16.0 spreadsheet statistical package. Values were taken to be significant at ( $p < 0.05$ ).

## **RESULTS AND DISCUSSION**

Results of the investigation showed that all the experimental animals that received alloxan monohydrate at the dose of 150.0 mg/kg manifested all the well-known clinical features of diabetes mellitus such as frequent urination and weight loss. The long-term significant reduction in body weights was more apparent in the untreated diabetic rats and culminated in the death of these animals after three months. Conversely, 62.03% increase in body weight was recorded in the normal (Negative control group) (Fig. 1). Treatment of the diabetic rats with the standard drug, glibenclamide, 20.0 mg/70 kg and NLAT extract (100.0 mg/kg) restored the rats' body weights by 51.87% and 68.05% respectively after six months. The positive impact of the extract on body weight correlates with the concomitant reduction in the average blood sugar levels (from  $398.0 \pm 20.00$  to  $191.5 \pm 2.5$ , 51.90%), although there were fluctuations (Fig.2). Reduction in body weight following the administration of any xenobiotic or plant extract is among the common indicators of adverse reaction [14, 15]. The observed consistent significant increase in body weights when compared with the untreated diabetic (Positive control) group showed that the NLAT extract is relatively safe. This is in conformity with findings from the oral acute, sub-acute, and sub-chronic toxicological studies on NLAT extract reported by [8, 16].

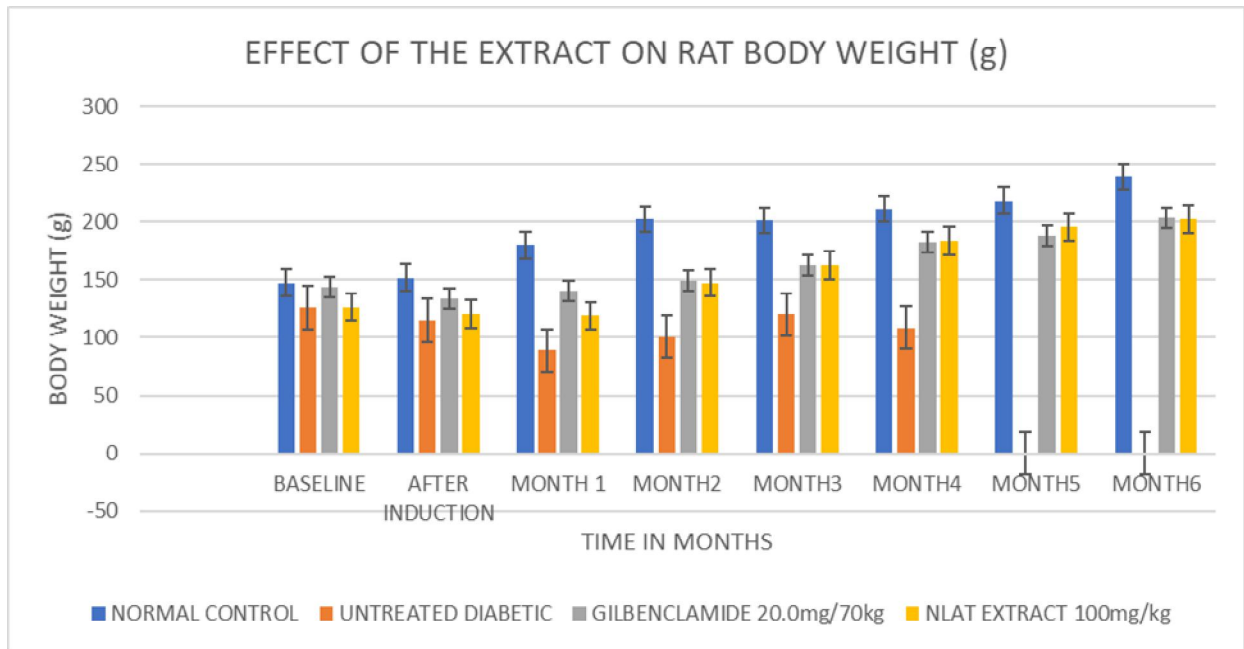


Fig 1: Effect of NLAT extract on rat body weight

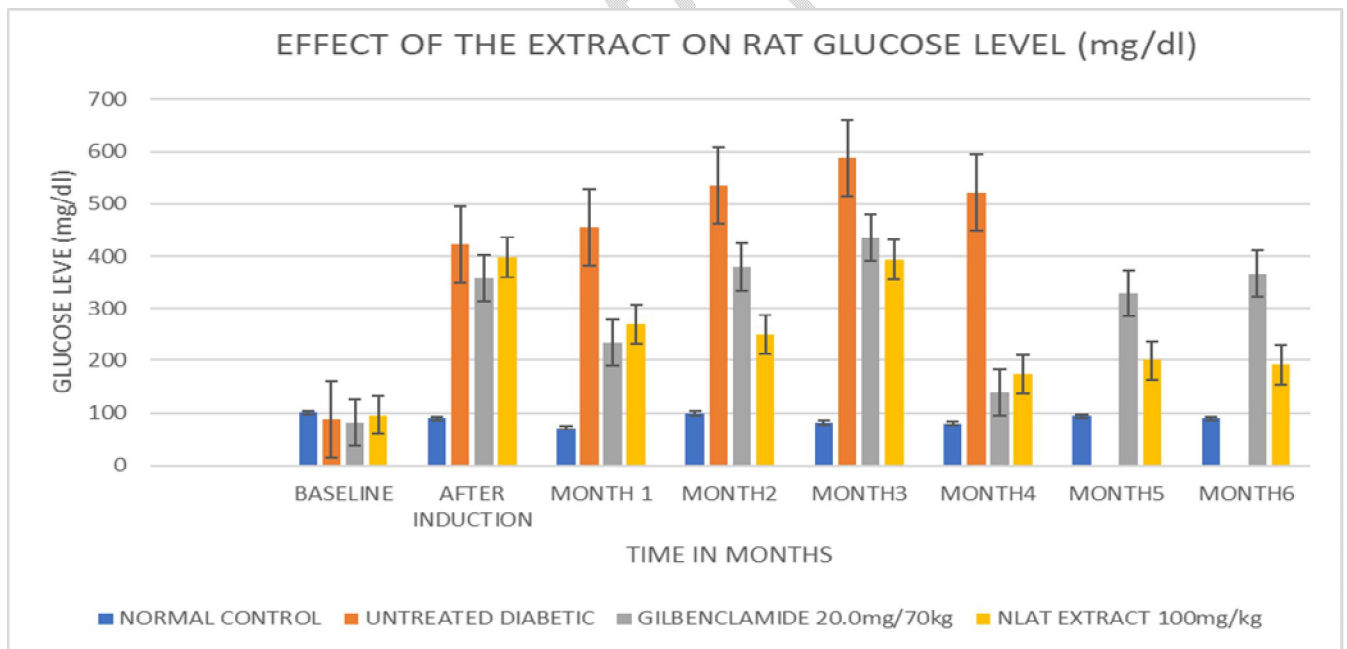


Fig 2: Effect of NLAT extract on blood glucose Level

Cellular enzymes are confined within the tissue compartments so that trace amounts of these enzymes appear in the blood, plasma or serum. Damage to these tissues triggers the leakage of these enzymes into the blood due to the disruption of cellular membrane integrity. Alanine

aminotransferase (ALT) and aspartate aminotransferase (AST) catalyze transamination reactions and are abundantly distributed within the hepatocytes. Elevations in the blood concentrations of these enzymes are therefore indicative of liver disease such as hepatitis, hepatobiliary obstruction, cholestasis or liver necrosis [17]. AST, which also predominates in the heart muscle, also serves as a biomarker for myocardial infarction and muscle injury [18]. In addition to these, alkaline phosphatase (ALP), total bilirubin (TB) and conjugated or direct bilirubin (DB) are markers of liver function. Large amount of ALP is also present in active osteoblasts of the bone.

Significant decreases ( $P < 0.05$ ) in all the liver parameters (ALT, AST, ALP, TB and DB) were observed at the early stage of the investigation. There were noticeable fluctuations in the values within four months and by the end of six months remarkable increases were seen when compared with their baseline readings. NLAT extract reduced ALT from  $77.93 \pm 1.11$  (baseline) to  $1.48 \pm 0.12$  u/l (after 4 months) and increased to  $14.78 \pm 0.79$  u/l (after 6 months), whereas AST declined from  $23.00 \pm 0.82$  (baseline) to  $7.00 \pm 0.41$ u/l (after 4 months) and then increased to  $30.26 \pm 2.13$  u/l (after six months) (see Figs 3 and 4).

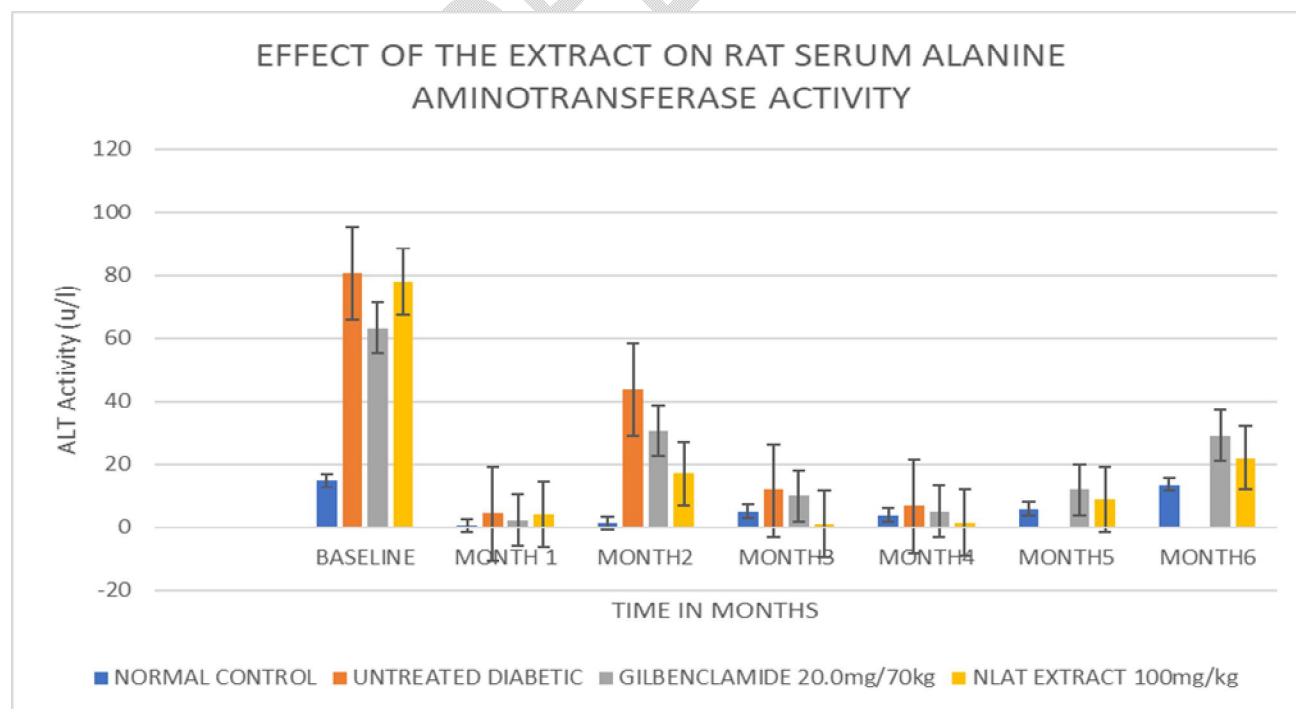


Fig 3: Changes in ALT activity following treatment with NLAT extract

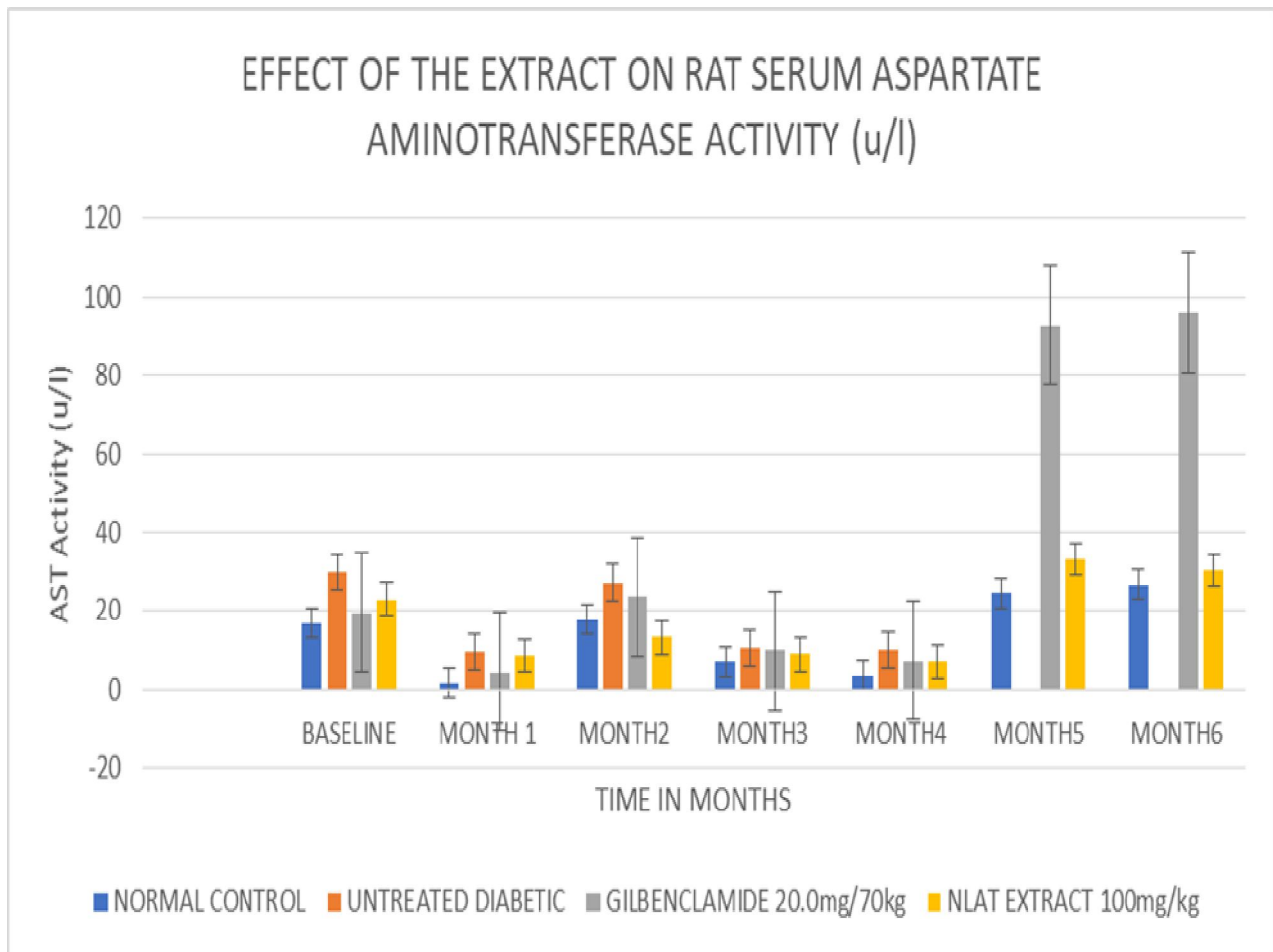


Fig 4: Changes in AST activity following treatment with NLAT extract

Result displayed in Figure 7 revealed steady and significant decline ( $P < 0.05$ ) in ALP throughout the six months duration in all the groups including the normal rats that were on normal saline. Treatment of the diabetic animals with aqueous NLAT extract reduced ALP from  $8.00 \pm 0.52$  to  $2.89 \pm 0.15$  u/l. Furthermore, the ranges of total and direct bilirubin recorded within the normal rats were 0.28 – 3.90 mg/dl and 0.10 – 1.31 mg/dl respectively. Inasmuch as steady reductions were observed, values in both the glibenclamide and NLAT extract treated animals were still within the lower and upper limits of the serum total and direct bilirubin levels (Figs 5 and 6).

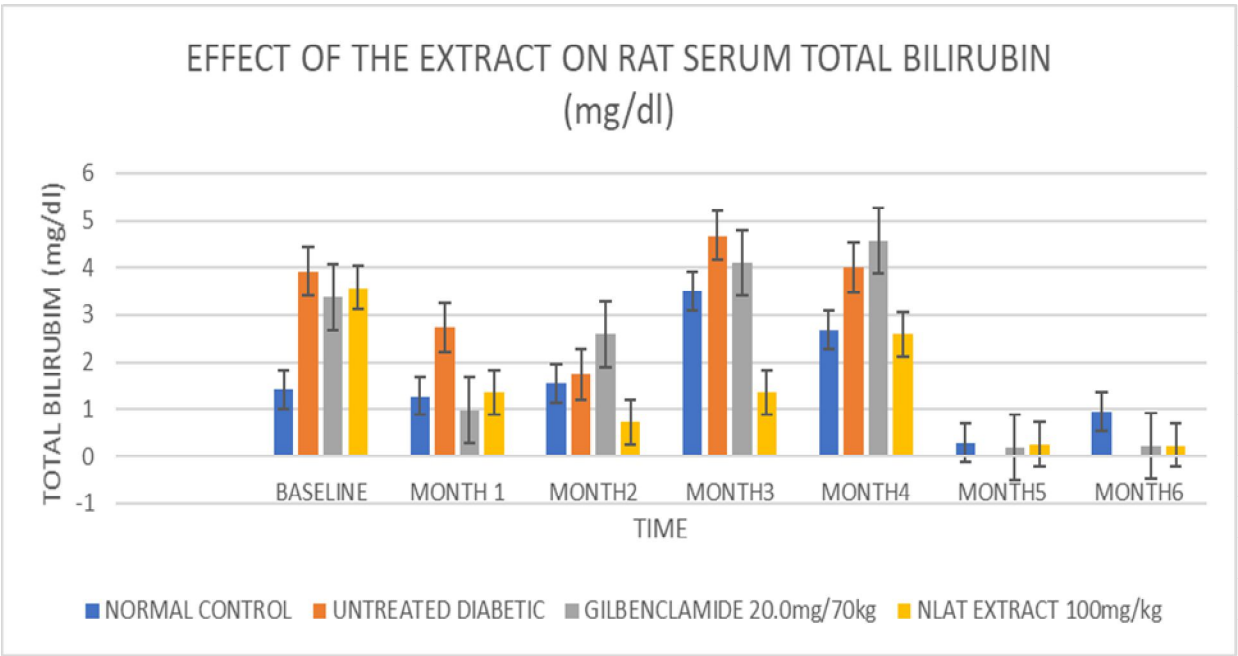


Fig 5: Showing the effect of aqueous NLAT extract on total bilirubin concentration in rat

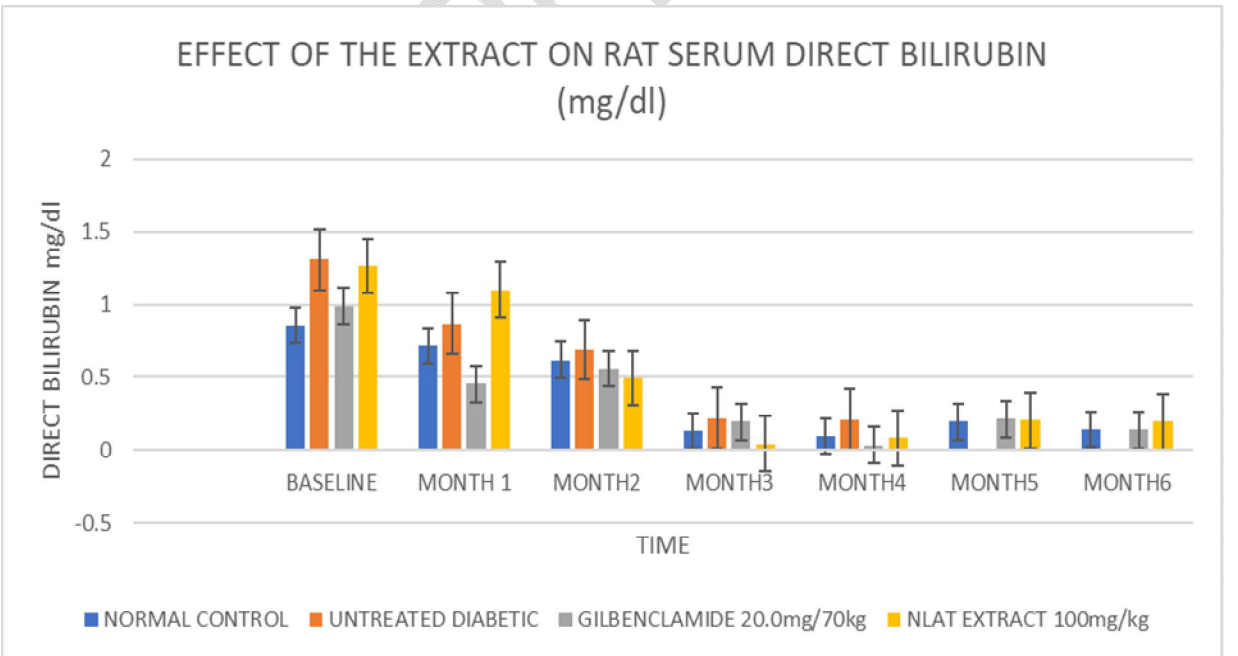


Fig 6: Showing changes in direct bilirubin concentration in rat

The demonstrated decreases in liver parameters may neither be the resultant effects of the treatment with extract, nor glibenclamide since the same effects were significantly observed in the normal rats ( $P < 0.05$ ). Rather, the progressive decline in enzyme activities per se could be an age – related phenomenon. Vyskocilovar [19] established a correlation between hepatic enzyme activity and life expectancy in experimental rat models. The team also reported a remarkable age – related decrease in UDP – glucuronyltransferase. Decline in tryptophan metabolizing enzyme activities has also been documented in Sprague – Dawley rat tissues [20]. Also, Testa and Kramer [21], studying the influencing factors on drug metabolism discovered that, generally, enzyme activities are lower in old individuals than in adulthood and in rodents if the study duration is  $\geq 3$  months, even reproductive changes could be observed [22].

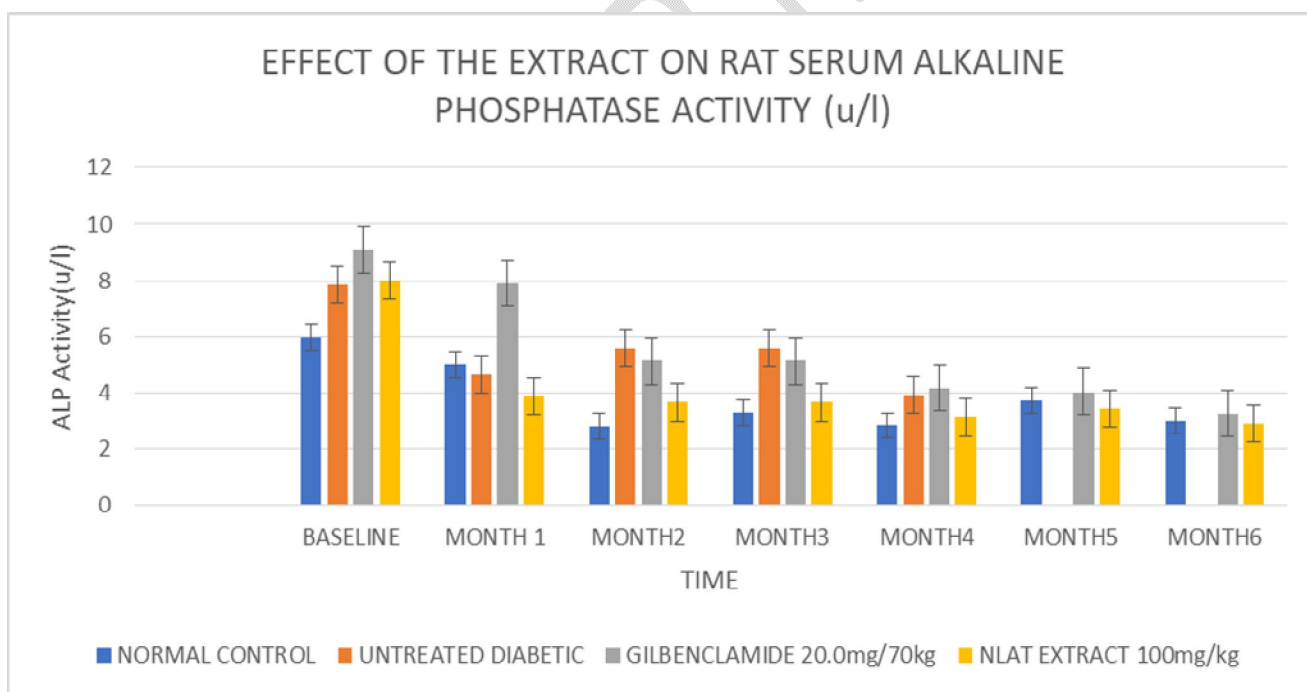


Fig 7: Changes in rat serum ALP activity caused by NLAT extract

Blood urea nitrogen (BUN) and serum creatinine are recommended and reliable indicators of renal functions and thus, nephrotoxicity [23]. Measurement of these indices are also among the determinants of estimated glomerular filtration rate (eGFR) which is a very useful tool in the

assessment of kidney functions [24]. Elevations in blood urea and creatinine levels are indicative of abnormal kidney function and by implication impairment of the renal filtration mechanism [25, 26]. Reductions in both urea and creatinine levels were seen in all the animal groups after three months of treatments. At the end of the fourth month, elevations in creatinine levels were observed in all the groups, and this effect was remarkable and significant ( $P < 0.05$ ) in the extract and glibenclamide treated diabetic animals (Figs 8 and 9). However, after six months of administration diminished amounts of creatinine were recorded in the control as well as the treated groups while urea level consistently reduced throughout the duration of the study. Aqueous NLAT extract reduced serum urea from  $246.81 \pm 25.80$  to  $67.06 \pm 8.77$  mg/dl and creatinine from  $11.17 \pm 0.36$  to  $0.11 \pm 0.01$  mg/dl. Similar patterns were observed in the control rats ( $212.55 \pm 6.41$  to  $61.23 \pm 4.58$  mg/dl and  $30.52 \pm 0.71$  to  $0.04 \pm 0.00$  mg/dl for urea and creatinine respectively).

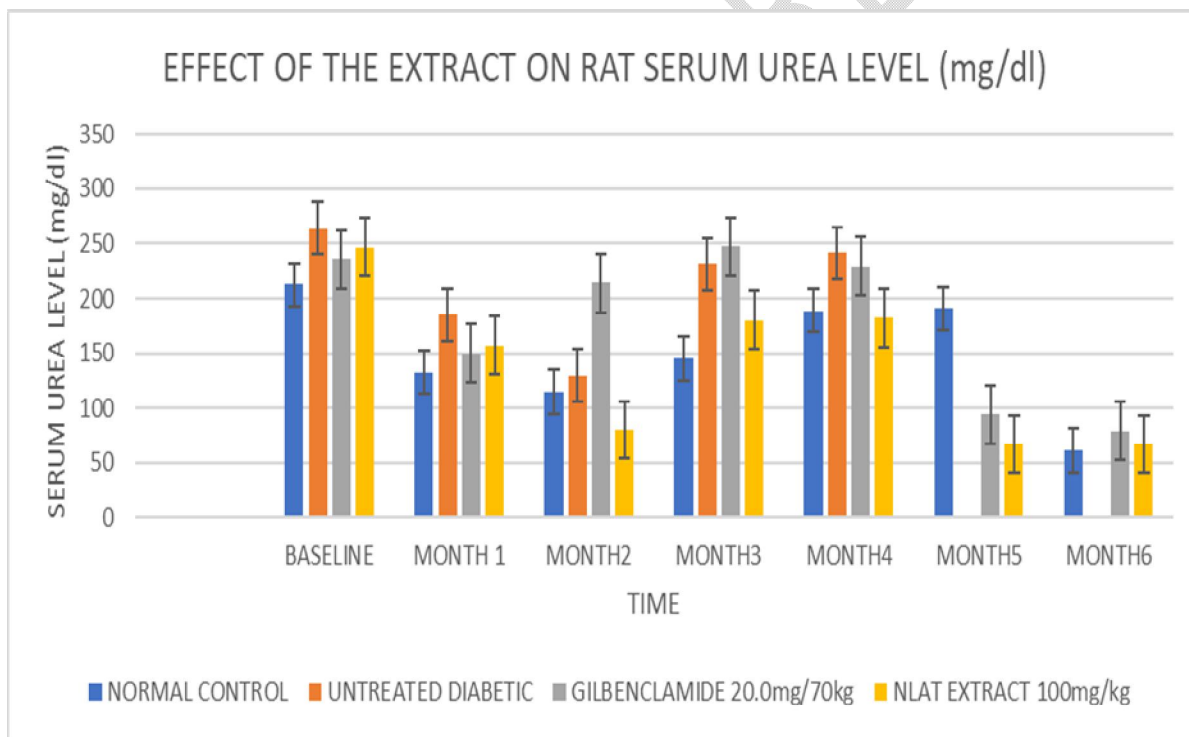


Fig 8: Effect of NLAT extract on serum urea level in rat

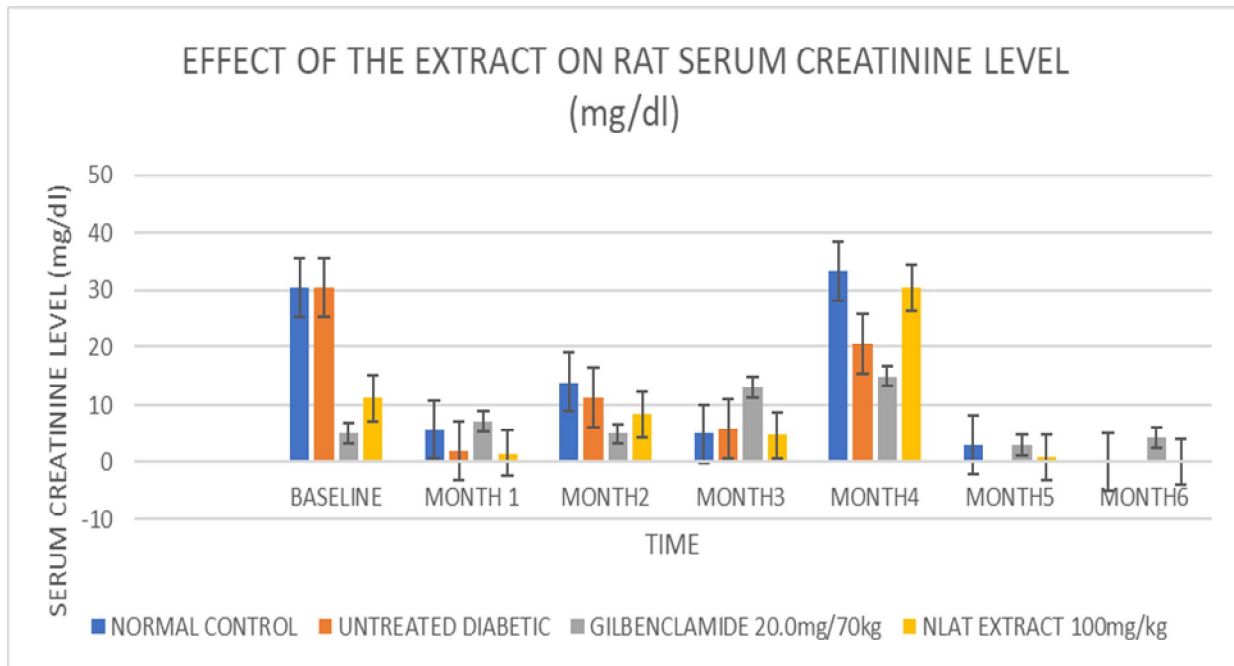


Fig 9: Effect of NLAT extract on serum creatinine level in rat

These observations showed that oral intake of NLAT extract did not inflict any injury on rat kidney at the administered dose of 100.0 mg/kg body weight.

For serum total lactate dehydrogenase which is one of the biomarkers of damage to the myocardium, increased activity was noted in the control, untreated – diabetic and treated – diabetic groups between the third and fourth months. The significant increase ( $P < 0.05$ ) was more in the untreated – diabetic rats and diabetic rats treated with glibenclamide. At the end of six months, similar activities were seen in both control group and NLAT extract – treated rats ( $121.04 \pm 23.36$  u/l and  $122.66 \pm 0.90$  u/l respectively) suggesting that the extract did not cause any measurable adverse effect on the hearts of the rats (Fig. 10).

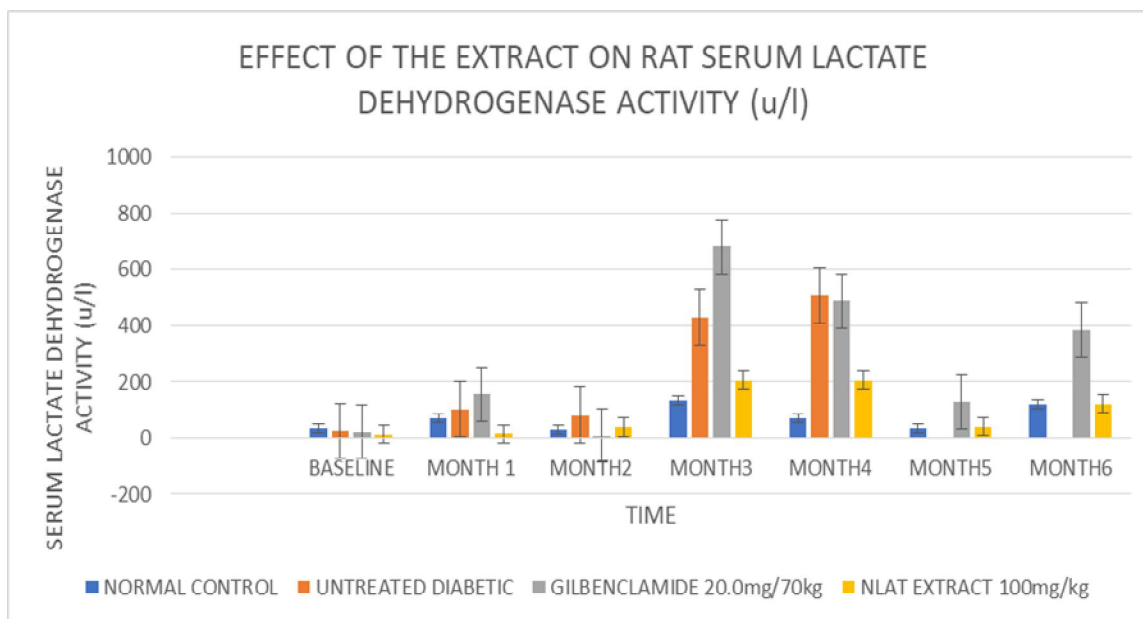


Fig 10: Changes in rat serum lactate dehydrogenase activity caused by NLAT extract

In toxicological evaluations histopathological examinations commonly serve as supportive evidence for biochemical estimations [27]. The photomicrographs of the liver, kidney and heart tissue preparations of the normal and NLAT – treated rats are presented in Plates 1- 6. The observed morphologies showed that chronic oral infusion of aqueous NLAT extract did not distort the normal architectures of the vital organs studied. However, in Plate 4, moderate microvesicular steatosis was detected in the hepatic tissue. Reportedly, aqueous *Acalypha wilkesiana* leaf extract stimulated significant dose-related elevations in ALT, AST, ALP, TP, albumin and urea. Histopathological analyses also showed dose-dependent mild to severe toxicity in the liver and kidney of rats when compared with the control group [28].

Findings from the present study did not reveal any synergistic relationship between the anti-diabetic potencies of *Nauclea latifolia* root and *Acalypha torta* leaf since the extracts of both plants when administered separately exhibited stronger anti-diabetic effects (*A. torta* (syn. *Wilkesiana*) leaf (66.5 %) and *N. latifolia* root (79.9 %) (6), while the combination produced 51.90 % reduction in average blood glucose level. Drug-induced hepatotoxicity and nephrotoxicity are among the principal reasons for the withdrawal of drug candidates (orthodox or herbal) with promising efficacies during clinical trials and any agent with  $LD_{50} \geq 5000\text{mg/kg}$  can be regarded as safe [29]. It is also interesting to deduce from our observations that

combining the two plant samples ameliorates the toxicity of *A. wilkesiana* leaf extract at acute [7] and sub-chronic levels [16]. Ogbonnia and his colleagues [30] also reported that when a combination of *N. latifolia* root and *Newbouldia laevis* root was administered to rats, no altered morphologies of the liver, kidney and heart were observed. Aqueous extract of NLAT therefore also possesses hepatoprotective, nephroprotective, as well as cardioprotective activities.

## CONCLUSION

In conclusion, the combination, NLAT, at the dose tested was well tolerated by the animals and there was no indication of hepatotoxicity, nephrotoxicity, or cardiotoxicity.

RECOMMENDATION: Further studies should focus on the effects of higher doses of NLAT above 100.0 mg/kg weight on the vital organs. Clinical testing in human subjects could also be initiated.

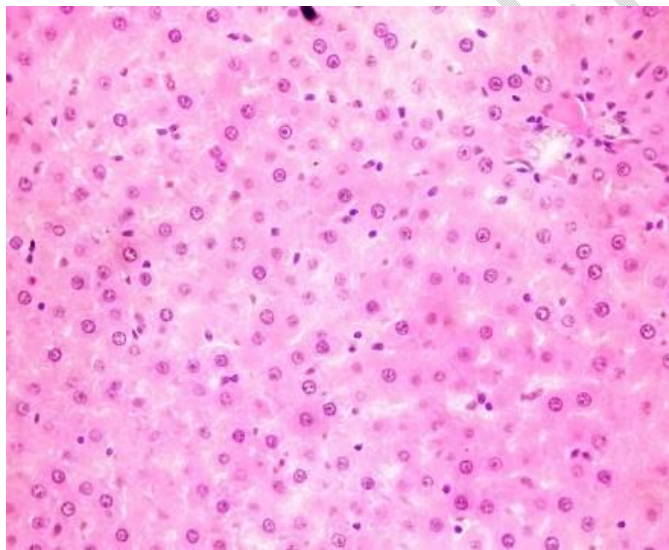


Plate 1. Control: High power photomicrograph (x40 objective) showing normal liver tissue

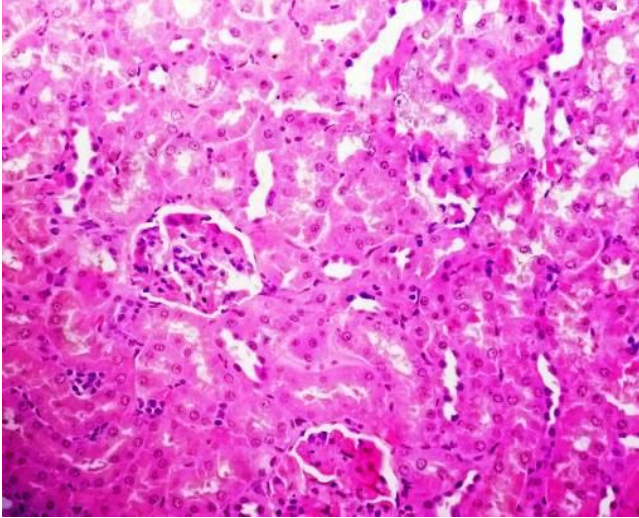


Plate 2. Control: A High-power photomicrograph (x40 objective) shows normal kidney tissue

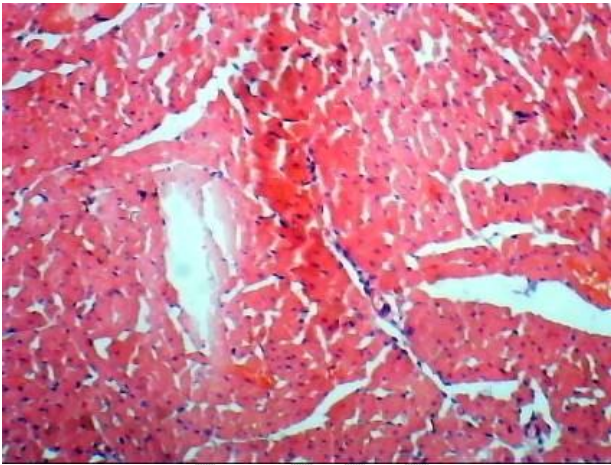


Plate 3. Control: High-power photomicrograph (x 40 objectives) shows normal cardiac fibres.

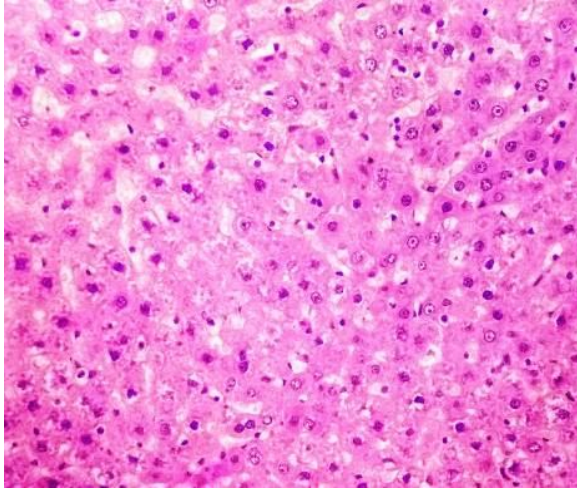


Plate 4. NLAT: High-power photomicrograph (x 40 objectives) shows liver tissue with moderate micro-vesicular steatosis.

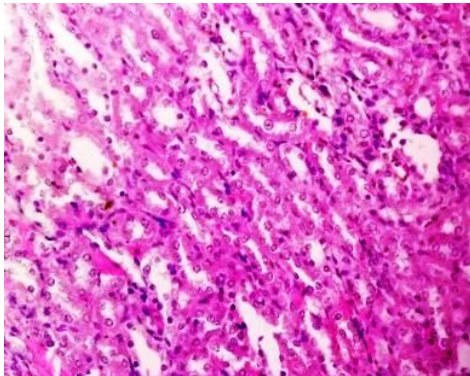


Plate 5. NLAT: A High-power photomicrograph (x40 objective) shows normal renal tissue

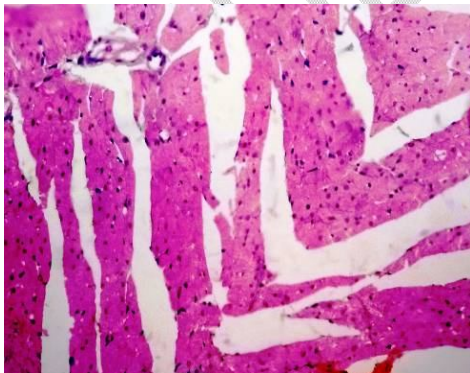


Plate 6. NLAT: A High-power photomicrograph (x 40 objectives) shows normal heart tissue

**ETHICAL APPROVAL:** All authors hereby declare that “ Principles of laboratory animal care “(NIH publication No. 85 – 23, revised 1985) were followed, as well as specific national laws where applicable. All experiments have been examined and approved by the appropriate ethics committee.

## REFERENCES

1. Fabricant D.S and Farnsworth N.R. (2001).The Value of Plants used in Traditionalmedicine for Drug discovery. *EnvironmentalHealth Project*, **1**:69-75.
2. WHO, (2003). Traditional Medicine Fact Sheet No. 134. Available <http://www.who.int/mediacetre/factsheets/fs134/en/>(February 6,2017).
3. Ezekwesili, C.N., Asomugha, R.N, Ekwealor, C.C, Ekwunife, C.A and Adindu, S.C.(2018). Antidiabetic effects of Combinations (ratios) of Selected Nigerian Antidiabetic Plants. *Journal of Pharmacy and Biological Sciences*, **13(2)**: 01-06.
4. Ezeigbo O.R.,Barrah C.S and Ezeigbo I.C. (2016). Phytochemical Analyses and Anti-diabetic effect of Aqueous and Ethanolic Extracts of *Moringa oleifera* leaves in Alloxan-induced Diabetic Wistar albino Rats using as Reference drug. *International Journal of Diabetes Research*, **5(3)**:48-53.
5. Aguora S.O., Unekwe P.C and Okechukwu E.C. (2015). Evaluation of Antidiabetic Activity of *Nauclea latifolia* Chloroform root Extract in Normal and Alloxan-induced Diabetic Rats. *IOSR Journal of Pharmacy and Biological Sciences (IOSR-JPBS)*, **10(3)**:53-57.
6. Ezekwesili, C.N and Ogbunugafor,H.A.(2015). Blood Glucose Lowering Activity of five Nigerian Medicinal Plants in Alloxan-induced Diabetic Wistar albino Rats. *Animal Research International*, **12(2)**: 2150 – 2158.
7. Ezekwesili, C.N., Ghasi,S and Nwodo, O.F.C.(2012). Evaluation of the Blood Pressure Lowering Activity of leaf Extract of *Acalypha torta* Muell. *African Journal of Pharmacy and Pharmacology*, **6(4)**:3235-3241.
8. Ezekwesili C.N, Aguzue N.M, Asomugha R.N, Ekwunife C.A, Ekwealor C.C and Adindu S.C. (2017). Effect of Aqueous Extract of a Combination of *Nauclea latifolia* root and *Acalypha torta* leaves on Liver, Kidney and Heart of Wistar albino rats. *IOSR Journal of Biotechnology and Biochemistry*, **3(4)**: 79-83.
9. Reitman S and Frankel A. (1957). A Colorimetric Method for the Determination of Serum Glutamic Oxaloacetic and Glutamic Pyruvic Transaminases. *American Journal of Clinical Pathology*, **28**:56-63.
10. Fawcett J.K and Scott J.E. (1960). A Colorimetric Method of Blood Urea Determination. *Journal of Clinical Pathology*, **13**:156-159.
11. Bartels H and Bohmer C.(1972). Serum Creatinine Determination Without Protein Precipitation. *Clinica Chimica Acta*, **37**:193-197.
12. Jendrassik I and Grof P. (1938). A Colorimetric Method of Bilirubin Determination. *Biochemical Zeitschrift*, **297**:82-89.

13. Rec.GSCC (DGKC)(1972). Optimised Standard Colorimetric Methods. *Journal of Clinical Chemistry and Clinical Biochemistry*, **10**:182.
14. Abbas M.Y., Ejiofor J.I and Yakubu M.I. (2018). Acute and Chronic Toxicity Profiles of the Methanol Leaf Extract of *Acacia ataxacantha* D.C. (Leguminosae) in Wistar rats. *Bulletin of Faculty of Pharmacy, Cairo University*, **56**:185-189.
15. Vahalia M.K., Thakur K.S., Nadkami S and Sangle V.D. (2011). Chronic Toxicity Study for Tamra Bhasma (A generic ayurvedic mineral formulation) in Laboratory Animals. *Recent Research in Science and Technology*, **3**:2076-5061.
16. Ezekwesili C.N, Aguzue N.M, Asomugha R.N, Ekwunife C.A, Ekwealor C.C and Adindu S.C. (2017). Effect of Aqueous Extract of a Combination of *Nauclea latifolia* root and *Acalypha torta* Leave on Haematological Parameters. *IOSR Journal of Biotechnology and Biochemistry*, **3(4)**: 39-42.
17. Kausar M.W., Moeed K., Asif N., Rizwi F and Raza S. (2010). Correlation of Bilirubin with Liver Enzymes in Patients in Falciparum Malaria. *International Journal of Pathology*, **8(2)**:63-67.
18. Kim W.K., Flamm S.L., Di Bisceglie A.M and Bodenheimer jr H.C. (2008). Serum Activity of Alanine aminotransferase (ALT) as an Indicator of Health and Disease. *Hepatology*, **47(4)**:1363-1370.
19. Vyskocilovar E., Szotakova B., Skalova L., Bartikoka H., Hlavacova J and Bousova I. (2013). Age-related Changes in Hepatic Activity and Expression of Detoxification Enzymes in Male Rats. *BioMed Research International*, **2013**: ID 408573, 10 Pages. <http://dx.doi.org/10.1155/2013/408573>.
20. Stefano C., Carlo V.L.C., Eugenio R., Antonella B and Graziella A. (2005). The Effect of Age on the Enzyme Activities of Tryptophan Metabolism along the Kyurenine Pathway in Rats. *Clinica Chimica Acta*, **360(1-2)**:67-80.
21. Testa B and Kraimer D. (2010). The Biochemistry of Drug Metabolism. Conjugations, Consequences of Metabolism, Influencing Factors. *Willey-VCH, Zurich, Switzerland, 1<sup>st</sup> edition*, 2010.
22. Vidal J.D. (2017). The Impact of Age on the Female Reproductive System. *Toxicologic Pathology*, **45**:206-215.
23. Dieterle F., Sistare F., Goodsaid F., Papaluca M., Ozer J.S., Webb C.P. et al.(2010). Renal Biomarker Qualification Submission: A Dialog between the FDA – EMEA and Predictive Safety Testing Consortium. *Nature Biotechnology*, **28**:455-462.
24. Besseling P.J., Pieters T.T., Nguyen I.T.N., de Bree P.M., Willekes N., Dijk A.H. et al. (2021). A Plasma Creatinine and Urea-based Equation to Estimate Glomerular Filtration Rate in Rats. *American Journal of Physiology, Renal Physiology*. <https://doi.org/10.1152/ajprenal.00650.2020>.
25. Taghizadeh M., Ostad S.N., Asemi Z., Mahboubi M., Hajezi S., Sharafati-Chaleshtori R. et al. (2017). Sub-chronic Oral Toxicity of *Cuminum cyminum* L.'s Essential Oil in Female Wistar rats. *Regulatory Toxicology and Pharmacology*, **88**:138-143.
26. Wasan K.M., Najafi S., Wong J., Kwong M and Pritchard P.H. (2001). Assessing Plasma Lipid

Levels, Body Weight, and Hepatic and Renal Toxicity Following Chronic Oral Administration of a Water Soluble Phytostanol Compound, FM-VP4, to Gerbils. *Journal of Pharmacy & Pharmaceutical Sciences* **4**:228-234.

27. Traesel G.K., Menegati S.E.L.T., dos Santos A.C., Souza R.I.C., Boas G.R.V., Justi P.N., Kassuya C.A.L., Argandona E.J.S and Oesterreich S.A. (2016). Oral Acute and Sub-chronic Toxicity Studies of The Oil Extracted from Pequi (*Caryocar brasiliense*, Camb.) Pulp in Rats. *Food and Chemical Toxicology*, **97**:224-231.
28. Olukunle J., Jacobs E.B., Ajayi O., Biobaku K.T and Abatan M. (2015). Toxicological Evaluation of the Aqueous Extract of *Acalypha wilkesiana* in Wistar Albino Rats. *Journal of Complementary and Integrative Medicine*, **12(1)**:53-56.
29. Ogonnia S.O., Mbaka G.O., Nkemhule F.E., Emordi J.E., Okpagu N.C and Ota D.A. (2014). Acute and Subchronic Evaluation of Aqueous Extracts of *Newbouldia laevis* (Bignoniaceae) and *Nauclea latifolia* (Rubiaceae) Roots used Singly or in Combination in Nigerian Traditional Medicines. *British Journal of Pharmacology and Toxicology*, **5(1)**:55-62.
30. Tauheed A.M., Mamman M., Ahmed A., Sani N.A., Suleiman M.M., Sulaiman M.N and Balogun E.O. (2021). Acute, Sub-acute, Sub-chronic and Chronic Toxicity Studies of Four Important Nigerian Ethnomedicinal Plants in Rats. *Clinical Phytoscience*, **7(1)**.  
<https://doi.org/10.1186/s40816-020-00244-2>