

*Original Research Article*

**Vaginal Atresia, Left Unicornuate Unicollis Uterus, Left  
Pelvic Ectopic Single Kidney with Right Inguinal Hernia Containing Ovary in  
a 14 y Old Female: A Rare MRKHS Variant**

**Abstract**

**Introduction:** Vaginal atresia is a component of Mayer–Rokitansky–Küster–Hauser syndrome (MRKHS), which includes variable Mullerian duct abnormalities with normal secondary sexual characteristics. Associated renal anomalies are present in about 30% of cases(1)

**Objective:** To present a rare variant of MRKHS in a 14-y old female with a right ovary in a right inguinal hernia and renal anomalies managed by sigmoid vaginoplasty.

**Case Description:** A 14-year-old girl presented with primary amenorrhea and cyclic abdominal pain one year before, pelvic abdominal swelling, right inguinal hernia, and well-developed secondary sexual characteristics with a single introital opening. Investigations revealed a left ectopic pelvic single kidney, hematometra with left hematosalpinx and right-sided inguinal hernia containing the right ovary with a left ovarian cyst. The first procedure included diagnostic laparoscopy and cystoscopy with the combined repair of the right-sided inguinal hernia and laparoscopic drilling of the left ovarian chocolate cyst. The patient was diagnosed with unicornuate unicollis uterus, left hematosalpinx with complete vaginal atresia associated with a left ectopic pelvic single kidney. One month later, sigmoid

vaginoplasty was done. At the 3-month follow-up, there was a full-thickness neovaginal prolapse which was managed surgically by resection.

**Conclusion:**To our knowledge, this is the first description of this variant of MRKH syndrome association, including vaginal atresia, left unicornuate unicollis uterus with ipsilateral left single pelvic ectopic kidney with right-sided inguinal hernia containing right ovary, in the literature. Renal assessment in cases of vaginal atresia and other mullerian anomalies is mandatory for detecting and managing such anomalies and preserving renal function. Anatomical and functional assessment of the urogenital system is mandatory, and multiple modalities can be integrated to get proper results. Diagnostic laparoscopy and cystoscopy give invaluable information in these cases and can add therapeutic aids.

**Keywords:**MRKHS Variant; Mayer–Rokitansky–Küster–Hauser syndrome; Vaginal atresia.

## **Introduction:**

Vaginal atresia occurs in an estimated 1 in 40,000-50,000 live female births.[1]The defect is often not discovered until adolescence, when primary amenorrhea or abdominal pain from a blocked uterovaginal tract induces a diagnostic evaluation.[2]It is a component of Mayer–Rokitansky–Küster–Hauser syndrome (MRKHS), which includes variable Mullerian duct abnormalities associated with normal secondary sexual characteristics.Two different types of MRKHS have been described; cases with the typical variety(typeA) have symmetric uterine remnants and normal fallopian tubes. Cases with the atypical form (type B) present with asymmetric uterine buds or aberrant development of the fallopian tubes. Multiple abnormalities in various organs or systems are more prevalent in cases with type B.[3]

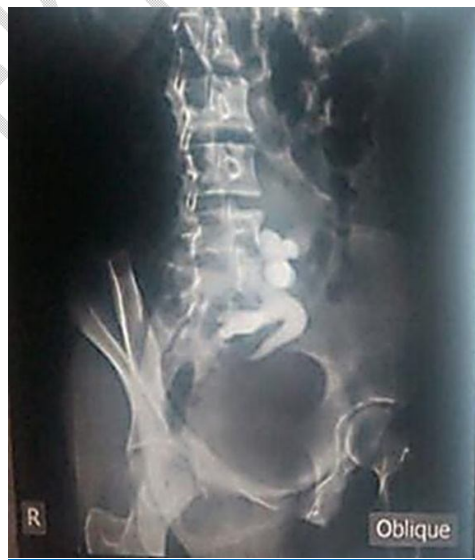Renal anomalies are present most frequently in cases with the type B variety and occur in about 30% of MRKHS cases. These anomalies include unilateral agenesis, horse-shoe kidney, ectopic kidneys, and crossed-fused ectopia. [4]Up to 12 % of cases have skeletal abnormalities, primarily type B instances, such as the Klippel-Feil syndrome, which is characterized by congenital fusion of the cervical vertebra.[5] Duncan proposed the term MURCS association to describe the combination of mullerian duct aplasia, renal aplasia, and cervicothoracicsomite dysplasia.[6]

Leng et al. in 2002 classified congenital vaginal atresia into two types; **Type I:**segmental vaginal agenesis (lower vaginal atresia that shows a normal upper vaginal portion & uterinedevelopment); thus,resulting in a similar presentation of cyclic abdominal pain and amenorrhea alongside a pelvic mass. The hymen has a normal appearance; however, the vagina is entirely absent.**TypeII:**complete vaginal atresia associated with cervical atresia, showing normal development or deformity of the uterine body & with a possible normal endometrial secretory function. [7]

### **Methodology:**

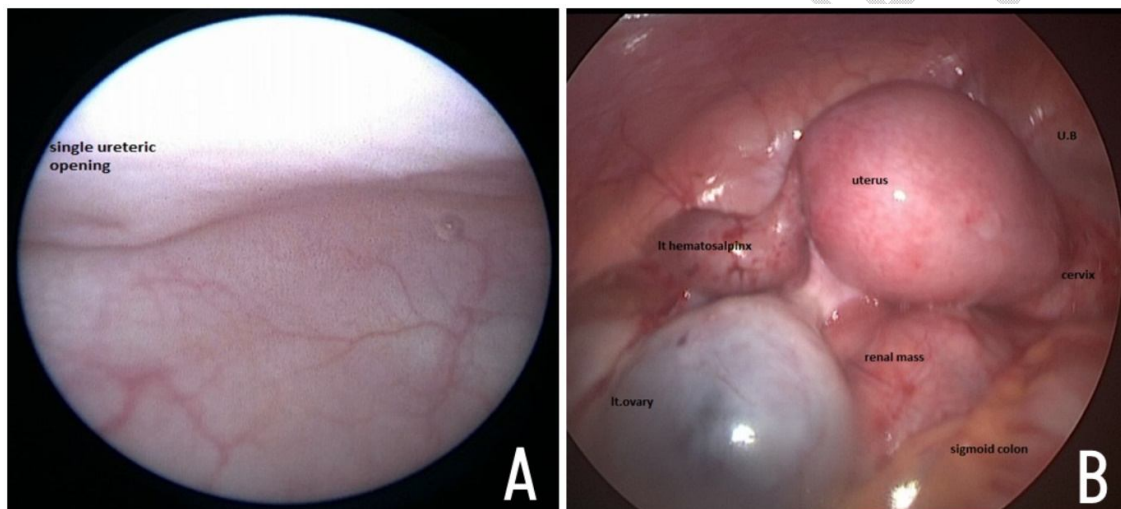
A 14-year-old female presented with primary amenorrhea and cyclic abdominal pain one year before, with intermittent urinary retention. On examination, a pelvic/abdominal swelling was found with a right-sided inguinal hernia containing a palpable gonad. The patient had well-developed secondary sexual characteristics with normal-looking external genitalia. Spreading of labia revealed a urethral opening, a vaginal dimple with a scar of a previous introital incision representing a failed hematometra evacuation trial three months ago, based on a wrong diagnosis of transverse vaginal septum.

Abdominopelvic MRI showed hematometra with left hematosalpinx, pelvic ectopic single kidney opposite L4, L5, and S1 levels with the right ovary in a right-sided inguinal hernia. Workup included Karyotyping, which revealed a 46XX pattern. The endocrine evaluation showed a normal female hormonal profile. The intravenous pyelogram showed a left ectopic pelvic single kidney, single ureter normally inserted into the compressed urinary bladder by a pelvic mass (known to be hematometra) from the left side. ([Fig:1](#))

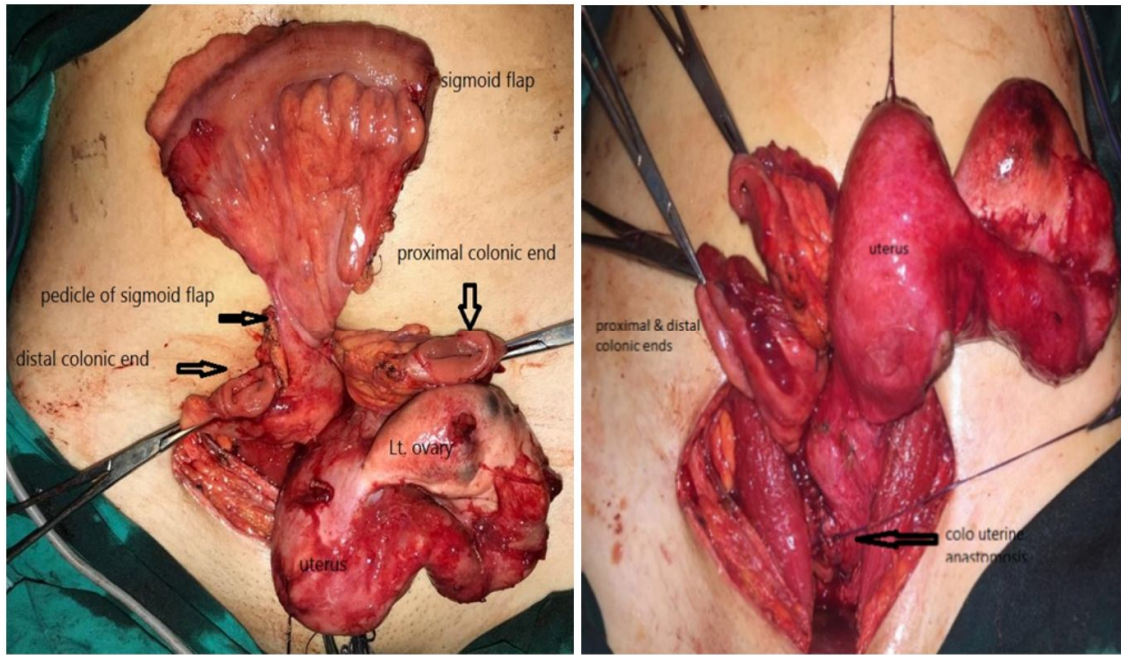


**Figure 1:** Oblique view of IVP showing single ectopic pelvic kidney.

The patient was subjected to a first procedure in the form of diagnostic cystoscopy, which revealed a single ureteric opening with a compressed bladder wall by the distended uterus. Laparoscopy revealed a right inguinal hernia containing the right ovary, which was repaired at that session, absent right fallopian tube, huge left ovarian chocolate cyst due to retrograde menstruation, which was drained laparoscopically, left hematosalpinx, pelvic ectopic single kidney, and unicornuate unicollis hugely distended uterus with no vagina. ([Fig:2,3](#))



**Figure 2:** A- Cystoscopy showing the single ureteric opening; B- Laparoscopy showing retro uterine single



pelvic kidney.

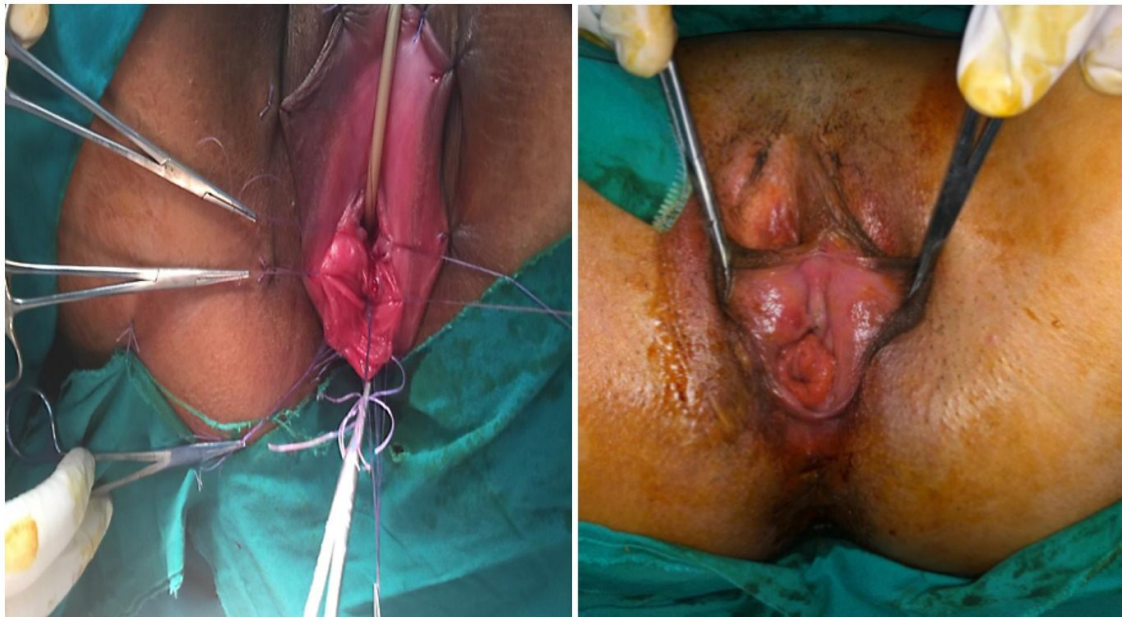
**Figure 3:** Sigmoid flap fashioned to be used as a neovagina.

One month later, the definitive repair was done through combined perineal and Pfannenstiel incisions. The uterus was opened at its lowest part with the evacuation of both hematometra and left hematosalpinx and washed with saline, and sigmoid vaginoplasty was done.

**Follow-up:** At early post-operative follow-up, pelvi-abdominal swelling, cyclic abdominal pain, and urine retention all improved, and the menstruation started one month later and is regular now. There was no reported urological complaints or urinary incontinence with normal urine analysis, pelvi-abdominal ultrasound, and uroflowmetry. Regular surveillance by clinical examination and calibration with Hegar dilators revealed no neovaginal stenosis, neither diffuse nor introital. At the 3-month follow-up, a full-thickness progressive neovaginal prolapse appeared, which did not improve on follow-up. One year after the original surgery, the prolapse was managed surgically by resection of the prolapsed part and re-

anastomosis of the colon to the introitus. [\(Fig:4\)](#) Excised prolapsed part was sent for histopathological examination, which revealed hyperplastic colonic mucosa and submucosal congestion with multiple lymphoid follicles and no neoplastic changes. Our case is still sexually inactive, so neither the quality of sexual life nor the fertility/pregnancy outcomes can be judged.

**Figure 4:** Full thickness neovaginal prolapse and its excision.



#### **Discussion:**

In managing cases of Mullerian anomalies, special attention must be directed to evaluate any associated renal anomalies, which occur in 30% of those patients, e.g., absent kidney unilaterally, which is the most common renal anomaly, ectopic kidney(s), horse-shoe kidneys, and crossed-fused ectopia. [3]

Unicornuate uterus, which occurs from total or near-complete halted development of one of the ducts, accounts for around 20% of all cases of Mullerian abnormalities. Most cases with

the isolated unicornuate uterus are asymptomatic unless the condition is discovered incidentally.[8]In this case, a unicornuate uterus was discovered during diagnostic laparoscopy as the diagnosis was missed initially by both ultrasound and MRI. It has been reported that the sensitivity of ultrasound in diagnosing Mullerian anomalies is as low as 44[9], while MRI is considered the most accurate imaging study for the diagnosis of uterine anomalies, with a sensitivity reaching 92% and specificity approaching 100%. [10]During surgery, the appearance of a laterally deviated, banana-shaped hemiuterus assists in diagnosing the unicornuate uterus. [11]In this case, the diagnosis of the unicornuate uterus without a rudimentary horn was confirmed only during the diagnostic laparoscopy. This emphasizes the significance of performing diagnostic laparoscopy in such cases for proper visualization of pelvic organs. Laparoscopy could also be used for therapeutic purposes; in our case, the right inguinal hernia was repaired, the left ovarian was drilled, and the left ovarian chocolate cyst was removed.

Complications linked with an isolated unicornuate uterus usually affect the future pregnancy outcome. These include preterm labor, first and second-trimester abortions, and intrauterine fetal death [11]. Our case is still not sexually active, so these outcomes cannot be evaluated now.

The unicornuate uterus is more frequently related to renal abnormalities than other types, with a percentage of roughly 40%. Renal agenesis is the most frequently documented anomaly, occurring in 67% of cases.[12] Other less common renal anomalies are ectopic pelvic kidneys, malrotated kidneys, horse-shoe kidneys, and duplicated renal pelvis[11]. In this case, the unicornuate uterus was associated with a solitary ectopic pelvic kidney, with renal agenesis occurring on the same side of tubal agenesis.

The ectopic kidney is defined as a mature kidney that is placed out of the renal fossa.[13]It occurs in approximately 1/2000-3000. It can be smaller, and its ureter joins the bladder in a normal fashion.[14]Upper abdominal,iliac or pelvic locations are the common locations for ectopic kidney, with the most frequent place being the pelvis, with a 55% incidence.[15] The contralateral kidney is abnormal in up to 50% of the cases, and the contralateral renal agenesis occurs in 10%. [16]

Other Mullerian malformations include vaginal duplication, bicornuate uterus and hypoplasia or uterine or vaginal agenesis, transverse vaginal septum, and uterine didelphys.[16]

The association of female phenotype with a vaginal dimple with unilateral inguinal hernia containing a gonad (ovary in our case) could be confused clinically with cases of complete androgen insensitivity syndrome with associated inguinal hernia containing a gonad (testis). The differentiation can be ascertained based on Karyotyping, which is 46 XX in cases of mullerian anomalies with a normal hormonal female profile, detection of normal mullerian structures and the recognition of ovarian tissue by radiologic investigations (US & MRI) and the final confirmation by laparoscopy.

Cystoscopy is also very important in such cases for checking any urinary tract anomaly; in our case, a solitary ureteric orifice was found, and also for tracking the vagina. Further evaluation by IVP was carried out based on this finding.

Additional cardiovascular, respiratory, genital or skeletal systems malformations are commonly seen with Mullerian anomalies. So, a careful general checkup of the patient is important.[16]

To our knowledge, this is the first report of a case of association of vaginal atresia, unicornuate unicollis uterus, ipsilateral pelvic ectopic single kidney and a right inguinal hernia containing

the right ovary in literature after search in Google scholar, PubMed, Medline and Cochrane Database using the keywords; vaginal atresia, single pelvic kidney, unicornuate unicollis uterus, Mullerian.

In 2016, Elmas et al. reported the coexistence of unicornuate uterus and unilateral left pelvic ectopic kidney as a rare case, but without vaginal atresia and with double anatomically normal ureters in a 48-year-old nulliparous woman who was referred to their center suffering from menorrhagia, dyspareunia, and chronic pelvic pain with noneventful other past histories.[17]

The classical intervention for a case of vaginal atresia ranges from the use of serial vaginal dilators to various types of vaginoplasty. In this case, we used vaginal replacement in the form of sigmoid bowel vaginoplasty. No post-operative complications occurred in the short term; however, long-term follow-up with calibration and dilatation, if needed, should be pursued. Neovaginal prolapse, which was presented in our case after three months postoperatively, could probably be due to the non-fixation of neovagina to the abdominal wall. The incidence of neovaginal prolapses is about 2.3%, which is more likely due to missing integration of neovagina into the pelvic floor compared to the native vagina.[18]

**Conclusion:** To our knowledge, this is the first description of this variant of MRKH syndrome association in the literature, including vaginal atresia, left unicornuate unicollis uterus with ipsilateral left single pelvic ectopic kidney with right-sided inguinal hernia containing the right ovary. Renal assessment in cases of vaginal atresia and other mullerian anomalies is mandatory for detecting and managing such anomalies and preserving renal function. Anatomical and functional assessment of the urogenital system is mandatory, and multiple modalities can be integrated to get proper results. Diagnostic laparoscopy and cystoscopy give invaluable information in these cases and can add therapeutic aids.

### Ethical Approval:

As per international standard or university standard written ethical approval has been collected and preserved by the author(s).

### Consent

As per international standard, parental written consent has been collected and preserved by the author(s).

### References:

- [1] Ding JX, Chen LM, Zhang XY, Zhang Y, Hua KQ. Sexual and functional outcomes of vaginoplasty using acellular porcine small intestinal submucosa graft or laparoscopic peritoneal vaginoplasty: A comparative study. *Human Reproduction* 2015;30. <https://doi.org/10.1093/humrep/deu341>.
- [2] Quinn T, Erickson V, Knudson MM. Down's syndrome, precocious puberty, and transverse vaginal septum: An unusual cause of abdominal pain. *J Pediatr Surg* 2001;36. <https://doi.org/10.1053/jpsu.2001.22309>.
- [3] Coran AG, Adzick SS, Krummel T, Caldamone A. *Pediatric Surgery*. 2012. <https://doi.org/10.1016/C2009-0-41746-X>.
- [4] McCann E, Fryer AE, Craigie R, Baillie C, Ba'ath ME, Selby A, et al. Genitourinary malformations as a feature of the Pallister-Hall syndrome. *Clin Dysmorphol* 2006;15. <https://doi.org/10.1097/01.mcd.0000184972.76657.e1>.
- [5] Mitchell W, Przybylski GJ. Klippel Feil Syndrome. *Fractures of the Cervical, Thoracic, and Lumbar Spine* 2022;625–33. <https://doi.org/10.4102/sajr.v6i3.1433>.
- [6] Kumar S, Sharma S. MURCS (Müllerian duct aplasia–renal agenesis–cervicothoracic somite dysplasia): a rare cause of primary amenorrhoea. *Oxf Med Case Reports* 2016;2016:73. <https://doi.org/10.1093/OMCR/OMW022>.
- [7] Leng J, Lang J, Lian L, Huang R, Liu Z, Sun D, et al. Congenital vaginal atresia: report of 16 cases. *Zhonghua Fu Chan Ke Za Zhi* 2002;37.
- [8] Heinonen PK. Clinical implications of the unicornuate uterus with rudimentary horn. *International Journal of Gynecology and Obstetrics* 1983;21. [https://doi.org/10.1016/0020-7292\(83\)90052-8](https://doi.org/10.1016/0020-7292(83)90052-8).
- [9] Troiano RN, McCarthy SM. Müllerian duct anomalies: Imaging and clinical issues. *Radiology* 2004;233. <https://doi.org/10.1148/radiol.2331020777>.

- [10] Báez AB, Ascanio MFdez del C, García CG, Perdomo R, Carrasco MSG. Uterine malformations assessment: MRI vs laparoscopy-hysteroscopy 2010. <https://doi.org/10.1594/ECR2010/C-1251>.
- [11] Reichman D, Laufer MR, Robinson BK. Pregnancy outcomes in unicornuate uteri: a review. *Fertil Steril* 2009;91. <https://doi.org/10.1016/j.fertnstert.2008.02.163>.
- [12] Li S, Qayyum A, Coakley F v., Hricak H. Association of renal agenesis and mullerian duct anomalies. *J Comput Assist Tomogr* 2000;24. <https://doi.org/10.1097/00004728-200011000-00001>.
- [13] Shapiro E, Telegrafi S. 130 - Anomalies of the Upper Urinary Tract. *Campbell-Walsh Urology*, 2016.
- [14] Cinman NM, Okeke Z, Smith AD. Pelvic kidney: associated diseases and treatment. *J Endourol* 2007;21:836–42. <https://doi.org/10.1089/END.2007.9945>.
- [15] Wu HY, Snyder HM. Developmental and Positional Anomalies of the Kidneys. *Ashcraft's Pediatric Surgery*, 2010. <https://doi.org/10.1016/B978-1-4160-6127-4.00054-9>.
- [16] Malek RS, Kelalis PP, Burke EC. Ectopic kidney in children and frequency of association with other malformations. *Mayo Clin Proc* 1971;46.
- [17] Elmas B, Tahir Burak Kadın Sağlığı Eğitim ve Z, Sarıdoğan E, Tavşan S, Kuntay Kokanalı M, Doğanay M, et al. Coexisting unicornuate uterus and pelvic ectopic kidney: a rare case. *Cukurova Medical Journal* 2016;41:411–3. <https://doi.org/10.17826/CUTF.203896>.
- [18] Kondo W, Ribeiro R, Tsumanuma FK, Zomer MT. Laparoscopic Promontofixation for the Treatment of Recurrent Sigmoid Neovaginal Prolapse: Case Report and Systematic Review of the Literature. *J Minim Invasive Gynecol* 2012;19. <https://doi.org/10.1016/j.jmig.2011.12.012>.