

Case study

Diagnostic Clue: Oral Manifestations in a case of Acute Myeloid Leukemia

ABSTRACT

Aims: Many systemic diseases and conditions find manifestations in the oral cavity, which if not promptly diagnosed can have grave consequences. Therefore, the aim of this case report is to stress the importance of an interdisciplinary approach by the periodontist, hematologist, and medical expert to minimize the time to establish diagnosis during the initial presentation of Acute myeloid leukemia (AML), which in this case were oral manifestations.

Presentation of case: This case report describes a 15 year old female who presented with enlarged gums with pain and bleeding. Diagnostic workup included complete blood count with differential leukocyte count followed by bone marrow biopsy and cytochemistry. These tests aided in diagnosing the condition as acute myeloid leukemia.

Discussion: Oral signs of leukemia include gingival enlargement, which appears bluish red in color and tends to bleed on slightest provocation. Immature leukocytes in the gingival tissues and chemotherapy induced immunosuppression makes the patients more vulnerable to tissue breakdown and secondary infections, all of which were evident in the present case.

Conclusion: Both, oral health care and medical professionals should work in sync in order to carry out prompt diagnosis and render timely treatment for the underlying pathology.

Keywords: Leukemia, gingival, oral manifestations, case report.

1. INTRODUCTION

Oral cavity reflects the overall health of an individual. Several systemic illnesses, including hematologic disorders, manifest themselves in the oral cavity. These manifestations may or may not be pathognomonic, but they are early signs of the underlying illness and can lead to an early diagnosis and treatment. Leukemia is one such malignancy, accounting for approximately 30% of all malignancies identified in children under the age of 15 years [1]. It is a hematological disease that develops from hematopoietic stem cells [2] and is caused by uncontrolled clonal neoplastic proliferation of myeloid precursor cells [3]. It is defined by impaired differentiation and failure of precursor cell maturation, which results in the accumulation of blasts in the bone marrow and the suppression of normal hematopoiesis, resulting in a lack of mature leukocytes, erythrocytes, and platelets.

2. PRESENTATION OF CASE

This case is reported in accordance with CAsEReports (CARE) guidelines 2013 checklist [4]. According to the 2017 Modified Kuppaswamy Scale, a 15-year-old female patient from lower socioeconomic strata, presented to Department of Periodontology at a tertiary care hospital with the chief complaint of swollen gums that had been present for a fortnight and was accompanied by pain and bleeding. According to the patient's present medical history, she was seemingly asymptomatic two weeks prior and only had gingival swelling, which later led to gingival hemorrhage and was accompanied by a dull aching pain while brushing. Her condition progressively worsened over few days, eventually leading to spontaneous gingival bleeding during mastication. The pain was gradual in beginning, persistent, dull aching, non-radiating, and aggravated during gingival bleeding. Additionally, a history of generalized malaise and dyspnoea on exertion was reported. Her prior medical records revealed that the patient had previously consulted physician with the similar primary complaints. Patient was then referred to dental office without having undergone any initial clinical or hematological evaluation. Her ancestry did not disclose anything noteworthy. The pedigree study in current case report did not produce any notable findings. Patient's personal history revealed that she avoided using tooth brush and used only fingers with dentrifice for daily oral hygiene. The duration between first reporting of her condition and subsequent evaluation was approximately one month.

Patient appeared frail during general examination. Her BMI was 17 kg/m^2 , which according to the Centers for Disease Control and Prevention (CDC) guidelines for children and teenagers between the ages of 02 and 20 is considered to be underweight with 3rd percentile (39.46 kg). Patient was febrile and had pale skin, cheeks, nail beds, and palpebral conjunctiva. Cervical lymphadenopathy was present upon extraoral evaluation. Intraoral inspection revealed generalized reddish blue discoloration of the gingivae with pronounced scalloping and rolled out margins. In relation to the maxillary arch, the gingival tissues were soft and edematous with loss of stippling and in the mandibular arch, it was fibrotic on palpation. According to Bokenkamp, [5] there was generalized Grade III gingival enlargement (Fig1). Ulceration was discerned on the dorsal and ventral aspect of the tongue. Periodontal probing was avoided due to unusual clinical presentation.

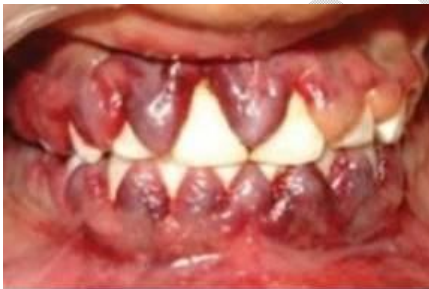

Fig 1 Gingival enlargement, covering 2/3rd crown structure

Complete blood count was advised and the results revealed erythrocytopenia, severe thrombocytopenia, and leukocytosis (Table 1). Patient was immediately hospitalized and further investigations were carried out. Leukocytosis with abundant blast cells that had irregular nuclear margins, prominent nucleoli, and anisopoikilocytotic, microcytic erythrocytes were found in the peripheral blood smear (Fig 2). Bone marrow biopsy revealed 90% hypercellularity with predominant sheets of blast cells (Fig 3). The diagnosis of acute myeloid leukemia (AML) without maturation was made on the basis of morphologic characteristics, cytochemistry, especially myeloperoxidase (or Sudan black B) and non-specific esterase staining, and bone marrow biopsy.

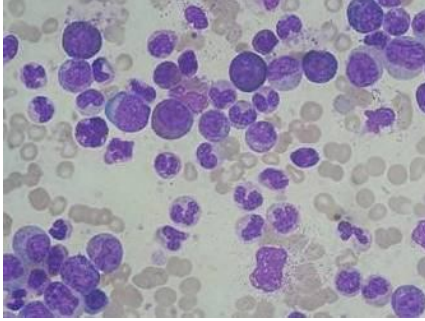


Fig 2. Peripheral blood smear

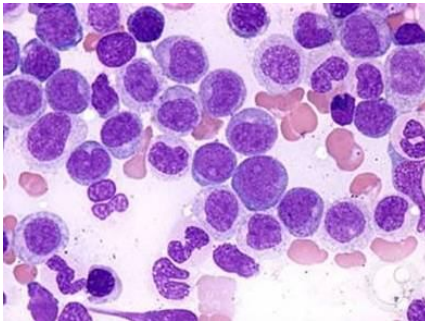


Fig. 3 Bone marrow biopsy

Since the disease is linked to substantial morbidity and mortality, induction chemotherapy was initiated after patient counseling and informed consent. Oral prophylaxis was delayed for the patient because dental intervention could worsen the condition and cause an exacerbation of acute symptoms. However, for chemical plaque control, twice-daily rinsing with 0.12% chlorhexidine gluconate was introduced as part of oral hygiene guidelines. Oral ulcerations were treated palliatively with topical 2% viscous lidocaine. Other oral care instructions included, eating soft foods, avoiding crusty foods which may cause ulcerations, keeping the lips moist to prevent dry or cracked lips. Use of dental floss or toothpicks was completely avoided. Patient was advised to apply ice or pressure with the help of moist cotton for at least 5 mins to stop gingival bleeding.

Despite providing prompt medical attention, the patient's situation worsened. After a week of induction chemotherapy, the blood tests revealed decreasing levels of neutrophils, erythrocytes, and platelets (Table 1).

Table1 Complete Blood Count

	Patient Values on admission	Patient Values after one week	Normal Values
Total Leukocyte count	107.69 × 10 ³ /mm ³ , 95% blasts	227 × 10 ³ /mm ³ 95% blasts Neutrophils-10% Lymphocytes-90% Eosinophils-0% Monocytes-0%	4.5–11.0 × 10 ³ /mm ³
Erythrocyte Count	1.67 × 10 ⁶ /mm ³	1.46 × 10 ⁶ /mm ³	3.8–4.8 × 10 ⁶ /mm ³
Hemoglobin	7.3 g/dl	5.2 (g/dl)	12–15 g/dl
Platelet count	0.16 × 10 ³ /mm ³	0.16 × 10 ³ /mm ³	1.5–4.5 × 10 ³ /mm ³

Additionally, the clinical appearance of the oral lesions worsened. There were formations of crevices at the junction of enlarged gingivae and adjoining tooth surfaces (Fig 4). The gingival enlargements almost reached the occlusal surfaces of the teeth and interfered with mastication. On the dorsum of tongue as well as the labial, buccal and palatal mucosae, numerous petechiae and ulcerations indicative of mucositis were noticed. These debilitating lesions did not resolve and further incapacitated the patient. During course of medical treatment, patient succumbed to the disease due to respiratory arrest.

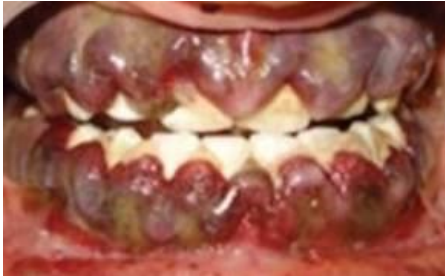

Fig.4 Worsening of gingival enlargement

3. DISCUSSION

AML has an annual incidence of fewer than 1 per 100000 people under the age of 30, according to the Indian Council of Medical Research Consensus Statement [6]. It is regarded as an aggressive malignancy that, if ignored, usually results in mortality within a few weeks or months. AML has been linked to genetic predisposition, radiation, chemicals, work exposures, and medications like alkylating agents and topoisomerase II inhibitors. However, most cases of AML are idiopathic. Considering the recent classification by World Health Organization in 2017, the reported case falls in the category of AML not otherwise specified (NOS), i.e. AML without maturation [7] which corresponds to M1 of French American British classification on the basis of morphological criteria [8].

Patient in this instance had widespread, generalized grade III gingival enlargement. Inflammatory enlargement, drug-induced enlargement, enlargement secondary to syndromes like Ramon Syndrome, Rutherford Syndrome, neoplastic enlargements, and enlargements as a symptom of systemic illnesses or conditions are all possible differential diagnoses for this condition.

In 15% to 80% of leukemia patients, oral symptoms occur more frequently in acute (65%) than in chronic (30%) leukemias [9]. Additionally, patients with acute leukemias are found to have greater prevalence of thrombocytopenia than those with chronic leukemia [10]. Oral manifestations were the initial clinical indicators of AML in 72.72% of cases [11]. Petechiae, ulceration, and gingival enlargement were the most frequent initial diagnostic oral manifestations of leukemia in a ten-year-old retrospective analysis of 155 patients [12]. Due to decreased erythrocytes, patients with AML frequently present with oral ulcerations, bluish or pale mucous membranes, and even regions of tissue necrosis. The platelet count in this instance was 16000 mm^3 which is the cause of spontaneous gingival bleeding which usually can occur when the count falls between 25,000 and 60,000 mm^3 .

Immature leukocytes enter the gingival tissues via the microcirculation, causing enlargement of gingivae which in turn harbors bacterial plaque and causes an exaggerated inflammatory reaction. The continuous trafficking of such myeloid cells in specialized post-capillary venules which are typically present in human gingivae allows for egress of these cells from the microcirculation into the gingival connective tissues at the sites of inflammation as in gingivitis or periodontitis [13]. According to ecological plaque hypothesis by PD Marsh in 1994, changes in the environment causes a shift in the bacterial flora towards the putative periodontal pathogens [14]. This disrupts the delicate balance between the host's immune

reaction to the microbial challenge and the resulting destructive periodontal disease. Chemotherapy induced immunosuppression makes the patients more vulnerable to secondary bacterial, viral, and fungal infections.

Despite the wide variety of treatment options available, AML has a high rate of morbidity and mortality and is responsible for about 4% of all cancer-related fatalities [15]. Therefore, the time taken for immediate diagnosis of such malignancies is crucial. Accessibility to healthcare services, the clinical presentation of the disease, the patient's age, and the degree of suspicion by a primary care physician may all be major factors in diagnosis delays. Main causes for delays in diagnosis may include accessibility to health care services, clinical presentation of the disease, patient's age, level of suspicion by a primary care physician [16]. The main causes of early mortality in patients with AML include infection, tumor lysis syndrome, leukostasis, and disseminated intravascular coagulation [17]. Thus, early diagnosis, prompt referral to the concerned specialist and appropriate treatment are indispensable for increasing the life span and also improving the quality of life.

The genetic basis of this condition cannot be overlooked. It's possible that the sufferer was a 'proband' because of inherited gene mutations and hence genetic counselling of family members is of utmost importance. The same can be thoroughly understood only by assessing family members using novel modalities like next generation sequencing / whole genome sequencing. To lessen a potentially fatal situation, it is important to discuss the likelihood of inheriting the disease and possible methods to reduce the risk.

4. CONCLUSION

Patients frequently seek dental treatment for oral conditions in the mistaken belief that the illnesses are local in nature. Alternatively, many patients prefer to go to the medical practitioners seeking palliative care. Therefore, the oral manifestations should be clearly identifiable by both the dental as well as medical professionals to arrive at a proper and early diagnosis. An interdisciplinary approach by the periodontist, hematologist, and medical expert is required in order to minimize the time frame to establish diagnosis during initial presentation itself, by thorough investigations leading to prompt diagnosis. Due to the high mortality rate associated with AML, unwarranted delays in diagnosis, as happened in this instance, could be avoided by interdisciplinary approach. This also requires health seeking behavior of patient themselves for professional care well in time. Patients should be educated about the importance of maintaining optimal oral hygiene with atraumatic oral hygiene practices, all of which will go a long way in improving the overall prognosis, life expectancy and oral health quality of life. Even in situations where the patient's family background is not particularly noteworthy, genetic counseling should be taken into consideration.

CONSENT (WHERE EVER APPLICABLE)

Written informed consent was obtained from the patient's family for publication of this case report and accompanying images. A copy of the written consent is available for review by the Editorial office/Chief Editor/Editorial Board members of this journal.

ETHICAL APPROVAL (WHERE EVER APPLICABLE)

Ethical approval was obtained from the Institutional Ethical committee safeguarding the patient's privacy.

REFERENCES

1. Puumala SE, Ross JA, Aplenc R, Spector LG. Epidemiology of childhood acute myeloid leukemia. *Pediatr Blood Cancer*. 2013;60:728-733. doi:10.1002/pbc.24464
2. Fernandes KS, Gallottini M, Castro T, Amato MF, Lago JS, Silva PHB. Gingival leukemic infiltration as the first manifestation of acute myeloid leukemia. *Spec. Care Dent*. 2018;38:160–162. doi: 10.1016/j.otohns.2010.04.010
3. Lupi SM, Baena ARY, Cervino G.; Todaro, C.; Rizzo, S. Long-Term Effects of Acute Myeloid Leukemia Treatment on the Oral System in a Pediatric Patient. *Open Dent. J*. 2018;12:230–237. doi: 10.2174/1874210601812010230
4. Gagnier JJ, Kienle G, Altman DG, Moher D, Sox H, Riley D; CARE Group. The CARE Guidelines: Consensus-based Clinical Case Reporting Guideline Development. *Glob Adv Health Med*. 2013 Sep;2(5):38-43. doi: 10.7453/gahmj.2013.008
5. Böenkamp A, Bohnhorst B, Beier C, Albers N, Offner G, Brodehl J. Nifedipine aggravates cyclosporine A-induced gingival hyperplasia. *Pediatr Nephrol*. 1994;8:181–185. doi: 10.1007/BF00865474
6. Indian Council of Medical Research. Consensus document for management of Acute Myeloid Leukemia. 2019 https://main.icmr.nic.in/sites/default/files/guidelines/Acute_Myeloid_Leukemia.pdf
7. Arber DA, Brunning RD, Le Beau MM, Swerdlow SH, Campo E, Harris NL. Acute myeloid leukaemia and related precursor neoplasms. WHO classification of tumours of haematopoietic and lymphoid tissues. 2017 Revised 4th ed. IARC Press; Lyon, France: 130–171.
8. Bennett JM, Catovsky D, Daniel MT, et al: Proposed revised criteria for the classification of acute myeloid leukemia: A report of the French-American-British

- Cooperative Group. *Ann Intern Med.* 1985;103:620-625 doi:10.7326/0003-4819-103-4-620.
9. Bodey GP. Oral Complications of the Myeloproliferative Diseases. *J Postgrad Med.* 1971;49:115-121. doi: 10.1902/jop.2004.75.3.483
 10. Hou GL, Huang JS, Tsai CC. Analysis of oral manifestations of leukemia: a retrospective study. *Oral Dis* 1997 Mar;3(1):31-8. doi: 10.1111/j.1601-0825.1997.tb00006.x
 11. Reyna Aguilar Quispe , Elizabeth Marques Aguiar Claudia Teresa de Oliveira , Ana Cristina Xavier Neves , Paulo Sérgio da Silva Santos. Oral manifestations of leukemia as part of early diagnosis. *Hematol Transfus Cell Ther.* 2022 Jul-Sep;44(3):392-401. doi: 10.1016/j.htct.2021.08.006
 12. Lynch MA, Ship I. Initial oral manifestations of leukemia. *J Am Dent Assoc.* 1967 Oct;75(4):932-940. doi:10.14219/jada.archive.1967.0301
 13. Shankarapillai, R.; Nair, M.A.; George, R.; Walsh, L.J. Periodontal and gingival parameters in young adults with acute myeloid leukaemia in Kerala, South India. *Oral Health Prev Dent.* 2010; 8:395–400.
 14. PD Marsh. Microbial Ecology of Dental Plaque and its Significance in Health and Disease. *Adv Dental Res.* 1994;Jul8(2):263-271.doi:10.1177/08959374940080022001
 15. Chowdhri K, Tandon S, Lamba AK, Faraz F. Leukemic gingival enlargement: A case report and review of literature. *J Oral Maxillofac Surg Med Pathol.* 2018;22,:S77–S81. doi: 10.4103/jomfp.JOMFP_205_17
 16. Dang-Tan T, Franco EL. Diagnosis delays in childhood cancer: A review. *Cancer.* 2007 Aug 15;110(4):703-713. doi:10.1002/cncr.22849
 17. Lins MM, Amorim M, Vilela P, Viana M, Ribeiro RC, Pedrosa A, et al. Delayed diagnosis of leukemia and association with morbidity and mortality in children in Pernambuco, Brazil. *J Pediatr Hematol Oncol.* 2012 Oct;34(7):e271-e276. doi:10.1097/MPH.0b013e3182580bea

ABBREVIATIONS

Acute myeloid leukemia (AML)