

## Original Research Article

# ROLE OF SUPRACHOROIDAL ANTI-VEGF INJECTIONS IN RECALCITRANT SEROUS PIGMENT EPITHELIUM DETACHMENT

### ABSTRACT

Retinal pigment epithelial detachments (PEDs) are characterized by separation between the RPE and the inner most aspect of Bruch's membrane. Many chorioretinal diseases can lead to pigment epithelial detachment of which most common is age related macular degeneration. PEDs can be classified as drusenoid, serous, vascularized, or fibrovascular type.

Currently serous PED has not shown much response to treatment, so no specific treatment guidelines are established. Whereas vascularized PEDs, have several treatment options such as anti-Vascular endothelial growth factor (VEGF) therapy, laser photocoagulation, photodynamic therapy (PDT), intravitreal steroids.

However we report an original study of thirty patients who were diagnosed with serous pigment epithelial detachment on Spectral domain optical coherence tomography and fundus fluorescence angiography. All the patients presented to our outpatient department with chief complaint of diminution of vision, central/paracentral scotoma and metamorphopsia.

All of whom underwent treatment with suprachoroidal anti VEGF (bevacizumab). All the patients were followed for a period of 8 weeks. BCVA and amsler grid assessment was recorded on 3<sup>rd</sup> day, 1<sup>st</sup> week, 2<sup>nd</sup> week, 4<sup>th</sup> week, 6<sup>th</sup> week and 8<sup>th</sup> week. Post injection SD-OCT macular scan was performed on 4<sup>th</sup> and 8<sup>th</sup> week. Functional improvement was reported by all patients. All the patients had reduced size and height of PED in SD-OCT. Thus, our result indicates that suprachoroidal bevacizumab is an efficacious treatment for serous PED.

KEY WORDS: serous PED, suprachoroidal, anti VEGF.

Comment [A1]: Can we make this structured abstract

### INTRODUCTION

Pigment epithelium detachment (PED) is the separation between the monolayer retinal pigment epithelium and underlying Bruch's membrane.<sup>1</sup> The prevalence is highest in patients with neovascular Age-Related Macular Degeneration (nAMD). Other ocular conditions like Idiopathic Central Serous Chorioretinopathy (CSCR), polypoidal choroidal vasculopathy (PCV) and Vogt Koyanagi Harada syndrome (VKH) may present along with PEDs.<sup>2</sup> PEDs have also been reported in some systemic conditions like infections, autoimmunity, lymphoma, leukemia and renal disorders.<sup>3</sup>

The exact pathology of PED is unknown and several contributing mechanisms have been proposed for their development. The most acceptable theory states that due to progressive deposition of metabolic waste products like lipids, cholesterol esters, triglycerides and fatty acids in Bruch's membranes, normal retino-choroidal flow is hampered and fluid gets accumulated

beneath the RPE leading to the structural splitting. Based on their contents they are classified into serous, drusenoid and hemorrhagic, although, simultaneously co-existence of more than one type is not uncommon.<sup>4</sup>

Clinically, a patient of PED generally presents with sub-acute blurring of vision, metamorphopsia or scotoma in the central visual field. The diagnosis of the PED is made on fundus examination combined with multimodal imaging techniques.<sup>4</sup>

The treatment of PED has always remained a challenge. Strategies like Verteporfin photodynamic therapy (PDT), laser photocoagulation and intravitreal anti-vascular endothelial growth factors (VEGFs) which have been used for managing vascularized PED, however, these strategies have otherwise proven ineffective for isolated serous PED.

Comment [A2]: Pl give citation

For management of such recalcitrant cases various novel techniques have been tried and one of them is injecting anti-VEGFs into suprachoroidal space (SCS). The SCS is the potential space between the sclera and choroid. The recent advancements in imaging techniques have made its in vivo examination possible via Optical coherence tomography (OCT).<sup>6</sup> Various studies have demonstrated that drugs injected into the SCS rapidly diffuse into the vitreous cavity, bypassing the risks of intraocular penetration.<sup>7</sup> Hence, the rationale of injecting anti-VEGF into SCS, targeting the hyper permeable choroid in patients of recalcitrant serous PED appears promising.

Therefore, the authors report a study of thirty patients for management of recalcitrant PED by injecting anti-VEGF into supra choroidal space. There were 22 males and 8 female patient in the age group of 27 to 50 years.

Comment [A3]: Pl give your rationale

## Methods

All the patients presented to us with the complaint of blurred vision in the affected eye for approximately past a year which was subacute in onset, non progressive. Many patients also complained of associated scotoma in the central field.

All patients had taken treatment in the form of one or two doses of intravitreal anti-VEGF ranibizumab at some other centre, but no improvement was noted in due course of time. On Amsler grid, metamorphopsia was noted. Dilated fundus examination revealed a well-defined dome shaped elevation of the retina at the macula. Neither haemorrhages nor drusen were associated with it. Diagnosis was confirmed on spectral domain-OCT a small zone of RPE elevation with some subretinal fluid at macula was appreciated which confirmed the diagnosis of serous PED. Keeping in mind the previous treatment history of the patient, the diagnosis of recalcitrant serous PED was made.

Patients were subjected to treatment with two doses of 0.1 ml of suprachoroidal anti VEGF (bevacizumab) at monthly interval through an indigenously designed device (patent for which has been applied for) which penetrates the sclera to reach upto the suprachoroidal space but not deeper. The suprachoroidal space is highly vascular; thus a smaller molecule like ranibizumab (molecular weight 48 KDa) if injected carries the risk of being washed away. Bevacizumab was chosen because it has higher molecular weight (149 kDa) being a complete antibody so less chances of losing it in the circulation

Comment [A4]: Kindly give details

Patients were followed up on 3rd day, 7th day, 2nd week, 4th week, 6th week and 8th week from first injection. All patients showed improvement in BCVA from the 7th day after the first injection. Symptoms of metamorphopsia and scotoma also started resolving by 2nd week.

Comment [A5]: Start under results heading

On fundus examination reduction in the size of PED was noted from the 2nd week post injection, with only some pigmentary disturbance in the subfoveal area. OCT was repeated for all the patients at 6th week of follow up, which revealed decrease in height and size of PED; although some disorganization of inner retinal layers was noticeable nasal to fovea. Patient was given Amsler grid to monitor the metamorphopsia on daily basis. Six weeks post injection the vision further improved with only slight metamorphopsia noted on Amsler grid. On subsequent monthly follow up visits, all patients improved remarkably.

Comment [A6]: How you interpret this finding

Comment [A7]: Add the values

All the patients were subjected to treatment with two doses of 0.1 ml of suprachoroidal anti VEGF (bevacizumab) at monthly interval through an indigenously designed device (patent for which has been applied for) which penetrates the sclera to reach upto the suprachoroidal space but not deeper.

Patients were followed up on 3<sup>rd</sup> day, 7<sup>th</sup> day, 2<sup>nd</sup> week, 4<sup>th</sup> week, 6<sup>th</sup> week and 8<sup>th</sup> week from first injection. All patients showed improvement in BCVA from the 7<sup>th</sup> day after the first injection. Symptoms of metamorphopsia and scotoma also started resolving by 2<sup>nd</sup> week. (Table I and II)

Comment [A8]: How you interpreted this?

On fundus examination reduction in the size of PED was noted from the 2<sup>nd</sup> week post injection, with only some pigmentary disturbance in the subfoveal area. OCT was repeated for all the patients at 6<sup>th</sup> week of follow up, which revealed decrease in height and size of PED. (Figure I, II, III, IV)

Comment [A9]: Reframe the sentence repetition

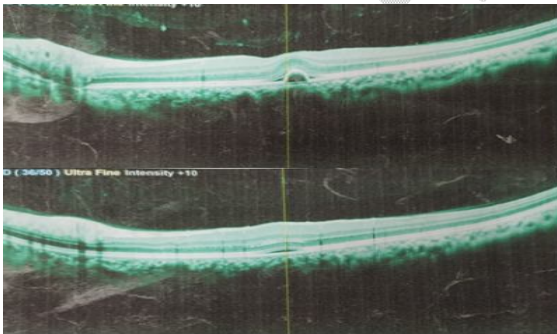


Figure I: Pre and post injection OCT after 2 doses of suprachoroidal Anti VEGF at 6th week of follow up showing complete resolution of serous PED in first patient.

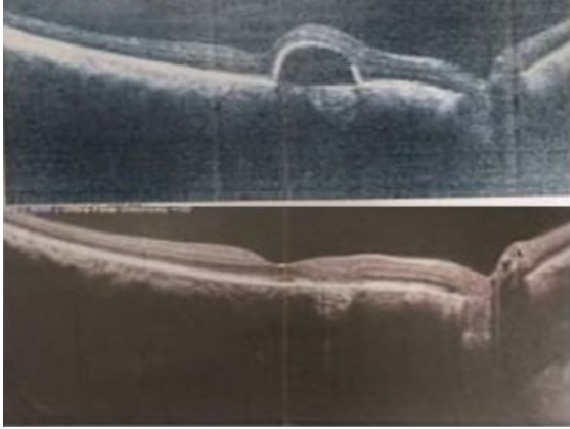


Figure II: Pre and post injection OCT after 2 doses of suprachoroidal Anti VEGF at 6th week of follow up showing complete resolution of serous PED in second patient.

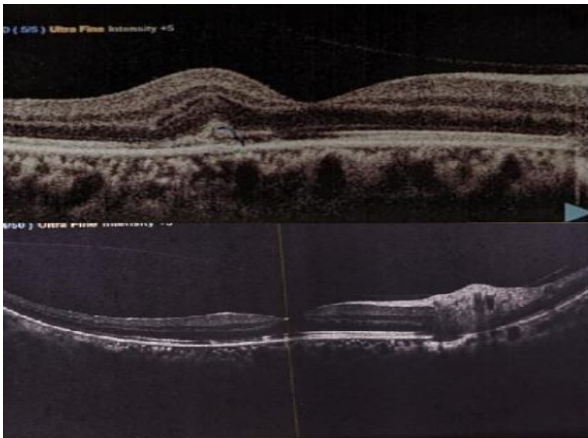


Figure III: Pre and post injection OCT after 2 doses of suprachoroidal Anti VEGF at 6th week of follow up showing complete resolution of serous PED in third patient.

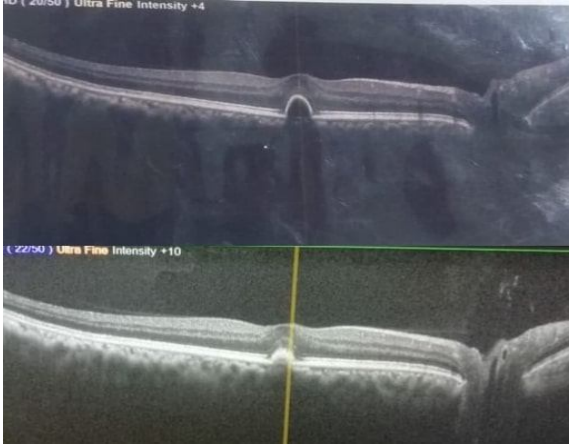

Figure IV: Pre and post injection OCT after 2 doses of suprachoroidal Anti VEGF at 6th week of follow up showing complete resolution of serous PED in forth patient.

No floaters were experienced which is a common complaint in the intravitreal injections. RPE tears which are dreadful complication in PED patients post intravitreal anti-VEGF, were not reported in any of the cases post suprachoroidal injections. None of the patient showed any sign of ocular infection, raised IOP, vitritis, vitreous haemorrhage or cataract.

Sr. No	Pre injection BCVA (n=30)	Post injection BCVA (n=30)					
		3rd day	7th day	2nd week	4th week	6th week	8th week
1	6/36	6/36	6/24	6/24	6/18	6/18	6/12
2	6/24	6/24	6/18	6/18	6/12	6/12	6/9
3	6/24	6/24	6/18	6/18	6/12	6/9	6/9
4	6/18	6/18	6/18	6/18	6/12	6/12	6/12
5	6/18	6/18	6/18	6/18	6/12	6/9	6/6
6	6/24	6/24	6/18	6/12	6/12	6/9	6/6
7	6/24	6/24	6/18	6/18	6/12	6/9	6/9
8	6/18	6/18	6/18	6/18	6/12	6/12	6/12
9	6/24	6/24	6/24	6/18	6/12	6/12	6/9
10	6/36	6/36	6/24	6/24	6/18	6/18	6/12
11	6/36	6/24	6/18	6/12	6/12	6/9	6/6
12	6/24	6/24	6/18	6/12	6/9	6/9	6/12
13	6/18	6/18	6/18	6/18	6/12	6/12	6/12
14	6/36	6/36	6/24	6/24	6/18	6/18	6/12
15	6/24	6/24	6/18	6/18	6/12	6/9	6/9

16	6/18	6/18	6/18	6/18	6/12	6/9	6/6
17	6/24	6/24	6/18	6/18	6/12	6/12	6/9
18	6/24	6/24	6/18	6/12	6/12	6/9	6/6
19	6/18	6/18	6/18	6/12	6/12	6/12	6/6
20	6/36	6/36	6/24	6/24	6/18	6/18	6/12
21	6/18	6/18	6/18	6/18	6/12	6/12	6/12
22	6/36	6/24	6/24	6/24	6/18	6/12	6/9
23	6/24	6/24	6/18	6/18	6/12	6/9	6/9
24	6/24	6/24	6/18	6/12	6/12	6/9	6/6
25	6/24	6/24	6/18	6/18	6/12	6/12	6/9
26	6/24	6/24	6/18	6/18	6/9	6/9	6/6
27	6/18	6/18	6/18	6/18	6/12	6/9	6/6
28	6/24	6/24	6/18	6/12	6/12	6/9	6/6
29	6/24	6/24	6/18	6/18	6/12	6/9	6/6
30	6/24	6/24	6/18	6/18	6/12	6/12	6/9

Comment [A10]: Show p value

Table I: Pre and post injection BCVA in patients diagnosed of recalcitrant serous PED treated with suprachoroidal anti VEGF

	Pre injection LogMAR BCVA(n=30)	LogMAR BCVA Post injection (n=30)					
		3rd day	7th day	2nd week	4th week	6th week	8th week
1	0.78	0.78	0.6	0.6	0.48	0.48	0.3
2	0.6	0.6	0.48	0.48	0.3	0.3	0.17
3	0.6	0.6	0.48	0.48	0.3	0.17	0.17
4	0.48	0.48	0.48	0.48	0.3	0.3	0.3
5	0.48	0.48	0.48	0.48	0.3	0.17	0
6	0.6	0.6	0.48	0.3	0.3	0.17	0
7	0.6	0.6	0.48	0.48	0.3	0.17	0.17
8	0.48	0.48	0.48	0.48	0.3	0.3	0.3
9	0.6	0.6	0.6	0.48	0.3	0.3	0.17
10	0.78	0.78	0.6	0.6	0.48	0.48	0.3
11	0.78	0.6	0.48	0.3	0.3	0.17	0
12	0.6	0.6	0.48	0.3	0.17	0.17	0.3
13	0.48	0.48	0.48	0.48	0.3	0.3	0.3
14	0.78	0.78	0.6	0.6	0.48	0.48	0.3
15	0.6	0.6	0.48	0.48	0.3	0.17	0.17
16	0.48	0.48	0.48	0.48	0.3	0.17	0
17	0.6	0.6	0.48	0.48	0.3	0.3	0.17
18	0.6	0.6	0.48	0.3	0.3	0.17	0
19	0.48	0.48	0.48	0.3	0.3	0.3	0
20	0.78	0.78	0.6	0.6	0.48	0.48	0.3

21	0.48	0.48	0.48	0.48	0.3	0.3	0.3
22	0.78	0.6	0.6	0.6	0.48	0.3	0.17
23	0.6	0.6	0.48	0.48	0.3	0.17	0.17
24	0.6	0.6	0.48	0.3	0.3	0.17	0
25	0.6	0.6	0.48	0.48	0.3	0.3	0.17
26	0.6	0.6	0.48	0.48	0.17	0.17	0
27	0.48	0.48	0.48	0.48	0.3	0.17	0
28	0.6	0.6	0.48	0.3	0.3	0.17	0
29	0.6	0.6	0.48	0.48	0.3	0.17	0
30	0.6	0.6	0.48	0.48	0.3	0.3	0.17
Mean	0.604	0.592	0.504	0.458	0.321333	0.259	0.146667

Comment [A11]: Pvalue

Table II: Pre and post injection LogMAR BCVA in patients diagnosed of recalcitrant serous PED treated with suprachoroidal anti VEGF

	Pre injection LogMAR BCVA(n=30)	LogMAR BCVA Post injection (n=30)					
		3rd day	7th day	2nd week	4th week	6th week	8th week
1	0.78	0.78	0.6	0.6	0.48	0.48	0.3
2	0.6	0.6	0.48	0.48	0.3	0.3	0.17
3	0.6	0.6	0.48	0.48	0.3	0.17	0.17
4	0.48	0.48	0.48	0.48	0.3	0.3	0.3
5	0.48	0.48	0.48	0.48	0.3	0.17	0
6	0.6	0.6	0.48	0.3	0.3	0.17	0
7	0.6	0.6	0.48	0.48	0.3	0.17	0.17
8	0.48	0.48	0.48	0.48	0.3	0.3	0.3
9	0.6	0.6	0.6	0.48	0.3	0.3	0.17
10	0.78	0.78	0.6	0.6	0.48	0.48	0.3
11	0.78	0.6	0.48	0.3	0.3	0.17	0
12	0.6	0.6	0.48	0.3	0.17	0.17	0.3
13	0.48	0.48	0.48	0.48	0.3	0.3	0.3
14	0.78	0.78	0.6	0.6	0.48	0.48	0.3
15	0.6	0.6	0.48	0.48	0.3	0.17	0.17
16	0.48	0.48	0.48	0.48	0.3	0.17	0
17	0.6	0.6	0.48	0.48	0.3	0.3	0.17
18	0.6	0.6	0.48	0.3	0.3	0.17	0
19	0.48	0.48	0.48	0.3	0.3	0.3	0
20	0.78	0.78	0.6	0.6	0.48	0.48	0.3
21	0.48	0.48	0.48	0.48	0.3	0.3	0.3
22	0.78	0.6	0.6	0.6	0.48	0.3	0.17

23	0.6	0.6	0.48	0.48	0.3	0.17	0.17
24	0.6	0.6	0.48	0.3	0.3	0.17	0
25	0.6	0.6	0.48	0.48	0.3	0.3	0.17
26	0.6	0.6	0.48	0.48	0.17	0.17	0
27	0.48	0.48	0.48	0.48	0.3	0.17	0
28	0.6	0.6	0.48	0.3	0.3	0.17	0
29	0.6	0.6	0.48	0.48	0.3	0.17	0
30	0.6	0.6	0.48	0.48	0.3	0.3	0.17
Mean	0.604	0.592	0.504	0.458	0.321333	0.259	0.146667

Comment [A12]: P value

Table III: Pre and post injection LogMAR BCVA in patients diagnosed of recalcitrant serous PED treated with suprachoroidal anti VEGF

**DISCUSSION:**

PED in itself is a non-specific finding, and is generally associated with ocular conditions like CSCR, nAMD, PCV, etc. For the development of serous PED, a spectrum of different mechanisms has been proposed and choroidal hyperpermeability has been implicated in their pathogenesis in the absence of Choroidal neovascularization (CNV).<sup>8</sup> In 1986, Bird and Marshall introduced the concept of age related reduced hydraulic conductivity of Bruch’s membrane. It states that there occurs progressive thickening of Bruch’s membrane due to deposition of lipid that increases its hydrophobicity. This interferes with the RPE pump and creates a barrier to the normal flow of fluid and ions across the Bruch’s membrane towards the choriocapillaries. With time the fluid gets collected beneath the RPE leading to its separation.<sup>9</sup>

Drusenoid PEDs are formed due to gradual coalescence of pre-existing soft drusen in the setting of AMD. This reduces the hydraulic conductivity of the Bruch’s membrane and initiates the cascade of RPE separation.<sup>10,11.</sup>

Hemorrhagic or fibrovascular PEDs are associated with CNV. The neovascularization slowly gains entrance into the sub-RPE space, breaking through the Bruch’s membrane and there it organizes into the fibro-vascular network, subsequently developing into fibrovascular PED. These are “leaky” blood vessels with improper blood-retinal barrier and hence tend to bleed into the sub-RPE space creating haemorrhagic PED.<sup>12,13</sup>

On fundus examination, PEDs appear as well defined dome shaped elevation of RPE, usually within the posterior pole. Serous PEDs have a smooth surface with orangish appearance mean while the drusenoid type have irregular surface with areas of hyperpigmentation. In fibrovascular and haemorrhagic type, due to the presence of CNV or their variants namely Retinal angiomatous proliferation (RAP) and Idiopathic polypoidal chroidal vasculopathy (IPCV), retinal haemorrhages are common finding along with intraretinal or subretinal fluid. As most of the PEDs occur due to the pathophysiological processes taking place beneath the RPE, hence indocyanine green angiography (ICGA) remains the diagnostic modality of choice. It can also differentiate between vascularized and non-vascularized PED. On fundus fluorescein angiography (FFA), serous PEDs exhibit early hyperfluorescence with increasing intensity within a well-defined area whereas drusenoid type show late staining. Both types do not

demonstrate any leakage in contrast to the fibrovascular type where one can notice leakage with stippled or lacy hyperfluorescence on the basis of whether CNV is “occult type” or “classic type” respectively. By OCT one can identify the contents of PED and monitor response to treatment. Drusenoid type may be iso-fluorescent or hyperauto-fluorescent surrounded by a well-defined hypoauto-fluorescent border. Vascular types are atypical and FAF imaging is not well defined hence further FAF studies are required to establish any specific pattern.<sup>4,14</sup>

PEDs tend to have an indolent course and generally remain unchanged over prolonged periods. Intravitreal anti-VEGFs have been tried for the treatment of the fibrovascular types but they are also associated with resistance to therapy. PDT and laser photocoagulation have also been tried with some success. Studies have reported that photothrombosis to the vascular components under ICGA guidance followed by application of laser to feeder vessels have shown satisfactory results in patients of vascular PED. Presently, no treatment has proven effective against serous and drusenoid PED and they may eventually become atrophic and cause permanent visual deprivation. Many even have underlying clinically undetectable CNV hence may progress to their fibrovascular counterpart.<sup>15-18</sup>

Serous avascular PED in clinical practice is managed conservatively with no defined therapeutic indications. Their resistance to treatment leads to patient dissatisfaction with visual compromise. This calls for the collaborative effort from the physician’s part to conduct studies and experiments in order to land up with a successful management protocol for such patients.

In this study we dealt with similar patients with recalcitrant PED who responded to the suprachoroidal injection of anti VEGF as seen by decrease in mean LogMAR visual acuity from 0.59 to 0.15 and resolution of PED on SD-OCT. With the continuous advancements in the medical field a novel route of drug administration; i.e.; suprachoroidal drug delivery, is now under trial run for the management of multiple posterior segment pathologies. Larger volumes, upto 1mL, can be tolerated in SCS which is much larger than required to achieve therapeutic levels hence can also be utilized as a drug depot system. Drug delivery through SCS can even bypass the outer blood retinal barrier and can be utilized to target the RPE. Small gauge needles long enough only to penetrate sclera (0.7-1.0 mm) can be used to perform SCS drug delivery. Taking into consideration such evidences, suprachoroidal drug delivery of anti-VEGF and their promising effects have been put forward through this case series.<sup>19</sup>

All the cases presented with blurred vision with central scotoma which is a usual presentation of serous PED. All of them had taken treatment as some form of intravitreal anti-VEGF along with conservative management but had no or poor visual recovery post injection. Resultant was a recalcitrant serous PED which was quite troublesome. All the patients were then undertaken for suprachoroidal anti-VEGF bevacizumab under topical anaesthesia.

**Comment [A13]:** Compare with previous studies and rewrite the discussion

The patients stated that during injection, they experienced more pain as compared to the intravitreal injections which they had received in past. There was a transient rise in intraocular pressure which was quickly recovered and no pressure lowering drug was needed other than the stat dose of oral acetazolamide 500mg. No adverse events like floaters, RPE tear, ocular infections were experienced. During follow-up visits, the visual recovery was significant and was maintained.

**Comment [A14]:** No data in result

## CONCLUSION

With this case series we concluded that suprachoroidal route of drug delivery is a practical and promising approach of treatment in patients of recalcitrant PED. It is rather safe and can be considered for other retinal pathologies.

Randomized control trial are required to conclude and establish suprachoroidal drug delivery systems as an effective line of management of recalcitrant PED.

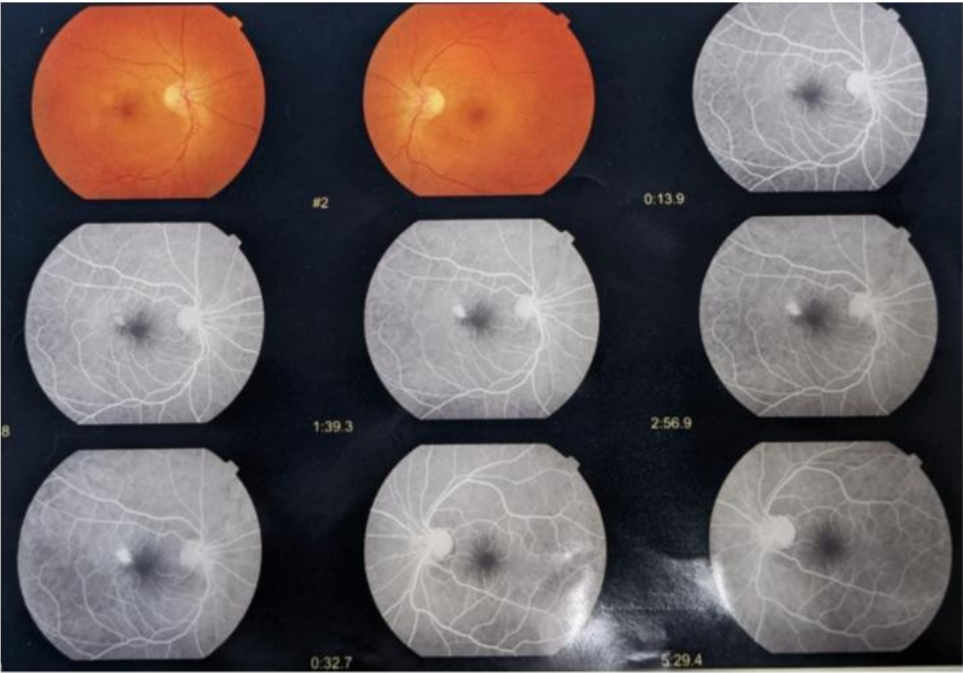
Comment [A15]: Add limitations

## REFERENCES

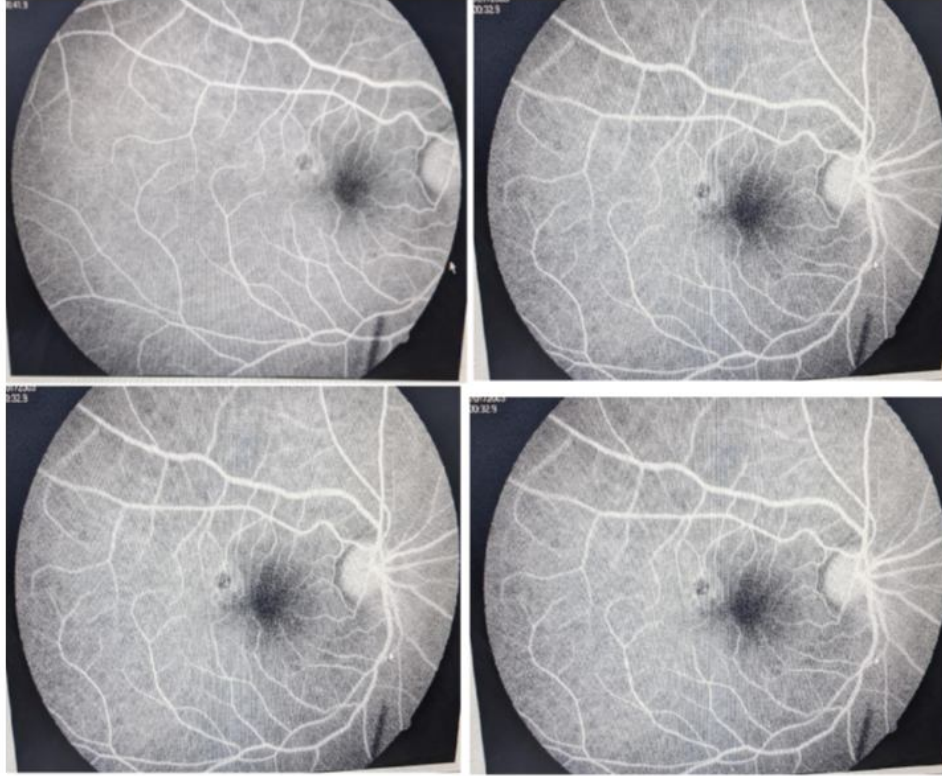1. Zayit-Soudry S, Moroz I, Loewenstein A. Retinal pigment epithelial detachment. *Surv Ophthalmol.* 2007 May-Jun;52(3):227-43.
2. Khochtali S, Ksiai I, Megzari K, Khairallah M. Retinal Pigment Epithelium Detachment in Acute Vogt-Koyanagi-Harada Disease: An Unusual Finding at Presentation. *Ocul Immunol Inflamm.* 2019;27(4):591–594.
3. Wolfensberger, Thomas J., and Adnan Tufail. "Systemic disorders associated with detachment of the neurosensory retina and retinal pigment epithelium." *Current opinion in ophthalmology* 11.6 (2000): 455-461.
4. Mrejen S, Sarraf D, Mukkamala SK, Freund KB. Multimodal imaging of pigment epithelial detachment: a guide to evaluation. *Retina.* 2013;33(9):1735-1762.
5. Krohn J, Bertelsen T. Corrosion casts of the suprachoroidal space and uveoscleral drainage routes in the human eye. *Acta Ophthalmol Scand.* 1997;75(1):32–35.
6. Ferrara D, Mohler KJ, Waheed N, et al. En face enhanced-depth swept-source optical coherence tomography features of chronic central serous chorioretinopathy. *Ophthalmology.* 2014;121(3):719–26.
7. Seiler GS, Salmon JH, Mantuo R, Feingold S, Dayton PA, Gilger BC. Effect and distribution of contrast medium after injection into the anterior suprachoroidal space in ex vivo eyes. *Invest Ophthalmol Vis Sci.* 2011;52(8):5730–36.
8. Goto S, Gomi F, Ueno C, Nishida K. Reduced-fluence photodynamic therapy for subfoveal serous pigment epithelial detachment with choroidal vascular hyperpermeability. *Am J Ophthalmol.* 2012 Nov;154(5):865-71.
9. Bird AC, Marshall J. Retinal pigment epithelial detachments in the elderly. *Trans Ophthalmol Soc U K.* 1986;105(Pt 6):674–82.
10. Casswell AG, Kohen D, Bird AC. Retinal pigment epithelial detachments in the elderly: classification and outcome. *Br J Ophthalmol.* 1985;69:397–403.
11. Bressler NM, Silva JC, Bressler SB, et al. Clinicopathologic correlation of drusen and retinal pigment epithelial abnormalities in age-related macular degeneration. *Retina.* 1994;14:130–42.

12. Macular Photocoagulation Study Group. Subfoveal neovascular lesions in age-related macular degeneration. Guidelines for evaluation and treatment in the Macular Photocoagulation Study. *Arch Ophthalmol.* 1991;109:1242–57.
13. Young RW. Pathophysiology of age-related macular degeneration. *Surv Ophthalmol.* 1987;31(5):291–306.
14. Gass JD, Norton EW, Justice J Jr. Serous detachment of the retinal pigment epithelium. *Trans Am Acad Ophthalmol Otolaryngol.* 1966;70:990–1015.
15. Hoerster R, Muether PS, Sitniska V, Kirchhof B, Fauser S. Fibrovascular pigment epithelial detachment is a risk factor for long-term visual decay in neovascular age-related macular degeneration. *Retina.* 2014;34:1767–73.
16. Verteporfin In Photodynamic Therapy Study Group. Verteporfin therapy of subfoveal choroidal neovascularization in age-related macular degeneration: two-year results of a randomized clinical trial including lesions with occult with no classic choroidal neovascularization--verteporfin in photodynamic therapy report 2. *Am J Ophthalmol.* 2001;131:541-560
17. Elman MJ, Fine SL, Murphy RP, et al. The natural history of serous retinal pigment epithelium detachment in patients with age-related macular degeneration. *Ophthalmology.* 1986;93:224–30.
18. Seiler GS, Salmon JH, Mantuo R, Feingold S, Dayton PA, Gilger BC. Effect and distribution of contrast medium after injection into the anterior suprachoroidal space in ex vivo eyes. *Invest Ophthalmol Vis Sci.* 2011;52:5730–5736.
19. Patel SR, Lin AS, Edelhauser HF, Prausnitz MR. Suprachoroidal drug delivery to the back of the eye using hollow microneedles. *Pharm Res.* 2011;28:166–176.

Fundus fluorescence angiography (FFA) of a patient enrolled in our study



Pre-treatment FFA showing hyper fluorescent area increasing in intensity with time but not in size i.e. pooling of dye typical of serous PED.



Post-treatment FFA showing disappearance of the hyper fluorescent area .

UNDER