

Case Report

Cardiac tamponade : a rare revealing form of hypothyroidism

ABSTRACT :

Hypothyroidism, is a prevalent endocrine disorder with multiorgan involvement, we report a case of primary hypothyroidism with cardiac tamponade in a 50 years old male presented with complaints of dyspnea. A bedside echocardiogram was done, showing Tamponade; pericardiocentesis was immediately performed, two litres of yellow fluid was removed. On laboratory investigation hypothyroidism diagnostic was made due to the presence of high TSH and low T3 and T4

in the presence of tamponade, hypothyroidism should be suspected in patients without sinus tachycardia, . The fluid characteristic in hypothyroid cardiac tamponade goes from clear to yellow,. The prognosis is good after hormone replacement therapy.

KEYWORDS :

Tamponade ; hypothyroidism , pericardiocentesis

INTRODUCTION:

Hypothyroidism, is a prevalent endocrine disorder with a wide range of symptoms and multiorgan involvement [1], characterized by elevated level of serum thyroid stimulating hormone (TSH) with lower or normal free thyroxine (fT4)

In the cardiovascular system (CVS), thyroid hormone plays a vital role in its development and function, mainly mediated by Triiodothyronine (T3). A lack of T3 in hypothyroidism leads to cardiovascular manifestations such as sinus bradycardia, pericarditis, dyslipidemia, and pericardial effusion which can be subclinical or can progress to an overt pathology.

Pericardial effusion in hypothyroidism is described with an incidence of 3–6%, however cardiac tamponade has been rarely reported

we report an uncommon case of primary hypothyroidism revealed by a cardiac tamponade.

CASE PRESENTATION:

A 50 years old male , active smoker without any toxic behaviors and no known comorbidities presented to the emergency department with complaints of progressive dyspnoea of 1 month duration. Dyspnoea has progressed from New York Heart Association Class II to Class IV over the last 10 days prior to his presentation.

He had also a history of lethargy and constipation with complaints of bilateral lower limb swelling without motivation for consult .

On physical examination, his pulse was 56 beats per minute, regular, normal in volume. His blood pressure was 92/60 mm of Hg, respiratory rate was 23c per minute, he displayed peripheral hypoperfusion with cold extremities , sweats with pulsus paradoxus. The rest of the examination found an engorged jugular vein, mild pallor, and non-pitting edema of the extremities. Oxygen saturation (SpO₂) was 89% . Lungs auscultation was clear and cardiac auscultation revealed muffled heart sounds .

The electrocardiogram showed low voltage complexes and electrical alternans (*Figure 1*). Chest X-ray revealed grade III cardiomegaly and suggestive water bottle image.

A bedside echocardiogram was performed (*Figure 2*), showed a large pericardial effusion of 26 mm in regard of RV , 25 mm at the apex level , with swinging heart features , Right Atrium (RA) and Right Ventricle (RV) diastolic collapse and significant transmitral 25% and transtricuspid 50% respiratory flow variation on pulsed wave doppler PW suggesting of tamponade .

Patient was immediately admitted to ICU under non-invasive monitoring, patient was placed in 30° semi-reclining position , we performed an urgent pericardiocentesis , retrieving 2 L- of clear yellow fluid (figure 3).

The patient showed dramatic dyspnea relief with better oxygen saturation raising to 94% from 89% . Control 2-D echocardiogram revealed minimal pericardial effusion with no evidence of tamponade.

On laboratory investigation, complete blood count (CBC), renal function test (RFT), liver function test (LFT), along total serum protein and albumin were normal. thyroid function test was performed, which revealed high thyroid stimulating hormone (>100mUI/l) and low T3 (<1.5 nmol/l) and free T4 (<0.4 nmol/l). Considering these findings, additional studies were performed where the antimicrosome antibody and antithyroglobulin antibody were negatives

Pericardial fluid analysis revealed an exudate with protein 36g/l, LDH 230.0 U/l as well as a normal ADA. Microbial culture was negative and there was no malignancy on cytological evaluation.

Ultrasonography of the thyroid with a high frequency probe featured normal thyroid gland with normal size, echotexture, and normal vasculature.

The patient was discharged after 5 days of admission with Tab. Levothyroxine 50 µg/day and was kept on follow-up, the pericardial effusion was followed up with serial transthoracic echocardiogram without signs of recurrence nor constriction. And Thyroid dosage adjustments were made once in every 6–8 weeks as per TSH to prevent recurrence.

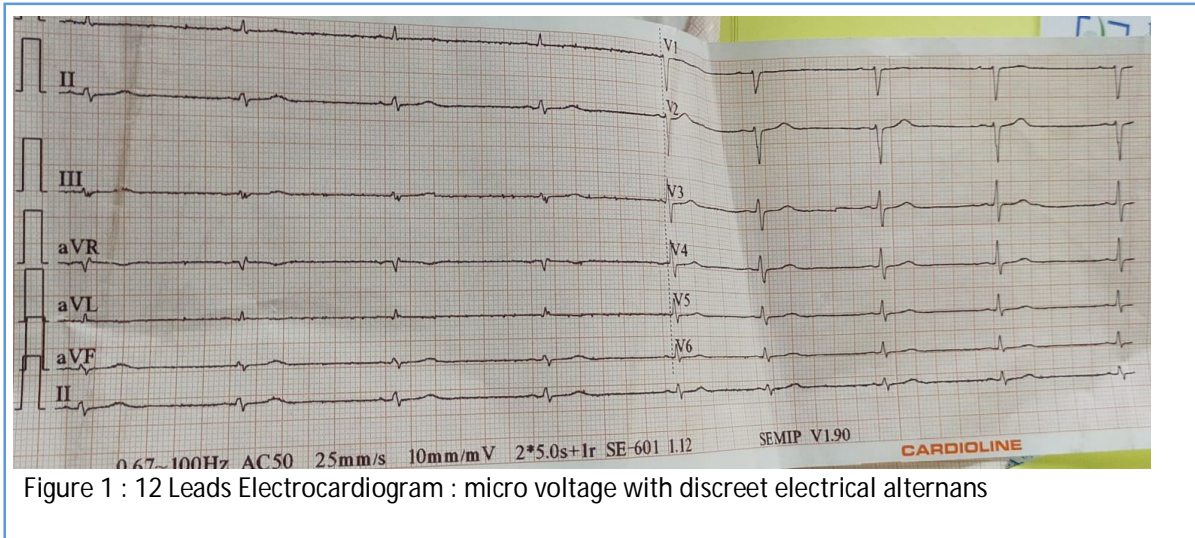


Figure 1 : 12 Leads Electrocardiogram : micro voltage with discrete electrical alternans

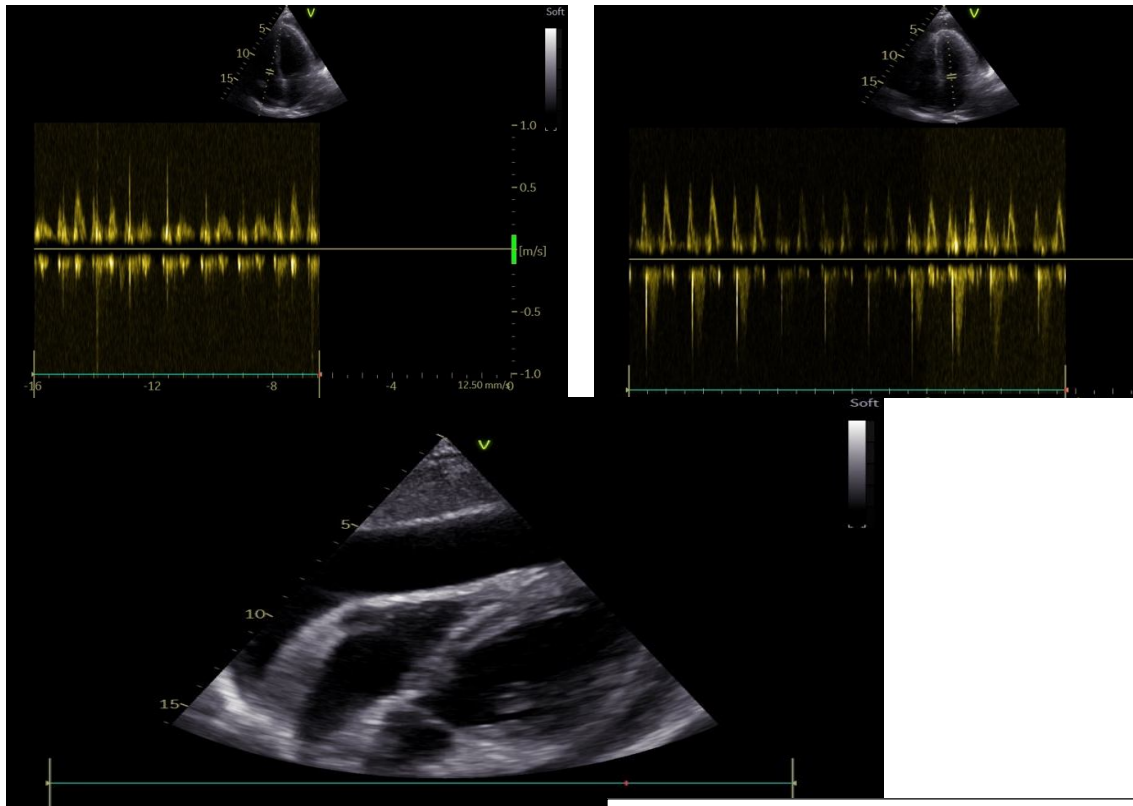


Figure 2 :Echocardiographic findings : large pericardial effusion 26 with significant mitral 25% and tricuspid 50% respiratory flow vari

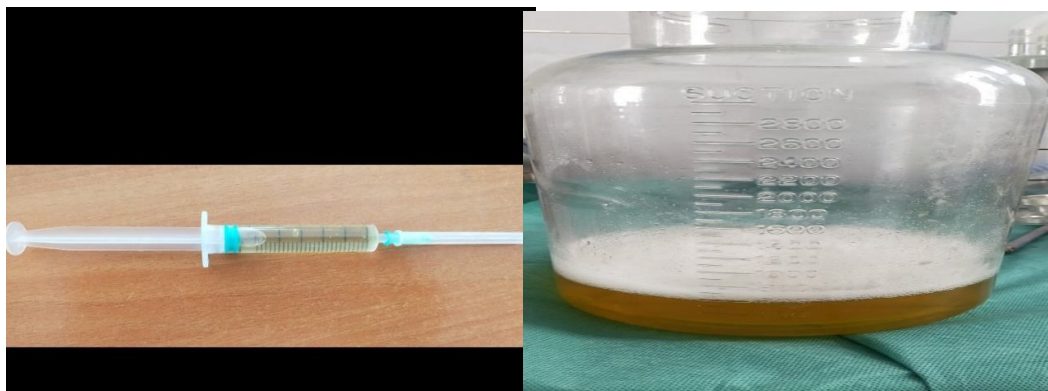

Figure 3 :Clear yellow appearance of pericardial fluid after pericardiocentesis

3. DISCUSSION:

Pericardial effusion is described as the abnormal accumulation of fluid within the pericardial cavity. Such liquid can be either exudate, transudate, pyopericardium, or hemopericardium [2]

A fibroelastic sac contains the heart and proximal great vessels. The pericardium anchors the heart to the mediastinum, provides lubrication, and acts against infection and acute distention of the heart chambers. It is made of two fine leaflets: one serous, visceral, and a fibrous, parietal, leaflet. The visceral leaflet is thin and in intimate contact with the epicardium, whereas the parietal pericardium is an external layer in contact with the thoracic wall [3]

Physiologically, pericardial fluid is formed by ultrafiltration that occurs at the site of pericardial capillaries. Normally, hydrostatic pressure is higher in the arterioles than the pressure in the venules, and the colloid osmotic pressure created by the plasma proteins is essentially the same at both ends. Thus, most of the fluid gets reabsorbed at the venous end, and some of the retained fluid will be drained out via lymphatic drainage[4]

Numerous causes can produce pericardial effusion. Any process which causes inflammation, wounds, or diminishes lymph drainage can cause it. The causes can be divided into inflammatory and non-inflammatory[5]

Metabolic diseases can cause pericardial effusion with signs and symptoms that may direct the diagnosis, like in hypothyroidism, there is low plasma volume, high vascular permeability, lower synthesis and catabolism rates of albumin, and prolonged passage time through the extravascular spaces causing increased albumin mass in the extravascular space [6]

In the presence of tamponade, hypothyroidism should be suspected in patients without sinus tachycardia, patients with hypothyroidism frequently present bradycardia because their heart rate is unable to accelerate at a normal level, although the right chambers are compressed, [7]

The fluid characteristic in hypothyroid cardiac tamponade is typically an effusion, with a color that goes from clear to golden hue, with predominance of lymphocytes and high protein content as in our case. Other superimposed causes like infection, connective tissue disease and trauma were ruled out, but the possibility of spontaneous pericardial hemorrhage also can exist[8] [9] [10]

Treatment depends on the hemodynamic state of the patient. Removal of even a small amount of pericardial fluid (about 50 ml) produces considerable hemodynamic and symptomatic improvement because of the steep pericardial pressure volume relationship

The prognosis is good after hormone replacement therapy. Pericardial effusion generally resolves in 2–12 months. Thyroid replacement alone is sufficient for resolution of these effusions. Pericardiocentesis is indicated only if cardiac tamponade develops. [11] [12]

However, there is a significant risk of recurrent effusion in the first few weeks if euthyroidism is not achieved. It is therefore important to ensure stringent ultrasound monitoring until thyroid function returns to normal. In addition, the presence of chronic effusion justifies prolonged follow-up to ensure that the condition does not progress to constrictive chronic pericarditis

CONCLUSION :

Hypothyroidism presenting with massive pericardial effusion with cardiac tamponade is an uncommon presentation, Thyroid replacement alone is sufficient for resolution of these effusions,. Pericardiocentesis is indicated only if cardiac tamponade develops

CONFLICTS OF INTEREST:

There is no conflict of interest for the present study.

ACKNOWLEDGMENTS:

There is no acknowledgment for the present study.

References

1. Klein, S. Danzi et al Thyroid disease and the heart *Curr. Probl. Cardiol.*, 41 (2) (2016 Feb 1), pp. 65-92,
2. Nainggolan, F.H., Dalimunthe, N.N., Harahap, S., Isnanta, R., Realsyah, T., Safri, Z., et al. (2018) Pericardiocentesis in Massive Pericardial Effusions Due to Hypothyroidism. *IOP Conference Series: Earth and Environmental Science*, 125, Article ID: 012172
3. Vakamudi, S., Ho, N. and Cremer, P.C. (2017) Pericardial Effusions: Causes, Diagnosis, and Management. *Progress in Cardiovascular Diseases*, 59, 380-388

4. Pericardial diseases in patients with hypothyroidism. Chahine J, Ala CK, Gentry JL, Pantalone KM, Klein AL
5. Azarbal, A. and LeWinter, M.M. (2017) Pericardial Effusion. *Cardiology Clinics*, 35, 515-524.
6. Rare presentation of cardiac tamponade in a patient with subclinical hypothyroidism. Almani MU, Usman M, Arif AW, Ayub MT, Fatima N.
7. Foley, C.M., McAllister, R.M. and Hasser, E.M. (2001) Thyroid status influences baroreflex function and autonomic contributions to arterial pressure and heart rate. *American Journal of Physiology—Heart and Circulatory Physiology*, 280, H2061-H2068.
8. Goswami, R., Tandon, N., Singh, B., et al. (1996) Circulatory collapse in a 30-year-old amenorrheic woman. *Post-graduate Medical Journal*, 72, 501-509.
9. Wang, J.L., Hsieh, M.J., Lee, C.H., et al. (2010) Hypothyroid cardiac tamponade: Clinical features, electrocardiography, pericardial fluid and management. *The American Journal of the Medical Sciences*, 340, 276-281.
10. Hurtado, J.J., Guevara, W., Ramos, E., et al. (2011) Hypothyroidism in a five-year-old boy with rhabdomyolysis and recent history of cardiac tamponade: A case report. *Journal of Medical Case Reports*, 5, 515-519.
11. [Cardiac tamponade: a rare manifestation of hypothyroidism]. *Pan Afr Med J* 2015;22:104.
12. Massive pericardial effusion caused by hypothyroidism. *Clin Case Rep* 2018